ee.com, for detailed information on cardiology books, visit our website www.ejaypee.com, for detailed information on cardiology books

Complimentary
Online Videos



CATH LAB PRACTICALS

Sundeep Mishra

Forewords
Prof Ron Waksman
Prof Samin Sharma

JAYPEE

Contents

Chapter 1 Slippery when Wet: Broken Guidewire, Ruptured Balloon in Cath Lab **1**
Sundeep Mishra, Gautam Sharma

• Fractured Guidewire *1* • Nondeflation of Balloon *5* • Balloon Rupture *8*

Chapter 2 If You Break it—You Own it: Embolization of Cath Lab Hardware **12**
Sundeep Mishra, Ranjit K Nath

• Stent Embolization *12* • Embolization of Other Coronary Hardware *20*

Chapter 3 Interventions for Left to Right Shunts—To Plug or not to Plug: That is not the Question **22**
Saurabh Kumar Gupta, Sivasubramanian Ramakrishnan

• Device Malposition and Embolization *23* • Cardiac Perforation and Erosion *29* • Impingement of Adjacent Cardiac Structures *30*
• Arrhythmia and Conduction Blocks *30*
• Air Embolism and Thromboembolism *30*

Chapter 4 Delicate Sound of Thunder: Coronary Perforations **32**
Sundeep Mishra, Neeraj Parakh

• Types of Perforations *32* • Factors Predisposing to Perforation *32*
• Clinical Outcomes of Perforation *33* • Management of Perforation *34*
• Guidewire Perforation *39*

Chapter 5 Bark at the Moon: Technical Difficulties in Cath Lab **42**
Sundeep Mishra, Rakesh Yadav

• Wire not Crossing *42* • Wire Crossing but Balloon not Crossing *43*
• Failure of the Balloon to Expand *48* • Difficulty in Stent Positioning *50*
• Stent not Expanding *51* • Concertina Effect after Guidewire Insertion *52*

Chapter 6 Honey I Shrunk the Stent: Issues in Stent Implantation **56**
Sundeep Mishra, Ranjit K Nath

• History of Stent Technology *56*

Chapter 7 Cannulation Blues: Issues with Guide Catheter **73**
Sundeep Mishra, Sunil Verma

• Guiding Catheters *73* • Native Coronary Arteries *75*
• Saphenous Vein Grafts *76* • Internal Mammary Artery *76*
• Anomalous Origin of Artery *77* • Exchange of Guide Catheter *81*

Chapter 8 Valvular Interventions: Keep Your Eyes on the Door and Your Mind on the Procedure **82**
Neeraj Parakh, Sundeep Mishra

• Balloon Mitral Valvotomy *82* • Tackling Complications *84*

Chapter 9 Management of Resistant Thrombus: Catastrophe and the Cure **90**
Sundeep Mishra, Neeraj Parakh, Marta Bande

• Huge Thrombus Burden *90* • Pathophysiology of Thrombus Containing Lesions *91* • Evaluation of Thrombus Containing Lesions *91*
• Management of Resistant Thrombus/Distal Embolization: Current Strategies *94*

Chapter 10 Complications of Rotablation and its Management **103**
Zehra Husain, Gianluca Rigatelli, Ramesh Daggubati

• Clinical Complications *103* • Angiographic Complications *104*
• Adjunctive Therapies *106* • Device Complications *107*

Chapter 11 Extremely Sick Patient: Role of Cardiac Assist Devices **116**
Ramesh Daggubati, Gary Nash, Sundeep Adusumalli, Narasimha Swamy Gollol Raju

• Levels of Cardiogenic Shock *124*

Chapter 12 Complications of Radial Access: Children of a Lesser God **127**
S Anandraja

• Radial Artery Spasm *127* • Radial Artery Occlusions *129*

Chapter 13 Momentary Lapse of Reason: Mortality in Cath Lab **136**
Sundeep Mishra, Neeraj Parakh

• Background *136* • Factors before the Procedure *137*
• Factors During the Procedure *141* • Factors After the Procedure *145*
• How to Prevent Mortality? *148*

Index *151*

Chapter 4

Delicate Sound of Thunder: Coronary Perforations

Sundeep Mishra, Neeraj Parakh

Perfect is the Enemy of Good

INTRODUCTION

Coronary perforations, albeit rare, are one of the most dreaded complications occurring in cath lab, perhaps because of high morbidity and mortality associated with it. The incidence varies from 0.2% to 0.6% but is higher with plain balloon angioplasty (0.61%) or with a debulking procedure (1%) like rotablation, cutting balloon or directional atherectomy.[1-5] The incidence is reduced with the use of stents (0.16%) but is unaffected by the use of IIb/IIIa antagonists.[5]

TYPES OF PERFORATIONS

Coronary perforations are graded according to anatomic classification proposed by Ellis and co-workers.[3] **Type I** = crater extending outside the lumen only in the absence of linear staining angiographically suggestive of a dissection; **Type II** = pericardial or myocardial blush without an exit hole ≥1 mm; **Type III** = frank streaming of contrast through an exit hole ≥1 mm; and **Type III Cavity Spilling** = perforation into an anatomic cavity chamber such as the coronary sinus, the right ventricle, left ventricle, etc. In addition there is another type of **Localized Perforation** which occurs postcardiac surgical procedures like coronary artery bypass grafting (CABG). The importance of this classification lies in the fact that it is co-relative of major clinical outcomes and therefore also the treatment strategy to be used.

FACTORS PREDISPOSING TO PERFORATION

Anticipation of patient and lesion characteristics is the most important step in the management of this complication and therefore a careful assessment of predisposing factors must be made in each and every case. The predisposing factors can be clinical, angiographic or technical **(Table 4.1)**. These factors may predict not only occurrence of perforation but also severity and may even influence the treatment decisions. Complex coronary anatomies are perhaps most important predictors of perforation and some co-relation exists between ACC/AHA lesion Class B2/C.[6] Among technical factors, the

Table 4.1 Predisposing factors of perforation

Clinical
• Advanced age
• Female gender
• Previous coronary artery bypass grafting (CABG)
Lesion morphology
• Calcific lesions
• Chronic total occlusion (CTO)
• Tortuous lesions
• Long lesions
• Eccentric lesions
• Ostial lesions
• Right coronary artery (RCA) lesions
• Fragile venous grafts
Technical factors
• Use of ablative devices
• Non use of stents
• Less use of intravascular ultrasound (IVUS)
• Use of hydrophilic and chronic total occlusion wires
• Use of extraction devices
• Device oversizing
• Use of high inflation pressures

use of atheroablative techniques resulted in a higher incidence of perforation (odds ratio of 16.3) and an increased severity of perforation type (odds ratio 28.9 for development of Type III perforation in atheroablative versus non-atheroablative techniques).[6,7] Attempts to over do the procedure like use of high inflation pressures and oversized balloon are also co-relative of perforation, amply justifying the idiom that '*perfect is the enemy of good*.' Surprisingly, no association existed between abciximab use with either the incidence or the angiographic classification of coronary perforation.

CLINICAL OUTCOMES OF PERFORATION

The clinical outcomes after perforation vary from innocuous to pericardial tamponade to MI, cardiogenic shock and need for CABG to cardiac arrest and death (up to 20% in Type III perforations). However, it should be remembered that most cases of perforations are not accompanied by any clinical sequel. The outcomes are determined to a large extent by the severity of perforation as defined by its classification, use of IIb/IIIa antagonists and occurrence

Table 4.2 Clinical outcomes after perforation

Classification	*Pericardial tamponade*	*MI*	*CABG*	*Death*
Type I	8%	0%	15%	0%
Type II	13%	14%	10%	0%
Type III	63%	50%	56%	19%
Cavity spilling	0%	0%	0%	0%
Contained perforations	6%	0%	24%	6%

of guidewire perforation **(Table 4.2)**. Ajluni and co-workers also found that overall clinical outcomes were worse for patients with free perforations (tamponade 20%, CABG 60%, death 20%) than with contained perforations (tamponade 6%, CABG 24%, death 6%).[6]

MANAGEMENT OF PERFORATION

Like in so many other complications, anticipation is the key to management of perforation. Thus patients with complex coronary anatomies or in those patients where use of adjunctive devices like rotablation is contemplated this problem should be anticipated and actively prevented. The best way of prevention of perforation is adequate lesion preparation. However once perforation happens it should be treated according to classification of perforation.

While Type I and Cavity Spilling perforations require no special treatment other than close observation because of their innocuous nature. Type II perforation also does not require much more than prompt recognition, discontinuation of glycoprotein IIb/IIIa antagonist and serial echocardiograms on follow-up. If however, cardiac tamponade develops (rare), immediate pericardiocentesis, prolonged balloon tamponade and blood transfusions and autotransfusions may be required. If patient develops myocardial infarction or intractable ischemia CABG may be required as a last resort.

The management of Type III perforation could however be more complex **(Flow chart 4.1)**. Conceptually, 2 treatment streams are simultaneously pursued. Attempts are typically made towards (a) hemodynamically stabilizing the patients (pericardiocentesis, blood and autotransfusions, intra-aortic balloon pump (IABP) and other cardiac support) and (b) sealing the leaking artery (prolonged balloon tamponade, tamponade with perfusion balloon, discontinuation of 2b/3a antagonists, reversal of heparin, intravenous platelet transfusions, or use of interventional sealing device like covered stent, autologous vein graft, makeshift stent sandwich, micro-coil embolization, injection of thrombin, fibrin glue, autologous clots, subcutaneous tissue, polyvinyl alcohol or gel foam. Open repair of the leaking artery along with CABG may be the last option.

Flow chart 4.1 Treatment algorithm of type III perforation

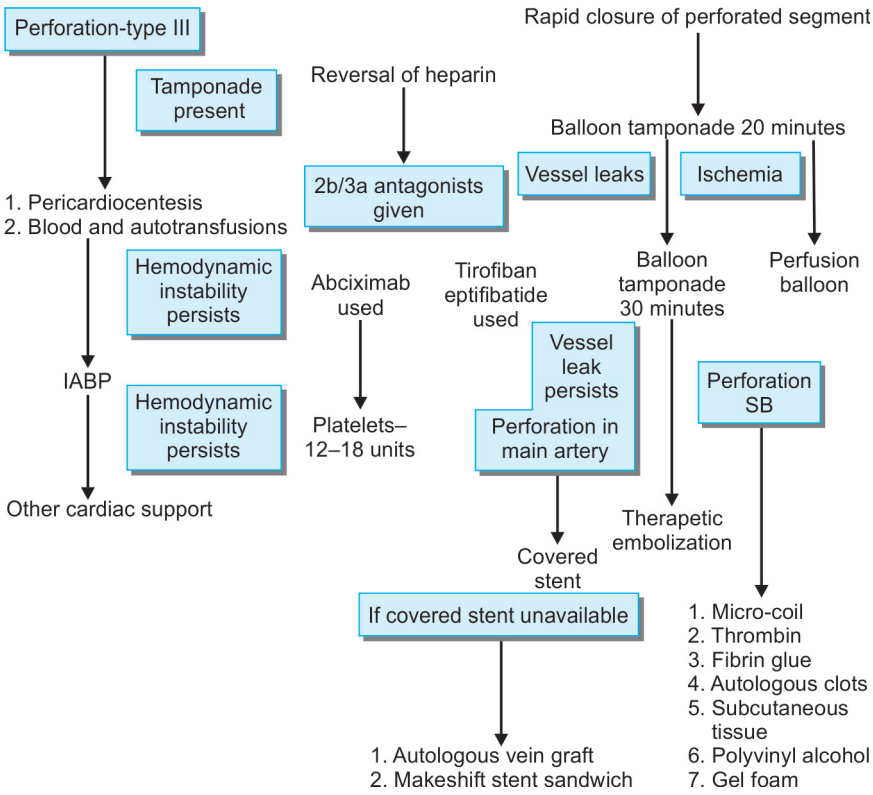

Sudden accumulation of blood in the pericardial space may lead to pericardial tamponade and even death. Therefore, prompt recognition, pericardial aspiration and rapid closure of perforated segment is crucial to reverse the fatal cascade. This generally involves immediate balloon tamponade of leaking vessel, rapid reversal of anti-coagulation and/or anti-platelet therapy, addressing hemodynamic instability, involvement of surgeons if appropriate, and specific treatment of leaking vessel with a bail-out device such as a covered stent or embolization coils. For addressing the leaking vessel generally balloon tamponade is the first treatment option and may be the only maneuver required in majority of cases. A balloon (with a balloon to artery ratio ~1.0) should initially be positioned over the site of perforation and inflated for at least 20 minutes. If the patient is unable to tolerate ischemia during balloon inflation, a perfusion balloon should be used. Perfusion balloons allow distal vessel perfusion, thereby reducing ischemia during prolonged inflations. Subsequently immediate attention should be directed towards reversal of heparin with the aim to achieve a PTT < 60 sec or ACT < 160. Usually, IV protamine sulfate is required to achieve this.[8] If abciximab is used platelet transfusion may be useful but it

does not work if small molecules (eptifibatide or tirofiban) are used for IIb/IIIa antagonism. In minority of cases if the vessel still continues to leak, definitive percutaneous therapy may be required. The major advance in this context is the development of a covered stent. Polytetrafluoroethylene (PTFE) covered stents can successfully seal the site of coronary perforation and consequently can lead to a decrease in mortality and the need for emergency surgery. However, the utilization of these devices may be limited by availability of covered stents in labs and limitation in available sizes contributing to marked under-utilization of this strategy.[6,9] In case of non-availability of this device other strategies to seal the leaking vessel like autologous vein graft and makeshift stent sandwich can also be attempted.[10,11] If the perforation is not in the main vessel but involves small, clinically insignificant side-branch, therapeutic embolization may be attempted. While there may be several ways by which it can be technically achieved (thrombin, fibrin glue, autologous clots, subcutaneous tissue, polyvinyl alcohol or gel foam), micro-coil embolization remains the most popular of all.[12] After achieving stabilization patient is further monitored in CCU and serial echocardiograms performed for at least 48 hours.

CASE EXAMPLES

Case 1

A 62-year-old male patient presented with recent worsening of angina since last 3 months. Echocardiogram revealed regional wall motion abnormalities (hypokinesia) in inferior territory. Coronary angiogram revealed a CTO of RCA with collaterals from LAD. Patient was taken up for angioplasty of RCA. Lesion cannulated with JL guiding catheter, lesion attempted to be crossed with 014 penetrating tip guidewire. However, despite repeated attempts wire could not cross and patient developed Type 1 dissection. In view of the dissection the procedure was abandoned and patient remained stable on follow-up and is scheduled for another PCI procedure for RCA.

Analysis of the case: Patient had CTO of RCA and a penetrating wire was chosen. CTO lesion morphology is more prone to developing perforations and so is the use of penetrating wire. Type I dissections are generally innocuous and by themselves may not require any treatment.

Case 2

Hypertensive, diabetic, 58-year-old post CABG patient done 12 years earlier presented with rest angina. Coronary angiogram revealed Native LAD disease with tight lesion in mid LAD, diffuse LCx disease 40–50% and diffuse RCA disease. LIMA to LAD was occluded but SVG to OM and PD were patent but 60% disease in ostial SVG to RCA graft. Patient was planned for PCI to native LAD and SVG to RCA. LAD was hooked with XB catheter, lesion crossed with BMW™ wire and dilated with 2.5 × 15 semi-compliant balloon.

However, waist was persisting in mid-LAD, therefore the lesion was dilated with 2.75 × 12 semi-compliant balloon. On check angiogram there was a cavity spilling perforation. The patient remained hemodynamically stable and the procedure was abandoned and patient carefully monitored in CCU. Patient was discharged in a stable condition.

Analysis of the case: Patient probably had a fibrotic lesion in LAD which was more resistant to opening. At this stage, may be cutting balloon or even Rota may have helped. However, use of over-sized balloon (for the artery) at high pressure led to the perforation. Luckily, it was Type III Cavity Spilling Perforation which really only causes coronary-ventricular fistula and therefore, by itself generally does not require any treatment.

Case 3

Hypertensive, 58-year-old male presented with recent onset, crescendo angina. Coronary angiogram revealed left coronary system normal but total occlusion from mid-RCA. RCA was cannulated with JL 3.5 guiding catheter, lesion attempted cross with 014 hydrophillic guidewire, but the guidewire could not cross. A rapid exchange balloon was taken to improve the guidewire support, but still the guidewire could not cross. A check angiogram was taken and revealed a ghastly intramyocardial perforation. Bed-side 2D-echocardiography revealed no fluid in the pericardium. Patient remained hemodynamically stable, therefore masterly inactivity was planned and patient observed in CCU for 48 hours and ultimately discharged after 5 days in a stable condition.

Analysis of the case: Again an occlusive lesion of RCA which can predispose to perforation. In this case wire was not crossing (was most likely lodged in the false lumen), but inability to cross was construed as a tough lesion and was forced to cross by taking an additional support by an OTW balloon. This forcing in the false lumen led to extrusion of wire tip out of vessel wall but fortunately not in pericardium but in myocardium leading to development of intramyocardial perforation. By itself intramyocardial perforation if it remains stable may require no treatment other than reversing the effect of heparin.

Case 4

A 62-year-old post CABG patient (done 15 years earlier), diabetic presented with NYHA Class angina of 6 months duration. Coronary angiogram revealed native triple vessel disease, mild left main, LAD calcific and diffusely diseased, diffuse disease in LCx-OM territory, RCA occluded, anastomotic tight lesion in LIMA to LAD, SVG to OM1 and OM2 patient and SVG to RCA occluded. Patient was planned for PCI to native occluded RCA followed by PCI to LIMA-LAD stenosis. RCA was cannulated with JL guiding catheter, but adequate support could not be obtained. The lesion was crossed with 014 hydrophilic guidewire. The presence of distal guidewire tip in true lumen was confirmed

by filling the distal RCA via injection through microcatheter. The occluded portion of RCA was sequentially dilated with 1.5, 2, 2.5 and 2.75 semi-compliant balloons at 15–20 atm. However, the waist in mid-RCA was still persisting. Finally, the lesion was dilated with 3 × 15 semi-compliant balloon at 22 atm but the waist was still persisting. Meanwhile, patient complained of severe chest pain and started dropping pressures. Check angiogram revealed a Type III perforation. Immediately heparin was reversed and balloon tamponade of proximal RCA (keeping from true to true lumen) was instituted and continued for 20 minutes. The patient stabilized. Echocardiography revealed mild pericardial effusion. Subsequent to tamponade angiogram revealed the leak had stopped but another angiogram few minutes later revealed re-leak. Another balloon tamponade was instituted for 30 minutes and subsequently a Jomed Jo™ Stent Graft 3 × 26 mm at 16 atm taking great care that the stent is deployed from "true lumen to true lumen." Subsequent to the stent graft deployment patient stabilized but there was no flow in RCA and the procedure was abandoned. Patient was carefully monitored in CCU for 48 hours and discharged in a stable condition.

Analysis of the case: Again RCA occlusion was attempted to be crossed. Most likely hydrophilic guidewire initially crossed into false lumen and then subsequently re-crossed into true lumen (as evidenced by filling of the distal RCA after injection was made through the microcatheter. So, when balloon was dilated, part of it was dilated in the false lumen. However, the false lumen could not accommodate the final balloon dilatation with the larger balloon and that probably lead to perforation. Once patient developed perforation he was managed by reversal of heparin and balloon tamponade. This technique did stabilize the patient and even sealed the perforation for some time but there was a tendency for re-leaking. As such a covered stent was deployed making sure that it extended from true lumen to true lumen.

Case 5

A 71-year-old female, PO CABG '91, hypertension, hyperlipidemia, DJD, hypothyroidism, post-tubal ligation. Stress Thallium revealed reversible ischemia in lateral territory. Coronary angiogram revealed native triple vessel disease, LAD occluded; significant calcific lesion in OM and RCA was occluded. LIMA to LAD was patent but SVG to PD and OM were occluded. Patient was planned PCI of OM. LCA cannulated with 7F 3.5 CLS guide catheter and the OM lesion crossed with PTGI™ guidewire. The guidewire was exchanged over OTW balloon with a Rota Floppy™ guidewire. 1.5 mm Rota burr was chosen and a total of 8 runs made (total time 115 sec). Angiogram after rotablation revealed a type II perforation. Patient complained of chest pain but remained hemodynamically stable. Urgent echocardiogram revealed a mild pericardial effusion with no evidence of tamponade. Heparin was reversed and LCx rewired with PTGI wire and rota wire removed. Subsequently, balloon tamponade was carried out with 2 × 20 balloon at 6 atm for 285 sec. However, as the perforation was persisting, another attempt at balloon tamponade was made for another 255 sec. Check angiogram revealed persisting perforation.

In view of persisting perforation a covered stent (Jomed Jo™ Stent) 2.75 × 26 was deployed at 16 atm. However, subsequent angiogram revealed worsening in the grade of perforation from Type II to Type III. Chest pain increased and patient became hemodynamically unstable. Echocardiogram revealed increasing effusion. LCx was rewired with BMW™ wire and PTGI™ wire removed. Another attempt at balloon tamponade with 2 × 20 balloon made followed by deployment of another Jomed Jo™ Stent Graft 2.75 × 18. These procedures lead to partial sealing of perforation but it was still persisting. Patient got stabilized and relived of chest pain. However, in view of persisting perforation patient was sent for CABG.

Analysis of the case: Calcific lesions and use of rotablation have a higher chance of developing perforation. Perforations with rotablation are generally caused when rota burr fails to advance and gets stuck in the same position (with loss of speed). Here the perforation can occur because of maldirection of the burr consequent to wire bias. Perforation less than Type III generally require no treatment unless accompanied by hemodynamic compromise or pericardial tamponade. In this case implantation of covered stent was executed in type II perforation with disastrous consequence because probably it was deployed partly in false lumen. Subsequently the lesion was rewired and another covered stent deployed with only partial sealing of the defect. In patients where interventional treatment fails or only partially successful one should not shy away from sending the patient to bypass surgery.

GUIDEWIRE PERFORATION

Guidewire perforations are the 2nd most common mechanism of perforation (only less common than balloon induced perforations: compliant or noncompliant balloons and the stent-balloon delivery system) occurring in nearly half the cases in some series.[5,13] Typically, these perforations do not manifest early but in as many as half the cases the pericardial effusion or tamponade may become clinically manifest only after several hours following the coronary procedure.[6] While in many cases minor perforation is missed during the procedure, in some cases it may not be angiographically obvious at the end of the procedure. The mechanism of this kind of perforation is a leak from a minor vessel, slowly filling up the pericardium and manifesting later. While most such cases occur in context of distal branch puncture with the guidewire tip such as a hydrophilic wire and the administration of glycoprotein IIb/IIIa antagonist, it may also be associated with use of debulking devices like cutting balloon and rotablator. **Table 4.3** enumerates the mechanisms of guidewire perforations.[5] Most guidewire perforations are of the type I and II perforations predominantly caused by hydrophilic and stiff wires, and do not require pericardial drainage or surgical intervention. However, many guidewire perforations can be type III as well and because they are usually "relatively small leaks" in the distal coronary bed or a side branch, they may be successfully treated by coiling or particle embolization technology.

Table 4.3 Mechanism of guidewire perforations

Mechanism	*Incidence*
Procedural characteristic	
Crossing lesion	51%
Distal wire penetration	30%
Wire fracture	10%
Hardware characteristic	
Hydrophllic wire	50%
Standard and intermediate wires	14%
Floppy tip wires	29%
Rotawire	11%

CASE EXAMPLE

Case 6

A 46-year-old lady presented with NYHA Class III angina. Coronary angiogram revealed long tight mid-RCA lesion. RCA engaged with JR 3.5 guiding catheter and lesion crossed with 014 guidewire. It was stented with 3.5 × 32 drug eluting stent (Biomime™) and post-dilated with 3.5 × 12 Sprinter NC™ balloon at 18 atm for 30 sec. Angiogram after the procedure showed a good end result. Five hours after the procedure patient developed severe chest pain along with hypotension. Echocardiography revealed large pericardial effusion with tamponade. Tamponade was immediately drained and patient brought to cath lab for a check shoot. Angiogram revealed Type III perforation in the proximal part of the stent. RCA engaged with the guiding catheter, wired and a covered stent 3.5 × 19 deployed at 14 atm for 30 sec. Finally there was a good end result.

Analysis of the case: Generally delayed perforations are guidewire related (being associated with hydrophilic or penetrating guidewires); however, occasionally they could be related to other cause. In this particular case the perforation arose as a result of proximal edge dissection which manifested late probably due to straining by the patient during the course of observation in CCU. In many cases guidewire perforations are innocuous leaks at the most requiring a pericardial tap. The only point of interest being awareness of the CCU physician of this phenomenon post-procedurally. Once the condition is suspected it warrants an immediate performance of echocardiogram to diagnose and a pericardial tap. Occasionally, however, it can be more malignant requiring definitive treatment of the perforation and in some cases if the treatment is delayed even mortality may ensue. In this particular case, the gravity of situation was recognized and corrected by use of a covered stent.

CONCLUSION

Perforations in cath lab are rare but dreaded complication because of serious morbidity and even associated mortality. As always "prevention is better than cure", the predisposing factors like CTO, use of hydrophilic wires or athero-ablative procedures should be carefully accounted. Once perforation happens recognizing the type of perforation is very important because some varieties (Type I, intramyocardial or cavity spilling perforations) may require no treatment except monitoring and masterly inactivity. On the other hand for more serious perforations a careful well defined approach (treatment algorithm) should be pursued.

REFERENCES

1. Lansky AJ, Yang YM, Khan Y, Costa RA, Pietras C, Tsuchiya Y, et al. Treatment of coronary artery perforations complicating percutaneous coronary intervention with a polytetrafluoroethylene-covered stent graft. Am J Cardiol. 2006;98(3):370-4.
2. Shirakabe A, Takano H, Nakamura S, Kikuchi A, Sasaki A, Yamamoto E, et al. Coronary perforation during percutaneous coronary intervenetion. Int Heart J. 2007;48(1):1-9.
3. Ellis SG, Ajluni S, Arnold AZ, Popma JJ, Bittl JA, Eigler NL, et al. Increased coronary perforation in the new device era. Incidence, classification, management, and outcome. Circulation. 1994; 90(6):2725-30.
4. Shimony A, Zahger D, Van Straten M, Shalev A, Gilutz H, Ilia R, et al. Incidence, risk factors, management and outcomes of coronary artery perforation during percutaneous coronary intervention. Am J Cardiol. 2009;104(12):1674-7.
5. Witzke CF, Martin-Herrero F, Clarke SC, Pomerantzev E, Palacios IF. The changing pattern of coronary perforation during percutaneous coronary intervention in the new device era. J Invasive Cardiol. 2004;16(6):257-301.
6. Ajluni SC, Glazier S, Blankenship L, et al. Perforations after percutaneous coronary interventions: clinical, angiographic, and therapeutic observations. Cathet Cardiovasc Diagn. 1994;32(3):206-12.
7. Rogers JH, Lasala JM. Coronary artery dissection and perforation complicating percutaneous coronary intervention. J Invasive Cardiol. 2004;16(9):493-9.
8. Briguori C, Di Mario C, De Gregorio J, et al. Administration of protamine after coronary stent deployment. Am Heart J. 1999;138:64-8.
9. Briguori C, Angelo A, Nishida T, et al. Emergency polytetrafluoroethylene-covered stent implantation to treat coronary ruptures. Circulation. 2000;102:3028-31.
10. Caputo R, Amin N, Marvasti M, et al. Successful treatment of a saphenous vein graft perforation with an autologous vein-covered stent. Cathet Cardiovasc Intervent. 1999;48:382-6.
11. Pienvichit P, Waters J. Successful closure of coronary artery perforation using makeshift stent sandwich. Cathet Cardiovasc Intervent. 2001;54:209-13.
12. Assali A, Moustapha A, Sdringola S, et al. Successful treatment of coronary artery perforation in an abciximab-treated patient by microcoil embolization.
13. Eeckout E, Palma R. Coronary Perforation. An inconvenient complication. J Am Coll Cardiol Intv. 2011;4(1):96-7.

If I were a swan, I'd be gone.
If I were a train, I'd be late again.
If I were a good man, I'd talk with you
More often than I do.

detailed information on cardiology books, visit our website www.ejaypee.com, for detailed information on cardiology books, visit our we

CATH LAB PRACTICALS

During our day-to-day work in catheterization lab, we encounter several problems. They may range from something simple like "wire crossing but balloon not crossing" to something more drastic such as "migration of thrombus in left main". Unfortunately, anybody who really has a significant volume of percutaneous coronary intervention (PCI) has faced this scenario (however skilled he/she may be). But, still there is a tendency to brush really serious complications like mortality under the carpet. On the other hand, these are the very cases where there is a maximum opportunity to learn. Further, there may be several alternate strategies to tackle these practical problems but they are not discussed in any book since there are no randomized controlled trials (RCTs) in this area.

In this manual, we discuss threadbare what went wrong (whether it was a wrong selection of case, wrong selection of hardware or technique), where exactly did it go wrong and finally what corrective steps were undertaken so that the situation could be salvaged. We feel that in this area, where no RCTs are available the best way to learn is by errors and tribulations of others and by building a mental library of the cases, so that one is prepared when a similar situation arises.



Sundeep Mishra MD DM FACC FSCAI is Professor, Department of Cardiology, All India Institute of Medical Sciences (AIIMS), New Delhi. He did his DM (Cardiology) from AIIMS, and did his Fellowship in Interventional Cardiology from Washington Hospital Center, USA. He is the Honorary Editor of Indian Heart Journal and in the past has been Guest Editor of Catheterization and Cardiovascular Interventions Journal. He is former Chairman of National Intervention Council of Cardiological Society of India (CSI). He is a Board of Trustees of the Society for Cardiac Angiography and Interventions (SCAI), USA. He is the Course Director for Transcatheter Cardiovascular Therapeutics (TCT), India, EuroCHORUS, SCAI Advanced Course and SIM. He was awarded Young Leader Award by Cardiovascular Revascularization Therapeutics (CRT), Washington DC, USA, and has been awarded Sujoy B Roy Young Investigator Award and KL Chopra Award by CSI. He was the first person to do Virtual Histology, Experimental Angiogenic Gene Therapy in India and he developed the Rat Hindlimb Ischemia Model for the first time in India. He has more than 200 manuscripts, abstracts and book chapters to his credit and has delivered several orations.

Shelving Recommendation
CARDIOLOGY

ISBN 978-93-5250-185-4

9 789352 501854

Buy from ejaypee

JAYPEE BROTHERS