trics & gynecology books, visit our website **www.jaypeebrothers.com,** for detailed information on obstetrics & gynecology books

Actocardiogram

Analysis of Fetal Motion and Heart Rate



Kazuo Maeda

JAYPEE

Contents

1. Electronic Fetal Monitoring and Cardiotocogram 1
   - The First Production of Fetal Heart Rate Monitor in Japan *2*
   - Diagnosis of Nonreassuring Fetal States in the FHR Monitoring *3*
   - Ultrasonic Doppler Autocorrelation Fetal Heart Rate Monitor *3*
   - Quantitative NRFS Diagnosis by FHR Score in the FHR Monitoring *5*
   - Controversies in the Cardiotocogram Diagnosis *7*
2. Actocardiogram 10
   - Terminology *10*
   - History of Actocardiogram *12*
   - The Principle of Actocardiogram *15*
3. Fetal Response to Acoustic and Visual Stimulation 22
   - Methods *22*
   - Results *23*
   - Discussion *24*
4. Prediction, Evaluation and Management of Hypoxia in Fetal Growth Restriction 25
   - Prediction of Hypoxia *25*
   - Diagnosis of Hypoxia in Fetal Growth Restriction *26*
   - Management of Hypoxia in FGR *27*
5. Actocardiographic Studies on Fetal Central Nervous System Lesions 28
   - Methods *29*
   - Results *31*
   - Discussion *34*
6. Short- and Long-term Fetal Outcomes of Fetal Disorders Determined by the A/B Ratio of Actocardiogram 35
   - Methods *35*
   - Results *37*
   - Discussion *39*
7. Developments of Fetal Heart Rate Acceleration and Baseline Variability Analyzed with Actocardiogram Regarding Fetal Brain Damage 42
   - Methods *43*
   - Results *45*
   - Discussion *48*

8. Automatic Computerized Analysis and Diagnosis of Fetal Heart Rate: The Expert System on Fetal Heart Rate 53
- Prototype Automated FHR Monitors *53*

9. Artificial Neural Network Computer Diagnosis of Fetal Heart Rate 55

10. Computerized Actocardiogram for the Diagnosis of Fetal Behavior 56
- Methods *56*
- Results and Discussion *56*

11. Computer Diagnosis of Sinusoidal FHR and the Loss of Variability with Frequency Spectrum Analysis 58
- Sinusoidal Heart Rate Diagnosis *58*
- Loss of Baseline Variability *59*

12. Centralized Automatic Diagnosis of Fetal Heart Rate with Rapid and Direct Alarm System 60
- Methods *60*

13. Controversies of CTG Solved by Actocardiogram 64
- Physiologic Sinusoidal FHR *64*
- Case Studies *64*
- Discussion *66*

14. Strategies to Prevent Fetal Brain Damages 69
- Early Rapid Delivery in the Abnormal CTG and ACG *69*
- Fetal PVE Preceding Neonatal PVL in Preterm Baby *70*
- Postwords *72*

References *73*

Index *77*

2 chapter

Actocardiogram

TERMINOLOGY

Fetal Movement Burst

The cluster or group of fetal movement spikes, recorded on the fetal movement channel of actocardiogram (Figures 8 and 9).

Actocardiogram

'Acto' means fetal movement and 'Cardio' fetal heart rate, namely 'Actocardiogram' means simultaneous record of fetal movement signal and heart rate curve. Abbreviation is 'ACG'. Uterine contraction is also simultaneously recorded in actual ACG machine to prepare the function of 'Cardiotocogram (CTG)' too.

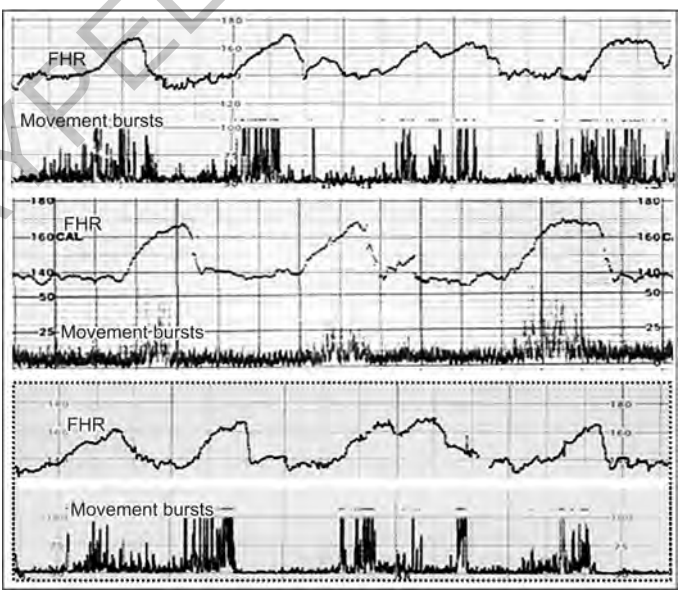

Figure 8 Fetal movement bursts were recorded with associated FHR accelerations in 3 normal active states

JAYPEE BROTHERS

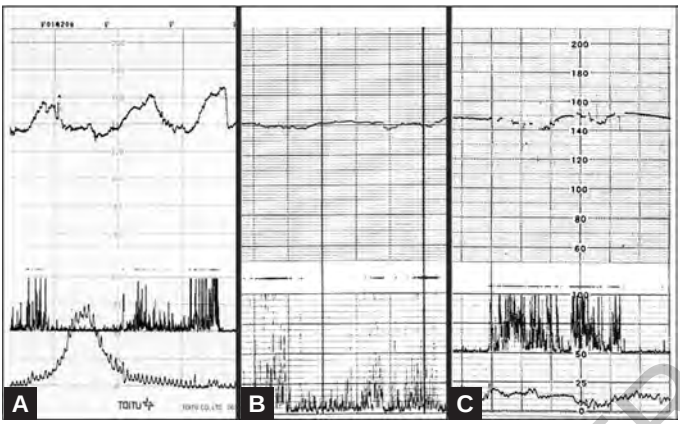

Figures 9A to C Similar waves of fetal movement bursts were recorded in various cases: (A) Normal active fetal state; (B) Nonreactive FHR of a growth restricted fetus; (C) An anencephalic fetus

FHR

Abbreviation of fetal heart rate.

FHR Acceleration

Triangular transient FHR increase, of which duration is 15 sec or more seconds and amplitude is 15 bpm or more in 30 or more gestational weeks, and 10 sec and 10 bpm or more before 30 weeks. The loss of acceleration against fetal movement burst is 'nonreactive FHR' which is preceding ominous nonreassuring fetal status (NRFS).[23]

Sinusoidal FHR

Two to four cycles per min sine wave-like smooth FHR curves of very ominous fetal outcome. The physiological sinusoidal FHR closely resembles to true sinusoidal FHR, while its outcome is benign without fetal obstacle. The true and physiological sinusoidal resembles each other in their shape, very difficult to distinguish in common CTG, but possible by the ACG.[22]

Deceleration

Transient decrease of FHR for more than 15 bpm and longer than 15 sec. There are periodic V-shaped decelerations including early (ED) and late (LD) decelerations, where the latter ones, delayed appearance to uterine contraction, is considered ominous. Variable U-shaped decelerations are divided benign, mild variable and severe variable decelerations of prolonged

JAYPEE BROTHERS

one which is ominous sign. Prolonged deceleration longer than 2 min is ominous sign.

FHR Baseline Variability

Minor variation of FHR baseline with the amplitude for 5–24 bpm. The loss of variability is a very ominous sign.

Bradycardia

Fetal heart rate decrease less than 110 beats per minute (bpm). Bradycardia is considered ominous sign of the fetus, particularly sudden and prolonged bradycardia. Two nonhypoxic fetal bradycardia were fetal cardiac atrio-ventricular block and the sick sinus syndrome.

Tachycardia

Fetal heart rate baseline higher than 160 bpm is fetal tachycardia. More than 200 bpm fetal tachycardia is pathologic fetal cardiac disorder, which needs pharmacologic treatment via placenta in pregnancy.

HISTORY OF ACTOCARDIOGRAM

Although fetal heart rate has been the mostly discussed in the relation to uterine contraction, the heart rate is principally increased by human movement in most situations, that is experienced by the adult heart rate after any exercise, e.g. in simple running the heart increases to output blood volume by increasing the beating frequency, which is the acceleration of heart rate. The fetal tachycardia in fetal motion is principal fetal heart rate mechanism, which was discussed in maternal perception of fetal kicking in the past, i.e. the FHR acceleration synchronized with fetal kicking was fetal well-being, while the reduction of fetal kicking was considered as the sign of fetal risk. There was no precise technique of fetal movement recording, and maternal kicking perception was subjective maternal sensation, the motion detected by mechanical fetal motion detector[12] were unable to study weak fetal motion, which did not reach the surface of maternal abdomen. Therefore, direct detection of fetal motion was intended by the author listening noises in the monitor sound of ultrasonic Doppler autocorrelation fetal heart rate monitor, which were listened at fetal motion observed at maternal abdomen. The author had studied fetal heart valve beating signals in the studies of continuous wave ultrasonic Doppler fetal heart detector,[12] and he noted the possibility to record fetal motion

JAYPEE BROTHERS

directly at fetal chest like as fetal heart beat action, then he analyzed the Doppler frequency of fetal motion by a real-time FFT frequency analyzer to be 20 to 50 Hz when the ultrasound was 2 MHz.[24] Already he knew that fetal heart beat Doppler frequency was more than 100 Hz including the cardiac valve, fetal heart wall and arterial blood flow, therefore, the differentiation of fetal movement Doppler signal was expected from that of fetal heart. Therefore, the author tried to separate Doppler fetal movement signals from fetal heart beat Doppler signal using a band-pass filter with -18 dB/Oct attenuation at 20 and 80 Hz, where single ultrasound could simultaneously detect the signals of fetal movements and fetal heart beats using single ultrasound probe. The author did it by himself with the remodeling of TN-400 ultrasonic Doppler autocorrelation fetal cardiotocograph (TOITU, Tokyo) of which continuous wave (CW) ultrasound frequency was 2 MHz, and inserted a commercial -18 dB/Oct 20–80 Hz band-pass filter in the separation circuit in 1983 (Figure 10). The results were successful, we studied basic engineering character and clinical fetal movement detection at fetal chest, which represented fetal movements of the chest, where the movements of fetal extremities and mouthing were conducted, and confirmed. The linear relation of fetal movement and actographic spike amplitude was confirmed using the movement of a steel ball (Figures 11A and B), then reported the creation of new ultrasonic Doppler fetal movement recorder to the Journal of Japan Society of Obstetrics and Gynecology in 1984.[24]

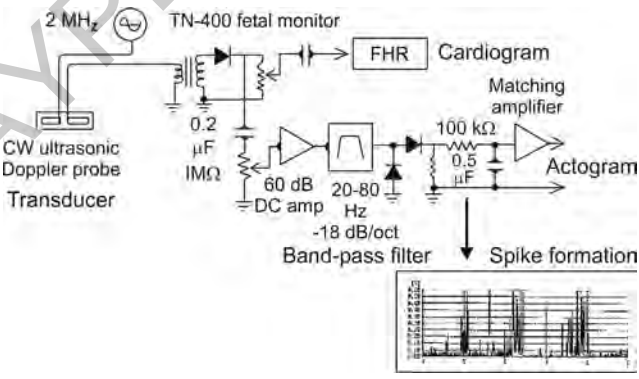

Figure 10 The basic circuit of ultrasonic Doppler actocardiograph. The cut-off frequency of band-pass filter is 20 and 50 Hz when the ultrasound is 2 MHz, while the commercial filter was 20 and 80 Hz in the prototype. The pass-band changes according to the ultrasound frequency, e.g. it will be 10-30 Hz, if ultrasound is 1 MHz. The high-pass filter cut-off frequency for the fetal heart beat is 100 or more Hz to use it in the autocorrelation heart rate meter for the fetal heart rate detection

JAYPEE BROTHERS

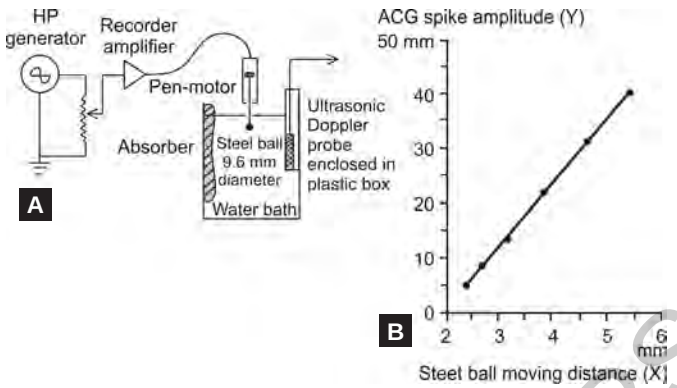

Figures 11A and B The relation of fetal movement width and the amplitude of movement spikes recorded on the actocardiogram (ACG) was confirmed by: (A) Steel ball of 0.96 cm in diameter was fixed at the top of a bar, which was moved by one Hz signal generated by the HP signal generator and a pen motor in front of the ACG probe in a water bath, where the steel ball moving was measured by a telescope; (B) The movement width of steel ball and the movement spike amplitude of the ACG chart were closely correlated, to confirm the accuracy of recorded movement spikes

The actocardiogram capacity to record fetal movements were tested by the comparison to the event marking at fetal motion of ultrasonic real-time B-mode image. The B-mode image observer clicked a Morse code key when he noticed fetal movement. In the images, all event marks of sonographic fetal motions corresponded the actographic movement spikes (Figures 12A to D).[20]

As the actocardiographic function was confirmed, the author asked TOITU (Tokyo) to produce new ultrasonic Doppler FHR and fetal movement recorder, of which name was 'actocardiograph', to TOITU (Tokyo) on 1984, and the first commercial model MT-320 actoardiogram was provided (Figures 13A and B).

Actocardiograph models produced by TOTU (Tokyo) were MT-320, MT-325, MT-332, MT-333U, MT-430, MT-522, MT-540, MT-516, MT-517, but just MT-516, MT-517, MT-522, MT-523 and MT-5700 are provided at present. The price of MT-516 is about 6,000 USD.

As the author mentioned, fetal movements evoke fetal heart rate increase by the reaction of fetal brain, and found that the loss of FHR acceleration, which was the reaction of fetal brain to fetal movement burst, will indicate the suppression of fetal brain.[26] Since the large fetal movement bursts provoke FHR acceleration (Figure 8), medium size fetal movement evokes medium size FHR variations (Figure 26), and finally the minor fetal movement evokes the FHR variability (Figure 27),

JAYPEE BROTHERS

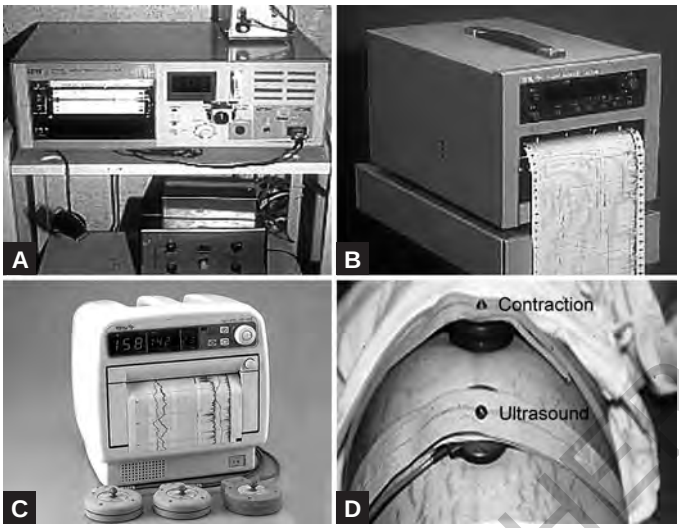

Figures 12A to D (A) Author's prototype actocardiograph; (B) The first commercial model, MT320; (C) Recent twin MT516 with twins probes; (D) Setting of probes on maternal abdomen in a singleton pregnancy

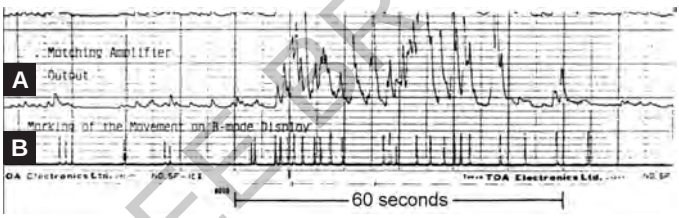

Figures 13A and B (A) Augmented record of ultrasonic Doppler fetal movement signals; (B) Event marks of fetal movements observed on real-time B-mode image monitor screen, pressing a rapid Morse code key. Every event marker record corresponded to the actocardiographic fetal movement signals

the loss of acceleration, that is nonreactive FHR, alarmed the initiation of hypoxic fetal brain suppression, and the loss of FHR variability could be heavy damage of general brain,[26] it may be recommended that a C-section would be performed before the loss of baseline variability, instead of the section after the detection of the loss of variability.

THE PRINCIPLE OF ACTOCARDIOGRAM

The Circuit to Detect Fetal Movements

The ultrasonic CTG TN-400 (TOITU, Tokyo) was re-modeled by the author himself, where the ultrasonic probe composed

JAYPEE BROTHERS

of 6 ultrasound units received reflected ultrasound, and the Doppler signals was detected in the machine and separated into two groups including low frequency signals of 20–50 Hz, which were changed to positive spikes by diodes, then passed a low-pass filter to record fetal movement spikes on the recorder chart. The original 100 Hz high-pass filter detected fetal cardiac Doppler signals and they were sent to autocorrelation FHR meter (Figure 10).[24] There were two kinds of movement signals recorded on the chart in commercial models including spikes and dots. Since the dots were inadequate for precise studies, because the dots were formed by the triggering of movement spikes at the 25% height of spike, and another fetal movement recorder with dots were criticized,[25] therefore, fetal movements were studied fully by movement spikes in the present report.

The Correctly Linear Recording of a Steel Ball Movement in the Water

The ultrasonic Doppler probe of the prototype ACG was fixed in the water, and a steel ball with the diameter of 0.96 cm was fixed at the top of light arm, which was moved by a pen motor of an ink-writing recorder with 1 Hz sine wave of a HP signal generator (Figure 11A). The steel ball motion was controlled by the signal amplitude of generator. Precise steel ball motion was measured by a telescope, and the movement spikes were recorded on the actocardiogram.

The amplitude of movement spike (Y) correlated closely to the steel ball motion (X), where 'Y = 12.03X – 24.32, $R^2 = 1.00$, $p < 0.001$ (Figure 11B), showing the correct fetal chest movement records in the clinical ACG.

Fetal Movement Signal of ACG Compared to the Real-Time B-Mode Image

Two-channel pen recorder was prepared. One channel was connected to a rapid Morse code key, because fetal movement in the ultrasound B-mode image was too fast to mark the movement event on the chart with common push button switch looking at the real-time B-mode images. Another channel recorded the ACG spikes, which traced fetal movements. In the results, every ACG movement sign corresponded the events marked by the Mores code key (Figure 12).[20]

World researchers confirmed the correct recording of fetal movement recording with ACG as follows; Positive predictive value was 93% and sensitivity was 94%, where maternal breathing, speaking and laughing did not influence the actocardiogram.[27] Maternal motion would be rejected, because

JAYPEE BROTHERS

the Doppler signal of maternal motion was as low as below 2 Hz, therefore, it was cut-off by -18 dB/Oct 20-80 Hz band pass filter. Actogram detected 96% of major movements, 97% of rolling movements, and 100% of all multiple movements,[28] Actograph accurately detected ultrasonic movement and resting from 20 weeks, and it was useful for objective and quantifiable measures.[29,30]

The Recording of Actocardiogram

The pregnant woman lies on supine or lateral position. The power supply is 100-220V AC as indicated in user instruction. Ultrasound probe of the ACG is attached on maternal abdomen via ultrasound jelly, on the abdomen at the most clearly listening fetal heart beats by the monitor sound. Uterine contraction probe is attached at the abdomen near by the uterine fundus. Both probes are fixed with belts. Chart speed is 3 cm/min. The recording duration is 30 or more min, to cover active and resting fetal states. The monitoring should be long enough to monitor whole labor in the delivery. It can be expanded for some days in case of high-risk pregnancy to detect any abnormality. The ultrasound is safe even in prolonged monitoring, because its ultrasound intensity was as low as 1 mW/cm^2 in MT 516 actocardiograph, which is 1/240 of ultrasound bioeffect threshold, and around 1/200 of 1.0 thermal index intensity,[32] where the ultrasound of 1.0 thermal index can be used for 1,000 min (17 hours), i.e. MT 516 ACG can be continuously used for 3400 hours (140 days).

The recorded ACG is continuously or frequently visually examined, and FHR score or the A/B ratio can be calculated to detect fetal abnormality. Computerized fetal monitoring is provided when the ACG is connected the FHR analyzing computer, which analyzes basic FHR changes, calculates FHR score, frequency spectrum for the detection of sinusoidal FHR or the loss of variability, and studies artificial neural network on the probabilities to be normal, pathological and suspicious outcome.

Various Fetal Movements

- *Fetal movement burst:* It is the grouped fetal movement signals with remarkable amplitude, which accompany FHR accelerations in normal fetuses (Figure 17).
- *Sporadic fetal movement:* It is clear movement signal, but not grouped.
- *Minor movements:* They were recognized by augmented movement channel using a computer scan.

JAYPEE BROTHERS

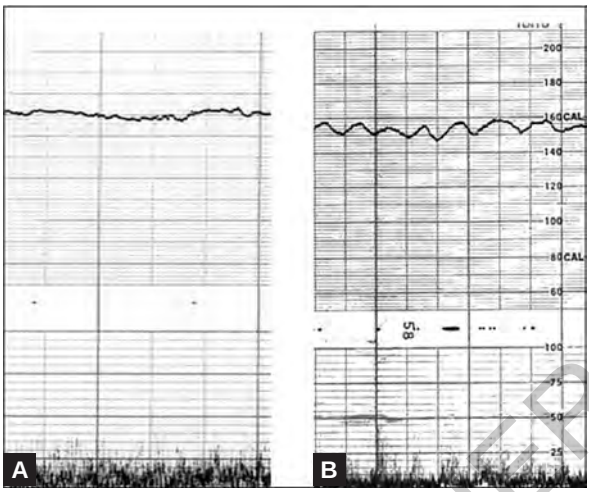

Figures 14A and B Two types of fetal respiratory movements. The frequency of fetal respiration is 1 Hz, namely the respiratory movements repeat 60 times in a minute. (A) Continuous respiratory movements. There is mild elevation of FHR baseline, but no acceleration; (B) Periodically changing fetal respiratory movements, which accompanies physiologic pseudosinusoidal heart rate

- *Fetal respiratory movements:* There are continuous 1 Hz movement spikes (Figure 14A). The periodically changing respiratory movement signals, which synchronize physiological sinusoidal FHR, separated it from true ominous sinusoidal FHR (Figure 14B).
- *Fetal hiccupping motion:* For 10–30 minutes lasting regular spikes with 2–3 sec intervals are fetal hiccupping movements, which can be perceived by the pregnant woman, but it will not accompany FHR acceleration (Figure 19). The hiccupping movements can appear twice in a day time, while its outcome was completely favorable without any hazard.

Quantitative Parameters of Fetal Movement

Four parameters are quantitatively determined in the fetal ACG.

1. Mean duration of fetal movement bursts (Sec)
2. *Occupancy (%):* Summarized fetal movement burst durations divided by the recording duration.
3. *Frequency (cycles per min, cpm):* The frequency of movement bursts in a min.
4. *A/B ratio:* The sum of FHR acceleration duration ratio to the sum of fetal movement burst duration (Figure 17).

JAYPEE BROTHERS

Fetal Behavior in the ACG

Fetal behavior is classified into resting, active, intermediate, hyperactive states in actocardiogram.

- *Resting fetal state:* Neither FHR acceleration nor movement burst is recorded, while FHR baseline variability is preserved. Its duration is 10 to 30 minutes, and active fetal state appears alternately (Figure 15). The resting fetal state is separated from nonreactive FHR (Figure 16) by the absence of fetal movement burst using actocardiogram. FHR variability is preserved both in resting fetal state and non-reactive FHR.
- *Active fetal state:* There are frequent movement bursts associated with FHR accelerations in active state. Baseline variability is larger than resting state, which is 5–24 bpm in normal active state. Active state duration is 20–50 minutes, and appears alternately with resting fetal state (Figure 17). The FHR acceleration duration ratio to fetal movement burst duration (A/B ratio) is obtained by the sum of acceleration (A) duration divided by the sum of fetal movement burst (B) duration.
- *Intermediate fetal state:* Sporadic appearance of movement burst associated with least FHR accelerations, which are less than active fetal state, but not a complete loss of movement. It lasts 10–20 minutes.
- *Hyperactive fetal state:* It is a highly active fetal state, where the duration of fetal movement burst and associated

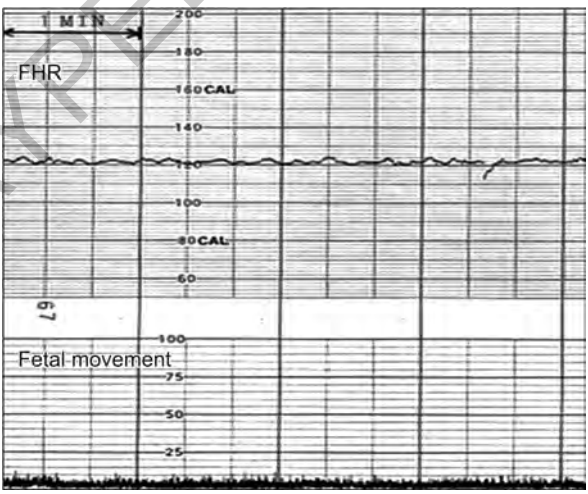

Figure 15 The actocardiogram recorded in normal resting fetal state, where neither FHR acceleration nor fetal movement burst was recognized. FHR baseline variability is preserved. A resting state lasts for 10 to 30 minutes, then moves to active state

JAYPEE BROTHERS

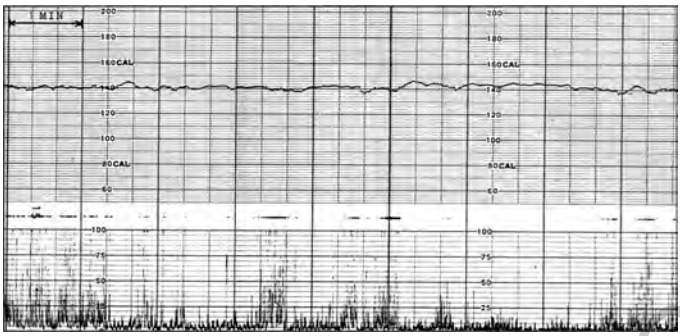

Figure 16 A pathological nonreactive FHR diagnosed by actocardiogram in a growth restricted fetus, where no FHR acceleration is recorded against repeated fetal movement burst, while baseline variability is preserved

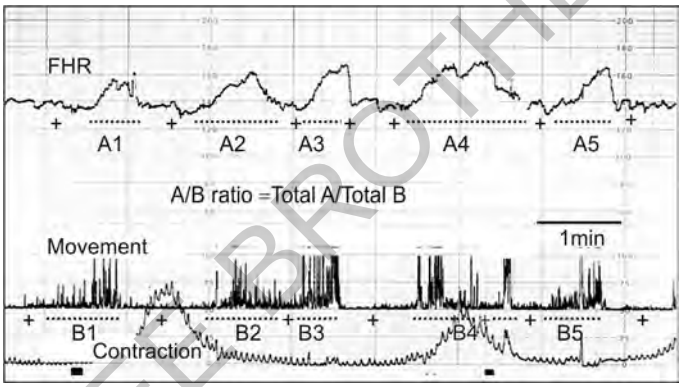

Figure 17 A normal active fetal state ACG. Multiple FHR acceleration (A1, A2, ---) are associated with fetal movement bursts (B1, B2, ---). The acceleration duration ratio to fetal movement burst (A/B ratio) is calculated with total A duration/total B duration. Active state lasts for 20–50 minutes then moves to resting state

FHR acceleration are prolonged. The longest movement burst was 4.5 min and acceleration was 5 min (Figure 17). The acceleration looks like a transient tachycardia in the prolonged hyperactive state as seen in Figure 17. The baseline variability is normal.

Four quantitative ACG parameters were determined in fetal behavioral states (Table 3), where four fetal behavioral states are identified by the quantified parameters. It is very important to find no significant difference in the A/B ratios among active, hyperactive and intermediate states (Table 3), i.e. the A/B ratio is applicable for the detection of ACG abnormality.

JAYPEE BROTHERS

Table 3 Four quantitative parameters in fetal behavioral states

Parameter	*Resting state*	*Active state*	*Hyper-active state*	*Inter-mediate state*
Mean burst duration (S)	0	29.7 ± 10.3	88.6 ± 14.6	17.7 ± 3.7
Occupancy (%)	0	32.7 ± 14.8	44.1 ± 5.3	8.4 ± 1.8
Frequency (cpm)	0	0.7 ± 0.2	0.5 ± 0.3	0.2 ± 0.03
A/B ratio	0/0	1.4 ± 0.4*	1.2 ± 0.3*	1.2 ± 0.10*

* No significant difference of A/B ratio was found between active, hyperactive and intermediate states

JAYPEE BROTHERS

For detailed information on obstetrics & gynecology books, visit our website **www.jaypeebrothers.com,** for detailed information

Actocardiogram

Analysis of Fetal Motion and Heart Rate

Actocardiogram (ACG) records fetal heart rate, direct fetal movements and uterine contractions using simple probes attached on the pregnant abdomen, and recorded on a moving chart. The same diagnosis is achieved as common cardiotocography (CTG), while fetal heart rate increases parallel to fetal movements, and unsolved problems in the CTG was solved by ACG, e.g. benign physiologic sinusoidal heart rate is diagnosed by cyclically changing fetal movements. Fetal hypoxia progresses according to changing ACG till severe fetal brain damage in the loss of fetal heart rate (FHR) variability. Fetal short- and long-term outcomes are diagnosed using the ratio of fetal heart rate acceleration duration to the fetal movement bursts duration. Fetal behavior is decided using ACG parameter values. The "Actocardiogram" book details these advantages.



Kazuo Maeda MD PhD graduated from Kyushu Imperial University, Faculty of Medicine, Fukuoka, Japan, in 1947. He studied in the Department of Obstetrics and Gynecology, Kyushu University. He published electroencephalographic studies on eclampsia and pre-eclampsia in 1954, neonatal respirography in 1954, maternal abdominal fetal ECG in 1960, using own hand-made systems, and provided Japan the first cardiotocography (CTG) monitor in 1964. He was Professor and Chairman, Department Obstetrics and Gynecology, Tottori University in 1968, and Honorary Professor, Tottori University in 1990. He also published Pathophysiology of Fetus in 1969, Computerized FHR Diagnosis in 1980, and Actocardiogram in 1984. He was Presidents of 4th Congress Federation Asia-Oceania Federation Perinatal Societies in 1986, 3rd The Fetus as a Patient Symposium in 1987, 5th World Congress Ultrasound in Obstetrics and Gynecology in 1995.

Available at all medical bookstores
or buy online at www.jaypeebrothers.com



JAYPEE BROTHERS
Medical Publishers (P) Ltd.
www.jaypeebrothers.com

Join us on facebook.com/JaypeeMedicalPublishers

Shelving Recommendation
OBSTETRICS & GYNECOLOGY

