our website **www.jaypeebrothers.com,** for detailed information on anesthesia books, visit our website **www.jaypeebrothers.com**

3rd Edition

Manual of Local Anesthesia in Dentistry

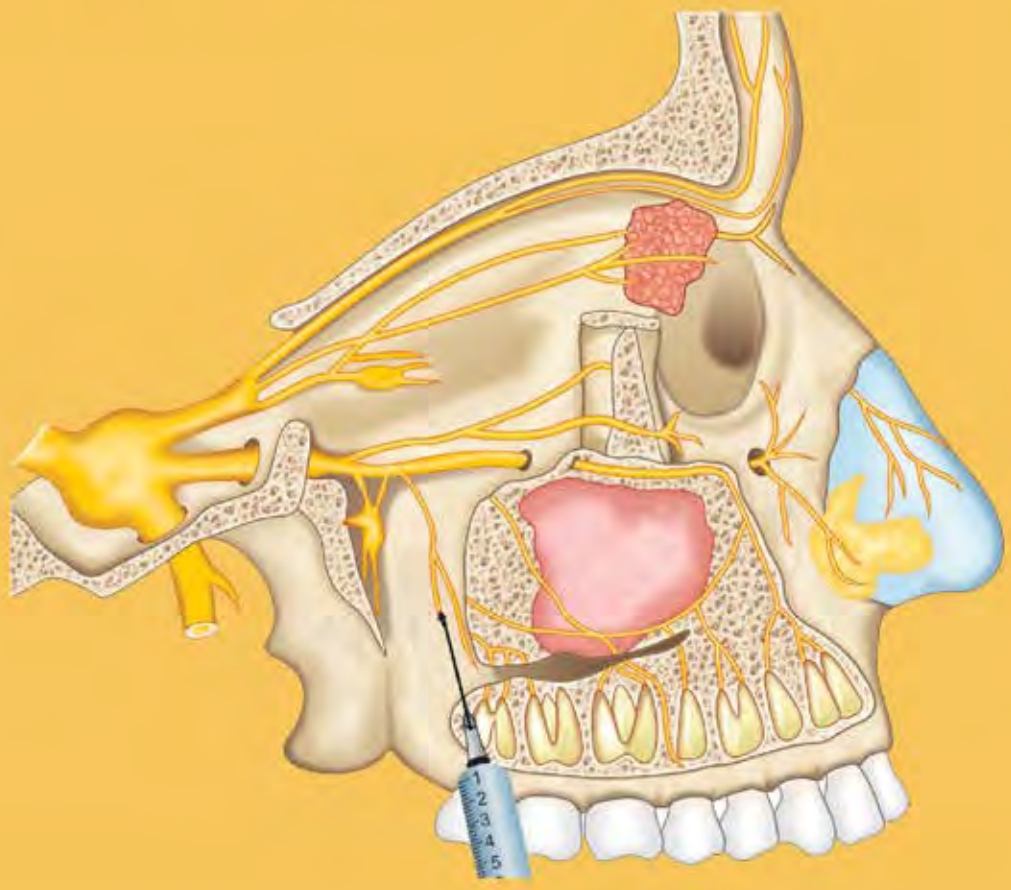



AP Chitre

JAYPEE

Contents

SECTION 1: HUMAN RACE AND PAIN RELIEF

1. History of Anesthesia 3
Early history of anesthesia 3
Discovery of inhalation anesthesia 4
Subsequent advances 5

SECTION 2: APPLIED ANATOMY OF MAXILLA AND MANDIBLE NEUROPHYSIOLOGY AND PHARMACOLOGY

2. Osteology of Maxilla and Mandible 11
Maxilla 11
Palatine bone 17
Mandible 18

3. Neuroanatomy 22
The trigeminal nerve (CN V) 22
The ophthalmic nerve (CN V_1) 23
The maxillary nerve (CN V_2) 25
Superior dental plexus 28
The mandibular nerve (CN V_3) 30

4. Fundamentals of Nerve Impulse Generation and Transmission 34
Actions of local anesthetic agents 34
Anatomy of a nerve cell or a neuron 34
Physiology of peripheral nerves 35
Electrochemistry 36
Membrane channels 37
Factors affecting nerve conduction 40
Effectiveness of local anesthetic agents 41
Sequence of mechanism of action 41

5. Theories of Pain Perception 42
Theories of pain perception 42
Dual nature of pain 43

6. Mode of Action of Local Anesthetic Agents 45
Mechanism of action 45

7. Local Anesthetic Agents 47
Properties of an ideal local anesthetic agent 47
Classifications 47
Properties of specific local anesthetic agents 47
Local anesthetic agents 48
Topical anesthetic agents 49
Injectable local anesthetic agents 50
Selection of local anesthetic agents 55
Newer local anesthetic agents 56

8. Vasoconstrictors 59
Definition 59
Actions 59
Classifications 59
Adrenergic receptors 59
Dilution of vasoconstrictors 60
Pharmacology of specific agents 60
Selection of a vasoconstrictor 63
Contraindications 63

9. Local Anesthetic Cartridge and Vial 67

SECTION 3: LOCAL ANESTHESIA IN DENTISTRY

10. Indications, Contraindications, Advantages and Disadvantages 71
Definitions 71
Indications 71
Contraindications 72
Advantages 73
Disadvantages 73

11. Methods of Pain Control 74
Methods 74
Therapeutic procedures 75

SECTION 4: ARMAMENTARIUM

12. Syringes, Cartridges, and Needles 81
Essential components 81
Additional armamentarium 90

SECTION 5: PRACTICE OF LOCAL ANESTHESIA

13. Medical Evaluation 95
Detailed medical history 95
Past dental history 96
Major illnesses 96

14. Infection Control 101
Asepsis and sterilization 101
Definition of various terminologies 101
Methods of sterilization 101
Disinfection 105
Disinfectants 105
Antiseptics 106

15. Preanesthetic Medications 108

16. Ergonomics in Dental Practice 109
Ergonomic risk factors in general 109
Types of musculoskeletal disorders (MSDs) 111
Preventive strategies for ergonomics 116
Neutral positions for the clinician 123
Basic positioning of the patient's head 124
Future considerations 126

17. Basic Techniques of Local Anesthesia 129
Methods of local anesthesia 129
Types of infiltration anesthesia 130

18. Injection Techniques for Maxillary Nerve and Its Branches 139
Infiltration techniques 139
Nerve blocks 139

19. Injection Techniques for Mandibular Nerve and Its Branches 154
Infiltration techniques 154
Nerve blocks 154
Intraoral nerve blocks 154
Nerve blocks for the mandibular nerve 160

20. Local Anesthesia in Children 166

21. Newer Injection Techniques 171
Electronic dental anesthesia (EDA) 171
Transcutaneous electrical nerve stimulation (TENS) 172

22. Management of Dental Clinic Waste 173
Waste disposal in a health care setting 173

SECTION 6: COMPLICATIONS OF LOCAL ANESTHESIA AND THEIR MANAGEMENT

23. Local Complications 179
Complications arising from the drugs or chemicals used for local anesthesia 179
Complications arising from injection techniques 180
Complications arising from both 184

24. Systemic Complications 190
Vasodepressor syncope (vaso-vagal attack) 190
Adverse drug reactions 192
Emergency drugs 196
Equipment used for treatment of complications 197

25. Medical Emergencies in the Dental Office 201

SECTION 7: GUIDELINES FOR MANAGING OCCUPATIONAL EXPOSURES TO BLOODBORNE PATHOGENS

26. Guidelines for Managing Occupational Exposures to BloodBorne Pathogens 209
Definition of an occupational exposure 209
Prevention of occupational exposure 209
Use of protective barriers 210
Exposure to blood/body fluids 210
National AIDS Control Organization (NACO) guidelines for occupational post-exposure prophylaxis (PEP) 213
Occupational exposure 214

Questions and Answers 217

Index 219

CHAPTER 2

Osteology of Maxilla and Mandible

MAXILLA (FIGS 2.1 TO 2.7)

The maxilla consists of a (a) Central body and (b) Four processes.

a. Central body: It is hollowed out by the maxillary sinus.
b. Processes: Comprise of the following (1) Frontal, (2) Zygomatic, (3) Palatine, and (4) Alveolar processes.

Body of Maxilla

The body of the maxilla can be described as a three-sided pyramid with its base facing the nasal cavity. It lies at an almost horizontal axis, the apex being elongated into the zygomatic process.

Surfaces

The three surfaces of the pyramid are as follows:

i. *Superior or orbital surface:* It forms the greater part of the orbital floor.
ii. *Anterolateral or malar surface:* It forms part of the skeleton of the cheek and face.
iii. *Posterolateral or infratemporal surface:* It is the surface towards the infratemporal fossa.

Base

It is rimmed on its inferior edge by the alveolar process housing the tooth sockets.

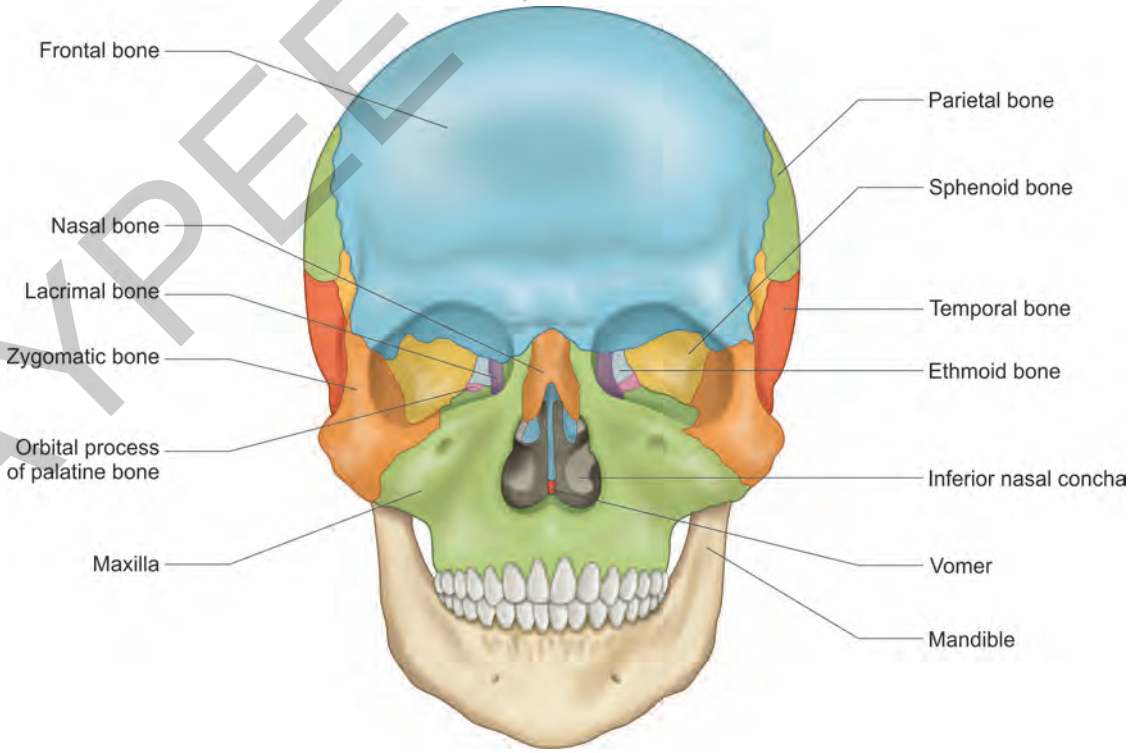

Fig. 2.1: Skull: Various bones forming the skull.

JAYPEE BROTHERS

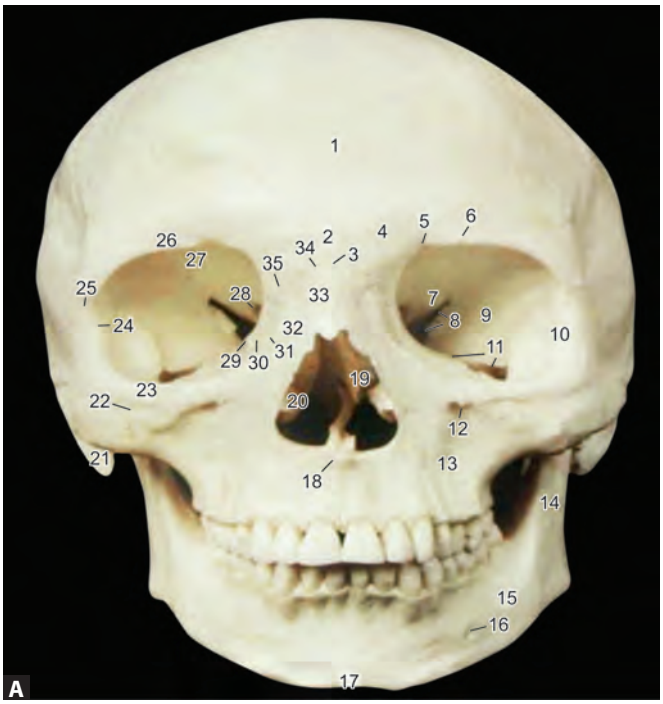

Skull from the front:
(1 Frontal bone. 2 Glabella. 3 Nasion. 4 Superciliary arch. 5 Frontal notch. 6 Supraorbital foramen. 7 Lesser wing of sphenoid bone. 8 Superior orbital fissure. 9 Greater wing of sphenoid bone. 10 Zygomatic bone. 11 Inferior orbital fissure. 12 Infraorbital foramen. 13 Maxilla. 14 Ramus. 15 Body of mandible. 16 Mental foramen. 17 Mental protuberance. 18 Anterior nasal spine. 19 Nasal septum. 20 Inferior nasal concha. 21 Mastoid process. 22 Zygomaticomaxillary suture. 23 Infraorbital margin. 24 Marginal tubercle. 25 Frontozygomatic suture. 26 Supraorbital margin. 27 Orbital part of frontal bone. 28 Optic canal. 29 Posterior lacrimal crest. 30 Fossa for lacrimal sac. 31 Anterior lacrimal crest. 32 Frontal process of maxilla. 33 Nasal bone. 34 Frontonasal suture. 35 Frontomaxillary suture)

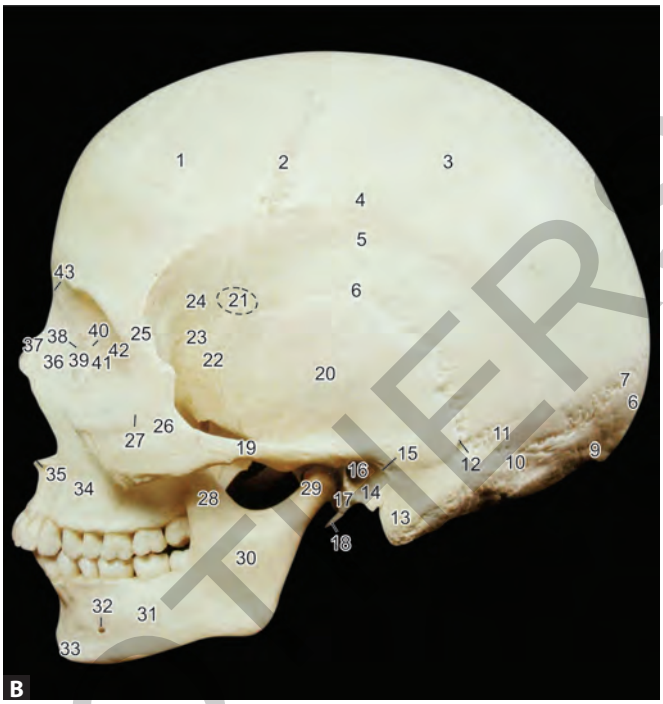

Skull from the left:
(1 Frontal bone. 2 Coronal suture. 3 Parietal bone. 4 Superior temporal line. 5 Inferior temporal line. 6 Squamosal suture. 7 Lambdoid suture. 8 Occipital bone. 9 External occipital protuberance. 10 Occipitomastoid suture. 11 Parietomastoid suture. 12 Asterion. 13 Mastoid process. 14 Tympanic part of temporal bone. 15 Suprameatal triangle. 16 External acoustic meatus. 17 Sheath of styloid process. 18 Styloid process. 19 Zygomatic arch. 20 Squamous part of temporal bone. 21 Pterion. 22 Sphenosquamosal suture. 23 Greater wing of sphenoid bone. 24 Sphenofrontal suture. 25 Frontozygomatic suture. 26 Zygomatic bone. 27 Zygomaticofacial foramen. 28 Coronoid process. 29 Condylar process. 30 Ramus. 31 Body of mandible. 32 Mental foramen. 33 Mental protuberance. 34 Maxilla. 35 Anterior nasal spine. 36 Frontal process of maxilla. 37 Nasal bone. 38 Anterior lacrimal crest. 39 Fossa for lacrimal sac. 40 Posterior lacrimal crest. 41 Lacrimal bone. 42 Orbital part of ethmoid bone. 43 Nasion)

Figs 2.2A and B: The skull: From the front and from left showing bony landmarks.

Processes of Maxilla

Frontal Process

It ascends from the anteromedial corner of the body, and serves as the connection with the frontal bone.

Zygomatic Process

It forms the lateral corner of the body and connects with the zygomatic bone.

Palatine Process

It is a horizontal process that arises from the lower edge of the medial surface of the body; and along with the process of the other maxilla, forms the major anterior part of the skeleton of the hard palate.

Alveolar Process

It is a curved process, extends downward; and carries the sockets for the maxillary teeth.

Surfaces of Body of Maxilla

Medial or Nasal Surface

Maxillary sinus: The medial or nasal surface of the body of maxilla contains the large irregular *maxillary hiatus* in its posterior part, which leads to the *maxillary sinus.* Behind the opening, the bone is roughened for its junction with the *vertical plate of the palatine bone.*

Pterygopalatine groove: It is a shallow sulcus that begins above the middle of the posterior border, and descends obliquely downward and forward. It terminates at the angle formed by the posterior borders of the palatine process and the medial surface of the body. The upper edge of the nasal surface contains, in its posterior part one or two shallow depressions that complete and close some *ethmoid cells.*

Lacrimal sulcus: It is a deep vertical groove further forward that flattens out inferiorly. This sulcus is bordered in front by the continuation of the posterior border of the frontal process and

JAYPEE BROTHERS



From the front: Muscle attachments

(1 Corrugator supercilii. 2 Orbicularis oculi. 3 Medial palpebral ligament. 4 Procerus. 5 Levator labii superioris alaeque nasi. 6 Levator labii superioris. 7 Zygomaticus minor. 8 Zygomaticus major. 9 Levator anguli oris. 10 Nasalis (transverse part). 11 Nasalis (alar part). 12 Depressor septi. 13 Buccinator. 14 Depressor labii inferioris. 15 Depressor anguli oris. 16 Platysma. 17 Mentalis. 18 Masseter. 19 Temporalis.)

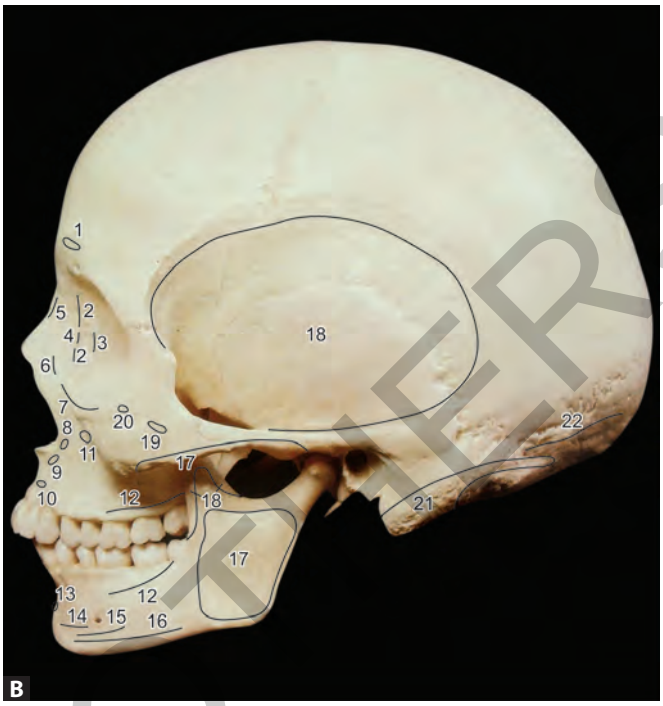

From the left: Muscle attachments

(1 Corrugator supercilii, 2 Orbicularis oculi (orbital and palpebral parts). 3 Orbicularis oculi (lacrimal part). 4 Medial palpebral ligament. 5 Procerus. 6 Levator labii superioris alaeque nasi. 7 Levator labii superioris. 8 Nasalis (transverse part). 9 Nasalis (alar part). 10 Depressor septi. 11 Levator anguli oris. 12 Buccinator. 13 Mentalis. 14 Depressor labii inferioris. 15 Depressor anguli oris. 16 Platysma. 17 Masseter. 18 Temporalis. 19 Zygomaticus major. 20 Zygomaticus minor. 21 Sternocleidomastoid. 22 Occipital belly of occipitofrontalis.)

Figs 2.3A and B: The skull: From the front and from left showing areas of muscle attachments.

in the back by a prominent bony spine that projects from the anterior edge of the maxillary opening. The remainder of the anterior half of the nasal surface of the body of maxilla is slightly concaved and terminates anteriorly at the sharp border of the *piriform* or *anterior nasal aperture.*

Conchal crest: It is a horizontal rough crest in front of the lacrimal sulcus and at its lower end. It serves for the attachment of the *inferior nasal concha.*

Orbital Surface

It is a triangular surface, and slightly sloping laterally and anteriorly. Its medial edge is sharp and joins, in its anterior part, the *lacrimal bone* and in its posterior part, the lamina papyracea of the *ethmoid bone.* At its posterior corner the palatine bone completes the orbital floor with its triangular orbital process.

Infraorbital rim: The anterior border of the orbital surface is smooth in its medial half. This part is thickened and forms a portion of the infraorbital rim. The lateral part of the anterior border of the orbital surface is rough and continues laterally onto the triangular sutural surface of the zygomatic process. This entire area serves as the junction with the zygomatic bone. Posteriorly, the orbital surface is separated from the infratemporal surface by a blunt border that forms the inferior boundary of the *inferior orbital fissure.*

Infraorbital sulcus: This is a groove that courses from approximately the middle of the blunt border, anteriorly to the floor of the orbit. This groove contains the *infraorbital nerve and vessels.* The lateral edge of the sulcus is rather sharp and bends tongue-like over the lateral part of the sulcus. Further forward this thin bony process completely covers the infraorbital sulcus and transforms it into the *infraorbital canal.* Anteriorly, the bony roof of the canal known as the *orbital plate* thickens considerably. Thus, the canal descends in its most anterior part and turns slightly inward at the same time. The axes of the two infraorbital canals converge downward and, if extended, would cross each other at a point 1–2 cm in front of the maxillary central incisors.

Frequently, a suture line can be seen extending from the infraorbital foramen upward to the infraorbital margin. This is the line at which the orbital plate joins the body of maxilla.

A characteristic and rare anomaly of the infraorbital canal is mentioned. The infraorbital canal and foramen are sometimes shifted laterally and the canal follows a laterally convex arch through the base of the zygomatic process, which may be of clinical importance in anesthesia of the infraorbital nerve.

Anterior or Anterolateral or Malar Surface

The anterolateral surface of the body of maxilla forms the skeleton of the anterior part of the cheek and is, therefore, called the *malar surface.* It is bounded posteriorly by a bony crest that begins at

JAYPEE BROTHERS



(1 Incisive fossa. 2 Palatine process of maxilla. 3 Median palatine suture. 4 Palatine grooves and spines. 5 Transverse palatine suture. 6 Horizontal plate of palatine bone. 7 Greater palatine foramen. 8 Lesser palatine foramina. 9 Tuberosity of maxilla. 10 Pyramidal process of palatine bone. 11 Pterygoid hamulus. 12 Medial pterygoid plate. 13 Scaphoid fossa. 14 Lateral pterygoid plate. 15 Infratemporal crest. 16 Zygomatic arch. 17 Articular tubercle. 18 Mandibular fossa. 19 External acoustic meatus. 20 Tympanic part of temporal bone. 21 Styloid process. 22 Stylomastoid foramen. 23 Mastoid process. 24 Mastoid notch. 25 Occipital groove. 26 Mastoid foramen (double on left). 27 Superior nuchal line. 28 External occipital protuberance. 29 Inferior nuchal line. 30 External occipital crest. 31 Foramen magnum. 32 Condylar canal. 33 Occipital condyle. 34 Hypoglossal canal. 35 Jugular foramen. 36 Carotid canal. 37 Sheath of styloid process. 38 Petrotympanic fissure. 39 Squamotympanic fissure. 40 Tegmen tympani. 41 Petrosquamous fissure. 42 Spine of sphenoid bone. 43 Foramen spinosum. 44 Foramen ovale. 45 Apex of petrous part of temporal bone. 46 Foramen lacerum. 47 Pharyngeal tubercle. 48 Palatovaginal canal. 49 Vomerovaginal canal. 50 Vomer. 51 Posterior nasal aperture (choana). 52 Posterior nasal spine.)

Fig. 2.4: The skull: The external surface of the base of the skull from below, showing bony landmarks.

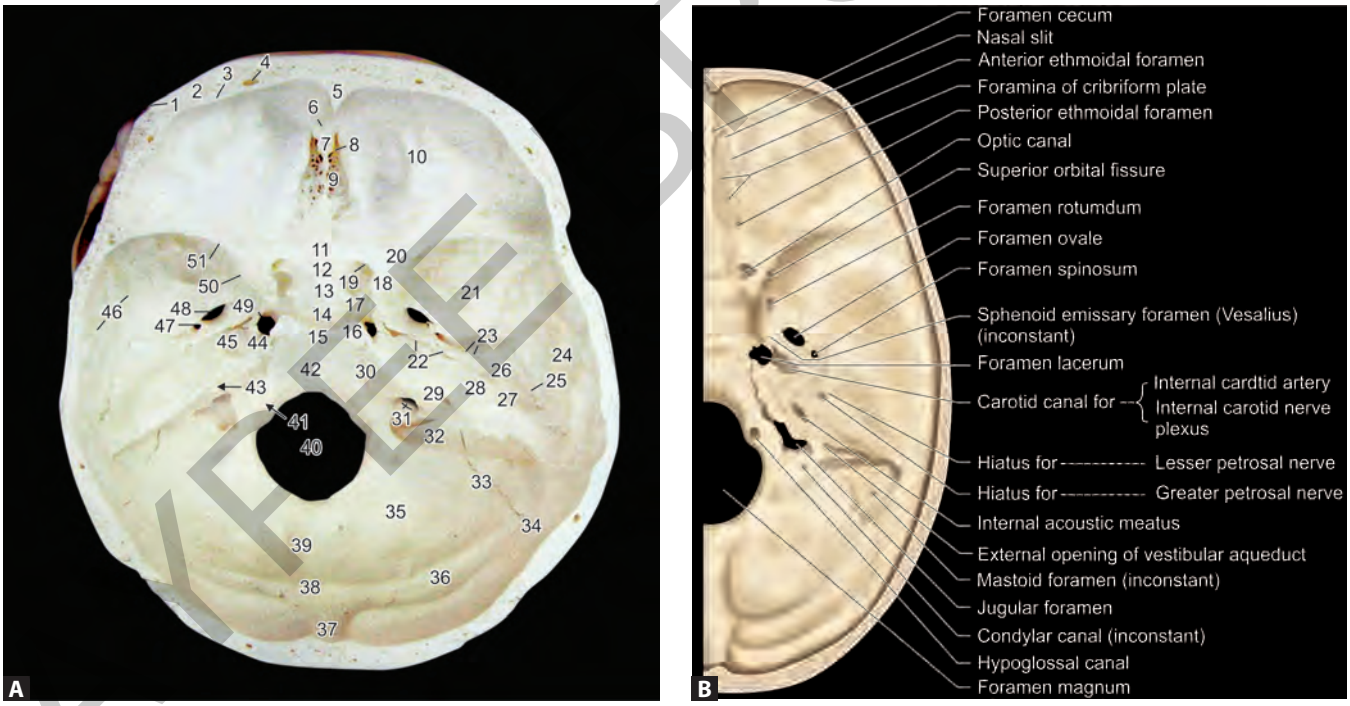

(1 Outer table. 2 Diploe. 3 Inner table. 4 Frontal sinus (upper extremity). 5 Frontal crest. 6 Foramen cecum. 7 Crista galli. 8 Groove for anterior ethmoidal nerve and vessels. 9 Cribriform plate of ethmoid bone. 10 Orbital part of frontal bone. 11 Jugum of sphenoid bone. 12 Prechiasmatic groove. 13 Tuberculum sellae. 14 Pituitary fossa (sella turcica). 15 Dorsum sellae. 16 Posterior clinoid process. 17 Carotid groove. 18 Anterior clinoid process. 19 Optic canal. 20 Lesser wing of sphenoid bone. 21 Greater wing of sphenoid bone. 22 Hiatus and groove for greater petrosal nerve. 23 Hiatus and groove for lesser petrosal nerve. 24 Squamous part of temporal bone. 25 Petrosquamous fissure. 26 Tegmen tympani. 27 Arcuate eminence. 28 Petrous part of temporal bone. 29 Groove for superior petrosal sinus. 30 Groove for inferior petrosal sinus and petro-occipital suture. 31 Jugular foramen. 32 Groove for sigrnoid sinus. 33 Occipitomastoid suture. 34 Mastoid (posteroinferior) angle of parietal bone. 35 Occipital bone. 36 Groove for transverse sinus. 37 Groove for superior sagittal sinus. 38 Internal occipital protuberance. 39 Internal occipital crest. 40 Foramen magnum. 41 Hypoglossal canal. 42 Clivus. 43 Internal acoustic meatus. 44 Apex of petrous part of temporal bone. 45 Trigeminal impression. 46 Grooves for middle meningeal vessels. 47 Foramen spinosum. 48 Foramen ovale. 49 Foramen lacerum. 50 Foramen rotundum. 51 Superior orbital fissure.)

Figs 2.5A and B: The skull: The internal surface of the base of the skull, showing bony landmarks.

JAYPEE BROTHERS

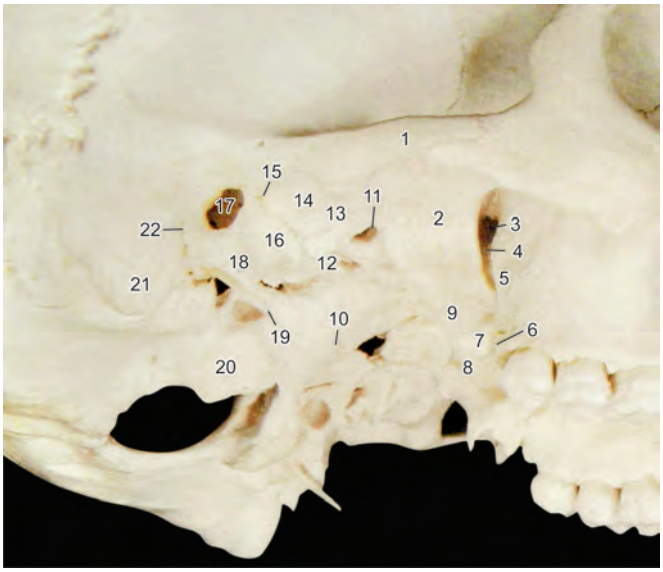

(1 Zygomatic arch. 2 Lateral pterygoid plate. 3 Sphenopalatine foramen. 4 Pterygomaxillary fissure. 5 Infratemporal surface of maxilla. 6 Tuberosity of maxilla. 7 Pyramidal process of palatine bone. 8 Pterygoid hamulus. 9 Medial pterygoid plate. 10 Pharyngeal tubercle. 11 Foramen ovale. 12 Spine of sphenoid bone. 13 Articular tubercle. 14 Mandibular fossa. 15 Squamotympanic fissure. 16 Tympanic part of temporal bone. 17 External acoustic meatus. 18 Sheath of styloid process. 19 Styloid process. 20 Occipital condyle. 21 Mastoid process. 22 Tympanomastoid fissure.)

Fig. 2.6: The skull: A = the right infratemporal region, obliquely from below, showing bony landmarks.

the tip of the zygomatic process and continues in an arc, concave laterally and inferiorly, in the direction of the socket of the first molar, and disappears at the base of the alveolar process. This bony crest is known as the *zygomaticoalveolar crest* or *jugal ridge,* or the *zygomatic process of maxilla*, or the *buttress of the zygoma*.

Anterior nasal spine: Medially, the malar surface extends to the edge of the border of the *pyriform aperture;* in the midline the bone projects at the lower border of the aperture as a sharp spine that forms, with the corresponding projection of the contralateral bone, the *anterior nasal spine.*

Canine fossa: The lateral part of the anterior surface that continues onto the zygomatic process is concave. The concavity is variably deep and contains near its upper and inner corner the opening of the infraorbital canal, the *infraorbital foramen.* This foramen is found exactly below the boundary between the smooth and roughened part of the anterior border of the orbital surface that is below the most medial point of the zygomaticomaxillary surface. The border of the infraorbital foramen is sharp in its upper and lateral circumference and blunt below and medially because of the oblique course (downwards, forwards and medially) of the infraorbital canal.

Posterior or Posterolateral or Infratemporal Surface

It is part of the anterior wall of the infratemporal fossa. This surface is convex in its greater medial part, the lateral part continues into the posterior concave surface of the zygomatic process. The posterior convexity of the body of maxilla is called the *maxillary tuberosity* or *tuber.* The posterior superior alveolar nerves enter the bone in the center of this surface through two or three fine openings, the *posterior superior alveolar foramina*. They lead into narrow canals that run downward and forward in the thin wall of the *maxillary sinus.*

The infraorbital canal itself just into the maxillary sinus at the border between its roof and anterior wall. The wall between the infraorbital canal and the maxillary sinus can be deficient in persons with a large maxillary sinus.

a. **Zygomatic process:** The zygomatic process of the maxilla is the elongated apex of the pyramidal body. Its triangular superior surface is inclined laterally and is irregularly rough. It serves as the suture with the zygomatic bone. The anterior surface of the zygomatic process is an extension of the anterolateral surface of the body of maxilla, the posterior surface is concave and continues into the convex infratemporal surface of the body of the maxilla.
b. **Frontal process:** It is a bony process which lies in an almost sagittal plane.
    i. Its anterior border takes part in forming the upper border of the piriform aperture and then extends upward in a straight edge, to which the nasal bone is joined.
    ii. The posterior border of the frontal process arises approximately at the anteromedial corner of the orbital surface, it is in contact with the lacrimal bone.
    iii. The upper border of the frontal process is thickened and abuts the frontal bone.

Anterior Lacrimal Crest

It is a blunt vertical crest, parallel to and close to the posterior border, runs up the lateral surface of the frontal process. Behind this crest the frontal process forms part of the lacrimal groove. In front of the lacrimal crest, the lateral surface of the frontal process is smooth and fairly flat.

Ethmoid Crest

It is a fine horizontal ridge that crosses the inner surface of the frontal process, near its lower end, to which the middle concha of the ethmoid bone is attached.

Lower Surface

Alveolar Process

The alveolar process arises from the *lower surface* of the body of the maxilla. It consists of two roughly parallel plates of bone that unite behind the last tooth to form a small rough prominence, the *alveolar tubercle,* which often contains a single large narrow space. The *lateral* or *external alveolar plate* continues upward into the anterolateral and posterolateral surfaces of the body of maxilla, while the internal alveolar plate continues into the palatine process and behind the posterior end of the latter into the nasal surface of the body of maxilla. The deep furrow between the two alveolar plates is divided by radial bony plates into the *sockets* of the individual teeth. These *interalveolar* or *interdental septae* connect the outer and inner alveolar plates. The sockets for multirooted teeth are, in turn, divided by *intra-alveolar or inter-radicular septae.* In the socket for the first premolar, the intra-alveolar septum is parallel to the alveolar plates. In the sockets of the molars a sagittal septum divides the socket of the palatal root from those of the buccal roots, which themselves are separated by a secondary frontal septum.

JAYPEE BROTHERS



A = From the front
B = From the lateral side
C = From the medial side
D = From behind
E = From above
F = From below
G = From the lateral side
H = From the medial side
J = From the lateral side
K = From the medial side

(1 Frontal process. 2 Infraorbital margin. 3 Infraorbital foramen. 4 Zygomatic process. 5 Anterior surface. 6 Canine fossa. 7 Canine eminence. 8 Alveolar process. 9 Incisive fossa. 10 Anterior nasal spine. 11 Nasal notch. 12 Lacrimal groove. 13 Anterior lacrimal crest. 14 Orbital surface. 15 Infratemporal surface. 16 Tuberosity. 17 Ethmoidal crest. 18 Middle meatus. 19 Conchal crest. 20 Inferior meatus. 21 Nasal crest. 22 Incisive canal. 23 Palatine process. 24 Greater palatine groove. 25 Maxillary hiatus and sinus. 26 Infraorbital groove. 27 Infraorbital canal. 28 Palatine grooves and spines. 29 Lateral surface and vascular foramen. 30 Internal surface and ethmoidal groove. 31 Lacrimal groove. 32 Posterior lacrimal crest. 33 Orbital surface. 34 Lacrimal hamulus. 35 Nasal surface. 36 Descending process)

Figs 2.7A to J: The left maxilla, showing the bony landmarks.

Surface of Palatine Process

The palatine process arises as a horizontal plate from the body of the maxilla at the boundary between the body and the alveolar process. The palatine process is, in anteroposterior direction, shorter than the body of the maxilla and terminates posteriorly with a rough beveled border, to which the horizontal plates of the palatine bone are joined in the form of transverse palatine suture, and thus completing the skeleton of the hard palate.

At the corner, between the posterior edge of the palatine process and the medial wall of the maxilla, the bone is notched where the pterygopalatine sulcus ends. The palatine bone closes this notch to form the *greater palatine foramen.* From this notch, the palatine groove extends anteriorly at the border between the palatine and alveolar processes. The groove houses the greater palatine nerve and vessels.

JAYPEE DIGITAL

The border between the palatine and alveolar processes is sharp only in its posterior part, where the two processes join almost at right angles. Anteriorly, the angle between these processes is not so sharply defined, and in the region of the canine and incisors the inner plate of the alveolar process continues in a smooth curve into the palatine process.

The lower, or the oral surface of the palatine process is rough and irregular. The nasal surface is smooth and transversely concave. Along the midline the bone is elevated to the sharp *nasal crest,* which serves as the attachment of the nasal septum.

The *incisive canal* marks the boundary between the two constituent parts of the maxillary bone that unite early in embryonic life, the *pre-maxilla* and the *maxilla* proper. From the nasal opening of the incisive canal a remnant of the line of fusion between the pre-maxillary and maxillary palatine processes can sometimes be traced, more often, however, the remnant of the incisive suture is observed at the oral surface of the palatine process. Here it begins at the *incisive foramen* and extends towards the mesial border of the canine sockets.

PALATINE BONE (FIG. 2.8)

The palatine bone supplements the maxilla and provides the link between the maxilla and the sphenoid bone. It consists of a *horizontal plate* and a *vertical plate* joined at right angles. The horizontal plate, with its smooth superior or nasal surface and its rough inferior or oral surface forms the posterior part of the *hard palate.* Its anterior beveled border overlaps the palatine process of the maxilla in the transverse palatine suture. The medial border connects with the palatine bone of the other side, in the *median or interpalatine suture,* which is a continuation of the *intermaxillary suture.* At its nasal surface, the medial border is elevated to a sharp crest that continues with that of the other side, the nasal crest of the maxillary bones. The posterior border of the horizontal plate is concave and terminates medially in a sharp spine that forms, in conjunction with that of the contralateral bone, the *posterior nasal spine.* In front of its posterior border, the oral surface of the horizontal plate is often elevated as a sharp transverse ridge, the *palatine crest.* The lateral border, between the horizontal and vertical plates, is connected to the medial surface of the maxilla at the level between the body and the alveolar process. This border is cut near its anterior end by a notch that completes its cut near its anterior end by a notch that completes a similar notch in the maxilla to form the *greater palatine foramen* (Table 2.1).

The vertical plate of the palatine bone is almost twice as high as it is wide. Its upper border is divided, by the deep *sphenopalatine notch* into two processes, (a) a larger *anterior orbital process* and (b) a smaller *posterior sphenoid process.* The greater part of the vertical lamella is in contact with the inner surface of the body of maxilla posterior to the opening of the maxillary sinus. A tongue like maxillary process of the vertical lamella, arising in the inferior part of its anterior border, closes posteroinferior part of the maxillary hiatus, thus narrowing it considerably. On the outer surface of the vertical plate a sulcus begins below the sphenopalatine notch and ends at the notch of the greater palatine foramen. This sulcus, the *pterygopalatine groove,* fits to the pterygopalatine groove of the maxilla and thus completes the walls of the *pterygopalatine canal.* Above this sulcus and around the palatine notch the lateral surface of the vertical plate of the palatine bone is smooth and forms the inner wall of *pterygopalatine fossa*.

The *sphenoid process* behind the *sphenopalatine notch* joins the *sphenoid body*. The orbital process fits into the posterosuperior corners of the maxillary body, where its orbital, infratemporal and nasal surfaces meet. It completes the orbital surface of the maxilla at this posterior corner. The orbital process is often hollowed out by a shallow fovea that closes a *posteroinferior ethmoid cell.* Behind this fovea this orbital process is connected to the anterior surface of the body of sphenoid. Since both the orbital and sphenoid processes are joined to the sphenoid bone above, the notch between these processes is closed by the body of the sphenoid to form the *sphenopalatine foramen,* a communication between pterygopalatine fossa and nasal cavity.

The medial or nasal surface of the vertical plate is generally smooth. At the border between the inferior third and middle third, it is traversed by a sharp horizontal ridge, the *conchal crest* which serves as the attachment for the *inferior concha.* Near its base the orbital process is crossed by another horizontal rough line, the *ethmoid crest*, to which the posterior end of the *middle nasal concha* of the *ethmoid bone* is joined.

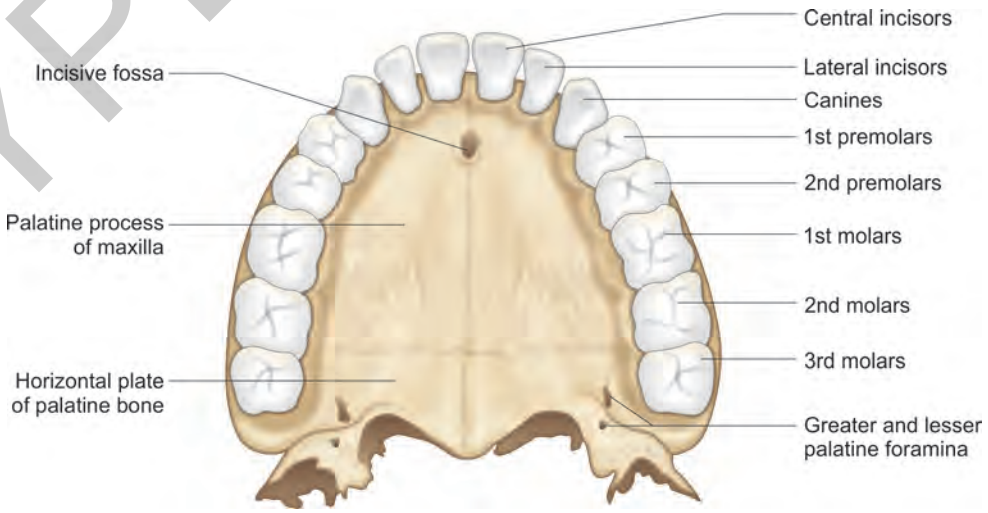

Fig. 2.8: The palatine bone, showing the bony landmarks.

JAYPEE BROTHERS

Pyramidal Process

It is a short stout process that arises from the junction of vertical and horizontal plates at the posterolateral corner of the palatine bones. It serves as the firm anchorage of the maxillopalatine complex to the lower end of the pterygoid process of the sphenoid bone. The pyramidal process fills the pterygoid plates, which themselves fit into grooves at the posterior surface of the pyramidal process. The lower surface of pyramidal process continues as the oral surface of the horizontal palatine plate at the posterolateral corner just behind the greater palatine foramen.

Lesser Palatine Foramina

These are one or two sometimes even three smaller openings, medially and behind this sharp crest behind the greater palatine foramen, at which narrow canals open that branch from the pterygopalatine canal and perforate the pyramidal process (Table 2.1).

MANDIBLE (FIGS 2.9 AND 2.10)

The mandible consists of two parts: (a) a horseshoe-shaped body, the two halves of the body meet in the midline; and is continuous upward and backward on either side with (b) the two mandibular rami.

a. **Body:** It is thick and has two borders. (i) the rounded lower border and (ii) the upper or the alveolar border (margin) that carries the alveolar process. It extends backward from the chin at the midline symphysis to the anterior limit of the ramus.

b. **Ramus:** It is for the most part a thin quadrilateral plate. It extends backward from the groove for the facial artery *(antegonial notch)* to include the region called the *mandibular angle.* It reaches upward to end in two processes, (i) the anterior muscular *coronoid process* and (ii) the posterior articular *condylar process.*

Parts

Mental Protuberance or Bony Chin

It is a triangular prominence projecting from the anterior surface of the body in and adjacent to the midline. The base of this triangle coincides with the lower border of the body and is extended on either side as a small tubercle, the *mental tubercle.* A depression, the *mental fossa,* lies laterally, on either side of the triangular chin. Two or three tiny openings through which small blood vessels pass are sometimes present in this fossa. Also a small raised oval area for the origin of the *mentalis muscle* can be found in the fossa.

Mental Foramen

It is through this foramen, the mental nerve and blood vessels pass. In the horizontal direction, it is located on the lateral surface of the body, below and between the roots of the first and second premolars (sometimes below the apex of the second premolar). In the vertical dimension, the foramen lies halfway between the lower border of the mandible and the alveolar margin. Sometimes, especially in younger individuals, the foramen lies closer to the lower border. In the elderly or in the edentulous mandible, the foramen lies close to the alveolar border. The opening of the

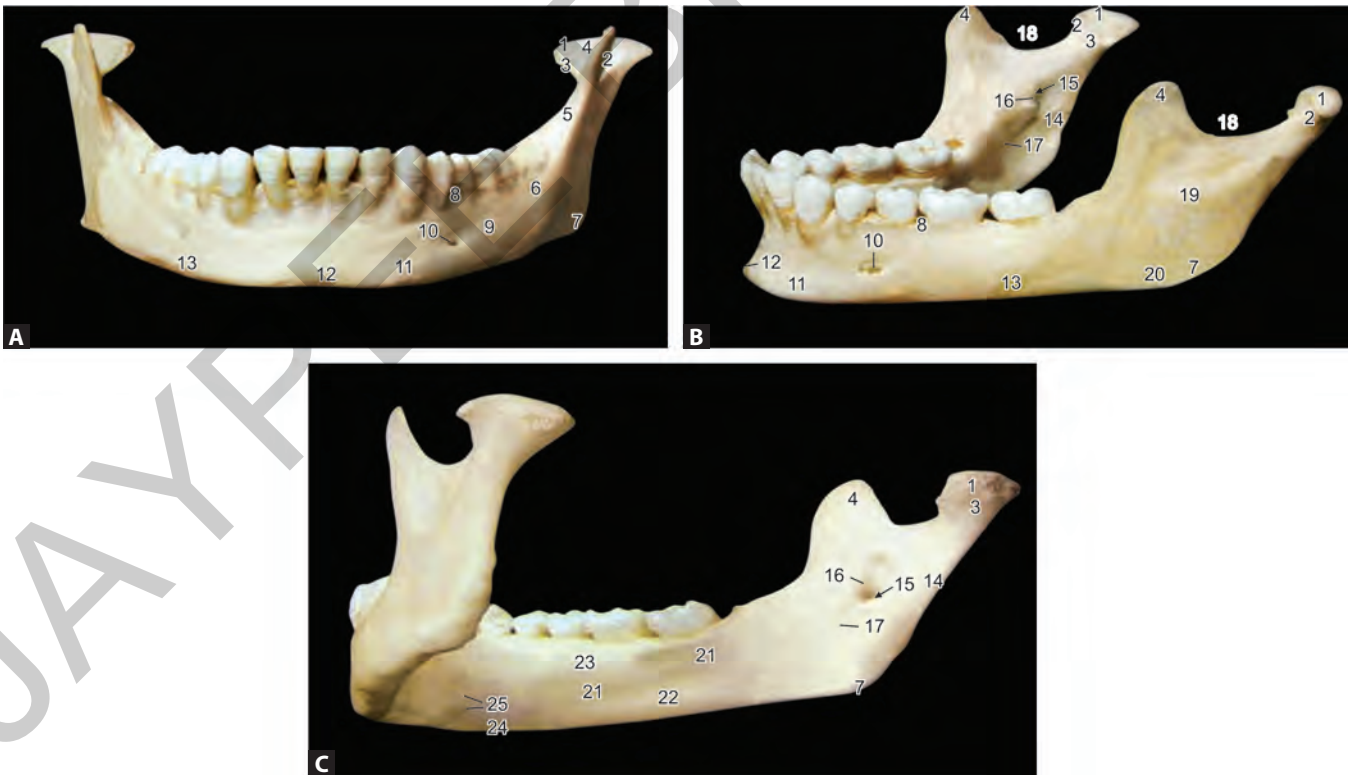

A = From the front
B = From the left and above
C = From the left and below

Figs 2.9A to C: The mandible, showing the bony landmarks.

JAYPEE BROTHERS



Muscle attachments (The dotted line indicates the limit of attachment of the oral mucous membrane)
A = From the front; B = From the left and above C = From the left and below.
1 Capsule of temporomandibular joint. 2 Temporalis. 3 Masseter. 4 Lateral pterygoid. 5 Buccinator. 6 Depressor labii inferioris. 7 Depressor anguli oris. 8 Platysma. 9 Mentalis. 10 Medial pterygoid. 11 Pterygomandibular raphe and superior constrictor of pharynx. 12 Mylohyoid. 13 Anterior belly of digastric. 14 Geniohyoid. 15 Genioglossus. 16 Sphenomandibular ligament. 17 Stylomandibular ligament

Figs 2.10A to C: The mandible: Showing areas of muscles attachments.
(The dotted line indicates the limit of attachment of the oral mucous membrane).

foramen faces outward, upward, and backward, consequently, the foramen is sharp only at its anteroinferior circumference, whereas its posterosuperior margin slants in gradually from the outer surface of the mandibular body. In edentulous mandible, the foramen comes to lie closer to the alveolar margin.

Superior View

a. **Body:** The alveolar process stems out from the upper border of the body and has a sharper curvature than does the bulk of the body itself. Thus, the body continues posterolaterally whereas the alveolar process turns inward toward the sagittal plane. Because of this, the posterior end of the alveolar process projects strongly inward from the arch of the body.
b. **Ramus:** It continues along the plane of the mandibular body, and is therefore situated well lateral to the plane of the alveolar process in the entire molar region. Thus, the anterior border of the ramus continues along the body lateral to the alveolar process as a blunt ridge, the *oblique line* or *the external oblique ridge,* running downward and forward to disappear at about the level of the first molar.

Body

Digastric fossae: On the posterior part of the lower surface of the chin, a shallow oval roughened depression lies on each side of the midline. These are meant for the origins of the anterior bellies of digastric muscles.

Mental spines/genial tubercles: The mandibular symphysis is elevated in more or less sharply defined projections slightly above the lower border on its inner surface. These may be fused or distinctly divided into right and left; and superior and inferior knobs, with small, roughened lateral hollows. The superior and inferior tubercles and adjacent hollow serve for the origins of the genioglossus and the geniohyoid muscles respectively.

Mylohyoid line/mylohyoid ridge: From the region of the third molar a rough and slightly irregular crest extends diagonally downward and forward on the inner surface of the mandibular body. It is usually, most prominent in its superior and posterior parts. If well developed, it reaches the lower border of the mandible in the region of the chin, passing between *digastric fossa* and *mental spines.* The mylohyoid muscle takes its origin from this crest. Since this muscle forms the floor of the oral cavity, the bone above the line is part of the wall of the oral cavity, whereas, the bone below this line, forms the lateral wall of the submandibular space and therefore is accessible from the neck.

Submandibular fossa: It is the slightly concave area below the mylohyoid line. It is so termed, because of its relation to the submandibular salivary gland.

JAYPEE BROTHERS

Sublingual fossa: It is a shallow depression above the anterior part of the mylohyoid line. It is in relation to the sublingual salivary gland.

Ramus

Mandibular angle: In the region of the mandibular angle, the bone is irregularly rough on the outer as well as on the inner surface. Depressions alternate with more or less pronounced ridges that frequently extend to the border, ending in small knoblike elevations. The irregularities are caused by the two muscles attached to the mandibular angle, the masseter muscle on the lateral side and the medial pterygoid muscle on the medial side. The upper end of the ramus is divided into the posterior *condylar* and the anterior *coronoid processes* by the semilunar, *sigmoid* or *mandibular notch.*

Condylar process: It carries the mandibular condyle or mandibular head, an irregulary cylindroid structure, the axis of which extends medially and posteriorly from laterally and anteriorly. The axes of the two condyles form an obtuse angle of 150° to 160° which is open to the front. The connection of the mandibular head with the mandibular ramus is slightly constricted and is known as *mandibular neck.* Above the neck the condyle itself is slightly bent anteriorly, so that the articulating surface faces upward and forward. The sharp border of the mandibular notch continuing backward and upward meets the lateral pole of the condyle.

Pterygoid fovea: It is a depression found medial to this crest and on the anterior surface of the mandibular neck, to which most of the fibers of the lateral pterygoid muscle are attached.

Coronoid process: It is a thin, triangular plate either sharply pointed or ending in a backwardly curved hook. Its posterior border is concave. Its anterior border is convex above then becomes concave below, the concavity, known as *coronoid notch*, being an important landmark for palpation in pterygomandibular block anesthesia. The coronoid process as it runs downwards divides into two bony ridges (little above halfway). The lateral border continues up to first molar which is the anterior border of ramus of mandible, and is also known as external oblique ridge. The coronoid notch is the deepest portion on the anterior border. The other ridge runs downwards and medially to join the posterior part of the alveolar process in the region of the last standing molar tooth. This ridge is known as internal oblique ridge; and the inverted triangular space thus created is known as retromolar fossa.

Mandibular foramen: It is a wide opening almost exactly in the center of the medial surface of the mandibular ramus, approximately 6–10 mm above the occlusal plane of mandibular molars, from where the *mandibular canal* starts. At its anterior circumference, a bony process, the *mandibular lingula* is found. At its posteroinferior circumference a narrow, sharply demarcated groove, the *mylohyoid groove,* commences and runs in a straight line downward and forward. It ends below the

TABLE 2.1: Major foramina and fissures

Foramen/fissure	*Located in or Formed by*	*Structures passing through*
Incisive foramen	Maxilla (Palatine process)	Nasopalatine nerve, sphenopalatine artery
Greater palatine foramen	Palatine	Greater palatine nerve and vessels
Lesser palatine foramina	Palatine	Lesser palatine nerve and vessels
Foramen ovale	Sphenoid	Mandibular division of trigeminal nerve (sensory and motor roots), Accessory meningeal artery, lesser petrosal nerve, emissary vein
Foramen spinosum	Sphenoid	Middle meningeal vessels, meningeal branch of mandibular division of trigeminal nerve (from undivided trunk)
Foramen lacerum	Articulation of the following bones: (i) sphenoid: greater wing and body, (ii) temporal: petrous, and (iii) occipital: basilar portion	Nothing passes through it Filled with fibrocartilage during life (although the anterior wall of the foramen has an opening for the pterygoid canal and the posterior wall has an opening for the carotid canal
Opening for auditory tube	Temporal and sphenoid	Cartilaginous portion of the auditory tube
Carotid canal	Temporal (petrous)	Internal carotid artery, internal carotid nerve plexus (sympathetics)
Tympanic canaliculus	Temporal	Tympanic branch of glossopharyngeal nerve
Jugular foramen	Temporal (petrous) and occipital	Glossopharyngeal nerve, vagus nerve, spinal accessory nerve, inferior petrosal sinus, sigmoid sinus, posterior meningeal artery
Mastoid canaliculus	Temporal (within the jugular fossa)	Auricular branch of vagus nerve
Petrotympanic fissure	Temporal	Chorda tympani nerve, anterior tympanic artery
Stylomastoid foramen		Facial nerve, stylomastoid artery
Tympanomastoid fissure		Auricular branch of vagus nerve
Hypoglossal canal	Occipital	Hypoglossal nerve
Condylar canal		Emissary vein, meningeal branches of ascending pharyngeal artery
Foramen magnum		Medulla oblongata, vertebral arteries, spinal roots of spinal accessory nerve

Adapted from: Norton NS: Netter's Head and Neck Anatomy for Dentistry. 2nd ed. Elsevier Saunders.

JAYPEE BROTHERS

posterior end of the mylohyoid line and sometimes is closed to form a canal for some part of its length. It houses the mylohyoid nerve, which supplies the mylohyoid muscle.

At the tip of the coronoid process a crest begins that runs straight down, traversing the coronoid process and then continuing on the medial surface of the ramus, becoming more prominent in its downward course. Behind the last molar, it bends into an almost horizontal plane and widens to a rough triangular field, the *retromolar triangle*. The prominent *medial and lateral borders* of the triangle continue into the *buccal* and *lingual alveolar crests* of the last molar. The vertical crest on the medial surface of the ramus serves as the attachment of the deep tendon of the temporal muscle and therefore is best designated as the *temporal crest*. Between it and the anterior border of the ramus is a depression the *retromolar fossa,* which is variable in its width and depth. The retromolar fossa continues between the alveolar process and the oblique line.

Ridge or crest of the mandibular ramus: Another ridge begins on the inner surface of the mandibular ramus at the inner pole of the mandibular condyle, crosses the mandibular neck in a forward and downward course and continues in the region above and in front of the mandibular foramen, where it fuses with the elevation of the temporal crest. This ridge is of variable height and in contrast to the temporal crest, smooth and blunt. Because of its relation to the neck of the mandible and because it is here that this ridge is most prominent, it may be designated as the *ridge* or *crest of the mandibular ramus.* It transmits the forces of the mastication from the base of alveolar process in a trajectory to the mandibular head and from there to the base of the skull. The trajectory consisting of strengthened and parallel trabeculae of the spongy bone, bulges toward the inner surface of the mandibular ramus, thus causing the elevation described as the *ridge of the mandibular neck.* The compact bone itself along this crest is also thickened behind and below the ridge. The bone is depressed to a shallow groove, the *groove of the mandibular neck,* which is bounded posteriorly and inferiorly by a more or less prominent fairly sharp ridge to which the posterior fibers of the *sphenomandibular ligament* are attached. The groove itself bends into the mandibular foramen. The groove does not contain the inferior alveolar nerve.

Mandibular canal: It houses the inferior alveolar nerve and blood vessels, begins at the mandibular foramen, curves downward and forward, and turns into a horizontal course below the roots of the molars. In the region of the premolars, the mandibular canal splits into two canals of unequal width, the narrow *incisive canal* continues the course of the mandibular canal toward the midline; and the wider branch the *mental canal* turns laterally, superiorly and posteriorly to open through the *mental foramen.*

Alveolar process: It consists of two compact bony plates, the *external* and *internal alveolar* or *cortical plates.* These two plates are joined to each other by the *radial interdental bone* and in the molar region by the *inter-radicular septae,* thus forming the sockets for the teeth much in the same manner as in the upper jaw. The outer alveolar plate is free distally to the level of the second molar. In the region of the second and especially the third molar, however, the bony substance of the oblique line is superimposed on the outer alveolar plate because of the divergence of the mandibular bony and the alveolar process. This relation between alveolar process and the ramus gives the impression that the outer alveolar plate is of a considerable thickness in the distal part of the molar region.

BIBLIOGRAPHY

1. Atkinson ME, White FH. Principles of Anatomy and Oral Anatomy for Dental Students. Churchill Livingstone, 1992.
2. Decker GAG, du Plessis DJ. Lee McGregor's Synopsis of Surgical Anatomy. 12th ed. Mumbai India: KM Varghese Co, 1986.
3. DuBrul EL.: Sicher and DuBrul's Oral Anatomy 8th ed. Ishiyaku EuroAmerica Inc. USA. ITBS Publishers and Distributors, 2000.
4. Last RJ. Anatomy: Regional and Applied. 8th ed. Churchill Livingstone, 1990.
5. Malamed SF. Handbook of Local Anesthesia. 4th ed. New Delhi, India: Harcourt India Private Limited (Mosby) Indian Reprint, 2001.
6. McMinn RMH, Hutchings RT, Logan BM: A Colour Atlas of Head and Neck Anatomy.
7. Norton NS: Netter's Head and Neck Anatomy for Dentistry. 2nd ed. Elsevier Saunders.
8. Richard Bennett C. Monheim's Local Anesthesia and Pain Control in Dental Practice. 7th ed. Delhi, India: CBS Publishers and Distributors, 1990.
9. Sinnatamby CS. Last's Anatomy: Regional and Applied. 10th ed. International ed. Churchill Livingstone, 2000.

JAYPEE BROTHERS

for detailed information on anesthesia books, visit our website **www.jaypeebrothers.com,** for detailed information on anesthesia

Manual of
Local Anesthesia in Dentistry

The third edition has been updated by adding four new chapters keeping in mind the present scenario and the curricula of all universities. The new chapters are on: Ergonomics in Dental Practice, Local Anesthesia in Children, Medical Emergencies in Dental Office and Guidelines for Managing Occupational Exposure to Bloodborne Pathogens.

Some of the old chapters have been revised and upgraded. The further significant and outstanding additions are many new diagrams in the chapters of Osteology, Neuroanatomy and Transmission of Nerve Impulse. The chapter on HIV and Guidelines for Occupational Post-exposure Prophylaxis has been totally revised to include management of exposure to other bloodborne pathogens. Thus, it has become a valuable and nearly complete reference book for Undergraduates, Postgraduates and Teachers in understanding Local Anesthesia; and to clinicians for safe and effective practice of Local Anesthesia in Dentistry.



AP Chitre MDS is Consultant Oral and Maxillofacial Surgeon, Bombay Hospital and Research Centre, Mumbai, Maharashtra, India. He was formerly: Hon. Oral and Maxillofacial Surgeon to His Excellency, Governor of Maharashtra; Member, Goa Health Advisory Council, and Consultant, Goa Dental College; Director, Dental Studies, Dean, Professor and Head, Department of Oral and Maxillofacial Surgery, YMT's Dental College and Hospital, Navi Mumbai; Professor and Head, Nair Hospital and Dental College, Mumbai; Professor and Chairman, Department of Oral Surgery, Garyounis University, Ben Ghazi, Libya; Professor and Head, Department of Oral and Maxillofacial Surgery and Postgraduate Teacher, Manipal College of Dental Surgery, Manipal, Karnataka; Professor and Head, Padmashree Dr DY Patil Dental College and Hospital, Navi Mumbai; Professor and Head and Postgraduate Teacher at KLES Institute of Dental Sciences, Belagavi, Karnataka; Postgraduate teacher and examiner, University of Bombay; Past President of: Association of Oral and Maxillofacial Surgeons of India; Indian Dental Association; and Indian Society of Oral Implantologists.

Available at all medical bookstores
or buy online at www.jaypeebrothers.com

JAYPEE BROTHERS
Medical Publishers (P) Ltd.
www.jaypeebrothers.com

Join us on facebook.com/JaypeeMedicalPublishers

Shelving Recommendation
DENTISTRY

ISBN 978-93-5250-198-4