sit our website www.jaypeebrothers.com, for detailed information on dermatology books, visit our website www.jaypeebrothers.com

Pocket Guide to Dermoscopy

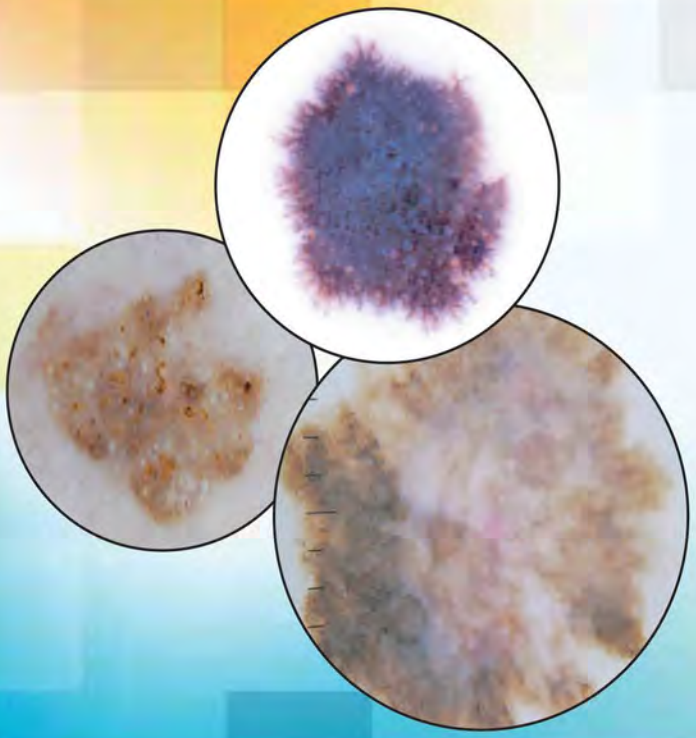

Editors
Natalia Jaimes
Ashfaq A Marghoob

Foreword
Harold Rabinovitz

JAYPEE

Contents

1.	Techniques of Dermoscopy	1
2.	Colors and Structures	8
3.	Two-Step Algorithm	23
4.	First Step: Differentiating Melanocytic from Non-Melanocytic Lesions	28
5.	Second Step: Nevus *vs* Melanoma	57
6.	Nevi: Benign Melanocytic Neoplasms	73
7.	Melanoma	87
8.	Special Sites	99
9.	Dermoscopy in General Dermatology	118
10.	Triage Amalgamated Dermoscopy Algorithm (TADA)	137
11.	Flowcharts	143
Index		*147*

First Step: Differentiating Melanocytic from Non-Melanocytic Lesions

4

MELANOCYTIC LESIONS

Lesions are considered to be melanocytic if they reveal any of the structures from levels 1, 7 or 8 (*see* Schematics 3.1 and 3.2, Table 3.1, Figs. 4.1A to G). Although some exceptions exist (e.g. Dermatofibroma), most lesions manifesting features listed in Level 1 of the algorithm are either nevi or melanoma. In contrast, many of the lesions in level 7 and 8 will prove to be non-melanocytic tumors on histopathology; however, since melanoma remains in the differential for lesions in level 7 and 8, it is most prudent to classify these lesions as melanocytic neoplasms so as to minimize the chances of missing a melanoma.

Melanocytic structures (*Level 1*)	Vascular structures (*Level 7*)	Non-specific structures (*Level 8*)
a. Pigment network (Dermatofibroma is an exception) b. Negative network c. Angulated lines d. Streaks (i.e. pseudopods and radial streaming) e. Aggregated (three or more) f. Peripheral rim of globules g. Homogeneous blue pigmentation	a. Comma vessels b. Dotted vessels c. Serpentine vessels (also known as linear irregular) d. Corkscrew vessels e. Polymorphous vessels (two or more morphologies within the same lesion) f. Milky-red areas or globules	The lesion does not reveal any structures that can assist in differentiating melanocytic from non-melanocytic lesions

JAYPEE BROTHERS

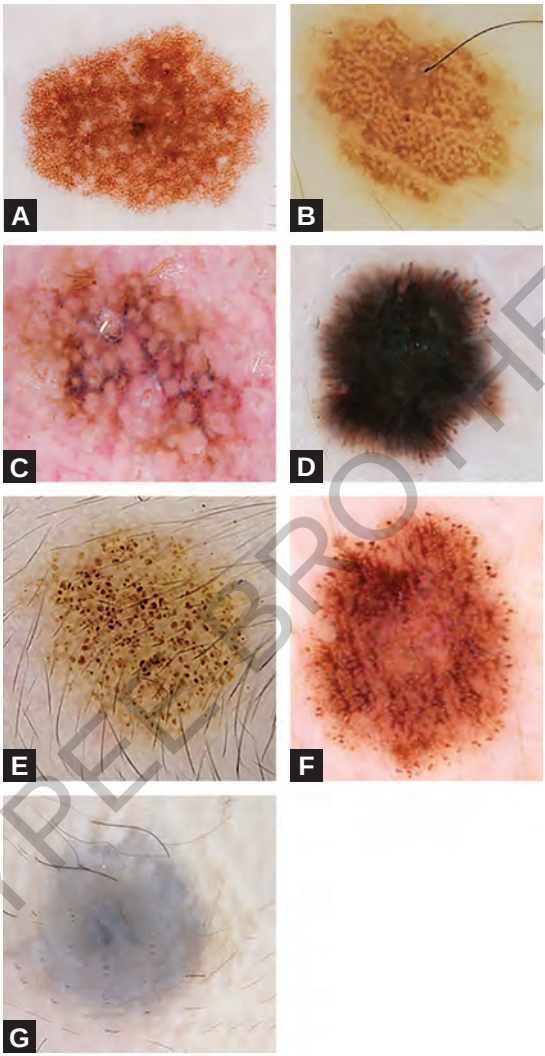

Figs. 4.1A to G: Criteria for melanocytic lesions. (A) Pigment network; (B) Negative network; (C) Angulated lines; (D) Streaks; (E) Aggregated (three or more) globules; (F) Peripheral rim of globules; (G) Homogeneous blue pigmentation.

JAYPEE BROTHERS

All lesions considered to be of melanocytic origin in step-1 of the two-step algorithm will need to be further evaluated in step-2 of the algorithm, which is intended to help differentiate nevi from melanoma (*see* Chapter 5).

NON-MELANOCYTIC LESIONS

Non-melanocytic lesions are diagnosed in the first step of the two-step algorithm (*Level 2 to 6*) (*see* Schematics 3.1, 3.2 and Table 3.1).

Exception to the Network Rule

Network can be seen in some non-melanocytic lesions, including dermatofibroma (DF), solar lentigo, polythelia (Accessory nipple), seborrheic keratosis (SK) (Table 4.1).

Table 4.1: Exception to the network rule. Non-melanocytic lesions that may present with network-like structures.[1,2]

Entity	*Network*	*Histopathological correlation*
Dermatofibroma 	Thin light tan network with minimal variability in color and thickness. Usually at the periphery, but can be seen throughout the lesion.	Hyperpigmented rete ridges, due to increased melanin in keratinoyctes overlying the DF.
Solar lentigo 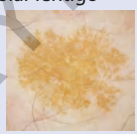	Thin light tan network with minimal variability in color and thickness, with a sharply demarcated moth-eaten border. The "ink-spot" lentigo is a variant of solar lentigo, which appears as a prominent dark brown or black network with thick or thin lines.	Hyperpigmentation of the basal layer of the epidermis, due to increased melanin production. The rete ridges form bud-like processes that expand into the papillary dermis.

Contd...

JAYPEE BROTHERS

Contd...

Polythelia (Accessory supernumerary nipple) 	Thin light tan network with minimal variability in color and thickness, with a central hypopigmented area.	The network like structure corresponds to the areolar epidermal hyperplasia.
Seborrheic keratosis 	Network-like structure in SK is thicker than network seen in melanocytic lesions. The lines form larger grids. It ends abruptly, has sharp demarcation, and it is usually darker.	The lines of a network-like structure in a SK represent the ridges of the skin, and the holes are due to the crypts, sulci or comedo openings.

Dermatofibroma

Dermatofibromas are common benign skin tumors that present as firm, pink to light brown or dark brown, single or multiple firm papules with a smooth surface. They are usually found on the lower extremities.

Clinically, DFs reveal the *dimple sign* (lateral compression of the lesion will reveal a firm lesion that dimples inward, producing a dimple-like depression).

Histopathologically, DFs are characterized by dermal fibrosis with vessels and epidermal hyperplasia consisting of elongated and broadened rete ridges and basal keratinocyte hyperpigmentation.[1,2]

Dermoscopy of DFs[1,2]

The clinical context and knowledge of the histopathology of DFs makes the diagnosis of DFs with dermoscopy quite easy. DFs are symmetric lesions that reveal one or more of the following dermoscopic structures (Table 4.2, Figs. 4.2A and B):

JAYPEE BROTHERS

Table 4.2: Dermoscopic structures observed in dermatofibromas and their histopathological correlation.[1,2]

Dermoscopic structure	*Definition*	*Histopathological correlation*
Delicated pigment network 	Thin grid-like network consisting of pigmented lines and hypopigmented 'holes'.	Melanin in keratinocytes along the dermo-epidermal junction.
Homogeneous structureless areas 	Areas devoid of dermoscopic structures within the lesion. Tan to brown in color.	Relative decrease concentration of melanin or flattening of rete ridges.
Scar-like area 	White, scar-like depigmentation.	Collagenous stroma
Shiny white lines 	Shiny white linear streaks that are often oriented parallel or orthogonal to each other. Better appreciated with polarized dermoscopy.	Appears to correlate with the collagenous stroma.
Ring-like or donut-shaped globules 	Tend to be located toward the center of the lesion, between the scar-like depigmentation and the peripheral network.	Widened, hyperpigmented rete ridges.
Vascular structures 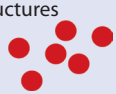	Vascular structures can be of different morphologies, including dotted vessels or polymorphous vessels, usually seen within the scar-like areas towards the center of the lesion.	Vascular vessels within the collagenous stroma.

JAYPEE BROTHERS

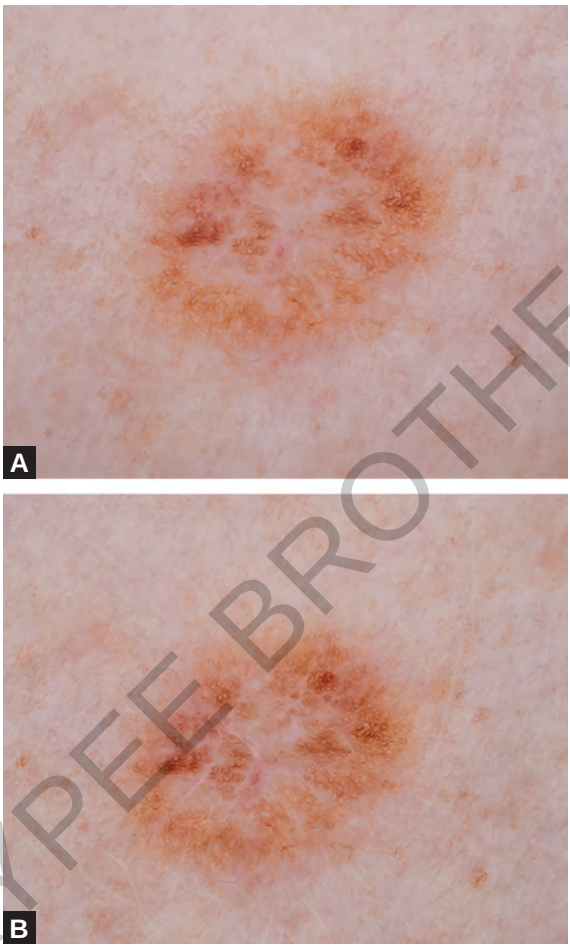

Figs. 4.2A and B: Dermatofibroma image taken with (A) non-polarized and (B) polarized dermoscopy. The structures (network, scar-like area, shiny white structures, vessels and ring-like globules) can be present in varying proportions resulting in lesions displaying a pattern of exclusively network to lesions with only scar-like areas.

N.B: The scar-like/shiny white areas, ring-like globules and vessels will always be located towards the center of the lesion.

JAYPEE BROTHERS

1. Peripheral pigment network. This is due to increased melanin in keratinocytes. It is not due to an increase in the number of melanocytes.
2. Homogeneous brown pigmented areas.
3. Central scar-like depigmentation.
4. Shiny white lines (seen with polarized dermoscopy (PD).
5. Vascular structures, including dotted and polymorphous vessels. They are found within the scar-like areas towards the center of the lesion.
6. Ring-like globules. These tend to be located in the zone between the scar-like depigmentation and the peripheral network. They correspond to widened hyperpigmented rete ridges.

The combination of the aforementioned structures results in different dermoscopic patterns,[1] which may range from delicate pigment network throughout the lesion, or with central scar-like area, to homogeneous pigmentation throughout the lesion, or scar-like area throughout the lesion.

Basal Cell Carcinoma

Basal cell carcinoma (BCC), the most common cutaneous malignancy in humans, is a locally invasive and relatively slow growing cancer. The most common histopathologic and dermoscopic variants include: nodular, superficial, and morpheaform. These BCC variants can be pigmented or non-pigmented.

Dermoscopy of BCC[3,4] (see Tables 2.3 and 3.1; Schematics 3.2, 4.1 and 4.2A and B; Figs. 4.3A and B)

Basal cell carcinomas have an *absence of a pigment network* and they also do not display any of the other

JAYPEE BROTHERS

Schematic 4.1: Dermoscopic criteria for basal cell carcinoma.

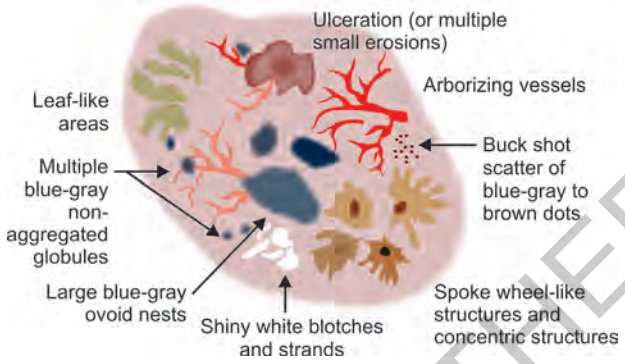

Schematics 4.2A and B: Dermoscopic criteria for (A) non-pigmented and (B) pigmented basal cell carcinoma.

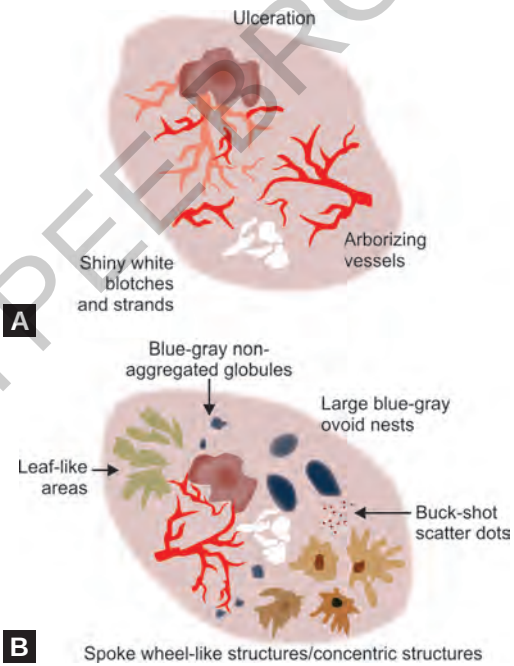

JAYPEE BROTHERS

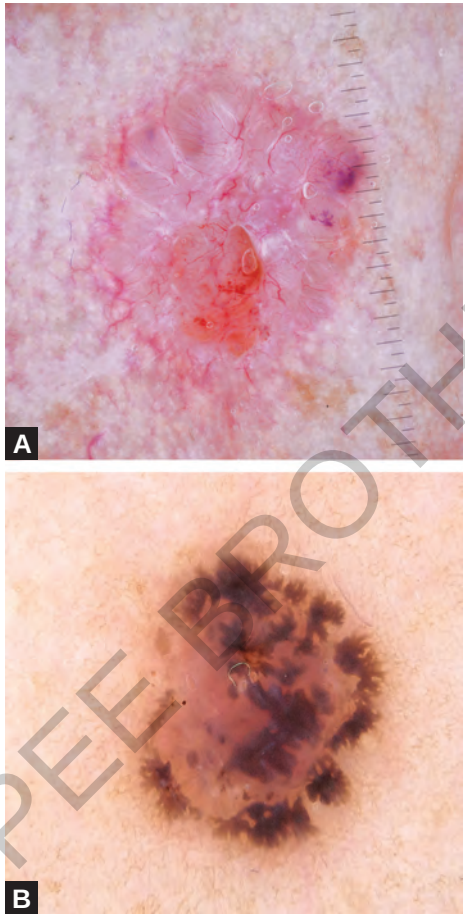

Figs. 4.3A and B: Dermoscopy of basal cell carcinoma. (A) Arborizing vessels, ulceration and shiny white blotches and strands seen in an almost completely non-pigmented BCC (a few bluish non-aggregated globules are present) under polarized dermoscopy. All of these structures can be seen in both pigmented and non-pigmented BCC. (B) Spoke-wheel-like structures and leaf-like areas in a pigmented BCC under nonpolarized dermoscopy. These two structures are 100% specific for diagnosis of BCC.
Images courtesy: Ana M Rivas, MD

JAYPEE BROTHERS

level-1 criteria specific for melanocytic lesions. In addition, they usually display *one or more of the following structures*:

1. Arborizing vessels. These vessels have a positive predictive value of 94% for BCC.
2. Spoke wheel-like structures or concentric structures. Spoke wheel-like structures are 100% specific for diagnosis of BCC.
3. Leaf-like areas. This structure is 100% specific for diagnosis of BCC.
4. Large blue-gray ovoid nests.
5. Multiple blue-gray non-aggregated globules.
6. Ulceration or multiple small erosions.
7. Shiny white blotches and strands, seen with PD.

Additional dermoscopic clues:

1. Short fine superficial telangiectasias.
2. Multiple in-focus dots in a buck-shot scatter distribution.

Dermoscopy structures can help predict BCC subtype.

1. Superficial BCC: spoke wheel-like structures, leaf-like areas, multiple small erosions, short fine telangiectasias.
2. Nodular BCC: arborizing vessels, large blue-gray ovoid nests, blue-gray non-aggregated globules, ulceration.
3. Morpheaform BCC: porcelain white areas with arborizing vessels and milia cysts.

Squamous Cell Carcinoma, Actinic Keratosis and Keratoacanthoma (*see* Tables 2.3, 2.5 and 3.1; Schematic 3.2)

Actinic keratosis, squamous cell carcinoma and keratoacanthoma are keratinizing tumors that have the potential to progress, invade and/or metastasize.

JAYPEE BROTHERS

Actinic Keratosis

Actinic keratosis (AK) consists of an atypical proliferation of kerantinocytes in the lower layers (basal layer and above) of the epidermis but not involving all the layers of the epidermis. Clinically they present as small plaques with adherent scale, usually located on chronic sun-exposed skin such as on the face, ears and dorsum of hands.

Clinical clues for AK include:

- Rough surface texture (in contrast, lentigo maligna (LM) has a smooth surface).
- Sharp, scalloped borders.

Dermoscopy of AK[5,6] (Figs. 4.4A and B)

Dermoscopic structures in *non-pigmented AK* (Fig. 4.4A):

1. Strawberry pattern. This pattern results from the pink color, which is due to blood, surrounding adnexal openings.
2. Rosettes (seen only with PD). This structure corresponds to hyperkeratosis within adnexal openings.
3. White-yellowish surface scale.

Dermoscopic structures observed in *pigmented AK* (Fig. 4.4B):

1. Same structures as seen in non-pigmented AK.
2. Annular-granular pattern, which consists of pigmentation and/or gray dots/granules surrounding adnexal openings.
3. Angulated lines forming zig-zag lines and polygons. The most common polygons are rhomboidal structures.

JAYPEE BROTHERS

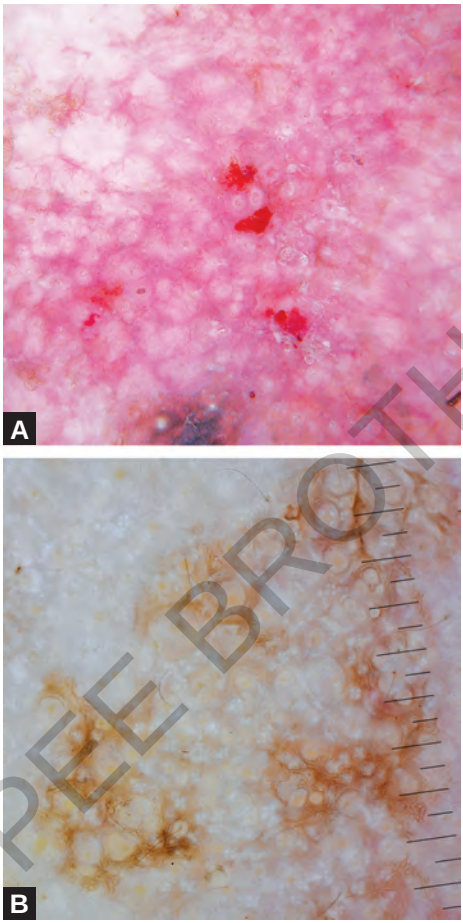

Figs. 4.4A and B: Dermoscopy of actinic keratosis. (A) Strawberry pattern seen in a non-pigmented AK. This pattern consists of a pink background with white or hypopigmented adnexal openings. (B) Pigmented AK, with rosettes and angulated lines forming zigzag lines.
Images courtesy: Harold Rabinovitz, MD.

JAYPEE BROTHERS

Pigmented AK can be difficult to differentiate from LM since both can reveal an annular-granular pattern and angulated lines. However, the annular granular pigment in pigmented AKs tends to be more prominent and keratin can be observed in the follicular openings as multiple rosettes. The rough texture, scalloped borders and strawberry pattern seen in AKs can assist in differentiating them from LM, which tends to have a smooth texture, few to no rosettes, and a non-scalloped border.

Squamous Cell Carcinoma/Bowen's Disease

Squamous cell carcinoma (SCC) is the second most common malignant neoplasm of the skin. Clinically, SCCs usually present as scaly papules, plaques, nodules or tumors. In situ SCC, also known as Bowen´s disease (BD), consists of atypical keratinocytes present in all layers of the epidermis. Invasive SCC can present with ulceration and they can be further classified according to the grade of keratinization into well, moderately or poorly differentiated.

Dermoscopy of SCCs[6-8] (Figs. 4.5A and B and Schematics 3.2 and 4.3)

Dermoscopic structures in *non-pigmented SCC/BD* (Fig. 4.5A; Schematic 4.3A)

1. Yellowish scale present focally or throughout the lesion.
2. Dotted and/or glomerular vessels that are most commonly distributed focally at the periphery of the lesion. However, glomerular vessels can also be present diffusely or aligned linearly within the lesion.
3. White circles, also known as keratinizing pearls.
4. Rosettes.

JAYPEE BROTHERS

Schematics 4.3A and B: Dermoscopic criteria for (A) non-pigmented and (B) pigmented squamous cell carcinoma.



JAYPEE BROTHERS

The first two structures are more frequent in SCC in situ, with a diagnostic accuracy of 98% when yellow scale and focal glomerular vessels are present in the same lesion.[6]

Additional dermoscopic clues in invasive SCC:

- Vascular structures: hairpin/looped, dotted, glomerular and/or serpentine vessels.
- Ulceration

Dermoscopic structures observed in *pigmented SCC/BD* (Figs. 4.5B and 4.6; Schematic 4.3B)

1. Same structures as seen in non-pigmented SCC/BD.
2. Brown dots or globules arranged in a linear configuration.
3. Brown circles

Keratoacanthoma

Keratoacanthomas (KAs) are squamous proliferative neoplasms with follicular infundibular differentiation. KAs are characterized by rapid growth and are considered by some to be well-differentiated SCCs. The clinical appearance of KA is characterized by a dome-shaped papule or nodule with a central keratin filled crater.[9,10]

Dermoscopy of KA[6,8,11] (see Tables 2.3, 2.5 and 3.1; Schematic 3.2; Fig. 4.7)

Dermoscopic structures of KA include:

1. Central brown-to-yellowish keratin scale-crust.
2. Hairpin/looped vessels surrounded by a white halo. These vessels tend to surround the central keratin crust in a radial fashion.
3. Other vascular structures: Serpentine, dotted and glomerular vessels, which also tend to be surrounded by a white halo.

JAYPEE BROTHERS

for detailed information on dermatology books, visit our website **www.jaypeebrothers.com,** for detailed information on dermatology

Pocket Guide to Dermoscopy

Salient Features

- This pocket guide is designed to deliver the salient points of dermoscopy via **concise text**, highlighting the most relevant and important dermoscopic structures and features required to evaluate skin lesions, nail lesions and hair conditions
- The text is complemented by:
  - Easy-to-follow algorithms and flow charts
  - Clear and easy-to-understand schematics
  - Exemplar dermoscopy images emphasizing specific features discussed in the text and illustrated in the schematics
- The information in this book is intended to provide the foundation on which to build one's expertise in dermoscopy.



Natalia Jaimes MD is a dermatologist specializing in the detection and management of skin cancer. Following the completion of her dermatology training in Medellín, Colombia, she participated in a 'skin cancer and pigmented lesion' fellowship at Memorial Sloan Kettering Cancer Center, New York, USA. She is currently in the process of transitioning from being an attending physician at Aurora Centro Especializado en Cáncer de Piel and Universidad Pontificia Bolivariana in Medellín to being an assistant professor at the Department of Dermatology & Cutaneous Surgery at the University of Miami, Miller School of Medicine, Miami, Florida, USA. She is a dedicated physician, educator, and researcher. Her research interests are focused on melanoma, nevi, dermoscopy, and other imaging techniques that enhance early detection of skin cancer.



Ashfaq A Marghoob MD is a board-certified dermatologist specializing in the diagnosis and treatment of cancers of the skin. He is the director of Memorial Sloan Kettering's regional skin cancer clinic in Hauppauge, New York, USA, and also sees patients at the Center's outpatient facility in Manhattan, New York. Although providing the best care possible for his patients remains his primary goal, he also remains committed to education and clinical research. He has published numerous papers on topics related to skin cancer with an emphasis on melanoma, atypical/dysplastic nevi, and congenital melanocytic nevi. His research interests are focused on the use of imaging instruments, such as photography, dermoscopy, and confocal laser microscopy to recognize skin cancer early in its development.

Available at all medical bookstores
or buy online at www.jaypeebrothers.com



JAYPEE BROTHERS
Medical Publishers (P) Ltd.
www.jaypeebrothers.com

Join us on facebook.com/JaypeeMedicalPublishers

Shelving Recommendation
DERMATOLOGY

