information on obstetrics & gynecology books, visit our website **www.jaypeebrothers.com,** for detailed information on obstetrics & gynecology books, visit our website **www.jaypeebrothers.**

THE CAESAREAN SECTION

Indications, Techniques, Complications and Alternatives with Notes on Obstetric Practice in the Tropics

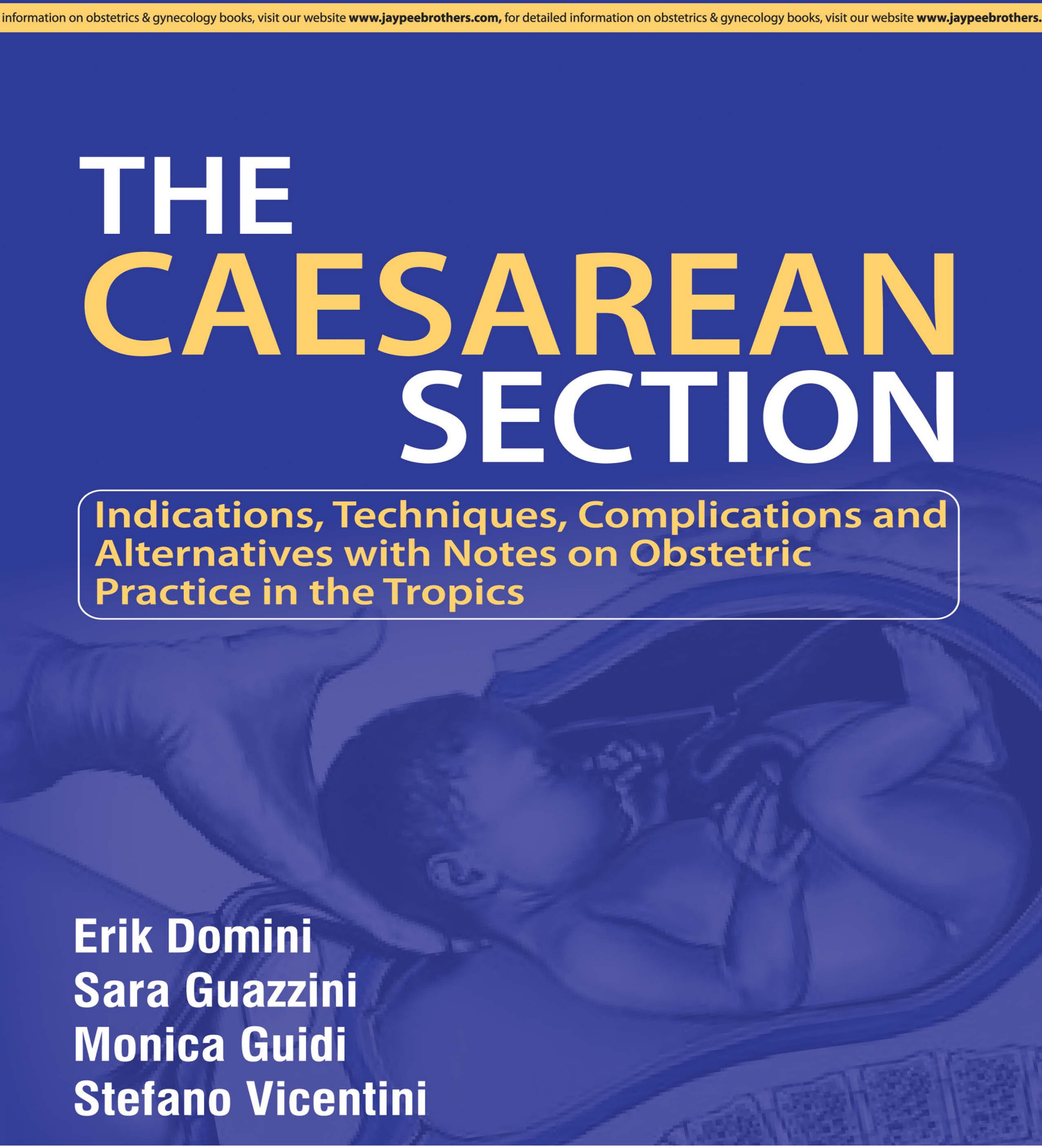

Erik Domini
Sara Guazzini
Monica Guidi
Stefano Vicentini

JAYPEE

Contents

SECTION 1: ANATOMY AND PHYSIOLOGY OF PARTURITION

1. Parturition 3

2. Birth Canal (Passageway) 4
Bony pelvis *4*
Mixed types *23*

3. Uterus 25
Mechanical functions *25*
Histology of the uterus *26*
Contractile activity *27*
Therapy *31*

4. Passenger (Foetus) 32

5. Mechanism and Physiopathology of Parturition 33
Mechanism of parturition *35*
Presentation *35*
Engagement *35*
Descent, rotation and progress *40*
Mechanism of parturition in various pelvic types *40*

SECTION 2: DIAGNOSIS

6. Diagnosis in Clinical Obstetrics 43
Instruments *43*
Diagnosis in clinical obstetrics *43*
Pelvic inlet (superior pelvic strait) *61*

7. Partograph 75
Structure of the partograph *78*
Progress of labour *78*
Uterine contractile activity *79*
Foetal well-being *79*
Treatment *81*
Maternal condition *81*
Filling in the partograph *81*
Matany partograph *86*

SECTION 3: CAESAREAN SECTION AND MANAGEMENT

8. Indications for Caesarean Section Outside Labour **91**
Maternal indications *91*
Foetal indications *99*

9. Indications for Caesarean Section During Labour **102**
Preliminary considerations *102*
Compromise of maternal–foetal gas exchange *102*
Obstacles to the engagement and progress of labour *103*
The two indications presented above in varying relations to each other *105*

10. Trial of Labour **106**
Preliminary assessment of the gravid patient *106*
Actual labour *107*

11. Preparing for the Operation **113**
Preoperative fasting *113*
Intravenous access *113*
Venous cut down *114*
Maternal intensive care *115*

12. Anaesthesia **121**
Basic equipment *121*
Basic medications *121*
Patient's position *121*
Types of anaesthesia *123*
Fundamental rule *123*
Premedication for anaesthesia *123*
Monitoring anaesthesia *123*
Spinal anaesthesia (isobaric subarachnoid) *124*
General anaesthesia *126*

13. Laparotomies **128**
Refresher of surgical anatomy of the abdominal wall *128*
Laparotomy *130*

14. The Various Types of Hysterotomy—Criteria of Choice **144**
Hysterotomy *144*
Lower uterine segment *144*
Criteria of hysterotomy choice *146*

15. Transverse Hysterotomies **147**
Transverse transperitoneal hysterotomies *147*
Technique used by the authors *148*
High transverse hysterotomy *152*
Method used by the authors *154*
Extraperitoneal transverse hysterotomies *157*

16. Vertical Hysterotomies **162**
Low vertical c-section *163*
Predominantly lower-segement c-section *164*
Vertical corpus/lower-segment c-section *165*

17. Management of Intraoperative Complications **168**
Control of haemorrhage *168*
Haemostatic procedures *169*
Uterine devascularisation *170*
Injury to the urinary tract *173*

18. Tubal Sterilization **181**
Indications *181*

19. Abdominal Wall Closure **185**
Physiological introduction of wound healing *185*
Repair of a vertical laparotomy wound *186*
Repair of a transverse laparotomy wound *191*

20. Perimortem and Postmortem Caesarean Delivery **195**
Physiopathology *195*
Indications *196*
Method *196*

21. Uterine Rupture **198**
Uterine rupture during pregnancy *198*
Uterine rupture during labour *199*

22. Monitoring Caesarean Section: Postoperative Recovery **211**
Ward doctor *211*
Observation *211*
Therapy *211*
Ward examination *214*
Abdominal compartment syndrome (ACS) *216*

23. Complications of the Laparotomic Wound Suture **221**
Wound dehiscence *221*
Aetiopathogenesis *221*
Enteric fistulas *225*
Symptomatology *225*

24. Postcaesarean Wound Dehiscence **226**
Early uterus and abdominal wall synchronous dehiscence *226*
Late dehiscence of hysterorrhaphy *227*

25. Obstructed Labour Injury Complex **229**
Vesicovaginal fistulas *229*
Anatomical functional classification of rectovaginal fistulas *231*

26. The Newborn **236**
Introductory remarks on physiopathology *236*
Meconium aspiration syndrome *237*
Labour assistance and assistance to the newborn *237*
Amniiotic fluid stained with meconium *243*

SECTION 4: ALTERNATIVES TO CAESAREAN SECTION

27. Version—Breech Presentation, Transverse and Oblique Lies **249**
Breech presentation *249*
Transverse lie *253*

28. Symphysiotomy–Vacuum Extraction (Foetus Alive–Head Engaged) **257**
Symphysiotomy *257*
Vacuum extraction *262*

29. Destructive Operations—A Vanishing Art in Modern Obstetrics (P Sikka, 2011) **268**
Craniotomy *269*
Evisceration *272*

Index *275*

CHAPTER 3

Uterus

JAYPEE BROTHERS

MECHANICAL FUNCTIONS

The mechanical functions of the uterus are, at different times:

1. To prevent expulsion of the product of conception.
2. To deliver the uterine contents.

Preventing Expulsion of the Product of Conception

The retention of a product of conception as large as that of the human, if managed by a system based on muscle sphincters would require energy and be subject to fatigue; a viscous-elastic structure, such as a cervix made mainly of collagenous connective tissue overcomes these problems.

The shape and composition of the cervix render it ideal for retaining the product of conception: The cervix is tubular in shape and constituted mainly of fibrous tissue (connective tissue, collagen) with a smooth muscle component of just 15% (Danforth, 1954). The cervical connective tissue is not organised structurally, it has been hypothesized that there is a concentration of muscle tissue in the lateral and superior part, and a concentration of elastic and vascular tissue near the fibromuscular junction—the area in which muscle tissue transits into fibrous tissue at the internal cervical os. The cervical canal is between 3 and 5 cm in length, but in advanced pregnancy this reduces to 2–3 cm, and the structure disappears completely during labour.

Composition of Connective Tissue

Base substance: Glycoproteins, water and electrolytes. Glycoproteins are glycosaminoglycans formed by a long protein chain bound covalently to lateral unbranched polypolysaccharides, endowing them with a gel-like consistency. The entire protein–carbohydrate complex can be synthesized within the cells (fibroblasts, muscle cells) and secreted externally via cytoplasmic vesicles.

Collagen: Thanks to their small radius of curvature and close bonding with each other, collagen fibres are nonelastic and capable of withstanding dilatation with a minimum of circumferential tension (Laplace's law). Parturition occurs through an increase in compliance (adaptation to stress) by the fibrils and the basic substances, made possible by dynamic changes in their composition: fibrils become more dispersed and less stable, while the concentration of collagen reduces and there is an increase in the amount of structural proteins—water-retaining glycosaminoglycans.

Cellular components: The cellular components are muscle cells, fibroblasts and macrophages.

Delivering the Product of Conception

Smooth muscle fibre has the following properties:

- *It acts like normal muscle fibre,* so that it returns to its previous length following isotonic contraction (cf. the Braxton–Hicks contractions during gestation). This property is present for long periods during pregnancy and in the primigravida *one contraction per hour* is physiological. During labour, however, the *relaxation phase* is replaced by *fibre retraction*
- *It takes on the property of retraction*, that is, the tendency not to regain its original length at the end of a contraction and to start the next contraction from the length

previously attained. This means that each contraction is followed by a progressive shortening of the fibre, leading to a reduction in the overall volume of the uterus.

HISTOLOGY OF THE UTERUS

The uterus is constituted of peritoneal serous membrane, myometrium and mucosa (Fig. 3.1); only the myometrium is relevant for the purposes of this discussion.

Myometrium

The myometrium comprises a muscle and a connective tissue component.

Muscle Component

During pregnancy, a marked increase in the amount of muscle fibre can be observed. This occurs through two processes:

- Hyperplasia, or the multiplication of existing muscle cells
- Metaplasia, or the transformation of fibroblasts or of certain histiocytes into muscle fibres.

Muscle fibres increase in length from 40–60 μ to 250–500 μ and their width increases from 3–4 to 5–10 μ. 20–100 of these fibres combine to form one individual anatomical unit: the smooth muscle bundle. Muscle bundles or fascicles may be flat, ribbon-shaped, or rope-like. Separated from each other by the connective tissue, they organise into concentric coils in which each one lies in the same orientation, each being joined to the others by many terminal or lateral anastomoses.

At full term of pregnancy, the uterus consists of three muscle layers (Fig. 3.1).

Superficial Layer or Neomyometrium (Fig. 3.1A)

This comprises two arrangements of fibre: Longitudinal and transverse.

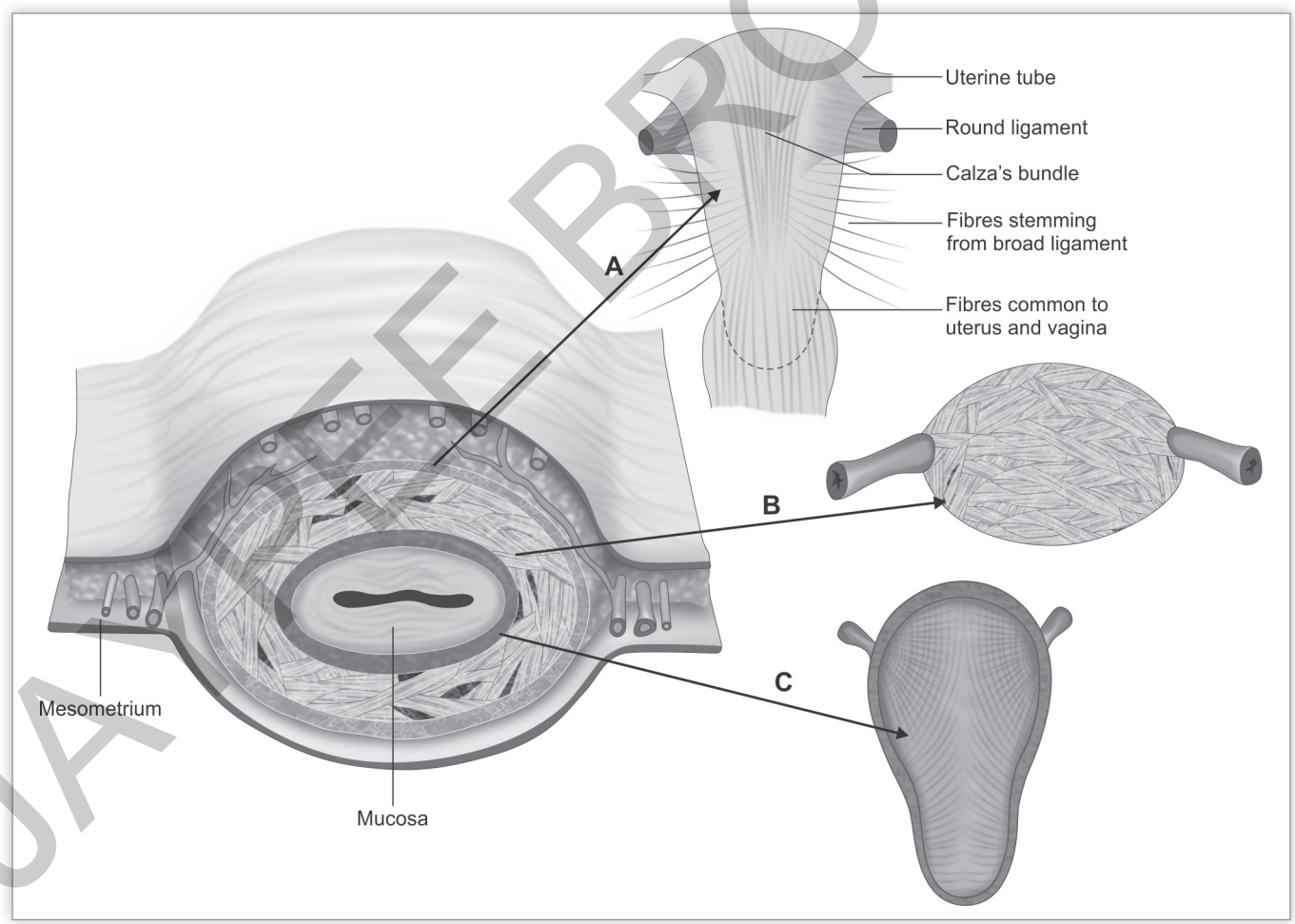

Fig. 3.1: Myometrium. (A) Superficial muscle layer or 'neomyometrium'; (B) Intermediate muscle layer or paleomyometrium (uterine fundus); (C) Internal muscle layer or subendometrial layer (From Kamina P *Anatomia ginecologica ed ostetrica,* DEMI Rome)

JAYPEE BROTHERS

The longitudinal fibres form a flattened body: *Calza's bundle* (Fig. 3.1), which is 10–25 mm wide and clearly seen on the median face of the gravid uterus, covering its anterior, fundal and posterior aspects, taking on a horseshoe shape, whose median portion, which envelops the uterine fundus, is known as the *ansiform fascia of Helie*.

The transverse fibres form a continuous and regular plane, running bilaterally along the whole length of the uterine corpus. As these fibres reach the lateral borders:

- Some bend to form an arch, spanning from the anterior to posterior parts and vice versa, being crossed at this site by numerous vessels
- Others extend beyond the confines of the organ:
  - Into the body of the broad ligament (*ligamentum latum uteri* or broad ligament of the uterus), where they give rise to the muscle laminae that form the double-layered peritoneal sheet
  - Anteriorly to the round ligament (*lig. teres uteri*), these form the ligament of the ovary (*lig. ovarii proprium*), and, on the external layer of the ovarian tube's muscular coat, posteriorly in two distinct bundles directed toward the sacrum, they form the uterosacral ligaments.

Middle Layer, Plexiform or Paleomyometrium Layer (Fig. 3.1B)

This originates from the fusion of the Müller ducts; the muscle fascicles intertwine in every direction, including the venous vessels in their mesh. Such vessels are particularly abundant here, hence the name *Kreitzer's vascular stratum*. On contraction of the uterus, the lumina of vessels within this mesh are occluded, thereby considerably reducing any hemorrhaging.

Internal or Subendometrial Layer (Fig. 3.1C)

This originates from the muscle layer of Müller's ducts; it consists of circular muscle fibres disposed in a series of concentric rings around the uterine orifices. Cephalad, they circumscribe the outlets of the uterine tubes—the uterine ostium (*ostia uterina tubarum*), inferiorly, at the isthmus, they can clearly be seen, protruding beneath the mucosa of the internal uterine os.

Connective Tissue Component

An increase in collagen synthesis occurs during pregnancy, as is revealed by the high percentage of (newly formed) collagen III molecules on analytical ultracentrifugation. This leads to an increase in the amount of connective tissue in the myometrium. Distribution varies in different segments of the uterus: From 40 to 50% in the uterine corpus, rising to 90% at the uterine cervix. The collagen increase in the corpus performs a specific function: by interlacing itself between the muscle fibres, it promotes their sliding over each other and their displacement during uterine contractions.

Lower Uterine Segment

The lower uterine segment (LUS) is derived from the uterine isthmus, which, anatomically considered, is bordered by the *internal histological orifice* (the point of transition between the endometrium of the corpus and that of the cervix) and the *anatomical internal os*. The isthmus differentiates from the corpus during labour, when, the dispersal of muscle fascicles resulting from the increase in loose connective tissue during pregnancy, is augmented by disassociation of the collagenous and elastic fibres, leading to the so-called *demuscularisation* of the lower uterine segment.

Uterine Cervix

The contractile activity of the uterus and the reduction in compliance by cervical fibres are autonomous processes. It is in fact possible for flattening and dilatation (effacement) of the cervix to occur without any contractile activity, just as contractile activity can occur without any change in the cervix (cervical dystocia). During labour these two processes continue almost independently and become coordinated only at a certain point.

CONTRACTILE ACTIVITY

Contraction originates from the area of the uterine tubes and round ligaments, whence it spreads across the whole uterus. It has been thought that there are pace-makers located in the uterus, but a whole series of studies on the subject has so far identified no specific structures dedicated to this purpose.

In the course of a contraction, various segments of the uterus present different pressure gradients, high at the fundus and gradually decreasing caudad to a relatively inactive lower uterine segment. This relation indicates *normal uterine polarity,* which is promoted by a well flexed foetal head and a presenting part that is a good fit for the lower uterine pole.

If the myometrium were spherical in shape, retraction would mean that every contraction would be followed by a reduction in size of the cavity, but not by the expulsion of the product of conception. Expulsion is made possible by the uterus' *truncated conical shape*, with the (truncated) apex pointing distally.

Each contraction brings about two types of phenomena:

- Due to retraction, the uterine cavity progressively reduces in size
- Also due to the process of retraction, as the fundus is functionally dominant, the apex of the cone is stretched

JAYPEE BROTHERS

upwards with each contraction (Fig. 3.2) and is forced to dilate. Concomitantly, flattening and dilatation of the cervix (cervical effacement) is taking place.

Two structures, therefore, two synchronised systems, connected together by the lower uterine segment, may be distinguished functionally: the corpus that contracts and shortens, and the cervix that flattens and dilates. Their harmonious interaction enables engagement and advancement of the presenting part.

Changes induced by a mechanical obstruction during labour, which can result in rupture of the uterus, are described in Chapter 23.

Physiology of Placental Circulation

At full term, uterine perfusion is commonly agreed to be between 500 and 700 mL/min. Of this, approx. 75% goes to the placenta (placental shunt), while the remainder permeates the myometrium (myometrial shunt). Flow volume depends on:

1. The maternal blood supply, in relation to the bore of the arteries and systemic arterial pressure.
2. Venous return.

Arterial blood, at a pressure of 70–80 mm Hg, enters the *intervillous space,* its pressure mirroring, at rest, that of the amniotic fluid, at 10 mm Hg, the blood is therefore projected upward toward the chorionic plate, passing through the villi with a vortex motion that promotes its mixing with the blood already present. Outflow is facilitated by the gradient between the intervillous space and the venous vessels, in which pressure is close to zero. The contractile activity of the myometrium interferes with blood flow to and from the intervillous space, and with foetal oxygenation.

Because of the squeezing action during the initial phase of contraction, blood escapes from the intervillous space and myometrium. This outflow, totalling approx. 200–300 mL, brings about a reduction in the volume of intervillous blood, which lasts until intramyometrial pressure is sufficient to cause the venous vessels to collapse.

Meanwhile, inflow of arterial blood (at a pressure of 80 mm Hg) continues until intramyometrial pressure and the pressure of the amniotic fluid become (at the acme of contraction) high enough to impede even this inflow.

Blood provision has nonetheless sufficed to replenish the initial volume with well-oxygenated blood and to enable effective gas exchange. It has in fact been shown that foetal oxygenation is at its highest at the peak of contraction. With the closure of the arterial vessels, intervillous blood is isolated from the external environment and gas exchanges between mother and foetus rapidly reach equilibrium.

During the relaxation phase, as soon as arterial pressure exceeds intramyometrial pressure, which has until now physiologically isolated the intervillous space, arterial flow resumes. As pressure finally ebbs, the collapsing of the venous vessels relents, allowing outflow of blood from the intervillous space.

It is well understood that the time of greatest danger for the foetus occurs during so-called *physiological isolation of the intervillous space*, characterised by very rapid transfer of O2 and the passage of CO_2 in the opposite direction.

It seems evident that if changes in the rate of blood flow, the properties of the placental membrane, or the timing

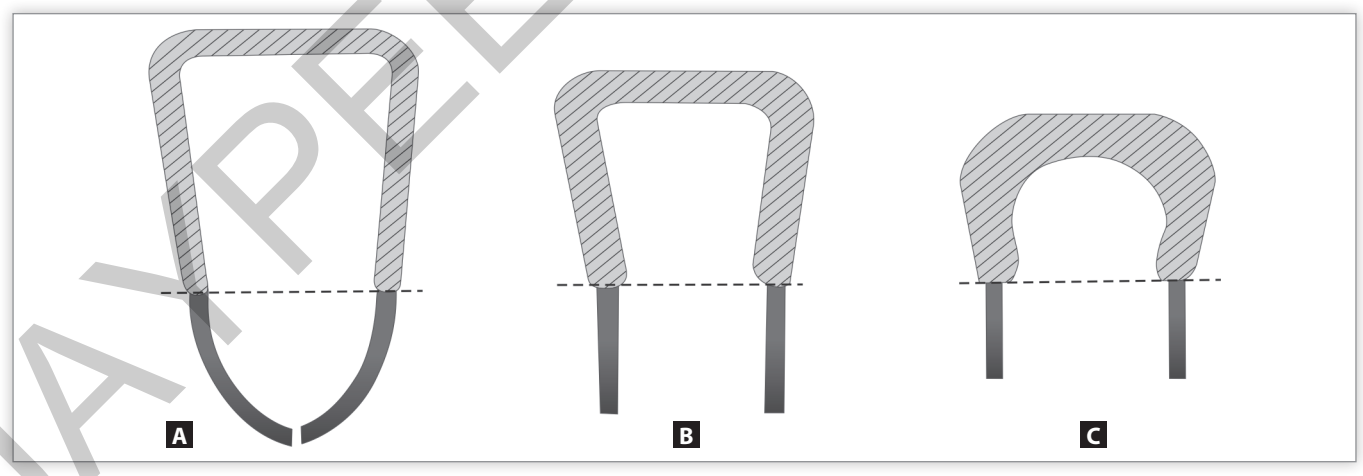

Figs 3.2A to C: Changes affecting the uterine corpus (hatched) and the LUS (in black) during normal labour: (A). At the start of labour, the corpus has the shape of a truncated cone; the LUS is hemispherical; (B). As the expulsive phase starts, the body reduces in height, concomitantly increasing its thickness, and the LUS takes on a cylindrical shape, due to an increase in its circumference and a simultaneous shortening and reduction in thickness; (C) During the expulsive phase, due to retraction, the height of the corpus is reduced still further. Simultaneously, the volume of the uterine cavity decreases. This is the mechanism by which the downwards progress and delivery of the product of conception takes place

JAYPEE BROTHERS

and frequency of contractions occur, gas exchanges will be compromised and a rapid decrease in pO_2 and increase in pCO_2 will result.

A high frequency of contractions entails a shortening of the relaxation phase, compromising the inflow of arterial blood and prolonging the overall period of isolation of the intervillous space, with resulting foetal hypoxia and foetal hypercapnia.

Contractile Activity of the Myometrium

Uterine contraction is defined according to:

- *Polarity*: this indicates the direction of pressure gradients in a contraction. Polarity is normal when pressure gradients are high at the fundus and, proceeding towards the cervix, decrease progressively to a minimally active lower uterine segment. Uterine polarity may be:

1. *Preserved*, with functional domination by the fundus: Pressure gradients decrease as we proceed from the fundus to the cervix. Viewed functionally, this may be:
   a. Normal (Fig. 3.3(1)).
   b. Weak (Fig. 3.3(2)) Ineffective from the point of view of engagement or advancement of the presenting part.
   c. Hypertonic, caused by:
      » Obstruction to engagement or advancement of the presenting part (Fig. 3.3(3))
      » Cervical dystocia: The cervix is flattened, but an organic or functional cause is preventing its dilatation (Fig. 3.3(4)). Without rapid intervention, the upshot of both these conditions will be the formation of Bandl's ring, or pathological retraction ring (Fig. 3.3(5)).
2. *Inverted*, resulting from
   – Hypertonia of the lower uterine segment (Fig. 3.3(6))
   – Cervical stiffness, preventing the normal effacement of the cervix (Fig. 3.3(7)).
3. *Uncoordinated* due to colicky contractile activity that is:
   – Pure (Fig. 3.3(8))
   – Sustained by asymmetry between the two uterine hemispheres (Fig. 3.3(9)).

In the case of a prior hysterotomy, contraction polarity is a valuable indicator of the quality and extension of the uterine scar and its relation to the surrounding myometrium. Normal polarity indicates that the scar is not interfering with contractions. Incomplete transmission of the contraction wave associated with deviations or asymmetries of the uterus, having the scar as their epicentre, indicate impairment of myometrial structure or extensive adhesions between the uterine body and the abdominal wall. Confirmation will come through C-section.

Frequency: This expresses the number of contractions per unit of time, which in obstetrics is 10 minutes. Normal frequency is between 2 and 5; if below 2, contractile activity is ineffective, if above 5, it is aggressive (see section on the physiology of placental circulation).

Intensity: This expresses pressure variations in the amniotic fluid during a contraction compared to uterine basal tone. It is expressed in mm Hg.

- *Basal tone* refers to the minimum pressure achieved by the amniotic fluid during the interval between two consecutive contractions; it is approximately 10 mm Hg.

A close correlation exists between the intensity of uterine contractions and progress of labour:

- *Labour does not start or, if started, it arrests* if contraction intensity is below 15 mm Hg



Fig. 3.3: Various forms of uterine polarity: Hatching indicates contractile activity and pressure gradients. (1) Normal polarity: Intensity of hatching, corresponding to pressure gradients, reduces proceeding caudad; (2) Hypotonic polarity; (3) Hypertonic polarity: obstruction represented by the passenger; (4) Hypertonic polarity: obstruction represented by cervical dystocia; (5) Hypertonic polarity: obstruction represented by Bandl's ring; (6) Inverted polarity due to hypertonia of lower uterine segment; (7) Inverted polarity due to cervical rigidity; (8) Uncoordinated contractile activity of colicky uterus; (9) Uncoordinated contractile activity due to asymmetry of the two uterine hemispheres

JAYPEE BROTHERS

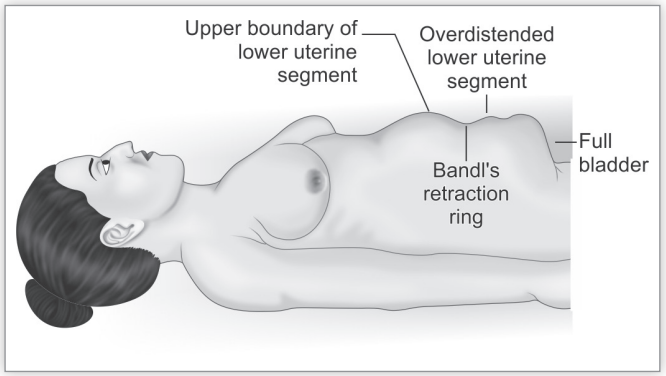

Fig. 3.4: Bandl's ring or retraction ring

- A minimum pressure of 15 mm Hg above basal tone (total pressure of 25 mm Hg) is necessary to dilate the cervix
- *Labour progresses*
- *Normally*, with pressure values between 25 and 50 mm Hg
- *Rapidly* and may result in a precipitate delivery, due to values between 50 and 60 mm Hg.

Duration: The uterine contraction curve can be divided into a rapid increment phase and a rapid decrement phase; both last 40–60 seconds, giving a total of 80–120 seconds, with a mean duration of 100 seconds.

Clearly, a cardiotocograph offers clear appreciation and definition of the features of uterine contraction referred to here. In resource-poor countries, however, this is not always available. Clinical science, however, offers evidential markers that enable a diagnosis of sufficient accuracy:

a. A contraction of the uterus becomes clinically salient only when it reaches 10 mm Hg above basal tone. Therefore, it actually lasts a little longer than can be identified by palpation.
b. The uterine wall can be indented by finger pressure as long as contraction intensity remains below 40 mm Hg. Above this value, it cannot be indented by the fingers.

When polarity is normal, anomalous uterine contractions can be divided into two main groups: hypoactivity and hyperactivity.

- *Hypoactivity* is diagnosed when there are fewer than two contractions every 10 minutes, or when contraction intensity is below 25 mm Hg (hypokinesia)
- *Hyperactivity* is diagnosed when there are more than 5 contractions every 10 minutes, when intensity is greater than 50 mm Hg (hyperkinesia), or when both are present
- *Hypertonia* is present when uterine basal tone is greater than 12 mm Hg. It may be caused by contractile incoordination, tachysystolia or overdistension of the myometrium due to polyhydramnios or multiple pregnancy.

Normal Uterine Polarity with Hyperkinesis (Overactive Contractile Activity)

Even in the presence of an obstruction to the engagement or progression of the presenting part, uterine contractile activity continues. The response of the myometrium to an obstruction consists in:

- Increased strength of contraction
- Increased frequency of contractions, which may reach the point of *uterine tetany*.

Due to the process of retraction, the height of the uterus will progressively reduce until it reaches a critical point, after which the truncated conical form is replaced by a spherical one. At this point propulsion gives way to compression.

The lower margin of the sphere thus formed at the junction with the overdistended lower uterine segment retracts away from the LUS, giving rise to *Bandl's ring or a retraction ring* (Figs 3.3(5), 3.4 and 3.5). This is to be distinguished from a *constriction or contraction ring* (Fig. 3.6).

The *constriction or contraction ring* (Smellie, 1743; White, 1916; Gilliat, 1933; Rudolph, 1937 Caldeyro-Barcia, 1958) is an isolated, persistent, annular contraction of circular fibres occurring in the absence of cephalopelvic disproportion or obstructed labour (Table 3.1).

A contraction ring may occur spontaneously in primigravidae, often preceded by contractile discoordination. It may also be seen in women who have given birth after an

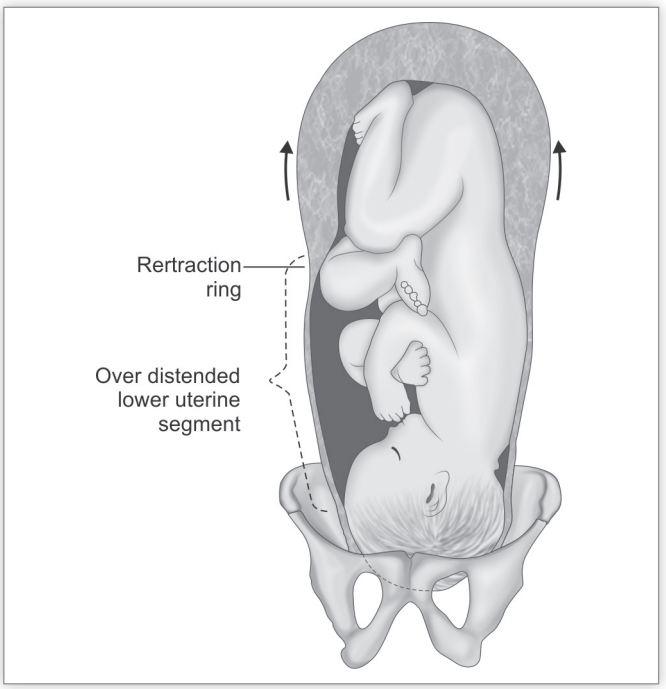

Fig. 3.5: Bandl's ring or pathological retraction ring: The lower uterine segment is overdistended

JAYPEE BROTHERS

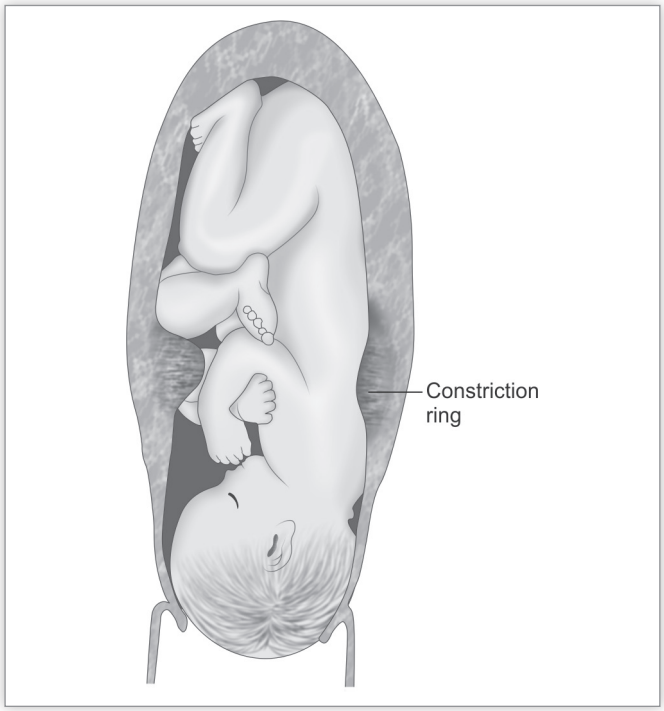

Fig. 3.6: Constriction or contraction ring: The contracted area follows the contours of a depression in the foetus; the lower uterine segment is not overdistended

Table 3.1

Distinguishing features of contraction ring and bandl's ring of retraction

Constriction ring	*Bandl's or pathological retraction ring*
During any period of labour	During dilatation
On the foetal body or an area of low resistance	At the junction between the lower uterine segment and uterine corpus
The uterine wall is thick in the ring area	
The uterine wall caudad of the ring is not thinned	The uterine wall is thinned
The uterine wall cephalad of the ring is not contracted	The uterine wall cephalad of the ring is contracted and hard
Once formed, the ring remains stable in that site	A retraction ring tends to rise
The round ligaments are not tensed	The round ligaments are tensed

insufficient administration of oxytocic agents (in hypertonic inertia or following I.M. administration of oxytocin), or may result from obstetrical handling.

The ring (Fig. 3.6) moulds onto a depression of the foetus: 45% are found at the neck; 21% around the foetal inferior pole; 15% on arms; 9% on the thorax, and 9% around the neck in breech presentation. At birth, signs left behind by a constriction ring on the foetal body can be clearly seen (Mills, 1949); it prevents foetal descent and, during contraction, the presenting part tends to recede.

Unlike the prognosis for Bandl's ring, with a constriction ring the lower uterine segment is not over dilated and there have been no reports of uterine rupture.

Uterine hypertonus, which is always present, compromises placental circulation and intrauterine asphyxia is common.

Complications vary depending on the stage of labour in which the ring appears:

- Prolonged dilatation stage, if it occurs at the uterine cervix
- Prolonged second stage, if around the neck or another part of the foetal body;
- Postpartum haemorrhage, responsible for the retention of the placenta.

THERAPY

- Pethidine during the dilatation stage
- General anaesthesia using volatile anaesthetic agents, in case of resolution of the ring, completion of the delivery by forceps or obstetric suction cap. If the ring fails to relax, C-section with vertical incision of the lower uterine segment is recommended.

BIBLIOGRAPHY

1. Brody S. Uterine distocia and constriction ring. Obstet Gynecol. 1961;18:502-6.
2. Caldeyro-Barcia R. Uterine contractility in Obstetrics. Main lecture. II World congress of International Federation of Obstetrics and Gynaecology. 1958.
3. El-Reyad M, Quinn M. Preterm uterine constriction rings and their consequences. J Obstet Gynaecol. 2008;28:440.
4. Gilliat W. The contraction ring in labour. J Obstet Gynecol Br Emp. 1933;40:1036.
5. Kaye Christopher H. Constriction ring dystocia. Can Med Assoc J. 1974;110:535-8.
6. Mills WG. Treatment of constriction ring dystocia. J Obstet Gynecol Br Commonw. 1949;56:838.
7. Rudolph L. Constriction ring dystocia. JAMA. 1937;108: 532.
8. Smellie W. Treatise on the Theory and Practise of Midwifery. Edited with annotations by McClintock AH. London, New Sydenham Society, 1876; pp. 223.
9. White C. The contraction ring as a cause of dystocia, with the description of a specimen removed by hysterectomy during labour. Proc R Soc Med (Obst Gynaec). 1912;13:70.
10. White C. The contraction ring as a cause of dystocia, with the description of a specimen removed by hysterectomy during labour. Lancet. 1913;1:604.
11. White C. Five cases of labour obstructed by a contraction ring. Br Med J. 1916;2:752-3.

JAYPEE BROTHERS

detailed information on obstetrics & gynecology books, visit our website **www.jaypeebrothers.com,** for detailed information on obstetrics & gynecology books, visit our website **www.jaypeebr**

THE CAESAREAN SECTION

Salient Features

- An excellent handy book
- Provides an in-depth knowledge of anatomy, physiopathology of childbirth, clinical diagnosis and management of obstetric problems
- Brings together 25 years' experience of obstetric practice in tropical countries
- Aims to offer practitioners of obstetrics some basic concepts for tackling the various emergencies which arise generally in resource-poor environments
- Targeted to those who have no specialised training and experience in obstetrics, difficulty in updating their knowledge, and practise obstetrics in local healthcare centres in outlying areas which can be poorly equipped and lacking in trained personnel.



Erik Domini MD FCOG (Padova) is Consultant Obstetrician and Gynaecologist (R) at Ospedale St Spirito, Nizza Monferrato, Italy; Father Ambrosoli Memorial Hospital, Kalongo, Uganda and St Kizito Hospital, Matany, Uganda. He is also Ex-Director of the Gynaecology and Obstetrics Unit at St Spirito di Nizza Hospital, Monferrato (Asti), Italy.

He is graduated from the Faculty of Medicine and Surgery at the University of Padova in 1964, where he went on to qualify as a practising surgeon and subsequently specialised in (a) obstetrics and gynaecology, (b) anaesthesia and resuscitation, and (c) medical oncology.

He has published five books titles as *Introduzione alla Rianimazione Neonatale (Introduction to Neonatal Intensive Care), Verduci, Rome; Le Basi della Terapia Infusionale (Fundamentals of Infusion Therapy), Verduci, Rome; Il Forcipe Ostetrico (Forceps in Obstetrics), Verduci, Rome; Manuale di Ostetricia e Ginecologia Tropicale (Manual of Obstetrics and Gynaecology for the Tropics), CIC, Rome;* and *Il Taglio Cesareo (The Caesarean Section)*, Verduci, Rome. He has authored 40 articles on various topics related to obstetrics and gynaecology. His principal interest is in reconstructive pelvic floor surgery.



Sara Guazzini MD FCOG (Florence) is Registrar, Department of Obstetrics and Gynaecology, Ospedale di Cittadella, Padova, Italy and former Registrar, Department of Obstetrics, St Kizito Hospital, Matany, Uganda. She is graduated from the Faculty of Medicine and Surgery at the University of Siena in 2001 and subsequently specialised in obstetrics and gynaecology at the University of Florence. She spent one year of her specialization training at St Kizito Hospital, Matany, Uganda, tutored by Dr Erik Domini. While writing this book, she has aimed principally at the doctors who wish to practise better obstetrics and gynaecology within limited resources.



Monica Guidi MD FCOG (Florence) is Registrar and Referee for Obstetrics, Department of Obstetrics and Gynaecology, Ospedale di Cittadella, Padova, Italy and former Registrar, Department of Obstetrics, St Kizito Hospital, Matany, Uganda. She is graduated from Faculty of Medicine and Surgery at the University of Florence in 2003 and became a Board certified obstetrician and gynaecologist in 2007. She spent one year intensive specialization training at St Kizito Hospital, Matany, Uganda. Her main interest is in opertative obstetrics.

Stefano Vicentini MD is Medical Superintendent of St. Kizito Hospital, Matany, Ugana.

Available at all medical bookstores
or buy online at www.jaypeebrothers.com

JAYPEE BROTHERS
Medical Publishers (P) Ltd.
www.jaypeebrothers.com

Join us on facebook.com/JaypeeMedicalPublishers

Shelving Recommendation
OBSTETRICS & GYNECOLOGY

ISBN 978-93-5270-019-6

9 789352 700196