bsite **www.jaypeebrothers.com,** for detailed information on dental books, visit our website **www.jaypeebrothers.com**

Celebrating 50 years
Passion, Quality and Innovation in Healthcare Publishing

Clinical Guide for Overseas DENTAL Examination (UK, Europe & Australia)

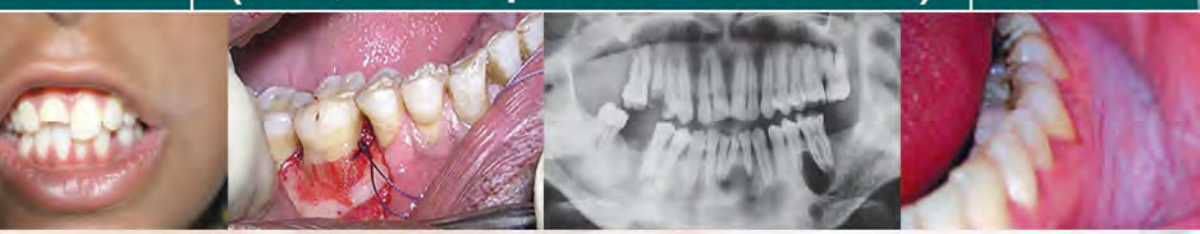



Pooja Verma Ahmad

Co-author
Priya Verma Gupta

Foreword
Manesh Lahori

JAYPEE

Contents

1. History and Examination 1

2. Paediatric Dentistry 25

3. Orthodontics 46

4. Periodontics 67

5. Conservative Dentistry 83

6. Endodontics 102

7. Prosthodontics 120

8. Oral Medicine and Pathology 139

9. Oral Radiology 178

10. Oral Surgery 202

11. Human Disease and Medical Emergencies 228

12. Drugs and Therapeutics 248

13. Dental Materials 266

14. Law and Ethics and General Dental Council 292

Annexures 311

Standards for Dental Team 311

Eligibility Criteria for Registration 312

Eligibility to Apply for Individual Assessment of Knowledge and Skill 312

Overseas Registration Exam 312

Contact Information 314

Application form for Registering as a Dentist with the General Dental Council (Overseas Qualified) .....

Application Process 328

Processing Times 330

Registration for Overseas Qualified Practitioners in Australia 331

Application for Practical Examination–Dentist 335

Application for Written Examination 342

Chapter 3

Orthodontics

Identify the following Statements as True (T) or False (F)

1. **Regarding craniofacial growth:**
   a. In maxilla, growth in width ceases before growth in vertical dimension
   b. Growth in length continues until 17–18 years in girls
   c. Bone is primary determinant of its own growth
   d. Nasal septum acts as independent growth centre
   e. Soft tissue matrix does not contribute to forward and downward maxillary translation.
2. **Regarding growth of craniofacial skeleton:**
   a. The cranial base is formed by intramembranous ossification
   b. Intersphenoid synchondrosis have profound impact on antero-posterior skeletal growth
   c. Spheno-occipital synchondrosis affects maxillary and mandibular relationship
   d. A long cranial base is associated with class III skeletal pattern.
3. **The maxilla:**
   a. Is derived from second pharyngeal arch
   b. Ossifies intra-membraneously, starting in the mesial aspect of nasal capsule
   c. Grows partly via surface remodelling
   d. Moves downward and forward in response to growth of alveolar processes
   e. Growth ceases earlier in males than females.
4. **The mandible:**
   a. Is derived from second pharyngeal arch
   b. Develops mesial to Meckel's cartilage
   c. Growth pattern is dependent on maxillary growth
   d. Growth ceases by 19 years in males.
5. **Growth rotations:**
   a. Have marked effects on the maxilla than mandible
   b. Forward rotation is more common than posterior growth rotation
   c. In forward growth rotation, anterior face height is increased
   d. Posterior growth rotation of mandible results in convex lower border

JAYPEE BROTHERS

e. Lower labial segment crowding results from both anterior and posterior growth rotations.

6. Development of dentition:

a. Spacing mesial to upper canine and distal to lower canine in primary dentition is called Leeway space
b. Leeway space is 1 mm in upper arch and 1.5 mm in lower arch
c. The permanent lower incisors develop buccal to their primary predecessors
d. The permanent upper anterior teeth are accommodated by increase in intercanine distance.

7. Regarding maturational changes in the occlusion:

a. Decrease in lower labial segment crowding
b. Increase in interincisal angle
c. Increased overbite
d. Increased overjet
e. Increase in upper labial segment crowding.

8. Factors implicated in lower labial section crowding:

a. Decrease in mandibular prognathism
b. Transseptal fibre contraction
c. Mandibular growth rotations
d. Presence of aproximal attrition
e. Mesial drift
f. Increased forward maxillary growth
g. Greater in females than males.

9. Regarding classification of malocclusion:

a. Angle's classification is based on incisor relationship
b. The British Standard Institute (BSI) classification is related to first molar relationship in permanent dentition
c. The mesio-buccal cusp of upper first permanent molar occludes anterior to the buccal groove of lower first permanent molar is class I relationship
d. The mesio-buccal cusp of upper first permanent molar occludes posterior to buccal groove of lower first permanent molar is mesio-occlusion
e. In class II division II, the upper central incisors are retroclined with may be increased overjet
f. In class II division I, the upper central incisors are proclined with increased overjet.

10. Aetiology of malocclusion:

a. Majority of antero-posterior skeletal problems are caused by environmental factors
b. Mandibular deficiencies are inherited
c. Mandibular prognathism is strongly related to patient's race
d. Dental arch dimensions are not influenced by environmental factors

JAYPEE BROTHERS

e. Soft tissues postural effects can contribute in developing anterior open bite
f. Early loss of primary teeth is also a cause for crowding.

11. Regarding cephalometrics:

a. It is not obligatory of orthodontic treatment
b. It allows assessment of growth
c. It is used for diagnosis
d. It is measured with maxillary-mandibular plane angle (MMPA) horizontal
e. It is used to compare the patient with normal population standard for his racial group
f. Helps to identify hard tissue pathology
g. Teeth not to be in occlusion during radiograph
h. Is taken with head tilted up
i. It is exact record of facial dimension.

12. Regarding cephalometric interpretation:

a. The cant of the S-N line does not affect SNA values
b. Skeletal pattern can be classified using ANB values
c. Mandibular prognathism can be assessed using SNA values
d. Frankfort plane joins porion and nasion
e. Mandibular plane joins gonion to menton
f. The Frankfort mandibular plane angle (FMPA) is average 27°
g. Maxillary-mandibular planes angle is not related with pattern of mandibular growth
h. Sella is the most anterior point on the cranial base
i. ANB can be influenced by position of nasion.

13. Cephalometric values:

a. SNA: 85°
b. SNB: 79°
c. ANB: 3°
d. S-N/Maxilla : 8°
e. Maxillary Incisors inclination to maxilla plane : 116°
f. Mandibular Incisors inclination to mandibular plane : 100°
g. Inter-incisal angle: 130°
h. MMPA: 22°
i. Facial proportion: 58%.

14. Hypodontia:

a. The most common missing teeth are lower second premolar in 30% cases
b. Affects upper lateral incisors more than second premolars
c. Affects more upper lateral incisors than lower lateral incisors
d. Third molars are commonly missing teeth
e. More common in males than females
f. Does not run in family

JAYPEE BROTHERS

15. Regarding supernumerary teeth:

a. Commonly occur in pre-maxilla
b. Often develops distal to first tooth in each dental series
c. More common in females than males
d. Occurs commonly in primary dentition than permanent dentition
e. Can cause spacing
f. Can occur in lower incisal section.

16. Regarding management of first permanent molars with poor long-term prognosis:

a. Extraction of lower first permanent molars is best when bifurcation of upper permanent third molar are calcifying
b. Extraction of upper first permanent molars is best delayed in class II division I until upper permanent second molar erupts
c. Extraction of upper first permanent molars is delayed in severely crowded mouth until upper permanent second molar erupts
d. Extraction of lower first permanent molars in class III can be deferred until upper permanent third molar erupts
e. Timing of extraction of upper first permanent molars is less important.

17. Regarding serial extractions:

a. Was developed by Kjellgren in 1945
b. Works best in children with class II malocclusion
c. Extraction of primary canines to encourage alignment of permanent incisors around 8–9 years of age
d. Extraction of first primary molar is done to encourage eruption of second permanent premolar
e. Extraction of primary canines as first premolars are erupting.

18. Regarding extraction of primary canines:

a. Loss of primary canines should always be compensated
b. Extraction of canine can prevent cross bite
c. Is indicated when permanent upper lateral incisors is erupting palatally
d. Can prevent loss of periodontal support in lower labial section
e. To promote alignment of displaced mandibular canine
f. Unilateral loss of upper canine does not result in centre-line shift.

19. Regarding extraction of first permanent molars:

a. Spontaneous alignment after extraction of permanent lower first molar, if angulation between crypt of permanent lower second molar and permanent lower first molar is > 30°
b. Increased tendency of mesial drift in mandible
c. If permanent upper first molar is extracted, the lower tooth has to be compensated
d. When permanent lower first molar is extracted, the opposing tooth permanent upper first molar should be compensated
e. Extraction of permanent first molar will relieve labial segment crowding

JAYPEE BROTHERS

20. Regarding maxillary canines:

a. Incident of ectopic maxillary canine occurs in 20% of population
b. 15% are palatal to arch while 85% are buccal
c. Absence of lateral incisors can cause canines to be displaced
d. Palatal displacement of canine has familial link
e. Occurs commonly in males than females
f. Palatal displacement occurs unilaterally
g. Transposition is common between lateral incisor and canine.

21. Spacing of dentition:

a. Commonly found in UK population
b. Median diastema prevails in 98% of 11-year-old
c. Diastema can be caused by proclination of upper labial segment
d. Treatment of diastema requires removable appliance
e. Does not require prolong retention
f. Frenectomy may be indicated
g. Thumb sucking habit one of the causative factor.

22. Increased overjet:

a. With increased overjet, trauma is more common in females than males
b. Anterior oral seal does influence incisor position
c. Overjet reduction can be difficult in patients with low facial height
d. Can be caused by digit sucking
e. Is commonly due to mandible being positioned posteriorly on the cranial base.

23. Digit sucking habit:

a. Can retrocline lower incisors
b. May increase overjet
c. May increase overbite
d. Procline upper labial segment
e. Does not cause buccal segment crossbite.

24. Bimaxillary proclination:

a. Is common in Caucasians
b. Represents inclination of upper and lower incisors
c. May exists in association with class I malocclusion
d. Increased chance of success post-treatment
e. Can be due to increased lips pressure than tongue pressure.

25. Regarding treatment of class II division I malocclusions:

a. The antero-posterior skeletal pattern class I will produce favourable results
b. The forward mandibular growth pattern is unfavourable
c. Digit sucking habit can persist
d. Presence or absence of an adaptive tongue thrust can aggravate malocclusion
e. Overjet reduction to precede overbite reduction

26. With regards to functional appliance:

a. Are effective for individual tooth movements
b. Works by restraining mandibular growth
c. Forward movement of the glenoid fossa
d. To be worn 14–16 hours per day to be effective
e. Does not require post-treatment retention.

27. Increased overbite:

a. In increased overbite, upper central incisors are proclined and upper laterals are retroclined
b. Reduced lower facial height
c. Is associated with posterior mandibular growth rotation
d. Is associated with high lower lip line
e. Reduced inter-incisal angle
f. Can be advantageous in class III malocclusions
g. Scissor bite can be present.

28. Regarding management of increased overbite:

a. Extraction to be avoided in upper arch
b. The inter-incisal angle to be reduced for stable result
c. Overbite reduction precedes overjet reduction
d. Upper removable appliance can be used to procline upper incisors alternatively
e. Does not require long-term retention.

29. Anterior open bite:

a. Only occurs in class III malocclusions
b. Associated with reduced maxillary mandibular plane angle
c. Tongue thrust can maintain anterior open bite
d. Can be seen in cleft lip palate
e. Extraction of molars can close down bite
f. Extrusion of incisors can produce favourable stable results.

30. Reverse overjet:

a. Usually associated with class I skeletal pattern
b. Cross bites are common
c. Dental crowding is greater in lower arch
d. The incisor relationship is less severe than skeletal relationship
e. Becomes worse with growth
f. In severe cases, surgery is indicated
g. Is associated with long anterior cranial base.

31. Cross bites:

a. Are usually skeletal in origin
b. Antero-posterior discrepancies can result is lingual cross bite
c. Occurs only with displacement
d. Can predispose patient to temporomandibular pain and dysfunction syndrome

JAYPEE BROTHERS

e. Unilateral posterior cross bites cannot be treated with upper removable appliance
f. Bilateral buccal cross bites can mainly due to transverse skeletal discrepancy
g. Bilateral buccal cross bites are associated with functional problems.

32. Regarding removable appliances:

a. Are capable of bodily movement
b. Cannot be used for moving blocks of teeth
c. Can be both active and passive
d. Inter-maxillary traction is possible
e. Efficient for multiple tooth movement
f. Can allow differential eruption of teeth
g. Can be used for correcting unilateral posterior cross bites.

33. Regarding fixed appliances:

a. Effective for multiple tooth movement
b. Can move teeth to compensate for skeletal discrepancy
c. Cannot be used in conjunction with other appliances
d. Inter-maxillary traction is used only to increase anchorage
e. Stainless steel wires are used for initial stages of treatment.

34. Functional appliances:

a. Requires wax bite to be recorded
b. Force is in the form of inter-maxillary traction
c. Twin block is the most common type of functional appliance in UK
d. Twin block can be used for cases with abnormal soft tissue pattern
e. Frankel appliances can be worn for meals.

35. Orthognathic surgery:

a. Preferably to be performed before cessation of growth
b. Pre-surgical orthodontic treatment is not indicated
c. Usually involves decompensation
d. Inter-maxillary traction is used post-surgically
e. Relapse can occur both surgically and orthodontically.

36. Regarding cleft lip palate:

a. Cleft lip palate is more common in females than males
b. Unilateral cleft lip palate is more common in right side
c. Cleft palate is more in males than females
d. Sub mucous cleft is noticed fairly early
e. Increased prevalence of supernumerary teeth
f. Cleft palate can be a feature of Treacher Collins syndrome

37. Management of:

a. Lip repair is carried around at 1 month of age
b. Lip repair can be carried out using Delaire technique
c.
d. Millard technique is the method of choice for palatal closure
e. Alveolar bone grafting is performed before child turns 8 years

JAYPEE BROTHERS

f. Alveolar bone grafts allow eruption of permanent canine
g. Rhinoplasty may be indicated as late procedure.

Identify the Single Best Answer for the following

38. Appliance of choice used for expansion in patients with cleft lip and palate:
a. Hass appliance
b. Cap splint type of expansion appliance
c. Hyrax appliance
d. Spring jet.

39. The process of opening bite is:
a. Extrusion of posterior teeth and intrusion of anterior teeth
b. Retroclination of incisors
c. Intrusion of posterior teeth and extrusion of anterior teeth
d. Extraction of lower anteriors.

40. The purpose of cephalogram is:
a. Overjet
b. Assess facial symmetry
c. Deep bite
d. Open bite.

41. ANB angle is used to determine:
a. Vertical jaw discrepancy
b. Crowding
c. Soft tissue profile
d. Sagittal jaw discrepancy.

42. Optimal force for bodily movement is:
a. 15–25 gm force per tooth
b. 50–75 gm force per tooth
c. 75–125 gm force per tooth
d. 200–300 gm force per tooth.

43. Prognathic profile is a characteristic feature of:
a. Skeletal class II malocclusion
b. Pierre-Robinson syndrome
c. Skeletal class III malocclusion
d. Mandibular hypoplasia.

44. The process of cortical drift includes:
a. Apposition of bone
b. Deposition of bone
c. Resorption of bone
d. Resorption and deposition of bone.

JAYPEE BROTHERS

45. The frequently encountered clinical feature along with lip biting, tongue thrusting and thumb sucking is:

a. Deep bite
b. Posterior cross bite
c. Anterior cross bite
d. Proclination of anterior teeth.

46. The function of night guard is:

a. Used to break the habit of tongue thrusting
b. Used to break the habit of lip biting
c. Used to break the habit of bruxism
d. None of the above.

47. In a spring, loops and helices are included so as to:

a. Increase the time interval between their re-activation
b. Increase the flexibility
c. Increase the time duration of its activation
d. All of the above.

Identify the answers to Extended Matching Questions

48. Regarding pre-natal growth and post-natal growth:

a. Intersphenoidal synchondrosis fuses at-------
b. Cranium to face ratio at birth is-------
c. Mid-saggital suture between the parietal bone completely closes at----
d. Total number of skull bones present at birth is-------
e. Time of development of major part of face is_____

1. 3rd to 8th weeks of intra-uterine life	6. 6 week of intrauterine life
2. Middle of third decade of life	7. Prenatally
3. 8:1	8. 78
4. At the time of birth	9. First decade of life
5. 45	

49. Regarding oral habits:

a. Hypertonic orbicularis oris activity is seen in
b. Orthodontic appliance to remove the thumb sucking habit is
c. Proclination of maxillary anteriors in a child can be due to
d. Classical adenoid facies is associated with

1. Water test and cotton test is used to diagnose	6. Vestibular screen
2. Thumb sucking habit	7. Bluegrass appliance
3. A passive removable appliance with cribs	8. Asthma
4. Tongue thrusting habit	
5. Mouth breathing habit	

JAYPEE BROTHERS

CASE DISCUSSIONS

Case 1: Palatal Incisors

A 17-year-old boy presents to your clinic with both upper retained primary canines. Discuss the cause and management of the patient.

History

Ask for patient's concerns and history of complaint

- Any history of trauma to both primary upper canines and loss of primary dentition
- *Medical history*—if Patient is fit and well and underdrawing any medical treatment
- *Dental history*—if patient has been visiting the dental surgery, and what is the treatment rendered.

Examination

- Extra-oral examination:
  - Skeletal class I/II/III
  - Frankfort mandibular plane angle, lower face heights, soft tissue pattern
  - Temporomandibular joint displacement.
- Intra-oral examination:
  - Oral hygiene
  - Any buccal or palatal swelling in primary upper canine area
  - Look for space discrepancies
  - Incisor and molar relationship
  - Any deviations from bites
  - Midline shifts.

Aetiology of Retained Primary Upper Canines

Absence of permanent canines is rare by affecting only 0.3% of Caucasian population. Ectopic position of canine is likely with 2% of Caucasian population. It occurs bilaterally in 17–25% of cases and more commonly found in females than males.

- Genetic: Palatally displaced canine could be due to inherited polygenic trait associated with missing or short rooted permanent upper lateral incisor and anomalies including hypodontia and microdontia
  - Crypt displacement—grossly displaced position of permanent canines
  - Upper canines have longest path of eruption
  - Arch length discrepancies—could be due to palatally placed permanent upper canines displaced in uncrowded or spaced arch
  - Trauma to anterior maxilla at early stage of development could be another season
  - Occurence of lack of guidance due to missing upper lateral incisors, short or peg-shaped upper lateral incisors therefore leads to palatally impacted canines.

JAYPEE BROTHERS

Clinical Investigations

- Palpation and palatal and buccal soft tissue
- Inclination of upper lateral incisors
- Examine position of adjacent teeth, malocclusion and spacing
- Colour, mobility and wear of primary upper canines.

Radiographic Investigations

- To assess position of canine
  - Dental panoramic tomography and intraoral view
  - Vertical or horizontal tube shift parallax.

Assessment

- Vertical placement of primary upper canine to incisor roots
- Root morphology of primary upper canines
- Mesiodistal position of primary upper canine to incisor root
- Axial inclination permanent upper canine
- Apex location permanent upper canine
- Any pathology or incisor root resorption.

Vitality Test

- To check status of upper incisors.

Management

- Interceptive treatment:
  - Removal of primary canines at the age of 10–13 years at mixed dentition stage should induce eruption in case permanent upper canine is slightly palatally impacted between permanent upper lateral incisor and permanent upper first premolar
  - Monitor permanent upper canine to erupt for 6 months
  - If no change, active treatment.
- Retain and observe treatment when:
  - If patient is not keen for treatment
  - No pathology, or root resorption is obeserved
  - Primary canine is not mobile and has good prognosis
  - Permanent upper lateral incisor and permanent upper first premolar are in good contact and aesthetic is not compromised
  - Permanent upper canine is severely displaced but with no associated pathology.
- Expose permanent upper canine and align when:
  - Patient is keen on having treatment and highly motivated for prolonged orthodontic therapy
  - Excellent oral hygiene and health
  - Space of permanent upper canine is available or can be created
  - Permanent upper canine should be in favourable position for orthodontic alignment

JAYPEE BROTHERS

- Expose permanent upper canine, allow it to erupt for 3 months, then orthodontic traction is used to move permanent upper canine towards arch.

- Surgically remove permanent upper canine:
  - If patient not keen on alignment of permanent upper canine
  - Cyst formation in permanent upper canine
  - Poor prognosis of permanent upper canine for alignment
  - Resorption of adjacent teeth
  - Permanent upper lateral incisor and permanent upper first premolar are in good contact and aesthetically pleasing
  - Permanent upper canine has good prognosis and aesthetics
- Transplantation of permanent upper canine:
  - If there is adequate space to fit larger and permanent tooth in space of deciduous tooth and permanent upper canine is 50–75% formed
  - If intact, removal of permanent upper canine is possible
  - Risk of ankylosis/resorption of transplanted permanent upper canine.

Case 2: Missing lateral incisors.

A 11-year old girl presents to your practice complaining of spacing in her upper dentition. On examination, upper lateral have not erupted. Discuss the causes of absent upper lateral incisors and management.

History

- Patient's complaint
- History of complaint
- Medical history—any syndromes of head and neck
- Dental history—history of trauma/avulsion/extraction

Examination

- Extra-oral examination:
  - Skeletal pattern I/II/III
  - Facial symmetry
  - Frankfort mandibular plane angle, lower face heights
  - Soft tissue profile
  - Temporomandibular joint displacement
- Intra-oral examination:
  - Dental hygiene, soft tissue health
  - Incisor relationship
  - Occlusion class I/II/III
  - Any midline shifts
  - Dentition present
  - Space discrepancies.

JAYPEE BROTHERS

for detailed information on dental books, visit our website **www.jaypeebrothers.com,** for detailed information on dental

Clinical Guide for
Overseas DENTAL Examination

The book is designed to provide an idea to students about the examination pattern of overseas examinations. The given multiple choice questions (MCQs) are arranged in combinations of single best answer (SBAs), extended matching questions (EMQs) or conventional true and false statements. Each chapter has a number of MCQs of the conventional true/false variety, single best answer, extended matching questions, coloured clinical pictures and related case studies to consolidate students' theoretical knowledge and clinical experience. The answers to each question are at the end of each chapter with some short notes. The book features over 750 questions and answers to ensure thorough exam preparation and the revision text is best suited for candidates preparing for MFDS, MJDF, ORE, LDS and dental school final examinations. The book intends to provide the perfect practice to build confidence for examination success.

Pooja Verma Ahmad BDS (Lon) MBA (Glas) MFDS RCS (Edin) MFGDP RCS (Eng) earned her Bachelor of Dental Surgery degree from King's College London, London (UK). After receiving an Honours Bachelor's of Arts degree and Master's in Business Administration (MBA) from the Glasgow Caledonian University (UK). After extensive clinical training, she went on to complete Postgraduate Diploma of Membership of the Faculty of Dental Surgery, Royal College of Surgeons of Edinburgh (UK) and thereafter obtained Membership of Faculty of General Dental Practitioner (UK). She is an experienced Dental Surgeon with special interest in aesthetic medicine. She has co-authored and contributed actively to various medical books and publications.

Priya Verma Gupta BDS MDS (Pedo) PhD (Pedo) FPFA is an experienced pedodontist, presently working as Professor and Head, Department of Pedodontics and Preventive Dentistry at KD Dental College and Hospital, Mathura, Uttar Pradesh, India. She has keen interest in academics and has many international and national publications to her credit. She has so far authored 21 books and has contributed actively to other medical and dental textbooks as a co-author as well as contributor. Currently, she is associated with the Editorial Board of Journal of Indian Medical Gazette and Jaypee's International Journal of Clinical Pediatric Dentistry.

Available at all medical bookstores
or buy online at www.jaypeebrothers.com



JAYPEE BROTHERS
Medical Publishers (P) Ltd.
www.jaypeebrothers.com

Join us on facebook.com/JaypeeMedicalPublishers

Shelving Recommendation
DENTISTRY

ISBN 978-93-5270-021-9