information on pathology books, visit our website **www.jaypeebrothers.com,** for detailed information on pathology books, visit our website **www.jaypeebrothers.com**

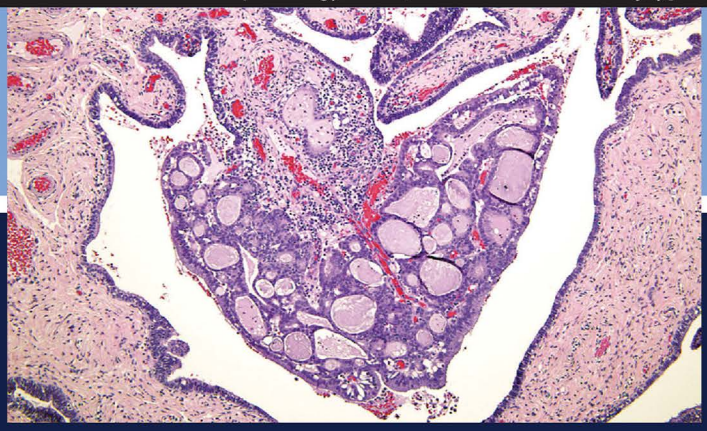

Review of Gynecologic and Breast Pathology

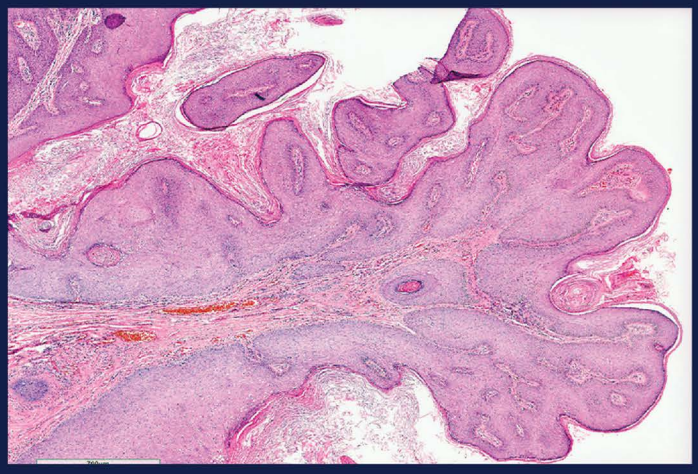

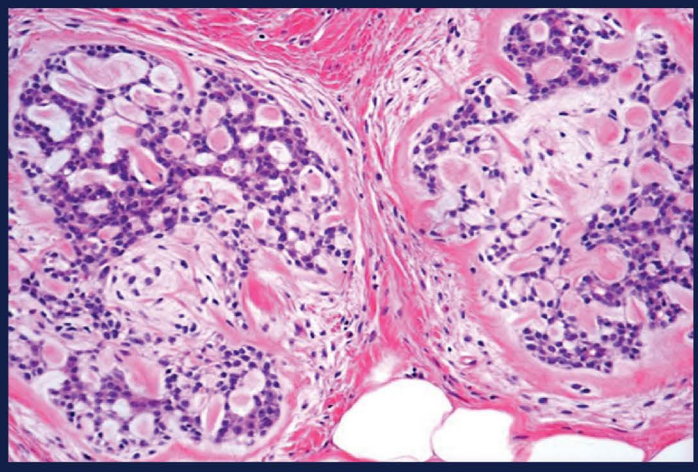

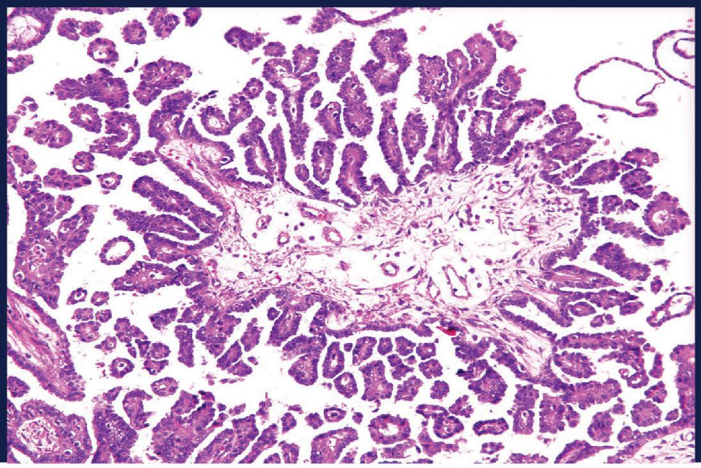

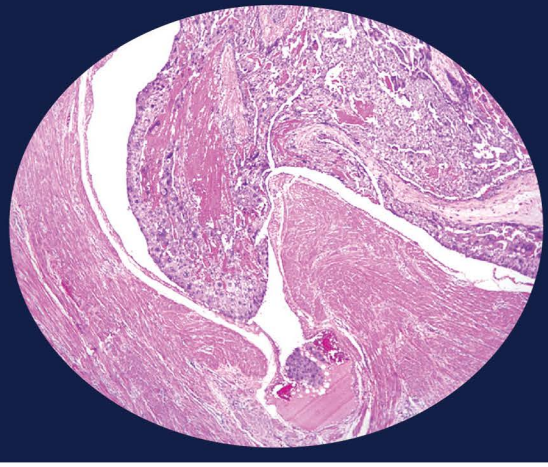

Ivan Damjanov
Semir Vranic
Faruk Skenderi

JAYPEE

Contents

Chapter 1	Vulva, Vagina and Cervix	1
Chapter 2	Uterus	24
Chapter 3	Fallopian Tubes	55
Chapter 4	Ovary	64
Chapter 5	Placenta	113
Chapter 6	Breast	129
Chapter 7	Immunohistochemistry and Genetics	168
Bibliography		*185*

CHAPTER 4

Ovary

JAYPEE BROTHERS

Q.1 Which cells form the Call-Exner bodies in the normal ovary?

A. Oocytes
B. Granulosa cells
C. Theca interna cells
D. Theca externa cells
E. Cortical stromal cells

Answer: B. Granulosa cells

Comment: Call-Exner bodies are formed by **granulosa cells** which aggregate around a centrally positioned acellular eosinophilic spherule composed of extracellular matrix and secretory material. Similar bodies are formed by the neoplastic granulosa cells. These bodies were first described in the rabbit ovary by Emma Louise Call and Sigmund Exner (1875), and deservedly carry their name.

Q.2 Figure 4.1 shows the perihilar tissue of a normal ovary of a postmenopausal woman. The polygonal cells with eosinophilic cytoplasm shown here in the vicinity of nerves and small blood vessels react with the antibody to which of the following antigens?

A. Cytokeratin 20
B. Chromogranin
C. Inhibin
D. Secretin
E. Prolactin

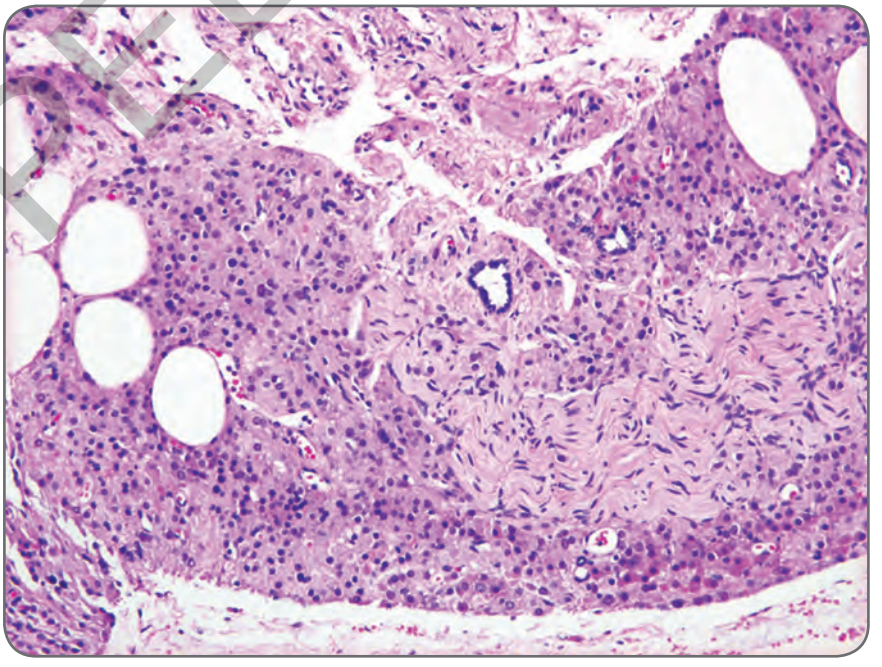

Figure 4.1

Answer: **C. Inhibin**

Comment: Figure 4.1 shows aggregates of **hilar cells** in the mesovarium, commonly found in postmenopausal women. These cells have eosinophilic cytoplasm, which typically reacts with antibodies to **inhibin**. There are two types of inhibin (inhibin A and inhibin B), but most pathology laboratories use antibodies to inhibin A. Hilar cells resemble testicular Leydig cells and may contain Reinke crystals. They are also calretinin positive. Similar groups of cells may be seen inside the ovary itself, usually in the hilum.

Q.3 What is the best diagnosis for the ovarian cyst shown in Figure 4.2?

A. Unluteinized follicular cyst
B. Granulosa lutein cyst
C. Theca lutein cyst
D. Corpus luteum cyst
E. Corpus albicans cyst

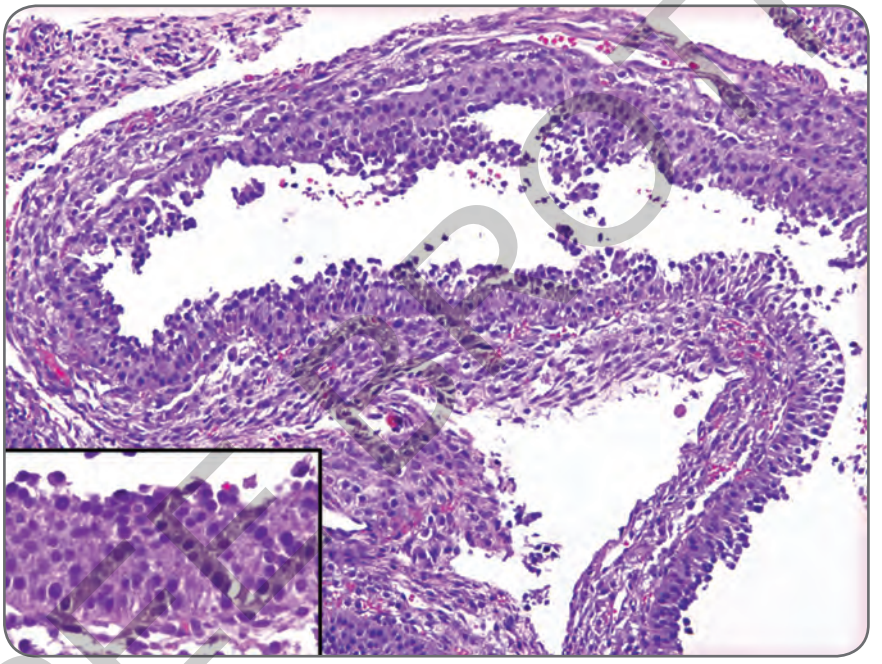

Figure 4.2

Answer: **B. Granulosa lutein cyst**

Comment: This cyst shown in Figure 4.2 is lined by luteinized granulosa cells. These cells are cuboidal and have eosinophilic cytoplasm.

Q.4 Which ovarian cysts predominantly produce estrogens?

A. Unluteinized follicular cysts
B. Theca lutein cysts
C. Granulosa lutein cysts
D. Corpus luteum cysts
E. Corpus albicans cysts

JAYPEE BROTHERS

Answer: A. Unluteinized follicular cysts

Comment: **Unluteinized follicular cysts** are lined by granulosa cells which predominantly secrete estradiol.

Theca lutein cysts secrete androstenedione.

Granulosa lutein cysts are lined by luteinized granulosa cells, which secrete progesterone. In this respect, granulosa lutein cysts resemble **corpus luteum cysts.**

Clinically, all these cysts are classified as **functional cysts**, in contrast to **nonfunctional cysts** which include **corpus albicans cysts** and those related to **endometriosis** or **mesothelial inclusion cysts** and cystadenomas.

Q.5 Which of the following statements is true of luteoma of pregnancy (Figure 4.3)?

A. They usually present clinically during the first trimester of pregnancy
B. Approximately 80% of luteomas of pregnancy occur in African-American women
C. They are usually cystic
D. They are almost always unilateral
E. Cells of these lesions contain abundant lipid droplets

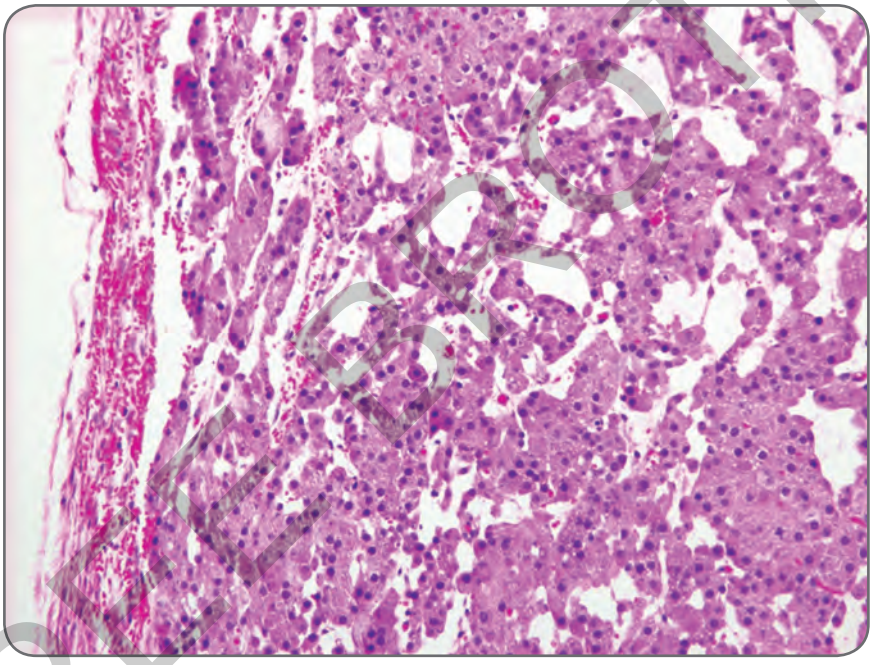

Figure 4.3

Answer: B. Approximately 80% of luteomas of pregnancy occur in African-American women

Comment: For unknown reasons **luteomas of pregnancy** show marked racial predominance and are in approximately 80% of cases found in African-American women. They are diagnosed usually in the third trimester of pregnancy. They present as solid nodules or solid masses, which are usually found in both ovaries. Microscopically, they are composed of cuboidal cells that have have small round nuclei and well-developed eosinophilic cytoplasm (Figure 4.3). In contrast to steroid cell tumors of the ovary, which microscopically may resemble these pregnancy lesions, luteoma cells contain no or only minimal amounts of lipid.

JAYPEE BROTHERS

Q.6 Which of the following diseases is most often associated with hyperreactio luteinalis presenting in pregnancy in form of bilateral multiple theca lutein cysts?

A. Diabetes mellitus
B. Preeclampsia
C. Hyperemesis gravidarum
D. Hydatidiform mole
E. Placenta accreta

Answer: D. Hydatidiform mole

Comment: **Bilateral theca lutein cysts ("hyperreactio luteinalis")** are found in 25% of **molar pregnancies**, as well as those associated with choriocarcinoma. Elevated levels of serum hCG play an important role in the pathogenesis of these cysts, although it is obvious that other conditions must be present for the cysts to arise. Other conditions that may be associated with bilateral theca lutein cysts include the following:

- Multiple fetuses
- Immune hydrops fetus
- Non-immune hydrops fetus
- Maternal chronic renal failure

Bilateral theca lutein cysts involute spontaneously during the postpartum period. Sometimes they may cause multicystic enlargement of the ovaries during pregnancy and may be mistaken during cesarean section or other surgical procedures for cystic tumors.

Q.7 In polycystic ovary syndrome, which of the following parts of the ovary becomes widened and more densely collagenous than in a normal ovary?

A. Outer fibrous part of the cortex
B. Inner cellular part of the cortex
C. Layer of the cortex that contains oocytes
D. Medulla
E. Hilum

Answer: A. Outer fibrous part of the cortex

Comment: In **polycystic ovary syndrome** (PCOS), which is characterized by hyperandrogenism and oligo-ovulation or anovulation, the ovary shows typical but otherwise non-diagnostic changes. These include collagenous widening of the **outer fibrous part of the cortex** and numerous **cystic antral follicles** in the inner part of the cortex (i.e. the part which normally contains the oocytes). The outer cortical layer, which is normally fibrotic and acellular , becomes wider and more collagenous resembling an "**ovarian capsule**". The cystic follicles are typically uniform and show theca cell hyperplasia, reflecting the common excessive LH stimulation of the ovaries. None of these ovarian changes is diagnostic of PCOS, and all of them may be found in other anovulatory conditions. The medulla and hilum are not altered in PCOS.

Q.8 A 25-year-old woman with a history of menstrual irregularities, infertility and mild masculinization presented with lower abdominal pain on the left side. A palpable solid left adnexal mass measuring 15 cm was identified by ultrasound. The contralateral ovary appeared normal. An intraoperative wedge biopsy revealed edema of the medulla and sparing of the cortex, which appeared normal (Figure 4.4). No carcinoma or lymphoma cells were identified by immunohistochemistry. What is the most likely diagnosis?

A. Torsion of the ovary
B. Massive ovarian edema
C. Fibroma of the ovary
D. Sclerosing stromal tumor of the ovary
E. Krukenberg tumor

JAYPEE BROTHERS

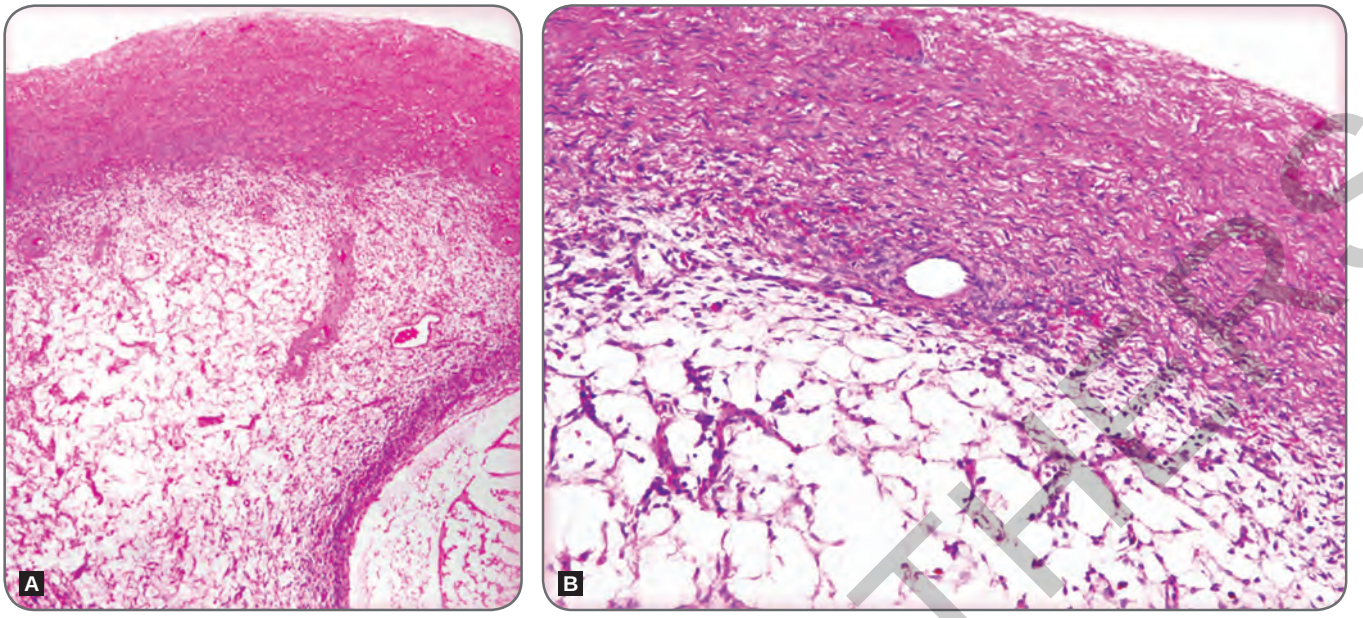

Figures 4.4A and B

Answer: B. Massive ovarian edema

Comment: Edema of the medulla and sparing of the cortex (Figure 4.4A and B), with no evidence of neoplasia on frozen section as well as by immunohistochemistry, is most consistent with the diagnosis of **massive ovarian edema**. The cause of this rare ovarian disease is not known. It has been hypothesized that edema results from partial or recurrent ovarian torsion, even though there is no histological evidence of necrosis or ischemia. As in the present case, the condition may be associated with hormonal changes, even those suggesting PCOS.

All the tumors listed as alternative answers need to be excluded on wedge biopsy, especially if one is contemplating preservation of the ovary.

Fibromas and **sclerosing stromal tumor** of the ovary may be edematous, but in those cases edema involves only the tumor and not the ovary itself. Fibroma is however a tumor of older women, with a peak incidence between 50 and 60 years of age; it is unlikely that it would develop in a 25-year-old woman. Sclerosing stromal tumors occur in the 25-year age group but these tumors have a pseudolobular appearance and tend to compress the ovary.

Krukenberg tumor may cause massive edema, but it is usually bilateral and it is usually found in women who are older than the present patient. In the third decade, one should also consider ovarian **lymphoma**, which may be quite edematous.

In women under the age of 30 years the differential diagnosis should include ovarian fibromatosis, a condition not mentioned in this question. **Fibromatosis of the ovary** is a non-neoplastic condition closely-related to massive ovarian edema, that also may cause enlargement of the ovary. The ovary is lobulated on cross-section and firm. Microscopically, there is dense collagenous matrix enclosing spindle cells that are arranged in a storiform or fascicular manner. Spindle cells extend between the relatively well-preserved normal elements involving the cortex as well as the medulla.

The pathologic entities to be included in the differential diagnosis of massive ovarian edema are included in the Table 4.1.

Table 4.1: Differential diagnosis of massive ovarian edema

Non-neoplastic conditions	• Fibromatosis of the ovary
Benign tumors	• Fibroma • Fibrothecoma • Sclerosing stromal tumor of the ovary
Malignant tumors	• Metastatic adenocarcinoma of GI origin (Krukenberg tumor) • Metastatic goblet cell carcinoid of GI origin • Lymphoma of the ovary

JAYPEE BROTHERS

Q.9 Pathologic examination of the ovaries and tubes removed for clinically diagnosed adnexal/ovarian torsion in children will not reveal an underlying pathologic cause of the torsion in how many instances, as expressed in percentages?

A. Less than 2% (i.e. the cause will be found in essentially all cases)
B. Less then10%
C. Approximately 30%
D. Approximately 50%
E. More than 85%

Answer: C. Approximately 30%

Comment: **Ovarian torsion** almost always involves a torsion of the fallopian tube and therefore it is more appropriate to call it **tubo-ovarian** or **adnexal torsion**. Torsion can occur at any age, including the neonatal period, childhood, and very old age. No identifiable pathologic cause for the torsion could be found in approximately **30% of children** clinically diagnosed to have adnexal torsion. In contrast to children, **adnexal torsion in adults** is most often caused by pathologic processes that cause enlargement of the ovaries. Hence, tumors are a common cause of adnexal torsion in adult women. An increased incidence of adnexal torsion also has been recorded in the first trimester of pregnancy, most likely due to increased mobility of the adnexa in early pregnancy.

Q.10 What is the most common cause of an afollicular premature ovarian failure ("premature follicular depletion")?

A. Unknown (idiopathic)
B. Autoimmune
C. Iatrogenic
D. Environmental
E. Genetic

Answer: A. Unknown (idiopathic)

Comment: The cause of premature follicular depletion resulting in premature ovarian failure cannot be identified in most instances, and it is thus considered to be **idiopathic.** Identifiable causes listed in this question are less common.

Q.11 All the following are constant clinical features of premature ovarian failure, *except:*

A. Amenorrhea for 4–6 months
B. Age under 40 years
C. High serum FSH exceeding 30 IU/L
D. Hypoestrinism
E. Evidence of virilization

Answer: E. Evidence of virilization

Comment: **Premature ovarian failure** (POF) is defined as amenorrhea of 4–6 months duration beginning under the age of 40 years, and associated with postmenopausal levels of FSH (>30 IU/L) and hypoestrinism. Virillization may be present but it is not a constant feature of POF.

Q.12 An infertile 30-year-old woman with typical signs of autoimmunity involving several organs had an ovarian wedge biopsy, which is shown in this Figure 4.5. Which autoantibodies are most likely to be found in this woman?

A. Anti-adrenal antibodies
B. Anti-thyroid antibodies
C. Anti-islet cell antibodies
D. Anti-parathyroid antibodies
E. Anti-pituitary antibodies

JAYPEE BROTHERS

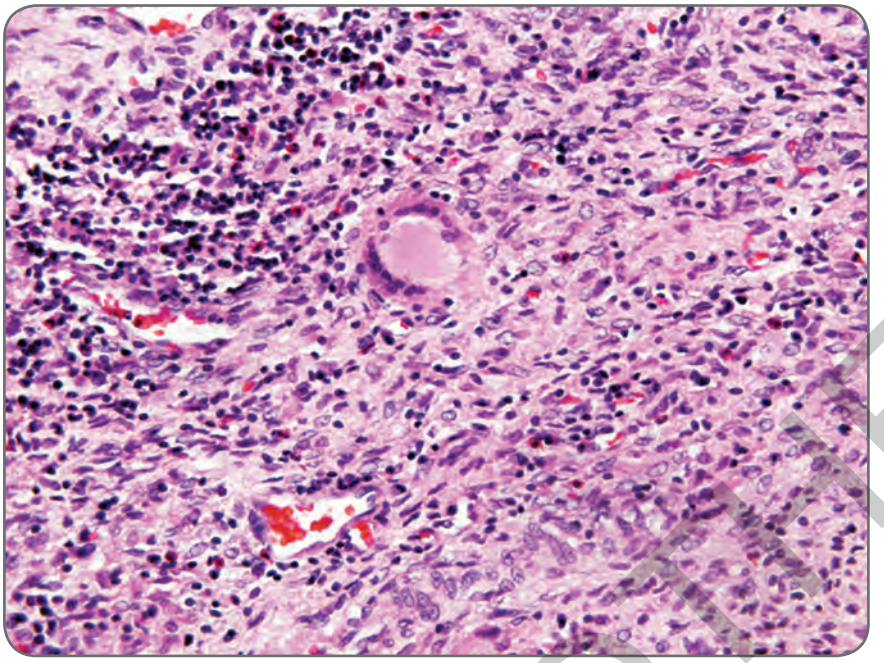

Figure 4.5

Answer: A. Anti-adrenal antibodies

Comment: Microscopic signs of **autoimmune oophoritis**, marked by infiltrates of lymphocytes, plasma cells and macrophages and multinucleated giant cells (Figure 4.5) are usually associated with signs of autoimmune adrenalitis and anti-adrenal antibodies in serum. Many other antibodies may be found in women with autoimmune infertility, but these serologic signs of autoimmune diseases usually do not cause autoimmune oophoritis.

Q.13 Severe ovarian hyperstimulation syndrome (OHSS) induced by clomiphen is characterized by ovarian enlargement. What is the predominant microscopic finding in such ovaries?

A. Multiple corpora lutea cysts
B. Multiple non-luteinized follicular cysts
C. Multiple granulosa-lutein cysts
D. Multiple theca-lutein cysts and one or more corpora lutea
E. Cortical stromal hyperplasia

Answer: D. Multiple theca-lutein cysts and one or more corpora lutea

Comment: **Ovarian hyperstimulation syndrome** (OHSS) is classified as mild, moderate or severe. In the **severe form of OHSS,** there are numerous theca-lutein cysts and one or several corpora lutea.

Q.14 Acute vascular changes induced by radiation of the ovary and mesovarium are most prominent in which blood vessels?

A. Arteries
B. Arterioles
C. Capillaries
D. Venules
E. Veins

JAYPEE BROTHERS

Answer: **A. Arteries**

Comment: Microscopic **vascular changes induced by radiation** of ovaries and mesovarium are most prominent in arteries, although it is believed that most of the tissue damage induced by radiation is caused by the damage of small blood vessels. The most common microscopic changes include fibrinoid necrosis of the arterial wall, thrombi, foam cell accumulation in the intima, and myointimal proliferation of fibroblasts and myofibroblasts.

Q.15 What is the most likely cause of massive hemorrhage from the right ovary?

A. Follicular cyst
B. Corpus luteum
C. Corpus albicans
D. Endometriosis
E. Massive edema of the ovary

Answer: **B. Corpus luteum**

Comment: **Ruptured corpora lutea** are the most common cause of profuse ovarian hemorrhage. Such hemorrhage is uncommon, but 65% of massive bleedings occur from the **right ovary,** usually between day 21 and 26 of the normal 28 day menstrual cycle. The reasons for the bleeding are not known, neither it is known why the **right ovary** is involved more often than the left ovary. Pregnancy and congenital or acquired coagulopathies increase the risk of massive ovarian hemorrhage. Pathologic examination of the wedge biopsy of the ovary will usually identify a partially necrotic corpus luteum as the most likely cause of the bleeding. Luteinized cells, shed from the ruptured corpus luteum, may be seen in the clotted blood removed from the peritoneal cavity.

Q.16 Which of the following is the most common malignant ovarian tumor accounting for approximately 70% of all primary ovarian carcinomas?

A. High-grade serous carcinoma
B. Endometrioid carcinoma
C. Clear cell carcinoma
D. Mucinous carcinoma
E. Low-grade serous adenocarcinoma

Answer: **A. High-grade serous carcinoma**

Comment: **High-grade serous carcinoma** (HGSC) is the most common malignant ovarian tumor accounting for approximately 70% of all carcinomas, which in turn represent over 95% of all ovarian malignant tumors.

Q.17 Expressed in percentages, how many serous ovarian tumors are benign?

A. 10%
B. 25%
C. 50%
D. 70%
E. >90%

Answer: **D. 70%**

Comment: Approximately, 70% of all **serous ovarian tumors** are benign, up to10% are borderline and 20–25% are carcinomas.

JAYPEE BROTHERS

Q.18 Expressed in percentages, how many serous borderline tumors (SBT) are bilateral at the time of diagnosis?

A. Less than 10%
B. Approximately 33%
C. Approximately 50%
D. Approximately 66%
E. More than 90%

Answer: B. Approximately 33%

Comment: Approximately, 33% (one-third) of all **serous borderline tumors** are bilateral at the time of diagnosis. In contrast to these tumors, only 20% serous cystadenomas are bilateral. Approximately, 60% of high-grade serous carcinomas are bilateral.

Q.19 Expressed in percentages, how many serous borderline tumors have spread beyond the ovaries and involve the pelvis or abdominal organs at the time of diagnosis, and are labeled as stage II and III tumors?

A. Less than 10%
B. 25–30%
C. Approximately 50%
D. Approximately 66%
E. More than 90%

Answer: B. 25–30%

Comment: One-fourth and even up to one-third of all **serous borderline tumors** have spread beyond the ovaries at the time of diagnosis.

Q.20 Expressed in percentages, how many borderline serous tumors are classified as serous surface borderline tumors, i.e. show papillary growth on their external surface?

A. 10%
B. 25–28%
C. 50%
D. 66%
E. >90%

Answer: C. 50%

Comment: Approximately, 50% of all SBTs have papillary structures covering their external surface. These tumors are classified as **serous surface borderline tumors**.

Q.21 A 15 cm ovarian cystic thin walled tumor filled with clear yellow fluid was removed from a 30-year-old woman. The inside surface of the tumor was lined by a single layer of cuboidal to cylindrical cells and scattered ciliated cells. There were no papillae, and there were no signs of nuclear atypia or mitoses. What is the most likely diagnosis?

A. High-grade serous carcinoma
B. Serous cystadenoma
C. Serous borderline tumor
D. Mucinous carcinoma
E. Endometrioid carcinoma

Answer: B. Serous cystadenoma

JAYPEE BROTHERS

Comment: This tumor is lined by an epithelial layer that resembles the epithelium of the fallopian tubes. There are no papillae, no atypia and no mitoses and accordingly this benign tumor best classified as **serous cystadenoma**. There is no evidence of malignancy which excludes the diagnosis of carcinoma. Serous cystadenoma must be distinguished from **serous borderline tumors,** which usually contain papillae projecting into the lumen or on their external surface. Microscopically, SBTs show multilayering and piling up of cells as well as nuclear atypia. **Mucinous cystadenomas** are lined by mucin secreting cells. Various cysts, such as epithelial inclusion cysts of the ovary and Müllerian or Wolffian remnant cysts are also in the differential diagnosis, although they rarely attain such a large size.

Q.22 A multilocular cystic tumor filled with serous fluid was removed from the ovary of a 40-year-old woman. It contained numerous solid areas and papillary excrescences inside the cysts and on its external surface. The tumor had the typical microscopic features of a serous borderline tumor but also contained areas as those shown in Figure 4.6. These areas accounted for approximately 5% of the entire tumor. No invasive glandular structures were identified. What is the best diagnosis?

A. High-grade serous carcinoma
B. Serous cystadenoma
C. Serous borderline tumor
D. Serous borderline tumor, micropapillary type
E. Endometrioid carcinoma

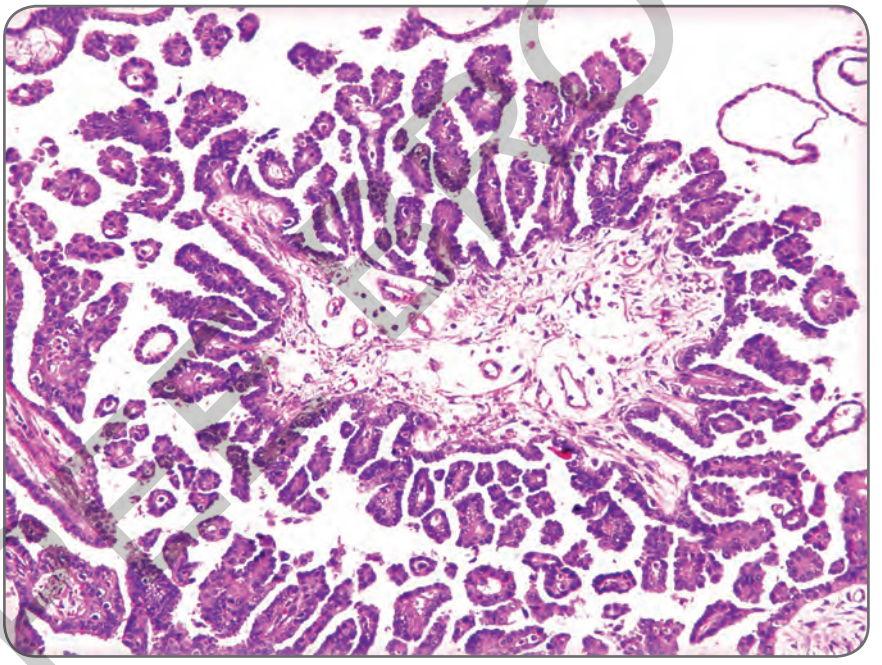

Figure 4.6

Answer: C. Serous borderline tumor

Comment: Up to 10% of all **serous borderline tumors** may contain areas of **micropapillary** growth pattern ("caput medusa like"). If the micropapillary growth pattern does not exceed 10% of the total tumor mass it should not be included in the diagnosis of SBT. If the micropapillary pattern exceeds 10% of the tumor mass, or its foci measure more than 5 mm in diameter, it should be included in the diagnosis (e.g. "SBT, micropapillary type").

Micropapillary growth pattern, is recognized by the characteristic arrangement of thin micropapillae that are five times longer than their cross-sectional diameter, arising abruptly from the central bulbous fibrous core. Micropapillae do not show hierarchical branching and they have no central fibrovascular core.

Contd...

JAYPEE BROTHERS

Contd...

Micropapillary SBT must be distinguished from **high-grade serous carcinoma (HGSC) with micropapillary features**, which is diagnosed when the foci of invasion exceed 10 square millimeters or their depth measures more than 5 mm diameter. Most HGSC with micropapillary features show other signs of malignancy and the diagnosis of HGSC is readily made. In questionable cases, the malignancy is best recognized by the presence of deep stromal invasion and foci of necrosis, as well as the formation of vascularized papillae which are wider and irregular, or confluent.

Q.23 What is the most likely diagnosis for this multilocular tumor filled with serous fluid, showing external surface papillary excrescences (Figure 4.7)?

A. High-grade serous carcinoma
B. Serous cystadenoma
C. Serous borderline tumor
D. Serous borderline tumor, micropapillary type
E. Endometrioid carcinoma

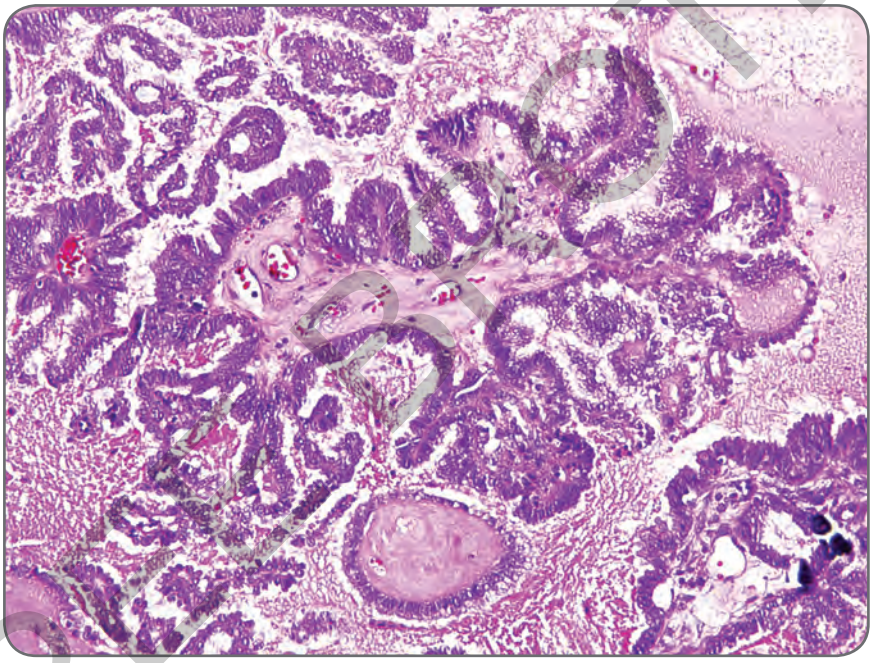

Figure 4.7

Answer: C. Serous borderline tumor

Comment: This tumor is composed of papillae showing hierarchical branching typical of serous borderline tumor.

Q.24 Which cells become especially prominent in serous borderline tumor showing microinvasion of the stroma?

A. Ciliated cells
B. Nonciliated columnar cells
C. Cells showing apocrine secretion
D. Eosinophilic cells
E. Mucinous cells

JAYPEE BROTHERS

Answer: **D. Eosinophilic cells**

Comment: Eosinophilic cells are more pronounced in foci of microinvasion.

Q.25 This ovarian multilocular cystic tumor (Figure 4.8) will most likely show immunohistochemically a diffuse positive reaction with all the following antibodies, *except:*

A. Estrogen receptor
B. Cytokeratin 7 (CK7)
C. WT 1
D. p53
E. PAX 8

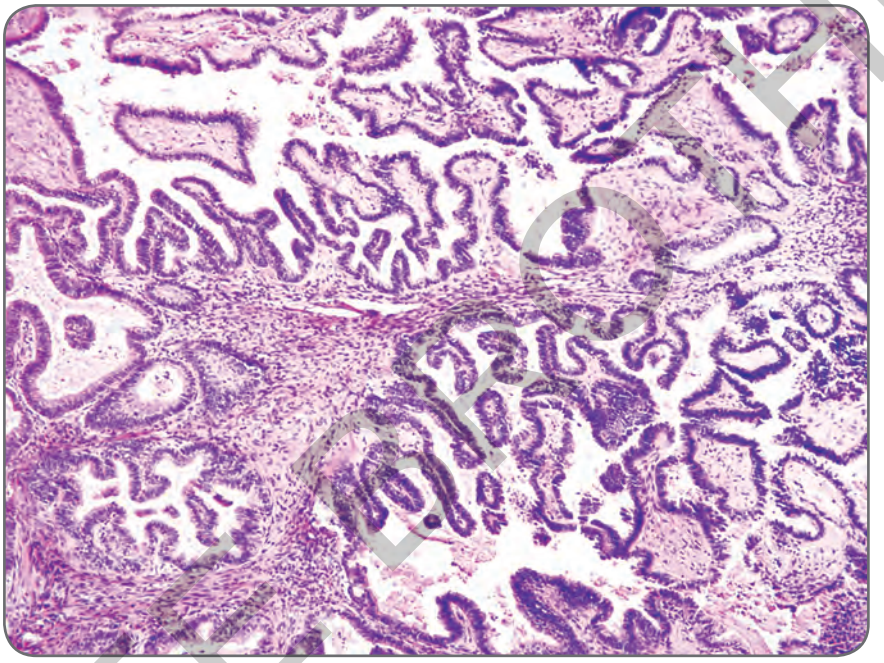

Figure 4.8

Answer: **D. p53**

Comment: This papillary tumor showing hierarchical branching of its papillae is a **serous borderline tumor**. SBTs do not react **immunohistochemically** with antibodies to p53, although the nuclei of some scattered tumor cells may be weakly positive. In this respect, SBTs differ from high-grade serous carcinomas, which are almost invariably positive for p53. Other antibodies react in a diffusely strong manner with most SBT cells.

Q.26 Genetic studies show that mutations of *BRAF/KRAS* genes are common in all the following tumors, *except:*

A. Serous borderline tumors
B. Serous borderline tumors with micropapillary features
C. Serous borderline tumors with invasive peritoneal metastases
D. Serous cystadenoma adjacent to serous borderline tumor
E. High-grade serous carcinoma

Answer: **E. High-grade serous carcinoma**

JAYPEE BROTHERS

detailed information on pathology books, visit our website **www.jaypeebrothers.com,** for detailed information on pathology books, visit our website **www.jaypeebrother**

Review of
Gynecologic and Breast Pathology

What is it?

- A book of questions and answers
- Questions pertain to gross and microscopic pathology of the female genital organs and breasts
- Some questions pertain to microphotographs of typical pathologic lesions
- Some questions pertain to immunohistochemical or molecular biology findings in gynecologic and breast tumors.

What is the aim of this book?

- To help novice students concentrated on most important aspects of gynecologic and breast pathology
- To help seasoned practitioners to review most fundamental as well as most recent aspects of gynecologic and breast pathology
- To improve readers' understanding of standard textbooks of gynecologic and breast pathology
- To test readers' overall understanding and knowledge of gynecologic and breast pathology.

For whom was it written?

- Pathology residents and fellows
- Practicing pathologists
- Academic pathologists
- Gynecology and surgery residents on rotation in pathology
- Advanced medical students contemplating a career in pathology, gynecology or surgery.



Ivan Damjanov MD PhD is Professor, Department of Pathology, The University of Kansas School of Medicine, Kansas City, Kansas, USA. He is the author of more than 30 medical books and over 300 peer-reviewed medical journal articles. He has special expertise in urogenital pathology and developmental biology of early embryos. He has received numerous awards for teaching medical students and residents. His textbooks of pathology are used worldwide and several of them have been translated from English into Chinese, Japanese, Spanish, Greek, Polish and Russian languages.



Semir Vranic MD PhD is Assistant Professor, Department of Pathology, Clinical Center and School of Medicine, University of Sarajevo, Sarajevo, Bosnia and Herzegovina. He is an academic pathologist with special expertise in breast and molecular pathology and a list of publications exceeding 60 peer-reviewed medical journal articles. He has been a lifetime member of the Union for International Cancer Control (UICC) since 2010 and has received awards in form of the American Cancer Society/UICC research fellowship and Erasmus post-doc fellowship. In 2016, he received recognition as "the rising stars in pathology" by the international trade journal *The Pathologist*. He is actively involved in continuing medical education most notably by organizing courses and diagnostic pathology schools with British Division of the International Academy of Pathology and the Turkish Division of the International Academy of Pathology.



Faruk Skenderi MD MSc is Senior Teaching Assistant, Department of Pathology, Clinical Center and Faculty of Health Sciences, University of Sarajevo, Sarajevo, Bosnia and Herzegovina. He has a special interest in kidney tumors and has so far published 20 articles in peer-reviewed journals. He has been awarded *Marie Curie Early Stage Research Fellow* and *BASILEUS* scholarships for research in viral immunology. He is actively involved in teaching pathology at University of Sarajevo, and has been co-organizing pathology and cytology schools in Bosnia and Herzegovina.

Available at all medical bookstores
or buy online at www.jaypeebrothers.com



JAYPEE BROTHERS
Medical Publishers (P) Ltd.
www.jaypeebrothers.com

Join us on facebook.com/JaypeeMedicalPublishers

Shelving Recommendation
PATHOLOGY

