ion on dermatology books, visit our website **www.jaypeebrothers.com,** for detailed information on dermatology books, visit our website **www.jaypeebrothers.com**

ACS(I)

PROCEDURAL DERMATOSURGERY

A Step by Step Approach



Editors

Biju Vasudevan
Manas Chatterjee
Shilpa K

Assistant Editors

Divya Gorur
Madura C
Savitha AS
Shekhar Neema
Harish Prasad
Sujala S Aradhya

Get Full Access with added features at **emedicine360.com**

JAYPEE

Contents

1. Essential Dermatosurgical Instruments **1**
Rajesh Verma, Aneesh KP, Ankan Gupta
- General Instruments *1*

2. Local Anesthesia for Dermatosurgical Procedures **16**
Sushil Tahiliani, Savitha AS
- Anesthetic Agents *16*
- Combination of Local Anesthetics with Adrenaline *16*
- Different Types of Administration of Local Anesthesia *16*
- Tips for Reducing Pain during Anesthesia *26*
- Avoid *27*

3. Suturing Techniques **28**
Vinay Saraf, Savita Yadav
- Suturing the Wound Edges *28*
- Needles *30*
- Suturing Techniques *31*
- Suture Removal *38*
- Complications and Their Management *39*
- Other Means of Wound Closure *40*

4. Dressings in Dermatosurgery **44**
Salim T, Soumya Jagadeesan, Surajit Gorai
- Principles of Wound Dressings *44*
- Types of Dressings *45*
- Choosing a Suitable Dressing *49*
- Complications of Wound Dressings *55*

5. Skin Biopsy Techniques **58**
Shyamanta Barua, Anupam Das, BM Shashikumar
- Indications *58*
- Contraindications *58*
- Selection of Site of Biopsy *58*
- Anesthesia before Skin Biopsy *59*
- Techniques of Skin Biopsy *59*
- Post-Biopsy Considerations *65*
- Complications *66*
- Biopsy at Special Sites *66*

6. Excisions of Cysts and Small Tumors **69**
Dhanashree Bhide, Harish Prasad
- Small Tumors and Cysts *69*
- Basal Cell Carcinoma *76*
- Sebaceous Cyst/Epidermoid Cyst *81*
- Lipoma *87*
- Steatocystoma Multiplex *89*
- Excision of Corn *90*

7. Mole Surgery **94**
Madura C, Pushpa KR
- Patient Selection *94*
- Principles of Surgery for Moles *95*
- Types of Mole Surgery *95*
- Postoperative Care in Mole Surgery *104*
- Complications of Mole Surgery *104*
- Congenital Melanocytic Nevi *106*

8. Dermabrasion **108**
Aarti Sarda, Abhishek De, Shilpa K
- History *108*
- Principles *108*
- Indications *109*
- Contraindications *109*
- Equipment *109*
- Patient Counseling *109*
- Step-by-Step *109*
- Operative Procedure *111*
- Modifications *114*
- Postoperative Care *114*
- Complications and How to Deal? *114*

9. Microneedling **117**
Pradyumna Vaidya, Shilpa K
- Definition *117*
- The Evolution *117*
- Indications of Microneedling *117*
- Contraindications *118*
- Principles of Microneedling *118*
- Histopathology *118*
- Instruments *118*
- Procedure of Microneedling *120*
- Postprocedure Care *121*
- Complications *121*
- Advantages *122*
- Disadvantages *122*
- Innovations *123*

10. Platelet Rich Plasma **124**
Swapnil Shah, Sukesh Mathapathi, Gautam Kumar Singh
- Pathophysiology of PRP Therapy *124*
- Preparation of Platelet Rich Plasma *125*
- Basic Principle of PRP Procedure *125*
- Step-wise Technique of Platelet Rich Plasma Procedure *125*
- Techniques of Preparation *125*
- Activation of Platelets *129*
- Techniques of PRP Delivery *129*
- Classification of Platelet Rich Plasma *130*
- Indications of PRP in Dermatology and Esthetics *130*
- Contraindications *132*
- Complications *132*

11. Surgical Treatment of Acne Scars **135**
Imran Majid, Syed Mubashir
- Types of Acne Scars *135*
- Scar Evaluation *135*
- Principles of Acne Scar Treatment *135*
- Procedures Used for Treatment of Acne Scars *136*
- Microneedling *136*
- Laser Resurfacing for Acne Scars *137*
- Subcision *140*
- Punch Techniques *141*
- TCA Cross *143*
- Dermal Grafting *143*

12. Skin Grafting **147**
Savitha AS, Sujala S Aradhya
- Indications *147*
- Steps of Graft Uptake *147*
- Procedure *148*
- Split Thickness Graft *149*
- Full Thickness Graft *153*
- Postoperative Care *155*
- Graft Contraction *155*
- Contraindications *155*
- Complications *155*

13. Scar Revision Techniques **157**
Shilpa K, Biju Vasudevan
- Ideal Scar *157*
- Counseling *157*
- Definition *157*
- Scar Revision Techniques *157*
- General Principles of Scar Revision *157*
- Types of Scar Revision Techniques *160*
- Complications of Scar Revision and Tips to Prevent Them *171*

14. Flap Surgeries **173**
Divya Gorur, Biju Vasudevan, Shilpa K
- Definition *173*
- Classification of Flap Surgeries *173*
- Preoperative Evaluation *174*
- Type of Anesthesia *174*
- Definition of Common Terms Used in Flap Surgery *174*
- Basic Steps of Flap Surgery *174*
- Rotational Flap *175*
- Advancement Flaps *177*
- Rhombic Flap *182*
- Complications of Flap Surgery *184*

15. Surgical Management of Leg Ulcers **187**
Umashankar Nagaraju, Priyanka Agarwal, Anagha Ramesh, Abhilasha MD
- Definition of Chronic Leg Ulcer *188*
- Management of Chronic Leg Ulcer *188*
- Investigations *188*

- General Measures for Management of Common Leg Ulcers *188*
- Surgical Management of Leg Ulcers *188*
- Debridement *188*
- Skin Graft *193*
- Platelet Concentrates *200*
- Flaps *204*

16. Tissue Grafting Techniques in Vitiligo **208**
Koushik Lahiri, Anupam Das
- Principle *208*
- Indications *208*
- Autologous Minipunch Grafting *208*
- Suction Blister Roof Grafting *211*
- Thin Split Thickness Skin Grafting (STSG) *212*

17. Modifications of Tissue Grafting Techniques for Vitiligo **216**
Debjit Kar
- Suction Blister Grafting *216*

18. Cellular Grafting Techniques **220**
Somesh Gupta, Suman Patra, Debdeep Mitra, Akshi Bansal
- Principles of Cellular Grafting for Vitiligo in Brief *220*
- Principle for Using Hair Follicle as Source of Melanocytes *220*
- Types of Cellular Grafting Techniques *221*

19. Modifications of Cellular Techniques for Difficult Vitiligo **236**
Munish Paul
- Challenging Cases *246*

20. Practical Tips for Management of Keloids and Hypertrophic Scars **248**
Sharad Mutalik, Meenaz Khoja
- Principles of Dermatosurgical Management of Keloids *248*
- Modalities for Treatment of Keloids *248*
- Detailed Procedure for Dermatosurgical Management of Keloids *248*

21. Surgical Management of Earlobe Keloids **254**
Govind Mittal, Biju Vasudevan
- Brief Discussion of the Dermatosurgical Procedure Performed for Some Ear Keloids *259*
- Complications *262*
- Prevention of Recurrence of Ear Keloids Postsurgery *263*

22. Earlobe Repair **266**
Nitin Barde
- Principles of the Surgical Procedure *266*
- Surgical Procedure *266*

23. Nerve Biopsy **273**
BM Shashikumar, Divya Gorur, Syed Mubashir, Amrita Hongal
- Indications *273*
- Preparation *273*
- Selection of Biopsy Site *274*
- Biopsy Sample Handling *274*
- Complications *274*
- Sural Nerve Biopsy *275*
- Distal Superficial Radial Nerve Biopsy *278*
- Tips to the Surgery *279*

24. Nail Surgery **282**
Chander Grover, Nirmal B Krishna
- Essential Prerequisites for Nail Surgery *282*
- Common Nail Surgical Procedures *290*
- Complications in Nail Surgery *300*

25. Hair Transplantation: Follicular Unit Transplantation **304**
Vaishalee Kirane, Narendra Patwardhan, Venkataram Mysore
- Principles of FUT *304*
- History of FUT *304*
- Rationale and Features of FUT *304*
- Indications *304*
- Case Selection and Planning *304*
- Preoperative Counseling *305*
- Informed Consent *305*
- Preoperative Assessment *306*
- Procedure of FUT *308*
- Graft Preparation *311*
- Recipient Area *316*
- Implantation (By Slit and Place) *316*
- Preformed Slits and Place *317*
- Implanters *318*
- Postoperative Care *319*
- Complications *319*

26. Hair Transplantation: Follicular Unit Extraction **325**
Aman Dua, Venkataram Mysore, Nirav V Desai
- Definition *325*
- Principle *325*
- Procedure *326*
- Postoperative Dressing and Healing *331*
- Comparison with Strip *332*
- Body Hair Transplant *332*
- Robotic Hair Transplant: Artas® Robotic System *332*
- Complications *332*

27. Hair Transplantation: Modifications for Other Uses **335**
Madura C, Shilpa K
- Scarring/Cicatricial Alopecia *335*
- Moustache, Beard and Sideburn Transplantation *339*
- Eyebrow Transplantation *342*
- Eyelash Transplantation *347*
- Follicular Unit Extraction (FUE) for Vitiligo *350*

28. Eyelash Transplantation **353**
Manas Chatterjee, Shekhar Neema
- Anatomical Considerations *353*
- Indications *353*
- Contraindications *353*
- Types *353*
- Techniques *353*
- Procedure *353*
- Post-Procedure Care *354*
- Complications *355*

29. Blepharoplasty **356**
Tolong K, Shekhar Neema
- Indications *356*
- Surgical Anatomy *356*
- Preoperative Consultation *357*
- Instruments for Blepharoplasty *357*
- Upper Eyelid Blepharoplasty *357*
- Double Eyelid Surgery or Asian Blepharoplasty *360*
- Lower Blepharoplasty *363*

30. Dimple Creation **370**
Salim T, Laila Achampat
- Anatomy of Dimple *370*
- Principle *370*
- Positioning of Dimple *370*
- Surgical Technique *370*
- Postoperative Care *372*

31. Lipobodysculpting **375**
Nilesh Goyal
- History *375*
- Procedure *375*

32. Autologous Fat Transfer **390**
Nilesh Goyal, Nitin Barde
- Indications *390*
- Principles of Fat Transfer *390*
- Basis/Rationale of Fat Transfer *391*
- Preprocedure *392*
- Procedure *392*
- Complications *396*

33. Surgical Management of Hyperhidrosis **400**
Leelavathy B, Eswari L
- Indications for the Procedural Management *402*
- Procedures *402*
- Surgical Procedures *406*
- Local Surgical Procedures *406*
- Liposuction *407*
- Microwave Device *411*

34. Treatment of Hidradenitis Suppurativa **412**
Shekhar Neema, Kumaresan M
- Clinical Features, Diagnosis and Disease Staging *412*
- Treatment *412*

35. Surgeries of Oral Mucosa **417**
Raghunatha Reddy, BM Shashikumar, Savitha AS
- Commonly Performed Procedures on Oral Mucosa *417*
- Principles of Procedures *418*
- Anesthesia *418*
- Vitiligo Surgery Over Lip Mucosa *420*
- Procedures for Mucous Cyst *427*
- Removal of Superficial Growths *429*
- Some Important Considerations in Oral Mucosal Surgery *431*

36. Surgeries of Genitalia **435**
Revathi TN, Lakshmi DV, Divya Gorur
- Anatomy of Male External Genitalia *435*
- Anesthesia *436*
- Simple Surgical Techniques Over Genitalia *437*
- Circumcision *438*
- Frenulectomy/Frenuloplasty *442*
- Preputioplasty *443*
- Local Skin Flaps for Penile/Genital Skin Loss *444*
- Female Genitalia Surgeries *444*

37. Moh's Micrographic Surgery **446**
Vandana Chatrath
- History *446*
- Indications *446*
- Technique *446*
- Tissue Reconstruction *450*
- Postoperative Care *452*
- Complications *452*
- Advantages *453*
- Disadvantages *453*

38. Sclerotherapy **455**
S Sacchidanand, Sujala S Aradhya, Nagesh TS
- Mechanism of Action *455*
- Indications *455*
- Contraindications *455*
- Sclerosants *455*
- Preprocedure Work Up *455*
- Procedure *457*
- Postprocedure Care *458*
- Complications *459*
- Special Techniques of Sclerotherapy *460*

39. Use of Chemicals in Dermatosurgery **462**
Niti Khunger, Shikha Bansal
- Acne Surgery *462*
- Nail Surgery *464*
- Chemosurgery for Viral Infections *466*
- Seborrheic Keratosis, Dermatoses Papulosa Nigra *467*
- Xanthelasma Palpebrarum *467*
- Freckles and Lentigines *468*
- Ear Lobe Repair (Chemical ELR) *469*

40. Cryotherapy **470**
Avitus John Prasad, Shruthi C
- Indications *470*
- Mechanism of Action *470*
- Cryosurgery Equipment *471*
- Cryotherapy Protocol *472*
- Treatment Modalities Using Cryotherapy *473*
- Innovation in Cryotherapy *475*
- Case Handling *480*
- Complications of Cryotherapy *480*
- Contraindications to Cryotherapy *482*

41. Radiofrequency and Electrocautery **484**
Bipin Deshpande
- Fundamentals *484*
- Radiofrequency *484*

42. Lasers in Dermatosurgery: Treatment of Hyperpigmentary Disorders **522**
BS Chandrashekar, Pavan Raj R, Madura C
- Laser Principles *522*
- Epidermal Pigmented Lesions *524*
- Mixed Epidermal/Dermal Pigmented Lesions *526*
- Dermal Pigmented Lesions *528*
- Patient Selection and Preprocedure Evaluation *532*

43. Lasers in Dermatosurgery: Treatment of Hypopigmentary Disorders **538**
BS Chandrashekar, Madura C, Shubhani Saini
- Excimer Laser/Lamp *538*

44. Lasers in Dermatosurgery: Treatment of Vascular Lesions **544**
BS Chandrashekar, Madura C
- Background *544*
- Laser Devices *546*
- Patient Selection and Preoperative Evaluation *547*
- Techniques *547*
- Treatment of Specific Conditions *548*

45. Lasers in Dermatosurgery: Treating Exophytic Lesions **561**
BS Chandrashekar, Madura C, Varsha DV
- Laser Principles: Laser Devices and Laser Tissue Interaction *561*
- Patient Selection *564*
- Preprocedure Preparation *564*
- Anesthesia *564*
- Specific Indications *564*
- Postlaser Instructions *573*
- Sequelae *573*
- Side Effects *573*

46. Lasers in Dermatosurgery: Treating Scars **577**
BS Chandrashekar, Madura C, Sushmitha Jayaprasad
- Prelaser Evaluation *577*
- Postprocedure Care *578*
- Acne Scars *578*
- Hypertrophic Scar and Keloid *581*
- Atrophic Scars *587*
- Lasers for Scar Prevention *587*
- Stretch Marks *589*

47. Lasers in Dermatosurgery: Treating Excessive Hair **592**
BS Chandrashekar, Teena Ramesh, Madura C
- Mechanism of Laser Hair Removal *592*
- Diverse Applications of Laser Hair Removal *593*
- Hypertrichosis and Hirsutism *593*
- Different Hair Removal Devices *596*
- Device Variables *600*
- Treatment Guidelines *600*

- Treatment Technique *601*
- Complications of Laser Hair Removal *603*
- Safety *604*
- During Pregnancy *605*
- Future Directions *605*

48. Lasers in Dermatosurgery: Safety and Complications **607**
BS Chandrashekar, Chaithra Shenoy
- General Safety Measures *607*
- Laser Hair Reduction *607*
- Ablative and Fractional Resurfacing Laser *609*
- Pigment Laser *610*
- Vascular Lasers *612*
- Complications due to Topical Anesthesia *612*
- Ocular Complications due to Lasers *613*
- Laser Safety and Application in Childhood and Pregnancy *613*

49. Lasers: Algorithms **615**
BS Chandrashekar, Madura C, Neelima Ravipati

50. Botulinum Toxin in Dermatosurgery **617**
Shehnaz Arsiwala, Pradeep Kumari, Rasya Dixit, Chaithra Shenoy
- Definition *617*
- Clinical Application of BTX in Dermatology *619*
- Contraindications for BTX Treatment *619*
- Hyperhidrosis *620*
- BTX in Palmar Hyperhidrosis (Off Label Indication) *621*
- BTX in Lichen Simplex Chronicus *622*
- Botulinum Toxin in Scars *622*
- Postherpetic Neuralgia *623*
- Blepharospasm *623*
- Multiple Eccrine Hidrocystoma *625*

51. Fillers in Dermatosurgery **626**
Rasya Dixit, Harish Prasad, Chaithra Shenoy
- Definition *626*
- Types of Fillers *626*
- Principle of Fillers *626*
- General Technical Considerations for Dermal Fillers *628*
- Needles versus Cannula *631*
- Complications and Their Prevention *632*
- Specific Indications for Fillers *632*

52. Micropigmentation **637**
Amit Kerure, Satish Udare, Madhulika Mhatre

Index *647*

CHAPTER 4

Dressings in Dermatosurgery

Salim T, Soumya Jagadeesan, Surajit Gorai

INTRODUCTION

Dressings are an important part of the therapeutic armamentarium of any dermatologist. In addition to the care of surgical sites, the dermatologists are also involved in the treatment of acute and chronic wounds. With the advances in the last few decades, we are faced with an increasing variety of dressing materials to choose from. The selection of the dressing is often crucial and depends on the practitioner's skilled assessment of the wound and the knowledge of how to provide an optimum wound healing environment through the use of the available appropriate dressings.

PRINCIPLES OF WOUND DRESSINGS

The principles of wound dressings have changed dramatically in the recent years with the changing social needs and the new insights into the pathophysiologic mechanisms of wound healing. Previously, it was not uncommon for a patient to be admitted for a prolonged period in the hospital for the management of a nonhealing ulcer, with frequent and often painful change of dressings. Currently, with the inadequate resources to provide in-patient treatment to all chronic wounds and with the reduced acceptance of prolonged morbidity, new parameters of dressings have emerged. A dressing is no longer a passive covering for wounds; it performs a rather active role in promoting wound healing and repair. The wound being recognized as a synthetic environment where numerous complex cellular processes are interlinked in the process of repair, the modern dressings are designed to nurture the cellular environment of the wound.[1]

Moist Healing Environment

One of the most important observations in the last several decades is that, the wound that is kept adequately moist heals faster. The evidence for this is more in acute wounds. However, even in chronic wounds, moisture-retentive dressings have been found to lead to a number of desirable outcomes such as pain control, painless autolytic debridement and stimulation of granulation tissue. Also, occlusion of the wound is contraindicated in the presence of infection. The principle behind moisture allowing greater re-epithelialization is not fully known. The proposed mechanisms include: (1) dry wound surface and scab inhibiting keratinocyte migration; (2) a favorable electrical gradient in moist wounds; (3) retention of cytokines and other growth factors in the wounds occluded with moisture-retentive dressings.[2-4]

The Role of Oxygen

For a long time, it was believed that the availability of oxygen was critical in wound healing. The subsequent studies have shown that hypoxia in fact triggers keratinocyte migration, promotes angiogenesis and stimulates the secretion of growth factors by the dermal fibroblasts.[5] The use of a semipermeable dressing can provide adequate oxygen tension required for the wound to heal properly.

The characteristics of an ideal dressing are listed in Table 4.1.[6]

Table 4.1: Characteristics of an ideal dressing.

- Absorbs extra exudates
- Allows gaseous exchange
- Barely need changing
- Comfortable and conformable
- Cost effective
- Damage protector (prevent further trauma)
- Long shelf life
- Noncytotoxic, nonsensitizing
- Provide sterile environment
- Provide thermal insulation

JAYPEE BROTHERS

Table 4.2: Advantages and disadvantages of the conventional dressings.

Advantages	*Disadvantages*
Inexpensive, readily available	Require frequent replacement, hence time-consuming
Less chance of adherence to the wound	Can cause maceration of the wound and the surrounding skin, if left in situ for a long time
Can be molded into deeper wounds, will fill the dead space and absorb exudates	Lack specialized properties

TYPES OF DRESSINGS

Conventional Dressings

The conventional dressings that are still being used widely are made of materials like cotton, silk, linen, cellulose, etc. and have been tried and tested since historical times. Other materials like white petrolatum, antibacterial agents like povidone-iodine, chlorhexidine or balsam of Peru may be impregnated in the conventional dressings, depending on the indication. It is important to know about the conventional dressings before we move to modern dressings.

The conventional dressing is usually a 'layered' or composite dressing which is either a 'pressure' or 'nonpressure' dressing.

The 3 layers commonly seen are:

1. A contact interface layer
2. The absorbent layer
3. The outer 'wrap'.

The contact layer is the one that is directly in contact with the wound and is usually permeable to fluids and is nonadherent. A layer of antibiotic ointment or a contact layer of nonadhesive material, such as paraffin gauze or antibiotic impregnated tulle, serves this purpose. The middle absorbent layer is usually composed of materials like cotton pads or gauze and helps to absorb the exudates and to mold to the shape of the wound. The outer layer (like a tape or a roller bandage) helps to secure the dressing in place. Each layer should be in close contact with the adjacent layer with no gaps or air pockets.

In a pressure dressing, the key difference is that more bulk is added to the absorbent layer with the aim of creating hemostasis. The usual sites of pressure dressings include the scalp and digits. It is commonly applied immediately after a surgical procedure and changed in 24 hours. Care should be taken that the pressure created does not become excessive, where it can result in ischemia and tissue necrosis.[7]

The advantages and disadvantages of the conventional dressings are listed in Table 4.2.[8]

Modern Dressings

***Occlusive dressings*:** These are of 6 categories—alginates, hydrogels, hydrocolloids, films, foams and hydrofibers. Their properties are listed in Table 4.3.[7] **Absorbent dressings** include *alginates* (Figs. 4.1A to F), *hydrofiber, foam dressings* and the more sophisticated super-absorbent dressings containing polyacrylate polymers. They handle fluid in different ways. Foams simply soak up fluid, alginates change in structure from a dry product to a gel and hydrofibers draw and lock the fluid away from the wound bed. **Moist dressings** work by either preventing the skin surrounding a wound from losing moisture or by actively donating moisture to the wound area. Examples are either *hydrocolloids* or *hydrogels*, both working by either adding or helping to maintain moisture by promoting autolytic debridement. **Surgical dressings** are used to cover the incision wounds postoperatively and generally, low adherent transparent polyurethane dressings like *films* (Figs. 4.2A and B) or island dressings are used for this purpose.

Antimicrobial Dressings

In the modern times, sophisticated dressings have emerged which provide adequate bacterial control over the wound site. They are impregnated with antimicrobial substances like silver and iodine and reduce the need for frequent topical application and dressing change.[7] Recent advances in antiseptic technology have resulted in the development of products that are less harmful to healthy tissue while being highly effective in destroying pathogens; some examples are honey, silver, iodine, cadexomer iodine and polyhexamethylene-biguanide (PHMB).

In older silver-containing dressings, the silver ions were present in the form of silver nitrate ($AgNO_3$) and silver sulfadiazine. However, newer formulations consist of high-density polyethylene mesh impregnated with

JAYPEE BROTHERS

Table 4.3: Properties of occlusive dressings.[7]

Type	*Properties*	*Indications*	*Advantages*	*Disadvantages*	*Trade names available*	*Tips*
Alginates	1. Derived from brown seaweeds (phaeophyceae) 2. Forms a gel when in contact with the wound surface, which can be lifted off at dressing removal or rinsed away with sterile saline	Infected wounds and highly exudative wounds Full-thickness burns Particularly useful in postoperative packing	Highly absorbent with spontaneous sucking ability The ion-exchange properties of some alginates make them hemostatic agents Nonadherent Conforms to wound shape No reports of toxicity Useful in infected wounds	Requires secondary dressing to absorb the exudates and these need to be changed regularly Possess an unpleasant appearance and odor; the yellowish color of the gel may be mistaken for pus	KALTOSTAT	May be used in dry wounds also, but after moistening with saline and daily dressing change to prevent dessication
Hydrocolloids	Usually composed of a hydrocolloid matrix bonded onto a vapor-permeable film or foam backing; forms a gel that provides a moist environment when in contact with the wound surface	Moderately exudative wounds Chronic ulcers Burns Surgical and traumatic wounds	Adhere to wound edges and therefore, allows the patient to bathe and shower. Capillary action facilitates debris removal Thermal insulation	Opaque Risk of maceration of surrounding skin Possible wound trauma with dressing change Gel has unpleasant appearance and odor; like alginates, may be mistaken for pus Caution in infected wounds	DUODERM TEGASORB	Can be cut according to size in the sheet form. When it absorbs the exudates- causes autolytic debridement and improves angiogenesis waterproof
Hydrogels	Consist of cross-linked insoluble polymers and up to 96% water	Mildly exudative wounds Lasers, superficial burns Chemical peels burn Graft donor sites	Donates fluid to necrotic tissue Soothing, cushioning and cooling effect (reduces temperature by about 5°C) Reduction of postoperative pain Semitransparent	Absorption is slow Requires secondary dressing Maceration can occur Caution in infected wounds	HI-ZEL	The cooling effect of the dressing can be augmented by prior refrigeration Topical antibiotic may be applied to prevent bacterial colonization, especially gramnegative bacteriae
Films	Thin, elastic, transparent sheets of polyurethane or other synthetic semipermeable, self-adhesive, polymer dressing	Intravenous catheter sites Skin tears Split-thickness graft donor sites Laser resurfacing	Translucent, can inspect the wound without removing the dressing Permeable to water vapor Can be left on the wound for days Tends to reduce postoperative pain Creates bacterial barrier	Difficult to position properly May adhere to wound as it dries No mechanical protection for the wound Possible exudate accumulation; not suitable for exudative wounds Nonabsorbent	TEGADERM	Can be used as a 'splint' to hold a thin split-thickness graft stiff as it is being harvested from the donor site
Foams	Normally contain hydrophilic polyurethane or silicone foam	Highly exudative wounds Dermabrasion Burns Laser resurfacing	Absorbent Permeable to water vapor Conforms to wound shape Thermally insulates Increases comfort	Opaque Cannot be used on dry wounds Possible undesirable drying effect on inadequately exudative wounds Needs to be frequently changed, almost daily	MEPILEX, ALLEWYN	Silicone-based rubber foams, known as silastic foams can be used for packing cavities or deep ulcers, such as pilonidal sinuses
Hydrofiber	Resemble alginates, are not occlusive and are more absorbent than standard hydrocolloid dressings	Highly exudative wounds Diabetic leg ulcers Burns Surgical wounds cavities Graft donor sites	Highly absorbent, 3 times more than alginates Anti-inflammatory properties Antimicrobial properties Reduces odor formation Reduced wear and tear	Requires secondary dressings Can cause maceration	ACQUACEL	Need secondary dressing

JAYPEE BROTHERS



Figs. 4.1A to F: Alginate dressings used effectively in nonhealing leg ulcers.

JAYPEE BROTHERS

nanocrystalline silver. Examples of nanocrystalline silver dressings include Acticoat™, Actisorb®, etc. Similarly povidone-iodine which has been used as an antiseptic, has been shown to inhibit wound healing, but the newer formulations release iodine at such low rates that it has not been found to be cytotoxic on the keratinocytes.[7,9-11]

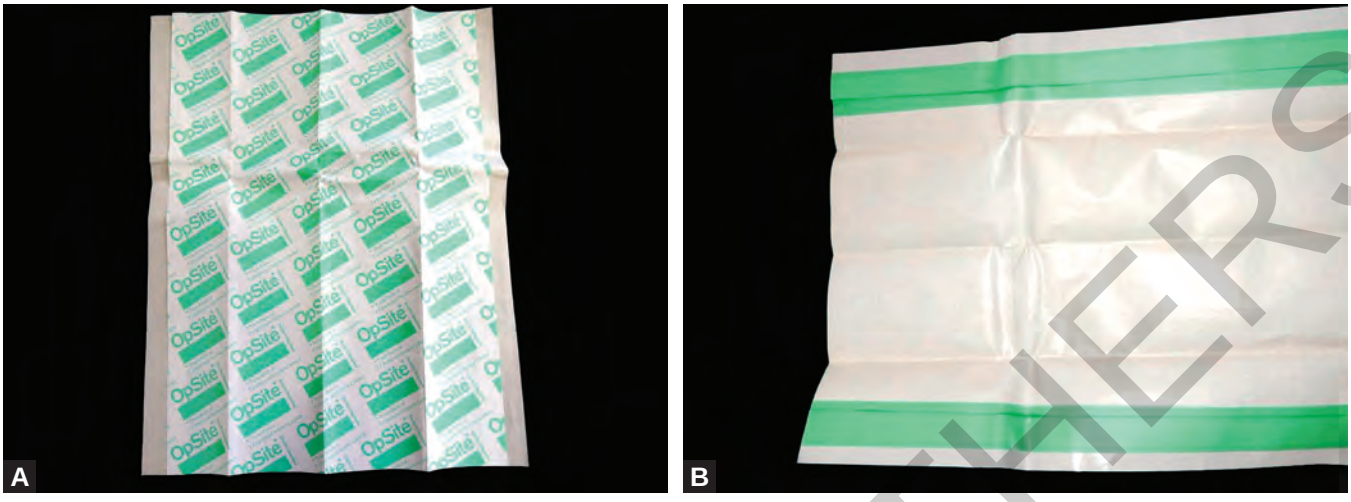

Figs. 4.2A and B: Film dressings.



Figs. 4.3A and B: Composite dressing with a pad and a film.

Composite Dressings

With the changing times and increasing demands, newer designs of occlusive/semiocclusive dressings have emerged. Composite dressings which incorporate 2 or more types of occlusive dressings are now in vogue; they typically have three layers. These are:

- A contact layer that is semi or nonadherent (hydrogel/hydrocolloid/alginate/foam)
- An absorptive layer
- An outer layer with an adhesive border like a film. (e.g. Lukomed Tplus®, Figs. 4.3A and B).

They are more waterproof and eliminate the need for a secondary retention dressing. There are also composite dressings which combine the advantage of an occlusive/semiocclusive dressing and an antimicrobial dressing like silver- based dressings (e.g. ACQUACEL Ag).

Tissue Engineered Skin–Equivalents

There are three types of tissue engineered skin -equivalents: epidermal grafts, dermal replacements, and composite grafts (with both epidermal and dermal component).

Epidermal grafts: Autologous keratinocytes obtained from the skin biopsy specimen of the patients are co-cultured with irradiated murine fibroblasts that serve as a feeder layer. A sheet of keratinocytes that is two to eight cells thick is formed and is attached to petroleum gauze. The graft must

JAYPEE BROTHERS

be sutured into place and the gauze backing is removed after 1 week, when the keratinocytes have attached to the wound. The commercially available product in the United States of America is Epicel®. There are additional epidermal grafts available outside of the US, such as Laserskin® and Celaderm™.[12,13]

Dermal replacements: Major component is collagen; occasionally, extracellular matrix, fibroblasts and basement membrane material are added. Can be xenogenic or allogenic. The goal is to provide a temporary biologic dressing to stimulate the process of healing.[14-16]

Composite grafts: Apligraf is a bi-layered human skin equivalent that is derived from the neonatal foreskin. Consists of keratinocytes with epidermal and dermal skin equivalents. The graft can repair itself, if wounded.[7,14]

CHOOSING A SUITABLE DRESSING[17]

Dressings in Dermatosurgery (How are they Used and Applied?)

General Measures while Applying/ Changing Dressings

- Hand hygiene must be practised before and after the dressing change.
- The tape or adhesive portion of the previous dressing if present is removed by pulling it parallel to the skin surface and in the direction of hair growth. Alcohol wipes or nonirritating solvents help in removing the adhesive quickly and painlessly.
- The old dressing is removed and placed in the appropriate biomedical waste disposal bin. A dressing should never be handled by an ungloved hand for the risk of transmitting pathogenic organisms.
- Clean the wound area with saline or antimicrobial solution; look for any signs of infection. Should keep in mind that with occlusive dressings like hydrocolloids or alginates, a brownish material may be seen on the wound surface, which is not pus.
- Apply the dressing; in case of modern dressings, keep in such a way that the sticky side of the dressing which adheres to the paper sticks to the wound.
- If a tape is used to secure the dressing, the correct way to use it is by placing the tape at the center of the dressing and pressing the tape down on both sides, applying tension evenly away from midline.
- An elastic adhesive bandage may be used to hold the dressings in place on mobile areas, or where pressure is required.

Dressings for Surgical Incision Wounds

Following a wound created by a surgical procedure, like an excision biopsy, sutures are usually placed to achieve hemostasis, better cosmesis, reduce risk of infection and better healing. In such a case, the wound heals by first intention. However, on some occasions, it may not be advantageous to close the wound in this way owing to the presence of a persistent source of infection, or if the wound is too small or some other reason. In these situations, the wound will be being encouraged to heal from the base upwards by the use of appropriate dressings that promote healing by secondary intention.

- An antibiotic ointment may be applied over the suture site, which will prevent infection and prevent the contact layer of the dressing from sticking to the sutures or the wound.
- It is generally considered best practice to cover all surgical incisions postprocedure and, when practical, this should involve low adherence, transparent polyurethane dressings, which protect the wound and give the opportunity to check the surgical incision site for any signs of wound infection without having to disturb the dressing itself. These dressings can be left in place for between 3 to 5 days, during which time the epithelialization process may be completed. If the procedure is a minor one such as a skin biopsy, the dressing may be dispensed with after a day or two; thereafter, the layer of antibiotic may be sufficient.
- If oozing of fluid (blood or exudate) from the incision site is anticipated in the immediate postoperative phase, dressings should incorporate an integral central pad of absorbent material (island dressings). These island dressings combine the advantages of transparent low-adherent polyurethane film dressings while also having the ability to absorb small amounts of exudate, aiding the normal debridement process in the wound and help to prevent any adverse effect on healing.
- After suture removal, tapes may be used as external splints; e.g. Steri-strips-(Figs. 4.4A to D) as they support the tissue, enable collagen remodelling and minimize the risk of hypertrophic scar formation.
- Conventional dressings (pressure or nonpressure dressings) may also be considered in surgical wounds that heal by first intention.

JAYPEE BROTHERS

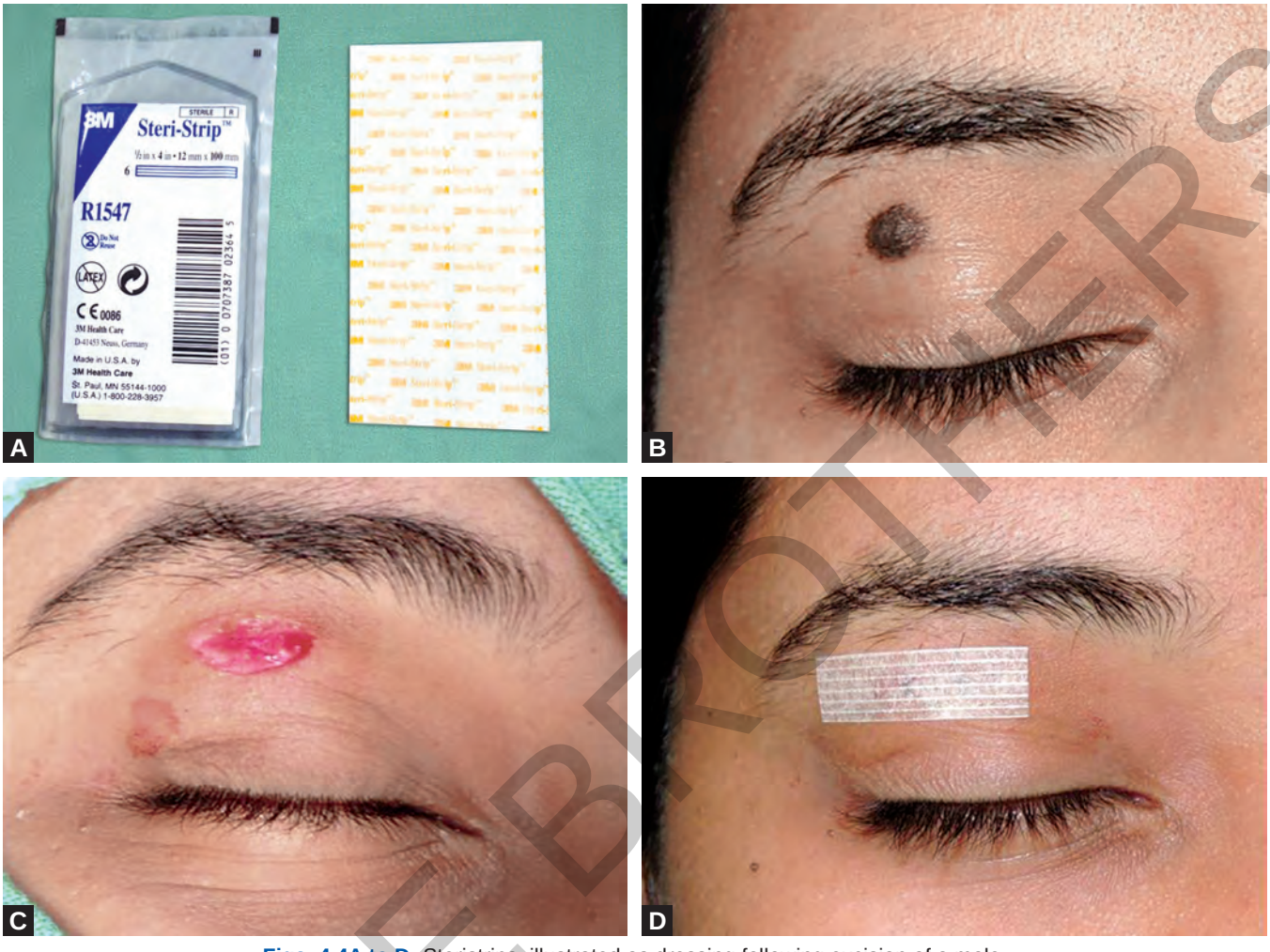

Figs. 4.4A to D: Steristrips, illustrated as dressing following excision of a mole.

Leg Ulcers

In more than 80% cases of leg ulcers, the etiology is venous insufficiency. In venous ulcers, moisture retention can be best achieved by occlusive dressings; but studies have not demonstrated the superiority of one category over the other. Therefore, the choice of the occlusive dressing depends on the practitioner's and the patient's preference. However, simple nonadherent dressings are generally recommended in the management of venous leg ulcers. Honey dressings, silver dressings or the routine use of topical antiseptics or antimicrobials are not recommended in the routine treatment of patients with venous leg ulcers.[18-20]

Compression is thought to be of utmost importance in the management of venous ulcers. Patients should be offered the strongest compression that maintains patient concordance. An ankle pressure of 30 to 40 mm Hg should be achieved to reduce edema, prevent capillary leakage and thereby improve healing rates of ulcers. At initiation of compression, patients should be assessed for skin complications within 24 to 48 hours. In patients with an ABPI < 0.8, and in patients with diabetes, compression should only be used under specialist advice and with close monitoring.[18-20]

Compression can be achieved by dressings, usually layered pressure dressings. With graduated compression stockings, the patient can independently wear it, provided they are able and healthy. Besides compression stockings, single layer and multilayered compression bandages are also available. Combining compression with occlusive dressings has been found to augment the healing rates of venous ulcers.

The Unna boot is a type of compression bandage which has been used for many years in the treatment of stasis ulcers. It was originally a cotton bandage

JAYPEE BROTHERS

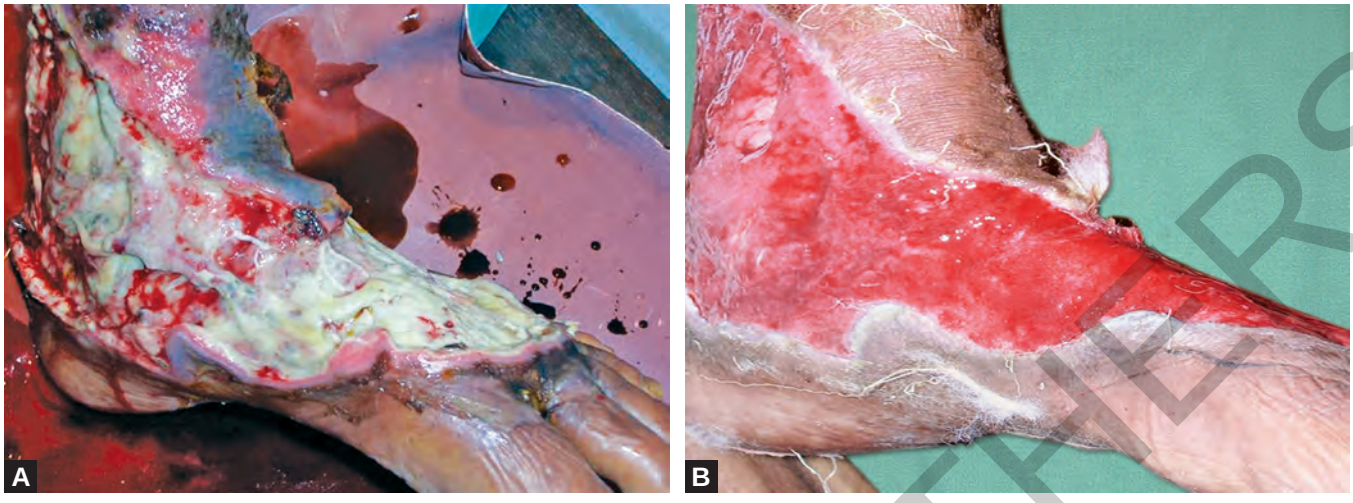

Figs. 4.5A and B: Enzymatic debridement using Papain, collagenase dressings. The photograph is before and after 10 days of papain dressing.

impregnated with zinc oxide, gelatin and glycerin paste. Applied in a semirigid state, Unna boot confers the dual advantage of compression along with the moisture retentive properties of an occlusive dressing. It should be applied by qualified medical personnel and changed at least weekly. Nowadays, flexible compression bandages are more preferred (when compared to the rigid nature of Unna's boot). They come in different varieties—elastic/inelastic, single/multilayered, long- or short-stretch compression, etc. The major concern is in identifying how much tension is needed while prescribing elastic compression bandages.[7]

The authors have used papain dressings and amniotic membrane dressings to good effect in leg ulcers (Figs. 4.5 and 4.6).

Pressure Sores

Overall, the quality of clinical evidence for wound dressings was found to be low to very low in most of the meta-analyses. No recommendations could be made about using specific types of dressings, except that gauze dressings should not be used for pressure ulcers. The NICE guideline development group emphasized that the effectiveness of each dressing would depend on the type of pressure ulcer and, therefore, chose to recommend a dressing that promotes the optimum healing environment, rather than a specific type of dressing. NICE advises that clinicians should discuss the type of dressing with the person with the pressure ulcer and, if appropriate, their family or caretakers, taking into account the person's pain and tolerance, the position of the ulcer, the amount of exudate and the frequency of dressing change. A dressing that promotes a warm, moist wound healing environment should be considered for grade 2, 3 and 4 pressure ulcers.[18]

A Cochrane data analysis found that hydrocolloid, film and foam dressings were found to prevent pressure ulcers compared with standard care. However, the authors also noted that dressings do not replace best practices, such as turning and repositioning, skin care, good nutrition and continence management.[21]

Vitiligo Surgery

Surgeries have become an indispensible tool in the current management of vitiligo. Procedures ranging from tissue grafts to cellular techniques have revolutionized the therapeutic options. Cosmetic outcome can be greatly improved if the right dressing can be applied in the right method during the surgery.

It is important to secure the grafts on the recipient area while carrying out miniature punch grafting. Dressings do have a significant role in proper immobilization and in securing the grafts. Various surgical adhesives like octyl cyanoacrylate, flexible collodion, etc., have been used in miniature punch grafting.

Cyanoacrylate tissue glue (Fig. 4.7) is helpful in providing quick and effective immobilization of donor grafts and securing grafts over areas that are difficult to treat, like the genitalia, groin, eyelids, palms, and fingertips.[22] The tiny droplets of octyl cyanoacrylate are expressed from

JAYPEE BROTHERS



Figs. 4.6A to C: Amniotic membrane in ulcer treatment as dressings.



Fig. 4.7: Cyanoacrylate tissue glue.

the needle tip; broken further into even smaller droplets by taking it on another sterile needle tip, and applied only at four points, at 12, 3, 6 and 9 o'clock positions between the edges of the donor grafts and the recipient wells. The adhesion between the graft and the recipient wells start within 10 seconds and is complete within 1 minute of application. No dressing or immobilization is required in any patients. Apart from the adhesive property, octyl cyanoacrylate also exhibits antimicrobial properties against staphylococci, *Pseudomonas*, and *E. coli*.[23]

Alternatively, paraffin embedded nonadherent sterile gauze (Jelonet®) can be applied as a primary dressing followed by surgical pad and elastic adhesive dressings to immobilize the area (Fig. 4.8).

In split thickness grafting and suction blister grafting, octyl cyanoacrylate gel can be used to secure the graft in position in place of sutures (Figs. 4.9A and B). Adhesive film

JAYPEE BROTHERS

dressings like Opsite® can be used as secondary dressings over the recipient site. Opsite is a transparent, adhesive film. The film is moisture vapor permeable, conformable and extensible which is widely used to provide a moist wound environment for superficial wounds. Opsite provides moisture vapor permeability, allowing the excess exudate to evaporate, helping to prevent skin maceration. The grafts can also be placed in position using sutures or without sutures and further dressed with absorbent pads and hydrofilm dressings. Lukomed T plus® is a film dressing with absorbent pad which can be directly applied over a grafted site.

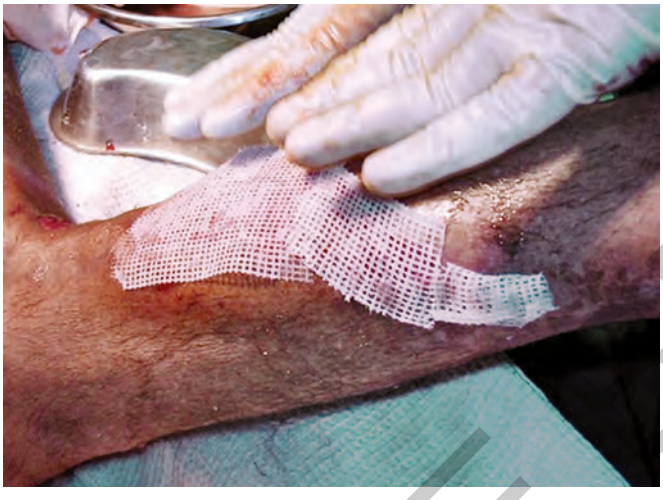

Fig. 4.8: Paraffin embedded nonadherent sterile gauze (Jelonet®) can be applied as a primary dressing in miniature punch grafting.

In cellular grafting techniques, primary dressing is done using collagen dressings. After applying the basal layer cell suspension, collagen sheets are used as primary covers to create a biological environment (Fig. 4.10). Alternatively, amniotic membrane can also be used (Figs. 4.11A and B). Mepitel dressing is also used in places where collagen sheets are not available (Figs. 4.12A and B). This is then covered with a sterile pad and finally with Tegaderm (3M) dressing.

Nail Surgeries

In nail surgery, the postoperative dressings must have these properties: nonadherent, absorbent, perfectly fixed and with adequate pressure to prevent bleeding.

Application of an antiseptic ointment covered with a paraffin embedded nonadherent sterile gauze (Jelonet®, Bactigrass®, Sofratulle®) as a first layer will protect the wound from drying and will allow easy and painless removal. Mepitel® is another nonabsorbent, porous, semitransparent flexible poyamide net, silicon- coated dressing useful as a primary dressing in nail surgeries and cellular grafting surgeries in vitiligo.

Second layer of dressing is made of 3 or 4 layers of absorbent mesh gauze that will absorb exudates and bleed and provide protection against trauma. Secure final layer of dressing can be made of elastic adherent plasters such as elastoplast, which will keep the surgical area secure and exert sufficient pressure so as postoperative bleeding can be prevented. Care should be taken to leave the tip of the toes and fingers uncovered so as to inspect for cyanosis if the dressing is too tight.



Figs. 4.9A and B: Tissue glue for securing grafts in SBEG, ultrathin epidermal grafting—applied over the periphery of grafts to secure them in place.

JAYPEE BROTHERS



Fig. 4.10: Collagen dressings used as primary dressings in cellular grafts in vitiligo surgery.

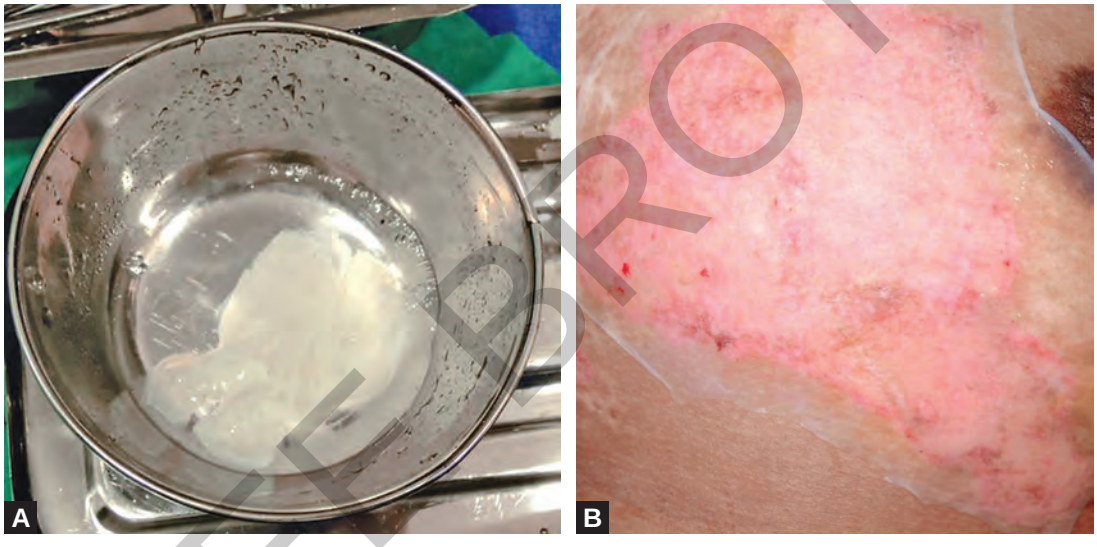

Figs. 4.11A and B: Amniotic membrane dressings in vitligo surgery.



Figs. 4.12A and B: Mepitel dressings.

JAYPEE BROTHERS

Recently, authors have found a new self-adhesive bandage without any chemical adhesive namely Coban® to be very effective in nail surgeries. The advantage being nonallergic and can be easily reapplied if the patient feels the dressing too tight without disturbing the inner layers of the dressing. It is a stretchable and self-adhesive dressing suitable for pressure dressings and also provides effective hemostasis (Figs. 4.13A to D).

Dressing Removal and Replacement in Nail Surgery

If the wound is clean and there is no bleeding on the first inspection, pressure dressings are not required further. Bertrand Richert suggested a simple dressing which provides protection to the toes and the surgical wound.[24] We found this method useful in our practice. This will also cover the tip of the toe and protect. A large porous plaster, half split into four on its length will cover easily a great toe or a finger (Figs. 4.14A to E).



Figs. 4.13 A to D: Coban® dressings in nail surgeries.

Hair Transplant

A pressure dressing may be given on the donor area after a hair transplant surgery. The recipient area is generally left uncovered with the newer techniques, but sometimes a nonadherent dressing may be given depending on the preference of the surgeon. The patient is called back the next day for inspection of the surgical site.

Liposuction

Absorbent dressings are generally given on the incision sites to facilitate drainage. Patients are also required to wear compression garments in the postoperative period.

Laser Surgery

The primary goal after laser resurfacing is total and uniform re-epithelialization. In the absence of infection and with the use of occlusive dressings, this is possible within 5 to 7 days. Delay in re-epithelialization has been attributed to crust formation, to which the wound is most prone during the first 2 to 3 postoperative days. The dressings may be open or closed. By open, we mean that the wound is left alone after applying a cream or ointment without covering it. The application is repeated in frequent intervals. Whereas by closed dressings, any of the 4 categories of occlusive dressings (except alginates and hydrofibers) may be used. Studies have shown that postlaser procedure, closed/occlusive dressings fared better in terms of re-epithelialization and patient comfort, when compared to open dressings. Foam dressings and hydrogel/hydrocolloid dressings are widely used postprocedure. In significant postlaser resurfacing wounds, the protocol recommended is— the dressing is placed immediately after the procedure and then the patient is called for review on postoperative day 1 and 2, when the wound is cleansed and the dressing is changed. The replacement dressing remains in place till day 5, when the dressing is changed to an open dressing.[7,25] But in most cases especially for laser done over face, e.g. acne scars, closed dressing is cosmetically less acceptable.

COMPLICATIONS OF WOUND DRESSINGS

- Maceration of the skin surrounding a wound may occur, if a dressing with a low absorptive capacity is used on a heavily exuding wound.

JAYPEE BROTHERS



Figs. 4.14 A to E: Nail dressing to provide protection to the wounds and the toes.

- If the dressing is highly absorptive, then more frequent dressing changes may be needed, in addition to investigation and management of the cause of the exudate (such as infection).
- Conversely, use of a highly absorptive dressing on a dry wound may lead to disruption of healthy tissue on the wound surface and cause pain when removed.

JAYPEE BROTHERS

- Iodine containing dressings should not be used in young children, pregnant or lactating women, or patients with known or suspected iodine sensitivity. As iodine is absorbed, caution must be taken when using these dressings in large wounds, wound with cavities, patients with a history of thyroid disease.
- Gauze dressings should not be used on pressure sores.

TIPS AND TRICKS

- To avoid the formation of bubbles/air pockets while applying dressings like films; the caregiver may use the proximal end of the thumb forceps and move it from one side to the other end of the dressing (like applying butter with a knife).
- The skin surrounding a highly exuding wound may be further protected through the use of emollients (such as 50:50 mix of white soft paraffin and liquid paraffin) or the application of barrier films.
- Hydrogel dressings have two removable thin sheets of polyethylene film, with some types containing a supportive inner gel mesh. For application to the wound, the film on the contact side is removed, leaving the outer film in place. With this mode of application, the dressing is semipermeable to gases and water vapor. If the outer film is also removed, then the dressing becomes permeable to fluid too; exudate can pass to a secondary gauze dressing. They are particularly useful in cosmetic procedures like chemical peels, laser resurfacing, dermabrasion, etc.

REFERENCES

1. Hayward PG, Morrison WA. Current concepts in wound dressings. Aust Prescr. 1996;19:11-3.
2. Gilje O. On taping (adhesive tape treatment) of leg ulcers. Acta Derm Venereol. 1948;28:454-67.
3. Winter GD. Formation of the scab and the rate of epithelialization of superficial wounds in the skin of the young domestic pig. Nature. 1962;193:293-4.
4. Eaglstein WH, Davis SC, Mehle AL, Mertz PM. Optimal use of an occlusive dressing to enhance healing. Effect of delayed application and early removal on wound healing. Arch Dermatol. 1988;124:392-5.
5. Li W, Dasgeb B, Phillips T, et al. Wound-healing perspectives. Dermatol Clin. 2005;23:181-92.
6. Jones V, Grey JE, and Harding KG. Wound dressings. BMJ 2006;332:777-80.
7. Menaker GM, Mehlis SL, Kasprowicz S. Dressings. In: Bolognia J, Jorizzo JL, Schaffer, JV (Eds). Dermatology. Philadelphia: Elsevier Saunders. 2012.
8. Matthews DN. Dressing of open wounds and burns with tulle gras. Lancet. 1941;237(6124):43–4.
9. Carter MJ, Tingley-Kelley K, Warriner RA 3rd. Silver treatments and silver-impregnated dressings for the healing of leg wounds and ulcers: a systematic review and meta-analysis. J Am Acad Dermatol. 2010;63:668-79.
10. Cooper RA. Iodine revisited. Int Wound J. 2007;4:124-37.
11. Hansson C. The effects of cadexomer iodine paste in the treatment of venous leg ulcers compared with hydrocolloid dressing and paraffin gauze dressing. Cadexomer Iodine Study Group. Int J Dermatol.1998;37:390-6.
12. Carsin H, Ainaud P, Le Bever H, et al. Cultured epithelial autografts in extensive burn coverage of severely traumatized patients: a five year single center experience with 30 patients. Burns. 2000;26:379-87.
13. Lobmann R, Pittasch D, Muhlen I, Lehnert H. Autologous human keratinocytes cultured on membranes composed of benzyl ester of hyaluronic acid for grafting in nonhealing diabetic foot lesions: a pilot study. J Diabetes Complications. 2003;17:199-204.
14. Bello YM, Falabella AF. Use of skin substitutes in dermatology. Dermatol Clin. 2001;19:555-61.
15. Smith DJ. Use of Biobrane in wound management. J Burn Care Rehabil. 1995;16(3 Pt 1):317-20.
16. Davis DA, Arpey CJ. Porcine heterografts in dermatologic surgery and reconstruction. Dermatol Surg. 2000;26:76-80.
17. British National Formulary (2015) BNF 70 September 2015-March 2016. Appendix 4; 1294-1319. BNF Group, London.
18. Chronic wounds: advanced wound dressings and antimicrobial dressings. NICE Guidelines. March 2016.
19. Agency for Healthcare Research and Quality (2014) Chronic venous ulcers: a comparative effectiveness review of treatment modalities. Comparative Effectiveness Review 127.
20. Scottish Intercollegiate Guidelines Network (2010) Management of chronic venous leg ulcers. SIGN Guideline 120.
21. Huang L, Woo KY, Liu LB, et al. Dressings for preventing pressure ulcers: a meta-analysis. Adv Skin Wound Care. 2015; 28:267-73.
22. Ghorpade A. Use of tissue glue for punch grafting in vitiligo—A preliminary report. Indian J Dermatol Venereol Leprol 2004;70:159-61.
23. Toriumi DM, O'Grady K, Desai D, Bagal A. Use of octyl-2-cyanoacrylate for skin closure in facial plastic surgery. Plast Reconstr Surg. 1998;102:2209-19.
24. Richert B,Di Chiacchio N, Haneke E. Nail Surgery ed 2011. 16-21, Informa healthcare UK.
25. Weinstein C, Ramirez O, Pozner J. Postoperative care following carbon dioxide laser resurfacing. Avoiding pitfalls. Dermatol Surg. 1998;24:51-6.

JAYPEE BROTHERS

for detailed information on dermatology books, visit our website **www.jaypeebrothers.com,** for detailed information on dermatology books, visit our website **www**

ACS(I) PROCEDURAL DERMATOSURGERY

A Step by Step Approach

This book is a dream project of the Association of Cutaneous Surgeons (India) [ACS(I)] Academy and involves the description of various surgical procedures in a step wise manner. It will contain the detailed steps involved in doing various dermatosurgical procedures accompanied by figures for each of the steps. This would help all budding and practicing dermatosurgeons to easily carry out these procedures just by reading and having a visual outlook of the respective surgeries.

The chapters are contributed by eminent dermatosurgeons, who are experts in their respective fields from all over the country. The book will be a ready reference for dermatologists, dermatosurgeons, dermatology residents and will also be a guide for other specialties when they encounter a dermatosurgery case.

Tips and tricks, modifications, complications and recent advances will be highlighted for each procedure. The chapters will be concise and have been made crisper by addition of tables, flowcharts and algorithms.



Dr (Lt Col) Biju Vasudevan MD FRGUHS (Dermatosurgery) from Armed Forces Medical College (AFMC), Pune has served the Indian Armed Forces for the past 18 years. He is presently Professor at Base Hospital Lucknow, Lucknow has a fellowship in Dermatosurgery from Bangalore Medical College and Research Institute (BMCRI), Rajiv Gandhi University of Health Sciences (RGUHS), Bengaluru and is a recognized postgraduate examiner of Maharashtra University of Health Sciences (MUHS), Nashik and West Bengal University, Kolkata. He has 84 indexed publications (14 international), 30 chapters in various books and is the Editor of the IADVL Color Atlas of Dermatology and Clinical Correlations in Dermatology. He has conducted 24 International/National/State level quizzes, is on the editorial board of 4 journals and is a reviewer of 12 journals. He is presently the Deputy Editor of IJDVL. He has delivered about 70 guest lectures and conducted 8 workshops in various conferences. He has been the past Joint Secretary of IADVL and his interests in dermatosurgery include hair transplantation, vitiligo surgery and flaps and grafts.



Dr (Col) Manas Chatterjee MD graduated from Armed Forces Medical College (AFMC), Pune in 1990 with Distinction and OP Malhotra Gold Medal in Medicine. He completed his MD from the same institution and Diplomate of National Board thereafter. He has served the Indian Armed Forces since the past 25 years, earning the Chief of Army Staff Commendation for distinguished service. He is presently Senior Adviser, Professor and Head, Department of Dermatology of INHS Asvini, Mumbai. He is postgraduate examiner at 6 universities in India.

He is past President of Association of Cutaneous Surgeons (India) [ACS(I)], Joint Secretary of the IADVL and Chairman of the IADVL Academy of Dermatology. He is the worldwide pioneer of eyelash transplantation for vitiligo with eyelash leucotrichia and Co-founder of the ACSI Dermatosurgery Registry. He has conducted multiple dermatosurgery workshops and is an accomplished quizmaster in Dermatology and Dermatosurgery. He is the Associate Editor of IJDVL, has been Editorial Board Member, Associate and Section Editor of 7 journals and has been invited as guest speaker more than 150 times in India and abroad and has more than 50 indexed publications and chapters in 10 textbooks to his credit in addition to being editor of Compendium of Pigmentary Disorders. He is the winner of several fellowships, scholarships and research grants in his specialty and has been involved in the design and conduct of 5 multicentric trials in his specialty. His interests include dermatosurgery, pigmentary disorders and photography in dermatology.



Dr Shilpa K MD FRGUHS (Dermatosurgery) from Bangalore Medical College, Bengaluru, is presently working as Assistant Professor at Bangalore Medical College and Research Institute (BMCRI), Bengaluru. She has a fellowship in Dermatosurgery (FRGUHS) from Rajiv Gandhi University of Health Sciences (RGUHS), Bengaluru and is a recognized postgraduate teacher of Rajiv Gandhi University. She has around 20 indexed publications, 15 chapters in various books and is the Assistant Editor of the IADVL textbook of Dermatology and Co-editor of snapshots in dermatology. She has delivered many guest lectures and is part of workshops in various conferences. Her fields of interest include clinical dermatology, dermatosurgery and trichology.

Available at all medical bookstores
or buy online at www.jaypeebrothers.com

JAYPEE BROTHERS
Medical Publishers (P) Ltd.
www.jaypeebrothers.com

Join us on facebook.com/JaypeeMedicalPublishers

Shelving Recommendation
DERMATOLOGY

ISBN 978-93-5270-212-1