information on cardiology books, visit our website www.ejaypee.com, for detailed information on cardiology books, visit our website www.ejaypee.com

Get Full Access
with added features at
emedicine360.com



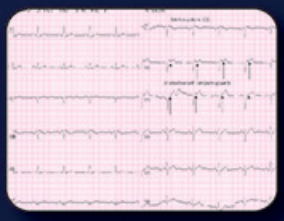

Textbook of Basic and Advanced Electrocardiography



Baren Chakraborty

JAYPEE

Contents

Chapter 1. Electrocardiogram: The Basics 1

- Parts of the Electrical System 3
- Waves of the Electrocardiogram 3
- Electrocardiogram Representation of Systole and Diastole 3
- Electrocardiogram Tracing 4

Chapter 2. Electrocardiogram Lead Placement and Standardization 5

- Electrode Placement 7
- Limb Leads 7
- Augmented Limb Leads 8
- Precordial (Chest) Leads 8
- Standardization of Voltage and Timing Intervals 9

Chapter 3. Interpretation and Identification of Different Waves in Electrocardiogram and Calculation of Heart Rate 13

- P Wave 14
  - » Characteristics of Normal P Wave 16
- PR Interval 16
  - » Causes of Prolonged PR interval 17
  - » Causes of Short PR interval 17
- PR Segment 17
- QRS Complex 18
- J-Point 19
- ST Segment 19
  - » Common Causes of ST Segment Elevation 19
  - » Less Common Causes of ST Segment Elevation 20
  - » Rare Causes of ST Segment Elevation 20
  - » Common Causes of ST Segment Depression 20
  - » Uncommon Causes of ST Segment Depression 21
- T Wave 22
  - » Patterns of Different "T" Waves 23
  - » Causes of T Wave Inversion 24
- QT interval 27
  - » Causes of Prolonged QT_c 29
  - » Drugs Causing QT Prolongation 30
  - » Causes of Short QT_c 31
- U Wave 32
  - » Causes of Prominent U Waves 32
- TP Segment 32
- Calculation of Heart Rate 32
- Sinus Bradycardia 34
- Sinus Tachycardia 35

Chapter 4. Axis Determination and Rotation of the Heart **39**

- Normal and Abnormal Axis on Electrocardiogram 41
- Axis Determination from QRS Configuration in LI, LII, and LIII 41
- Axis Calculation from Lead I and aVF 41
- Rotation of Heart 43
- Interpretation of QRS Axis 45
- Axis Determination by Isoelectric (Equiphasic) Lead Method 45
- Quick and Easy Determination of Electrocardiogram Axis 45

Chapter 5. Normal Variant Electrocardiogram **55**

- Sinus Arrhythmia 55
- Inverted P Waves 55
- PR Interval Variation 55
- QRS Duration: Bundle Branch Block Pattern 55
- Axis Deviation 58
- Q-Wave Abnormality 58
- Early Repolarization Pattern 58
- Nonspecific T-Wave Inversion 61
- Persistent Juvenile Pattern 64
- Wandering Pacemaker 64
- Tall R in V1 64

Chapter 6. Chamber Enlargement **68**

- Electrocardiographic Criteria for the Diagnosis of Left Ventricular Hypertrophy 68
  - » Increased QRS Amplitude (Voltage Criteria) 68
  - » Delayed Intrinsicoid Deflection (Increased Ventricular Activation Time) 70
  - » Widened QRS/T Angle 70
  - » Left Axis Deviation 70
  - » Secondary ST-T Abnormalities 70
  - » Left Atrial Abnormalities 73
- Diagnostic Criteria of Left Ventricular Hypertrophy Based on QRS Voltage 73
  - » Factors Influencing QRS Voltage 74
  - » Sokolow–Lyon Criteria 74
  - » Cornell Criteria to Detect Left Ventricular Hypertrophy 75
  - » Romhilt–Estes Score 75
  - » Perugia Score 75
  - » Framingham Electrocardiographic Score and Other System 75
  - » Left Ventricular Strain Pattern 76
  - » Differentiation Between Left Ventricular Hypertrophy with Strain and Ischemia 76
  - » Diagnosis of Left Ventricular Hypertrophy in the Presence of Left Bundle Branch Block 77
  - » Electrocardiographic Diagnosis of Left Ventricular Hypertrophy in Presence of Right Bundle Branch Block 77
  - » Left Ventricular Hypertrophy in Presence of Left Anterior Fascicular Block 77
  - » Left Ventricular Hypertrophy Pressure Versus Volume Overload 78

- Right Ventricular Hypertrophy 79
- Biventricular Hypertrophy 82
  - » Katz–Wachtel Sign 83
- Atrial Abnormalities 84
  - » Left Atrial Abnormality/Enlargement 84
  - » Right Atrial Abnormality/Enlargement 85
  - » Pseudo-P Pulmonale 85
  - » Biatrial Abnormality/Enlargement 85

Chapter 7. Myocardial Ischemia 98

- ECG Features of Stable Angina 98
- ECG Features of Acute Coronary Syndromes 98
- ST-Segment Depression 99
  - » Causes of ST Depression 99
  - » Patterns of ST-Segment Depression 99
  - » Primary and Secondary ST Depression 100
  - » Reciprocal ST-Segment Depression 103
- True Posterior ST-Segment Elevation Myocardial Infarction 104
- Wellens' Syndrome 104
- Nonspecific ST- and T-Wave Changes 104
- Diffuse ST-Segment Depression 108
- Prinzmetal Angina 111
- MINOCA (Myocardial Infarction with Nonobstructive Coronary Arteries) 112

Chapter 8. ECG Diagnosis of ST-Elevation Myocardial Infarction (STEMI) 117

- Hyperacute T Waves 117
- ST-Segment Elevation 119
  - » Causes of ST Elevation with Convexity Upward 121
  - » Causes of ST Elevation with Concavity Upward 121
  - » Causes of Saddle-Shaped ST Elevation in Leads V1–V3 121
- Appearance of Pathological Q-Waves 121
- T-Waves Inversion 122
- Normalization of the ST-Segment 122
- Significance of Reciprocal ST-Segment Depression in STEMI 125
- Localization of Site of Infarction 125
  - » ECG Criteria of Acute Anterior Myocardial Infarction 126
  - » ECG Criteria of Acute Inferior Myocardial Infarction 127
  - » ECG Criteria of Right Ventricular Infarction 129
  - » ECG Criteria of Posterior Infarction 131
- High Lateral ST-Elevation Myocardial Infarction 131
- Tombstone ST Elevation 134
- Diagnosis of ST-Elevation Myocardial Infarction in Presence of Bundle-Branch Block 134
  - » ECG Diagnosis of ST-Elevation Myocardial Infarction in Presence of Left Bundle-Branch Block 134
  - » Sgarbossa Scoring System for Diagnosis of ST-Elevation Myocardial Infarction in Presence of Left Bundle Branch Block 136
  - » ECG Diagnosis of ST-Elevation Myocardial Infarction in Presence of Right Bundle Branch Block 138
- Differential Diagnosis of ST-Segment Elevation 138

- Causes of ST-Segment Elevation Other Than ST-Elevation Myocardial Infarction 138
- Identification of the Exact Site of the Infarct-Related Artery 140
  - » ECG Criteria of Left Main Coronary Artery Occlusion 140
  - » ECG Criteria of Left Anterior Descending Artery Occlusion 141
  - » ECG Signs of Different Sites of Left Anterior Descending Artery Occlusion in the Context of Anterior ST-Elevation Myocardial Infarction 142
  - » Electrocardiogram Criteria of Left Circumflex Artery Occlusion 143
  - » ECG Criteria of Right Coronary Artery Occlusion 143
  - » de Winter's T Wave 143
  - » ECG Distinction Between Right Coronary Artery Versus Left Circumflex Coronary Artery Related Acute Inferior Myocardial Infarction 145
- Atrial Infarction 149
- Arrhythmias and Conduction Disturbances in the Acute Phase of STEMI 150
- ECG Evidence of Prior Myocardial Infarction 151
- Poor R-Wave Progression 151
- Significance of Persistently Elevated ST Segment After STEMI 151

Chapter 9. Electrocardiogram Documentation of Reperfusion in ST-Elevation Myocardial Infarction 161

- Electrocardiogram Assessment of Resolution of ST Elevation 164
  - » Sum ST-Segment Resolution 164
  - » Single-Lead ST-Segment Resolution 164
  - » Max ST-Segment Elevation 164
- Appearance of Early T-Wave inversion 166
- Arrhythmias Following ST Elevation Myocardial Infarction 168
- Resolution of ST-Segment Depression 169
- ECG Criteria of Successful Reperfusion 170
- Calculation of ST-Segment Change 170

Chapter 10. Ectopic and Escape Beats 172

- Premature Atrial Complex 173
- Premature Junctional Complex 176
- Premature Ventricular Complex 176
  - » Electrocardiogram Criteria for Diagnosis of Premature Ventricular Complex 178
  - » Causes of Premature Ventricular Contraction 181
- R-On-T Phenomenon 182
- Interpolated Beat 182
- Parasystole 183
- Differentiation Between Aberrant Ventricular Conduction and Premature Ventricular Complex 186
- Escape Beats 190
- Differences Between Premature Atrial Complex and Premature Ventricular Complex 193
- Differences Between Ectopic Beat and Escape Beat 193

Chapter 11. Narrow Complex Tachycardia 195

- Sinus Tachycardia 195
- Sinus Node Reentrant Tachycardia 196
- Multifocal Atrial Tachycardia 196

- Atrial Fibrillation 197
  - » Mechanisms of Atrial Fibrillation 197
  - » Causes of Atrial Fibrillation 197
  - » Classification of Atrial Fibrillation Based on the Temporal Pattern of the Arrhythmia 199
  - » Lone Atrial Fibrillation 201
- Atrial Flutter 202
- Paroxysmal Supraventricular Tachycardia 206
- Atrioventricular Nodal Reentrant Tachycardia (AVNRT) 207
  - » Types of Atrioventricular Nodal Reentrant Tachycardia 208
  - » ECG Characteristics of Atrioventricular Nodal Reentrant Tachycardia 208
- Atrioventricular Reentrant Tachycardia (AVRT) 209
  - » ECG Difference Between Atrioventricular Nodal Reentrant Tachycardia and Atrioventricular Reentrant Tachycardia 210
- Atrial Tachycardia 211

Chapter 12. Broad Complex Tachycardia 217

- Causes of Broad Complex Tachycardia 217
- Ventricular Tachycardia 217
  - » Electrocardiogram Criteria of Ventricular Tachycardia 217
  - » Monomorphic Ventricular Tachycardia 220
  - » Polymorphic Ventricular Tachycardia 222
- Torsades de Pointes 222
- Ventricular Flutter 223
- Ventricular Fibrillation 224
- Fascicular Ventricular Tachycardia 225
- Right Ventricular Outflow Tract Tachycardia 226
- Bidirectional Ventricular Tachycardia 227
- Accelerated Idioventricular Rhythm 227
- Broad Complex Tachycardias of Supraventricular Origin 227
  - » Supraventricular Tachycardia with Aberrant Conduction 229
  - » Supraventricular Tachycardia with Accessory Pathway 229
- Broad Complex Tachycardias: Ventricular Tachycardia Versus Supraventricular Tachycardia with Aberrancy 229
- Fusion Beats 231
- Capture Beats 231
- Josephson's Sign 233
- Tachycardia QRS More Narrow Than Sinus QRS 233
- Newer Criteria to Differentiate Between Ventricular Tachycardia and Supraventricular Tachycardia with Aberrancy 233
  - » The Brugada Algorithm 235
  - » Vereckei "the AVR" Algorithm 236
  - » Griffith Algorithm 236
  - » The Bayesian Approach 236
  - » Ultra Simple Brugada Criterion: R Wave Peak Time 237

Chapter 13. Bundle-Branch Block 242

- Bundle-Branch Block: Basic Principles 242

- Types of Bundle-Branch Blocks 243
- Right Bundle Branch Block 244
  - » ECG Criteria of Complete Right Bundle Branch Block 244
  - » ECG Criteria of Incomplete Right Bundle Branch Block 245
- Left Bundle Branch Block 247
  - » ECG Criteria of Left Bundle Branch Block 249
- Hemiblock Concept 252
  - » Left Anterior Hemiblock (LAHB) 255
  - » Left Posterior Hemiblock (LPHB) 255
  - » Left Septal Hemiblock 255
- Bifascicular/Trifascicular Block 259
- Peri-infarction Block 265
- Nonspecific Intraventricular Conduction Disturbance 265

Chapter 14. Sick Sinus Syndrome 271

- Sinus Bradycardia 271
- Sinus Arrest 271
- Escape Rhythms 271
- Tachycardia-Bradycardia Syndrome 272
- Sinoatrial Exit Block 279

Chapter 15. Atrioventricular Block 282

- First-Degree Atrioventricular Block 282
  - » Electrocardiogram Criteria of First-Degree Heart Block 285
- Second-Degree Atrioventricular Block 285
  - » Mobitz Type I Second-Degree Atrioventricular Block (Wenckebach Phenomenon) 285
  - » Mobitz Type II Second-Degree Atrioventricular Block (Hay Phenomenon) 286
  - » Site of Block 286
  - » Vagally-Mediated Atrioventricular Block and Atrioventricular Block in Athletes 293
- Third-Degree Atrioventricular Block (Complete Heart Block) 294

Chapter 16. Electrocardiographic Diagnosis of Cardiac Channelopathies 307

- Brugada Syndrome 307
  - » Types of Brugada Pattern Electrocardiograms 308
  - » Electrocardiographic Criteria for the Diagnosis of Brugada Syndrome 308
  - » Electrocardiogram Differentiation: Brugada Syndrome/Pattern Versus Right Bundle Branch Block 310
- Long QT Syndrome 312
  - » Different Varieties of Inherited Long QT Syndrome 313
  - » Acquired Long QT Syndrome 313
  - » QT and QTc Interval 314
  - » T-Wave Morphology in Long QT Syndrome 315
  - » Arrhythmias in Long QT Syndrome 315
  - » Drugs Associated with QTc Prolongation 315
- Short QT Syndrome 317
- Catecholaminergic Polymorphic Ventricular Tachycardia 317

Chapter 17. Preexcitation Syndromes 325

- Types of Preexcitation Syndromes 326
- Wolff–Parkinson–White Syndrome 326
- Concealed Accessory Pathways 328
- Arrhythmias in Wolff-Parkinson-White Syndrome 328
- Diagnosis of Coronary Artery Disease in Presence of Wolff-Parkinson-White Syndrome 331
- Localization of the Accessory Pathways 332
- Atrial Fibrillation in Wolff–Parkinson–White Syndrome 335
- Sudden Death in Wolff–Parkinson–White Syndrome 338
- Lown–Ganong–Levine Syndrome 338
- Mahaim-Type Preexcitation 338

Chapter 18. Electrocardiographic Diagnosis of Cardiomyopathies 345

- Hypertrophic Cardiomyopathy 345
  - » Basic Criteria for ECG Diagnosis of Hypertrophic Cardiomyopathy 351
  - » Anis-Baren ECG Triad 351
  - » Apical Cardiomyopathy 351
  - » Sudden Cardiac Death in Hypertrophic Cardiomyopathy 355
- Dilated Cardiomyopathy 361
  - » Goldberger's Triad 361
- Restrictive Cardiomyopathy 365
- Arrhythmogenic Right Ventricular Cardiomyopathy/Dysplasia 365
- Left Ventricular Noncompaction 367
- Takotsubo Cardiomyopathy 368
  - » Differentiation Between Acute Anterior Myocardial Infarction and Takotsubo Cardiomyopathy 368

Chapter 19. Electrocardiogram Diagnosis of Pericarditis and Other Cardiac Inflammatory Conditions 375

- Pericarditis 375
  - » Spodick's Sign 376
  - » Differentiation of Acute Pericarditis from Acute ST-Elevation Myocardial Infarction 378
  - » Differentiation of Acute Pericarditis from Early Repolarization Pattern 380
  - » Electrocardiogram Changes in Pericardial Effusion 382
  - » Cardiac Tamponade 383
- Electrocardiographic Diagnosis of Myocarditis 384
- Electrocardiographic Diagnosis of Endocarditis 387
- Electrocardiogram Changes in Rheumatic Carditis 387

Chapter 20. Electrocardiographic Manifestations of Electrolyte Abnormalities 392

- Hyperkalemia 392
  - » Different Stages of Hyperkalemia 393
- Hypokalemia 394
- Hypercalcemia 398
- Hypocalcemia 401
- Hypermagnesemia 401
- Hypomagnesemia 401
- Electrocardiogram Features of Multiple Electrolyte Imbalances 401

Chapter 21. Electrocardiograms in Specific Clinical Conditions 404

- Chronic Obstructive Pulmonary Disease (COPD) 404
- Pulmonary Embolism 406
  - » McGinn-White Sign 407
- Hypothermia 409
- Thyrotoxicosis 409
- Hypothyroidism 411
- Electrocardiogram Features of Increased Intracranial Pressure 412
- Parkinson's Disease 415
- Electrocardiogram Changes in Neuromuscular Disorders 415
- Friedreich's Ataxia: Cerebellar Ataxia 415
- Electrocardiogram After Heart Transplantation 416
- Electrocardiogram Features of Primary Pulmonary Hypertension (PPH) 417

Chapter 22. Effects of Various Drugs on the Electrocardiogram 425

- Digitalis 425
  - » Digoxin Effect 425
  - » Reverse Tick Sign 425
  - » ECG Manifestations of Digitalis Toxicity 426
- Tricyclic Antidepressants 430
- Beta-Blockers 430
- Verapamil 431
- Fluoroquinolones 432
- Macrolide Antibiotics 432
- Antiarrhythmic Drugs 432

Chapter 23. Electrocardiogram Features of Congenital Heart Diseases 435

- Atrial Septal Defect (ASD) 435
  - » ECG Features of Secundum ASD 435
- Crochetage Sign 437
- ECG Features of Primum ASD 440
- ECG Features of Sinus Venosus Type ASD 440
- ECG Findings in Ventricular Septal Defect (VSD) 444
- Tetralogy of Fallot 444
- Ebstein's Anomaly 446
- Dextrocardia 446
- Technical Dextrocardia 450
- Patent Ductus Arteriosus 450
- Coarctation of Aorta 450
- Pulmonary Stenosis 450
- Eisenmenger Syndrome 450
- Transposition of the Great Arteries 453
- Tricuspid Atresia 453
- Mitral Valve Prolapse (MVP) 453

Chapter 24. Pacemaker Electrocardiogram Interpretation 459

- Indications for Permanent Pacing 459
- Atrial Pacing 460

- Ventricular Pacing 460
- Pacemaker Types 462
- Pacemaker Codes 462
- Pacemaker Terminology 465
  - » Interpretation of Pacemaker ECG 466
- Effects of Pacemaker on ECG 466
- Pacemaker Malfunctions/Complications 466
- Diagnosis of ST-Elevation Myocardial Infarction (STEMI) in Presence of Pacemaker 466
- Diagnosis of Hyperkalemia in Presence of Pacemaker 468
- Electrocardiogram Interpretation After Cardiac Resynchronization Therapy 469

Chapter 25. Pediatric Electrocardiogram Interpretation 473

- Heart Rate 473
- Age-related Changes in Ventricles and QRS Axis 473
- Variations from Sinus Rhythm 476
  - » High Grade AV Block in Children 478
  - » Extrasystoles 478
- Influence of Sex 480
- Complete Heart Block in Pediatric ECG 480

Chapter 26. Exercise Tolerance Test 484

- Safety 485
  - » Normal Electrocardiographic Changes During Exercise 485
- Criteria for a Positive Exercise Test 485
  - » ST-Segment Depression 485
  - » ST-Segment Elevation 486
- Significance of ST-Segment Depression Limited to the Recovery Phase of Exercise Stress Test 488
- J-Point Depression During Exercise Tolerance Test 489
- Blood Pressure Response During Exercise Tolerance Test 489
- False-Positive Test 491
- False-Negative Test 491
- Exercise-Induced Arrhythmias 491
- Limitations 491

Chapter 27. Ambulatory Electrocardiogram Monitoring (Holter Monitoring) 496

- Arrhythmia and Ambulatory Electrocardiogram Monitoring 496
- Continuous Monitors (Holter Technology) 496
- Indications for Holter Monitoring 496
- Diagnostic Value of Holter Monitoring 497

Index *503*

Chapter 3

Interpretation and Identification of Different Waves in Electrocardiogram and Calculation of Heart Rate

INTRODUCTION

The standard electrocardiogram (ECG) paper speed is 25 mm/sec or 25 small squares per second. In this way it is possible to calculate the duration of individual waves (Fig. 3.1). Ten small squares (two large squares) vertically are equal to 1 millivolt (mV) (Fig. 3.2). So it is possible to calculate the amount of voltage being released within the heart. If the line is flat at any time in the duration of a series of waves, it indicates no electrical activity at that particular moment. The direction in which the waves point indicates whether electricity is moving toward or away from a particular lead. So different leads may have waves pointing in different directions, e.g. in lead augmented vector right (aVR) (right shoulder/right arm/wrist) will always see the electrical stimulus travelling away from it, therefore the

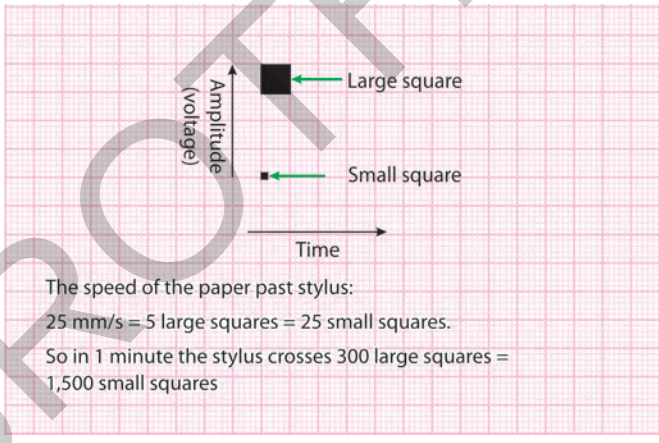

Fig. 3.1: Standard electrocardiogram (ECG) recording paper showing large and small squares.

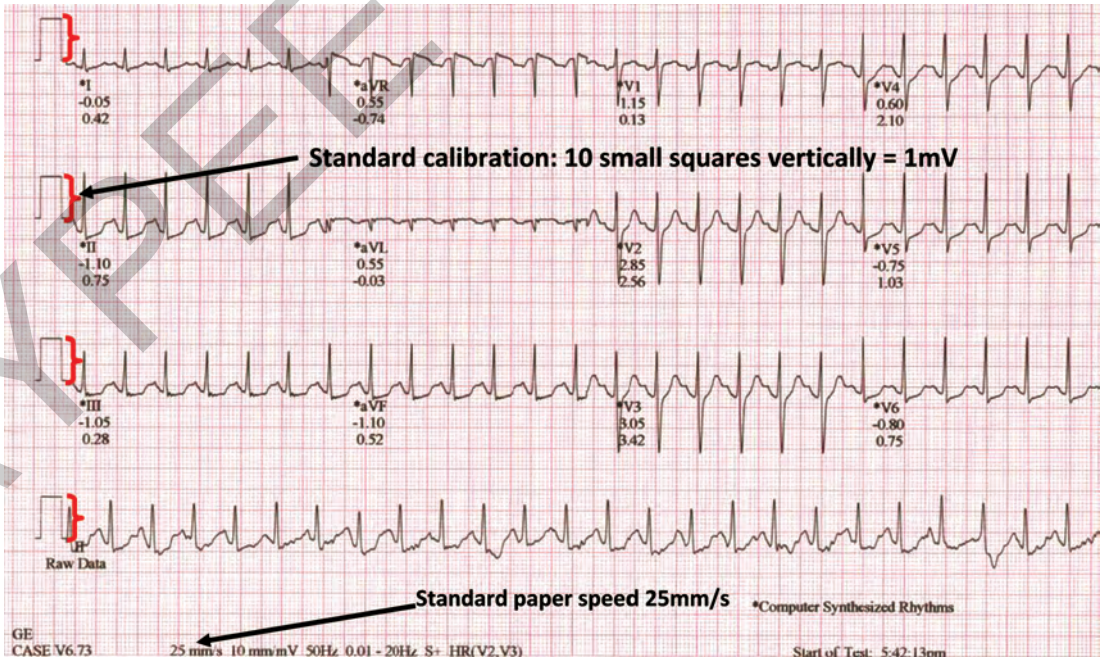

Fig. 3.2: Electrocardiogram showing standard calibration. Normal ECG machine calibration is 1 mV = 2 large squares = 10 small squares. Before interpreting ECG, calibration must be checked. Because, if machine calibration is wrong then calculation of the amplitude of all the waves will be also wrong. If paper speed is wrong (standard paper speed 25 mm/s) then time calculation will be also wrong. So, proper calibration signal along with standard paper speed should be included with every ECG record.

JAYPEE BROTHERS

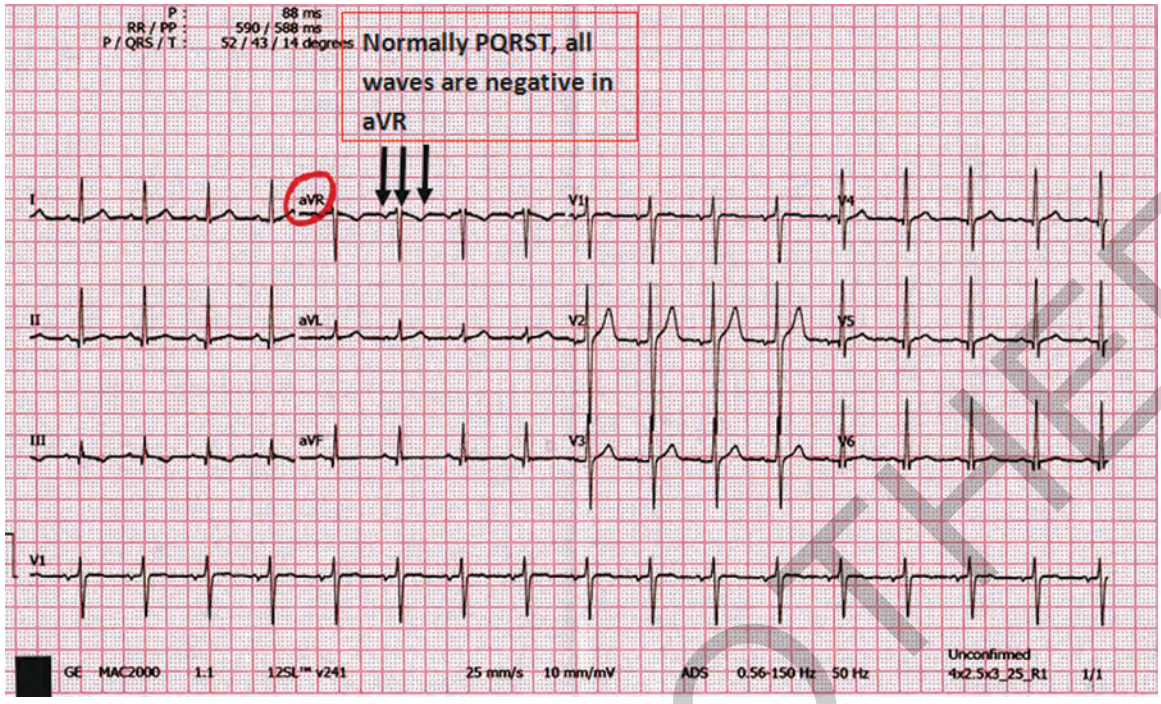

Fig. 3.3: In normal ECG, PQRST, all the waves are negative in lead aVR (*arrows*).

waves expressed in aVR for sinus rhythm, PQRST, will all point downward and negative (Fig. 3.3). Before interpreting ECG the calibration information on the ECG paper must be checked. A standard signal of 1 mV should move the stylus of the ECG machine vertically 1 cm (equal to two large squares). If machine calibration is wrong then calculation of the amplitude of all the waves will be also wrong (Figs. 3.4A to C). So, proper calibration signal should be included with every ECG record and before starting interpretation of ECG clinician must check that whether the calibration is correct or not.

Typically an ECG has five deflections, arbitrarily named "P" to "T" waves. The Q, R, and S waves occur in rapid succession, do not appear in all leads, and reflect a single event, and thus are usually considered together. A *Q wave* is any downward deflection after the *P wave*. An *R wave* follows as an upward deflection, and the *S wave* is any downward deflection after the R wave. The *T wave* follows the *S wave*, and in some cases an additional *U wave* follows the *T wave* (Fig. 3.5A).

During each cardiac cycle the first structure to be depolarized during normal sinus rhythm is the right atrium, closely followed by the left atrium. So the first electrical signal on a normal ECG originates from the atria and is known as the *P wave*. Although there is usually only one P wave in most leads of an ECG, the P wave is in fact the sum of the electrical signals from the two atria, which are usually superimposed. There is then a short, physiological delay as the atrioventricular (AV) node slows the electrical depolarization before it proceeds to the ventricles. This delay is responsible for the *PR interval*, a short period where no electrical activity is seen on the ECG, represented by a straight horizontal or "isoelectric" line. Depolarization of the ventricles results in usually the largest part of the ECG signal (because of the greater muscle mass in the ventricles) and this is known as the *QRS complex*. The Q wave is the first initial downward or "negative" deflection. The R wave is then the next upward deflection (provided it crosses the isoelectric line and becomes "positive"). The S wave is then the next deflection downward, provided it crosses the isoelectric line to become briefly negative before returning to the isoelectric baseline. In the case of the ventricles, there is also an electrical signal reflecting repolarization of the myocardium. This is shown as the *ST segment* and the *T wave*. The ST segment is normally isoelectric, and the T wave in most leads is an upright deflection of variable amplitude and duration (Fig. 3.5B).

P WAVE

Atrial activity, the P wave is usually apparent in most ECG leads. However, sometimes the P wave is of low amplitude and it may be necessary to inspect all leads of the ECG to establish the rhythm as sinus. Atrial depolarization wave spreads from the sinus node, which lies at the junction of the superior vena cava and right atrium, in an inferior direction toward the AV junction. The P wave, therefore, is upright in leads I, II, III, and augmented vector foot (aVF), which face the inferior surface of the heart, and is inverted in aVR, which faces the superior surface of the heart. In a 12-lead ECG, the small and rounded P wave is clearly visible

JAYPEE BROTHERS

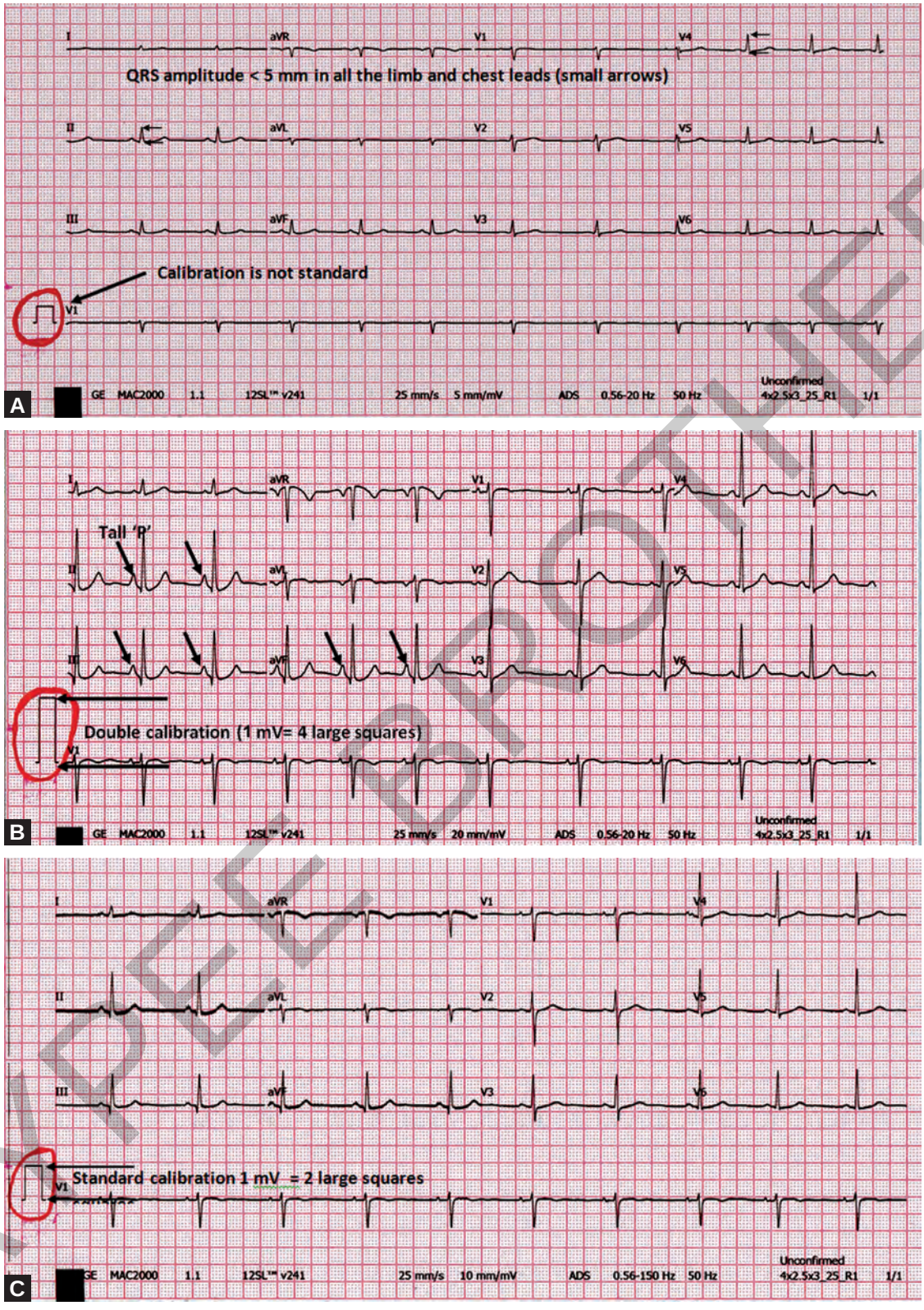

Figs. 3.4A to C: (A) Apparently this electrocardiogram is suggestive of low voltage ECG. But if you look at the calibration signal (red circle, *large arrow*), you can easily detect that the standardization of the machine is not proper. Machine calibration was not set at standard 1 mV (2 large squares), rather it was set at half of standard calibration (1 mV = 1 large square). So, the ECG is wrongly depicting low voltage, QRS amplitudes less than 5 mm in all the leads (*small arrows*). (B) In the same patient (A) this ECG suggests *P*-pulmonale [Tall and peak "P" waves >2.5 mm in height in LII, LIII, and augmented vector foot (aVF)]. But if you look at the calibration signal (red circle), you can easily detect that the standardization of the machine is not proper. Machine calibration was not set at standard 1 mV (2 large squares), rather it was set at double of the standard calibration, 1 mV = 4 large squares (*large arrows*). So, in this tracing all the waves appearing bigger and the ECG is wrongly depicting P-pulmonale (*small arrows*). (C) In the same patient with standard calibration (1 mV = 2 large squares) of the machine, the ECG appears normal (*red circle with arrows*).

JAYPEE BROTHERS

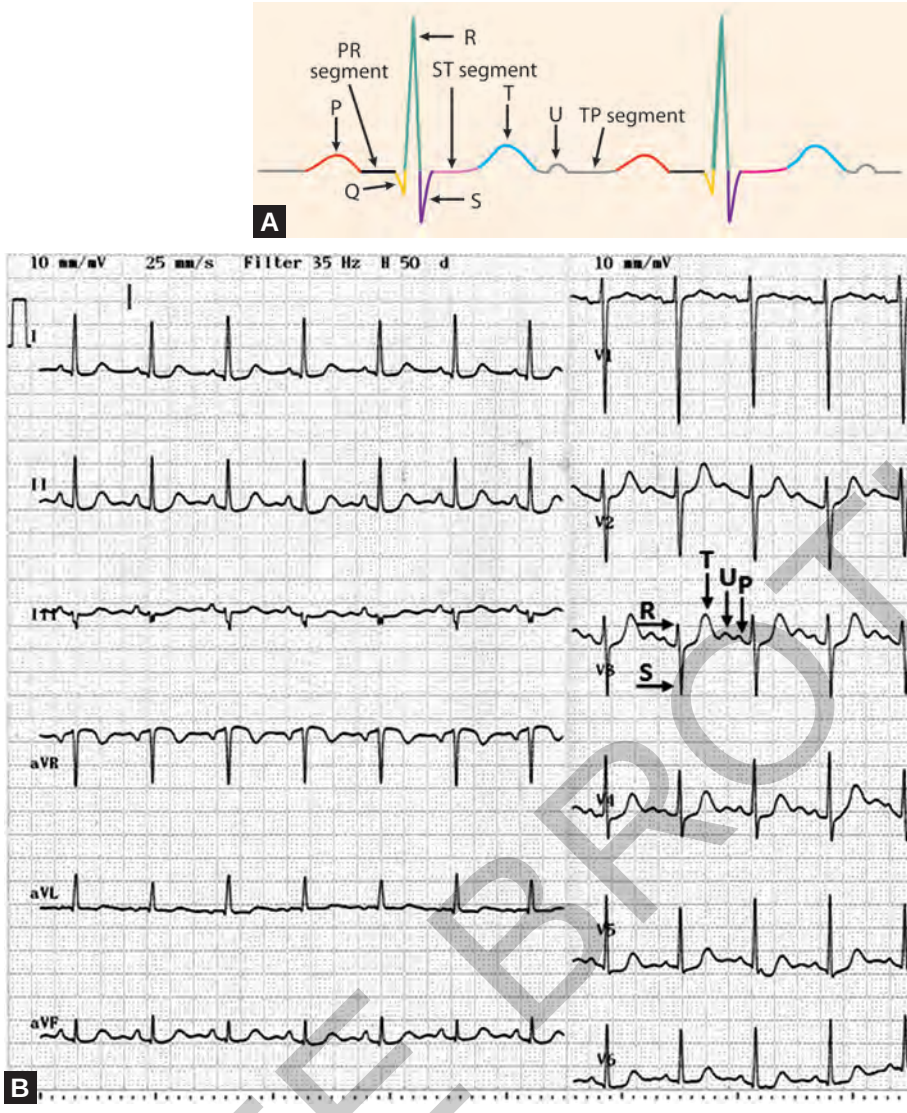

Figs. 3.5A and B: (A) Waves of the normal ECG. (B) Waves of the normal ECG. In this ECG "q" wave is not clearly discernible in any lead. "q" wave may be absent in normal tracing.

just before the taller, more peaked QRS complex. But if the heart rate (HR) is very fast, the P wave may merge with the preceding T wave and becomes difficult to identify.

Atrial depolarization proceeds sequentially from right to left, with the right atrium activated before the left atrium. The right and left atrial waveforms summate to form the P wave. The first one-third of the P wave corresponds to right atrial activation, the final one-third corresponds to left atrial activation; the middle one-third is a combination of the two (Fig. 3.6). In most leads (e.g. lead II), the right and left atrial waveforms move in the same direction, forming a monophasic P wave except in lead V1. In lead V1 the right and left atrial waveforms move in opposite directions (Fig. 3.7). This produces a biphasic P wave with the initial positive deflection corresponding to right atrial activation and the subsequent negative deflection denoting left atrial activation (Fig. 3.8).

Characteristics of Normal P wave

1. P wave precedes each QRS complex.
2. Upright in leads LI, LII, LIII, and aVF and inverted in lead aVR.
3. The P-wave contour is normally smooth.
4. P duration less than 0.12 seconds (120 ms)
5. P amplitude less than 2.5 millimeter (less than 0.25 mV)
6. Frontal plane P-wave axis: 0° to +75°
7. May see notched P waves in frontal plane.
8. The P waves in leads I and II must be upright (positive) if the rhythm is coming from the sinus node.

PR INTERVAL

The AV node delays conduction of the atrial impulse to the ventricles. The PR interval, which is measured from the

JAYPEE BROTHERS

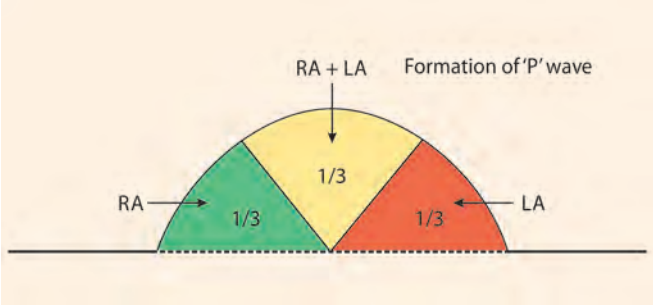

Fig. 3.6: The right atrial (RA) and left atrial (LA) waveforms summate to form the P-wave. The first one-third of the P-wave corresponds to RA activation, the final one-third corresponds to LA; the middle one-third is a combination of the two.

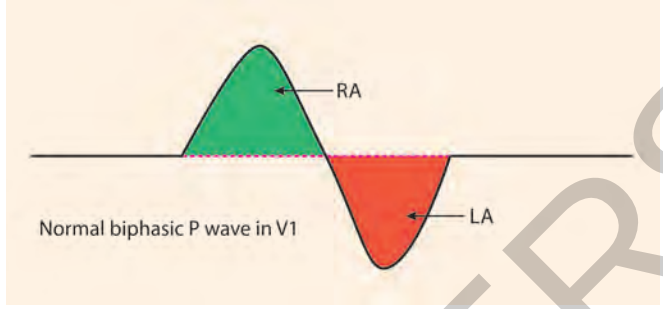

Fig. 3.8: Contribution of right and left atrium in the formation of biphasic P-wave in V1. The part of the wave above the isoelectric line is contributed by the RA and the part below the isoelectric line is by LA (*arrows*).

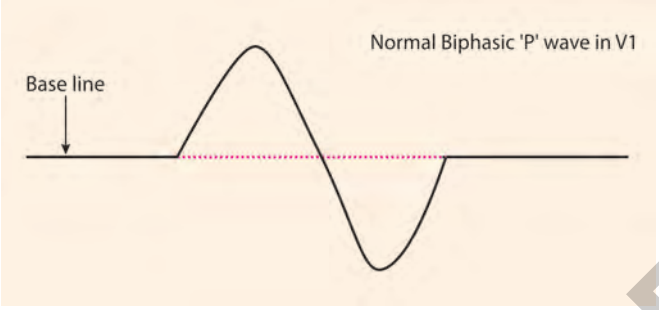

Fig. 3.7: Normal biphasic "P" wave in V1.

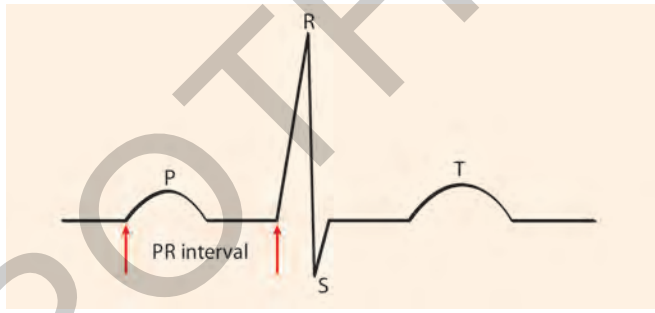

Fig. 3.9: The PR interval, which is measured from the onset of the P-wave to the onset of the QRS complex (*arrows*).

onset of the P wave to the onset of the ventricular complex (QRS), indicates the time taken for an atrial impulse to reach the ventricles (Fig. 3.9). If a Q wave is present then the PR interval is termed as PQ interval. So PR interval and PQ interval are synonymous.

The normal PR interval ranges from 0.12 seconds to 0.20 seconds (120–200 ms) or 3–5 small squares in duration. But the duration of PR interval depends on the HR, being shorter at faster HR [sinus tachycardia, HR greater than 100 beats/min (bpm)] and widens during slower HR (sinus bradycardia, HR less than 60 bpm). PR interval appears shorter during childhood and adolescence and tends to increase with age.[1-4] The PR interval is longer with high vagal tone. A prolonged PR interval corresponds to impaired AV conduction. Prolonged PR interval, or first degree AV block, has been traditionally regarded as a benign electrocardiographic finding in healthy individuals. In the middle-aged general population, prolonged PR interval normalizes in a substantial proportion of subjects during the time course, and it is not associated with an increased risk of all-cause or cardiovascular mortality.[3]

Causes of Prolonged PR Interval

PR interval greater than 0.20 seconds (greater than 200 ms, greater than 5 small squares)[4-6]

- Intrinsic AV nodal disease
- Enhanced vagal tone
- Acute myocardial infarction (MI), particularly acute inferior wall MI
- Myocarditis
- Electrolyte disturbances (e.g. hypokalemia and hypomagnesemia)
- Drug induced (beta-blockers, calcium channel blockers, digoxin, quinidine, procainamide, disopyramide, etc.).

Causes of Short PR Interval

PR interval less than 0.12 seconds (less than 120 ms, less than 3 small squares)[7-9]

1. Normal variant
2. Atrioventricular junctional rhythm
3. Wolff–Parkinson–White syndrome
4. Lown–Ganong–Levine syndrome.

PR SEGMENT

The *PR segment* is the flat, usually isoelectric segment between the end of the P wave and the start of the QRS complex (Fig. 3.10). PR segment is also called PQ segment or PTa segment. The PR segment is different than the PR interval which is measured in units of time (ms). Abnormalities of the PR segment are not very common, however, can indicate certain cardiac disease states. PR segment depression can indicate pericarditis or atrial infarction. PR segment elevation occurs in lead aVR in the setting of pericarditis.

JAYPEE BROTHERS

PR segment elevation or depression in patients with MI indicates concomitant atrial ischemia or infarction. This finding has been associated with poor outcome following ST-elevation myocardial infarction (STEMI) and associated with increased risk for the development of AV block, supraventricular arrhythmias, and cardiac free-wall rupture.

QRS COMPLEX

On 12 lead ECG ventricular activation is represented by the QRS complex (Fig. 3.11) which is normally less than 0.10 seconds (less than 100 ms). Normal range in adults varies from 0.06 seconds to 0.10 seconds (60–100 ms). A duration of 0.11 seconds (110 ms) is sometimes observed in healthy subjects. After traversing the AV node, the impulse reaches the bundle of His and right and left bundles which rapidly conduct it to the ventricular myocardium through the distal part of the bundles and Purkinje fibers.

The amplitude of QRS complex is much larger than that of the atrial P wave, because the muscle mass of the ventricles is much larger than the atriums. QRS complex consists of three distinct waves, each of which has a name (Fig. 3.11):

1. The first downward deflection is called "Q" wave.

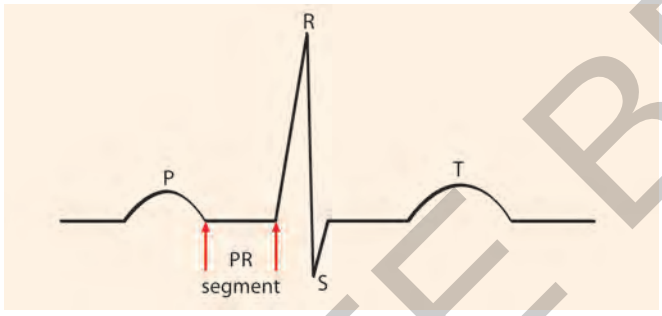

Fig. 3.10: The PR segment extends between the end of the P-wave and the start of the QRS complex (*arrows*).

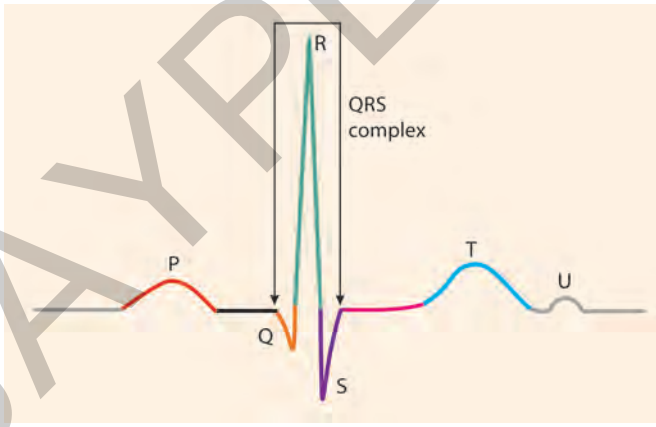

Fig. 3.11: QRS complex consists of three distinct waves, each of which has a name. The first downward deflection is called "Q" wave, the first positive wave after Q-wave is named as "R" wave and the first downward deflection following R-wave is the "S" wave (*arrows*).

2. The first wave after Q wave is named as "R" wave.
3. The first downward deflection following R wave is the "S" wave.

Q wave may be physiological or pathological. Physiological Q wave is usually less than 0.03 seconds duration. A Q wave of any size is considered normal in leads LIII and aVR. The presence of small Q wave in leads V5 and V6 is considered normal. But in some leads V1, V2, and V3, the presence of a Q wave should be considered abnormal.

The presence of a Q wave does not indicate any specific electrophysiological mechanism. To the contrary, Q waves can be related to one or more of the following four factors.[10,11]

1. Physiologic and positional effects (physiological Q wave)
2. Myocardial injury or infarction
3. Ventricular enlargement
4. Altered ventricular conduction.

Clinicians should be aware of three principles with respect to Q waves[11,12]

1. Not all Q waves are pathologic.
2. Not all pathologic Q waves are due to MI caused by fixed coronary artery occlusion.
3. There is no firm consensus on the criteria for the diagnosis of pathologic Q waves. But pathologic Q waves are usually defined as duration greater than or equal to 0.04 seconds or greater than 25% of R-wave amplitude.

R wave (Fig. 3.5) normally increases in amplitude and duration from lead V1 to V5 (V6) as during each cardiac cycle electrical activity progress from the thinner right ventricle towards the thicker left ventricle. So in normal 12-lead ECG "R" waves are smaller in amplitude in leads V1, V2 and larger in leads V4, V5. But reversal of this sequence occurs in presence of ventricular hypertrophy. Tall "R" waves are produced in leads V1 and V2 by right ventricular hypertrophy (RVH) and tall "R" waves are present in leads V5 and V6 in presence of left ventricular hypertrophy (LVH). Loss of R wave or poor progression of R wave from leads V1 to V5 may indicate previous myocardial infarction.

The *S wave* is the first downward deflection of the QRS complex that occurs after the R wave (Fig. 3.5). An S wave may not be present in all ECG leads in a given patient. In the normal ECG, there is a large S wave in V1 which progressively becomes smaller to the point where almost no S wave is present in V6. A large slurred S wave is seen in lead I and V6 in the setting of a right bundle branch block (RBBB).

The duration of QRS complex is termed as "QRS interval" and normally ranges from 0.06 seconds to 0.10 seconds. It tends to be slightly longer in males than females. The QRS interval has no lower limit that indicates abnormality. But QRS prolongation is usually caused by ventricular hypertrophy, arrhythmia, and conduction abnormalities. The QRS complex is often used to determine the axis of the ECG, although it is also possible to determine a separate P-wave axis. The duration, amplitude, and morphology of the QRS complex are useful in diagnosing cardiac arrhythmias,

JAYPEE BROTHERS

conduction abnormalities, ventricular hypertrophy, MI, electrolyte derangements, and other disease states.

J-POINT

The point at which the QRS complex meets the ST segment is known as the J-point. The J-point is easy to identify when the ST segment is horizontal and forms a sharp angle with the last part of the QRS complex (Figs. 3.12A and B). However, when the ST segment is sloped or the QRS complex is wide, the two features do not form a sharp angle and the location of the J-point is less clear. There is no consensus on the precise location of the J-point in these circumstances.[13,14]

ST SEGMENT

The ST segment is the flat, isoelectric section of the ECG between the end of the S wave (the J-point) and the beginning of the T wave. It represents the interval between ventricular depolarization and repolarization. The most important causes of ST segment abnormalities (elevation or depression) are myocardial ischemia/infarction, bundle branch block, ventricular hypertrophy, and pericarditis.

An ST elevation is considered significant if the vertical distance inside the ECG trace and the baseline greater than 1 mm or 1 small square in a limb lead or 2 mm or 2 small squares in a precordial lead. The baseline is either the PR segment or the TP segment. Significant ST depression is defined as depression of the ST segment level greater than 0.1 mV (1.0 mm) compared with the baseline.

Common Causes of ST Segment Elevation (Figs. 3.13A and B)

- Acute MI

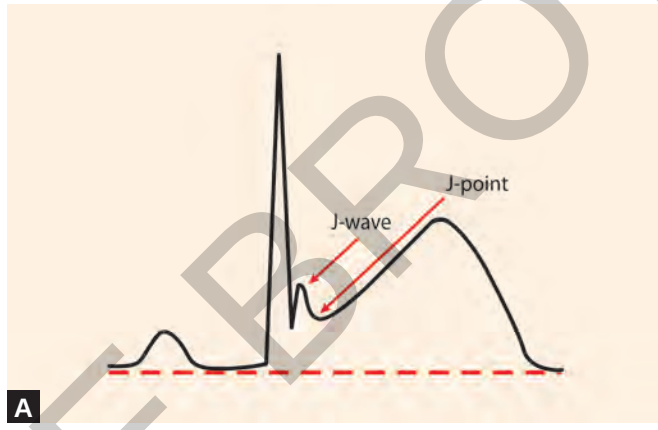

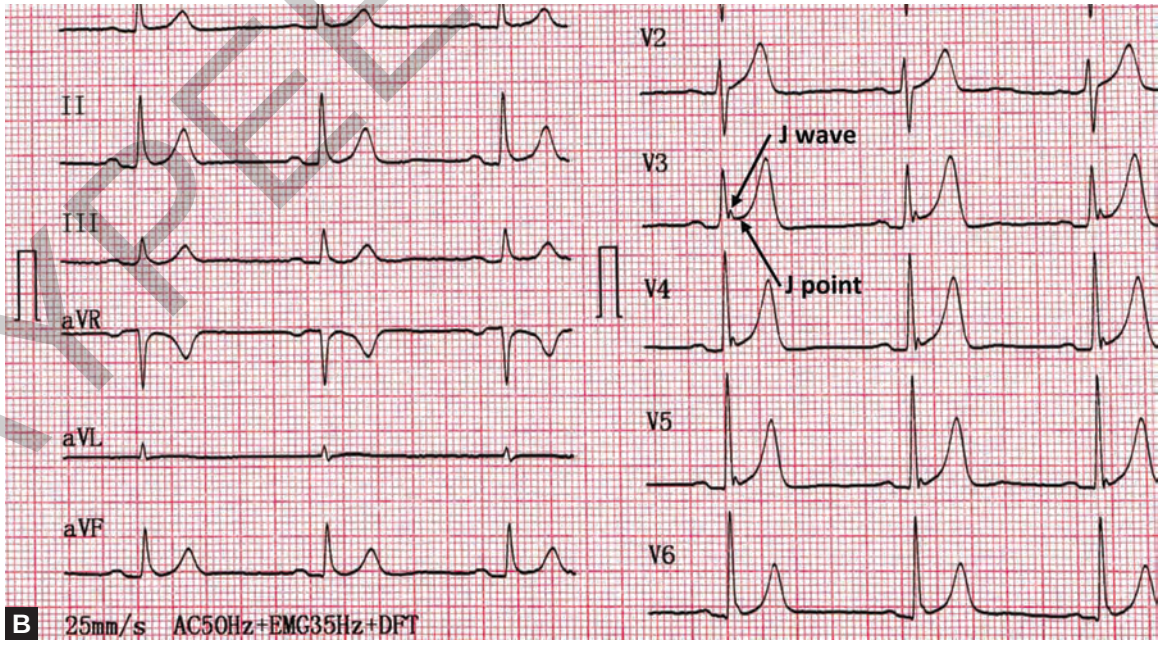

Figs. 3.12A and B: (A) J-point, the point at which the QRS complex meets the ST segment (*arrows*). (B) J-point elevation in leads V3 to V6 suggestive of early repolarization pattern, usually normal variant.

JAYPEE BROTHERS

- Pericarditis
- Coronary vasospasm (Prinzmetal's angina)
- Early repolarization pattern (normal variant)
- Left bundle branch block
- Hyperkalemia
- Ventricular aneurysm
- Ventricular paced rhythm
- Raised intracranial pressure.

Less Common Causes of ST Segment Elevation

- Pulmonary embolism
- Acute aortic dissection
- Brugada syndrome
- Hypothermia
- Hypercalcemia
- Following electrical cardioversion.

Rare Causes of ST Segment Elevation

- Cardiac tumor
- Pancreatitis/gallbladder disease
- Myocarditis
- Septic shock
- Anaphylaxis.

Common Causes of ST Segment Depression

- Acute coronary syndrome (Non-STEMI/unstable angina)
- Left ventricular hypertrophy
- Physiologic J-junctional depression with sinus tachycardia
- Digoxin effect
- Subendocardial ischemia
- Reciprocal changes in STEMI.

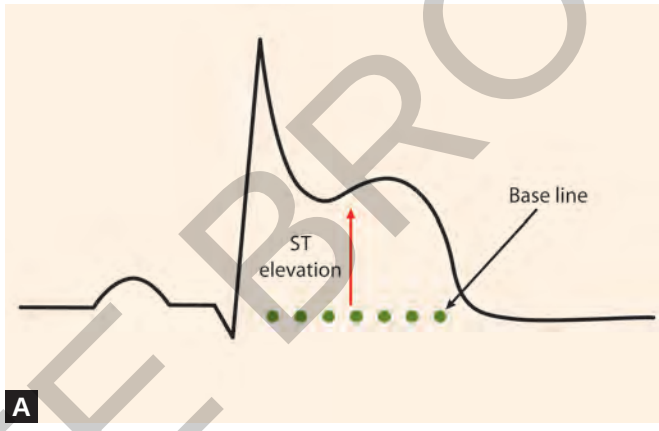

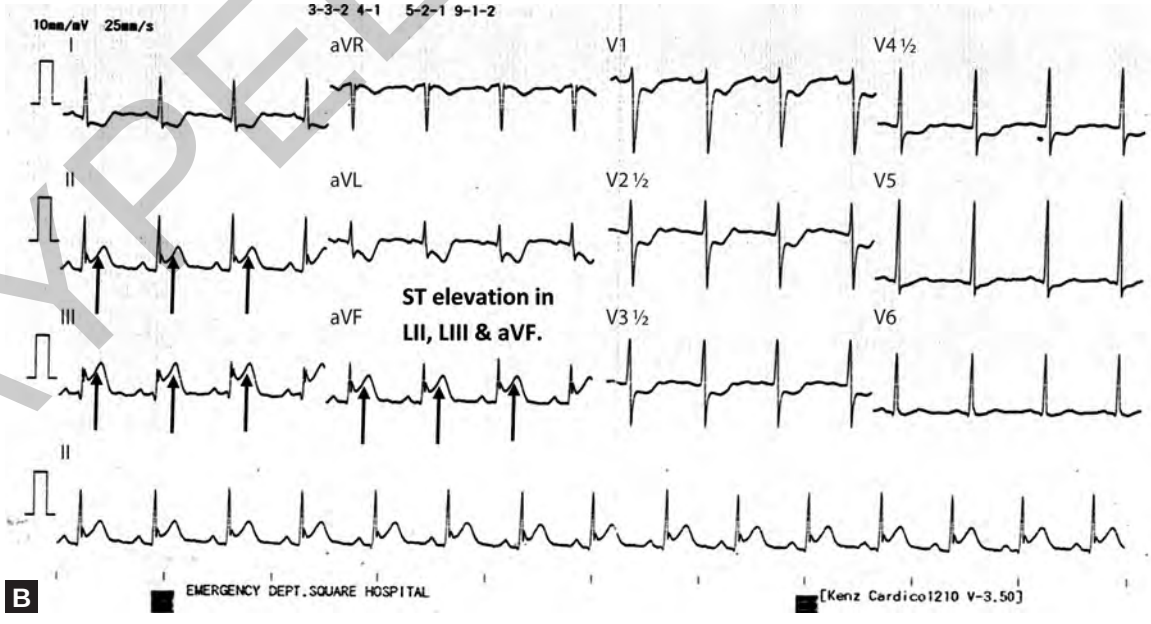

Figs. 3.13A and B: (A) ST segment elevation with convexity upwards suggestive of ST-elevation myocardial infarction (STEMI). (B) ST elevation with convexity upwards in LII, LIII, and aVF suggestive of acute inferior myocardial infarction.

JAYPEE BROTHERS

Uncommon Causes of ST Segment Depression

- Hypokalemia
- Hyperventilation
- Hypothermia
- Mitral valve prolapse.

Heightened awareness of the characteristic patterns of ST-segment depression and T-wave inversion is paramount to quickly identify life-threatening disorders. Depression of the ST segment and inversion of the T wave are common electrocardiographic abnormalities. Knowing the various ischemic and nonischemic morphologic features is critical for a timely diagnosis of high-risk myocardial ischemia and electrolyte or drug-related abnormalities. ST-segment depression may be primary or secondary. ST segment and T-wave abnormalities may be unrelated to any QRS abnormality, in which case they are called primary repolarization abnormalities. These are caused by ischemia, pericarditis, myocarditis, drugs (digoxin and antiarrhythmic drugs), and electrolyte abnormalities, particularly potassium abnormalities. ST-T abnormalities concordant to the QRS complex suggest ischemia.[15] In secondary ST segment or T-wave abnormalities, QRS criteria for LVH or RVH or LBBB or RBBB or preexcitation are usually present. In secondary ST-segment depression the ST segment and T wave are directed opposite to the QRS—this is called discordance between the QRS complex and the ST-T abnormalities.[15] ST segment depression is often characterized as "upsloping" (Figs. 3.14A and B),

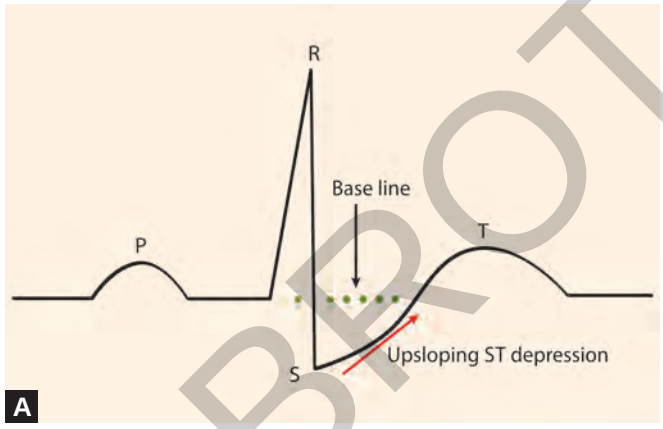

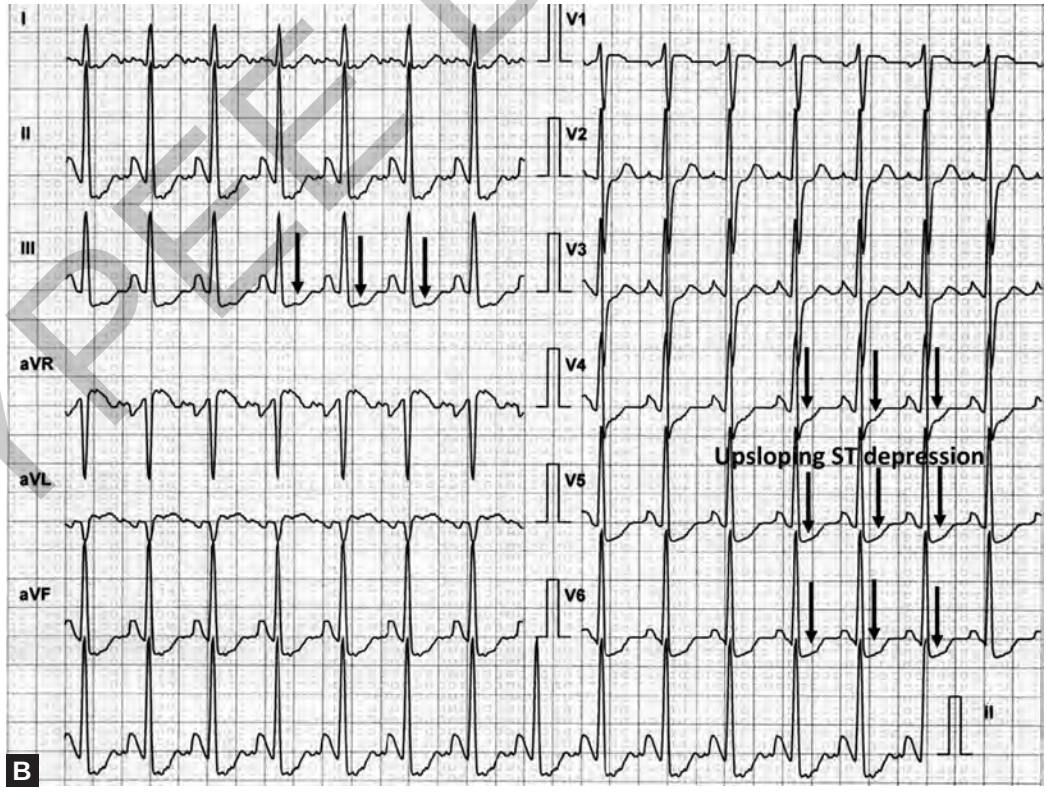

Figs. 3.14A and B: (A) Upsloping ST segment depression. (B) ECG showing widespread upsloping ST segment depression.

JAYPEE BROTHERS

"horizontal" (Figs. 3.15A and B), or "downsloping" (Figs. 3.16A and B). Horizontal or downsloping ST segment depression is always significant.

ST depression attributable to ischemia is often diffuse and can be located in both anterior and inferior leads, and is not necessarily localizing. Extensive experience from cardiac stress testing shows that the actual configuration of the ST-segment depression influences the specificity of this finding, with a downsloping segment more specific for the diagnosis of ischemia than horizontal depression. A depressed but upsloping ST segment lacks adequate specificity for ischemia. At least 0.10 mV (1.0 mm) depression at the J-point and either horizontal or downward sloping ST segment depression is suggestive of myocardial ischemia.

T WAVE

The T wave reflects ventricular repolarization. This is the most labile wave in the ECG. T wave changes including low-

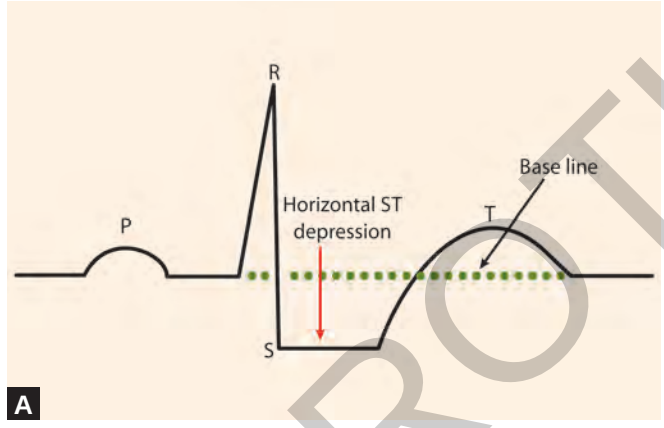

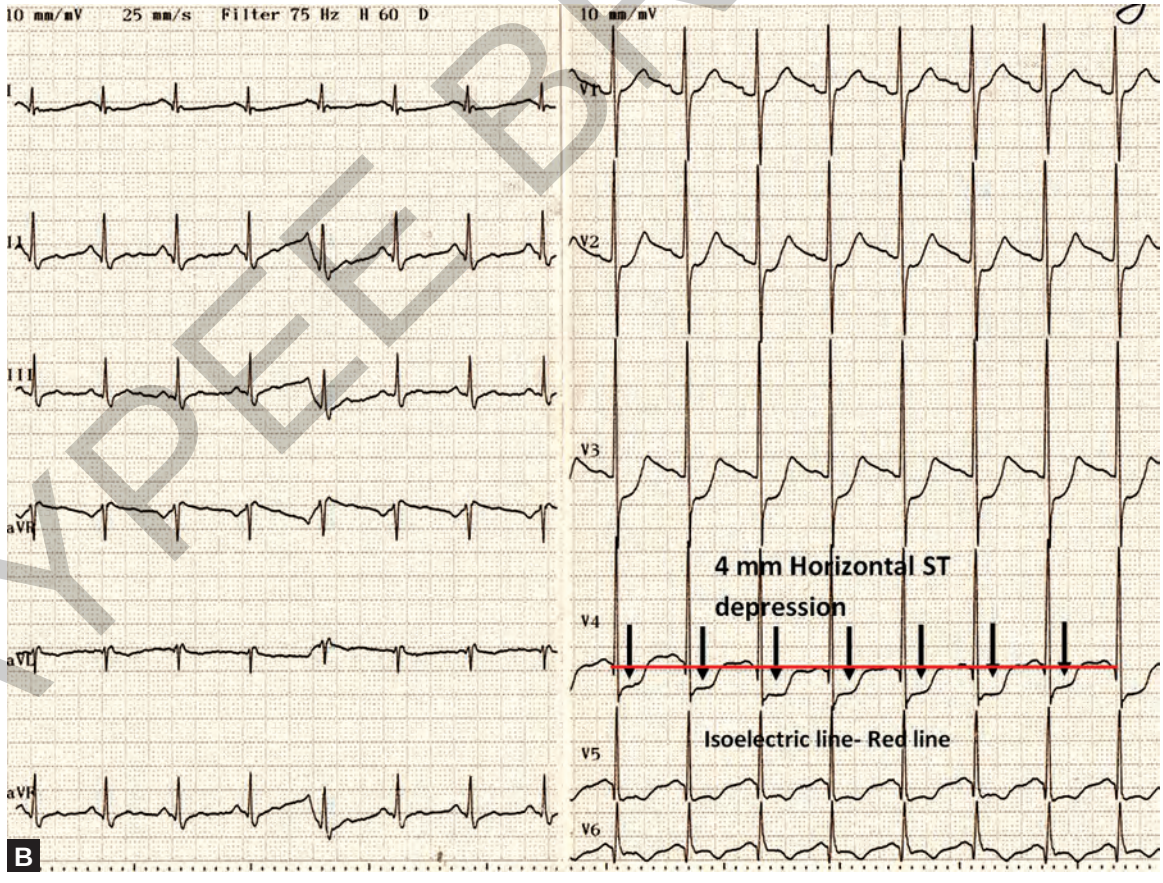

Figs. 3.15A and B: (A) Horizontal ST segment depression. (B) ECG showing 4 mm horizontal ST segment depression (*black arrows*). Red line indicates isoelectric line.

JAYPEE BROTHERS

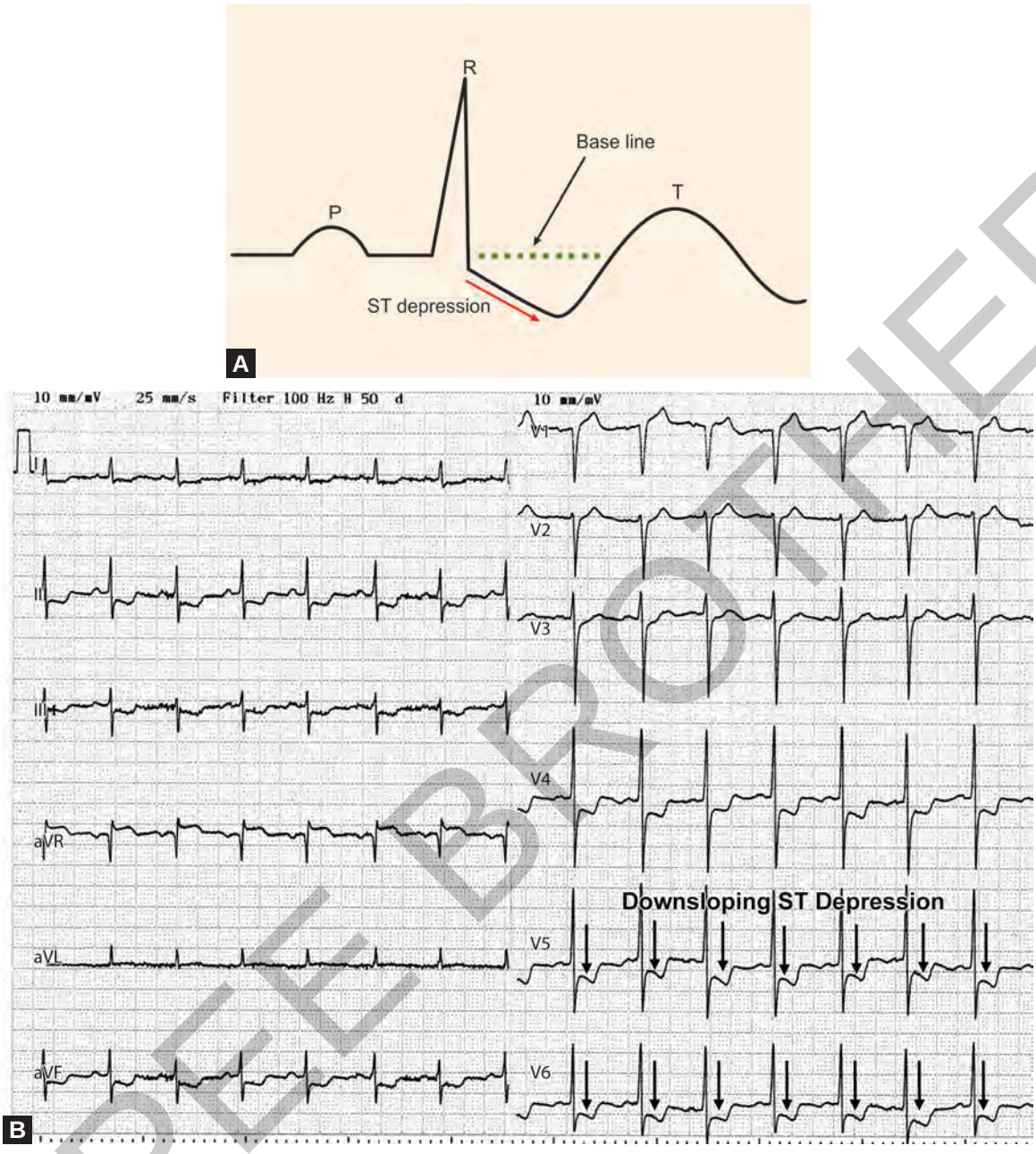

Figs. 3.16A and B: (A) Downsloping ST depression (*red arrow*). (B) Downsloping ST depression in lead V5, V6 (*black arrows*).

amplitude T waves and abnormally inverted T waves may be the result of many cardiac and noncardiac conditions. The normal T wave is usually in the same direction as the QRS except in the right precordial leads. Also, the normal T wave is slightly asymmetric with the first half moving more slowly than the second half. In the normal ECG the T wave is always upright in leads I, II, V3 to V6, and always inverted in lead aVR. The other leads are variable depending on the direction of the QRS and the age of the patient.

It usually takes the same direction as the QRS complex (concordance); opposite polarity (discordance) may indicate past or current infarction. The T wave is usually smooth and rounded but may be of low amplitude in hypokalemia and hypomagnesemia and may be tall and peaked in hyperacute MI, hyperkalemia and LVH.

The T-wave amplitude tends to vary with QRS complex amplitude and should always be greater than that of the U wave, if it is present. T waves do not normally exceed 5 mm in limb leads or greater than 10 mm in any precordial leads.

Patterns of Different "T" waves (Fig. 3.17)

- Normal T wave (Fig. 3.17A)
- Inverted T wave (Fig. 3.17B) may be symmetric or asymmetric

JAYPEE BROTHERS

or detailed information on cardiology books, visit our website www.ejaypee.com, for detailed information on cardiology books, visit our website www.

Textbook of Basic and Advanced Electrocardiography

Salient Features

- 'Simplicity is complexity resolved' goes the motto of this textbook. Here, the presentation is simple and comprehensive. The description of the subjects have been made in lucid and unambiguous language. This book will deliver the latest and most essential aspects of electrocardiogram (ECG) to students, both undergraduate and postgraduate, in a readable and compelling manner.
- Each and every chapter of this book has been divided into two different sections: 'Text' and 'Summary'. 'Text' part is meant for in-depth learning and the 'Summary' part includes only the key points for easy and quick revision and an examinee will be able to revise and re-read the essence of the whole book even before the night prior to examination.
- This book includes over 600 ECGs along with schematic drawings, colored sketches, flowcharts and boxes. Numerous annotations have been made inside the original ECGs for better understanding and convenience of the beginner undergraduate students.
- All information is up-to-date and evidence based. The book is intended to fill the gap of information between the contemporary ECG textbooks and new ideas & ECG signs published in different peer-reviewed journals in recent past. So, this book delivers an all encompassing grasp of the all basic principles of electrocardiogram including the latest developments on the subject.
- Must know areas have been highlighted in all the chapters.
- Throughout this book the author has described all aspects of electrocardiogram in an easy-to-understand style.
- This textbook will not only be the 'must have' companion of the MBBS and postgraduate students, it will also definitely guide the cardiologists, physicians and intensivists in emergency bedside decision making and thus will aid in urgent treatment planning.
- Undoubtedly, this book will deserve a place on the shelf of any medical student, general physician and cardiologist and it will be a definitive source of learning and relearning of the basic principles of electrocardiogram.

Baren Chakraborty is a medical graduate from Dhaka Medical College, Bangladesh and passed both Membership and Fellowship examinations in Medicine from Bangladesh College of Physicians and Surgeons. He did his Senior Fellowship training in Clinical and Interventional Cardiology from Singapore General Hospital, Singapore; Narayana Hrudayalaya Institute of Cardiac Sciences, Bengaluru, Karnataka, India, and University of Hawaii, USA. He is a Fellow of Royal College of Physicians of Edinburgh, Ireland, Glasgow, American College of Chest Physicians and American College of Cardiology. He is now working as a Professor, School of Health Science, State University of Bangladesh & Chief, Medical Education and Research & Senior Consultant and Interventional Cardiologist at Labaid Cardiac Hospital, Dhaka. Earlier he worked as Registrar in the Department of Cardiology, Singapore General Hospital, Singapore; Classified Instructor at Armed Forces Medical Institute, Dhaka; Coordinator Cardiac Catheterization Laboratory at Combined Military Hospital, Dhaka, and Professor of Cardiology at Bangladesh Medical College. He published over 100 original articles in different peer-reviewed journals at home and abroad and so far authored 38 books. Currently, he is the Editor of Bangladesh Journal of Cardiology. He received a number of well-acclaimed national and international awards for his excellent academic performance including Young Investigator Award from Singapore Cardiac Society in 1994. He has to his credit several celebrated national awards including second highest National Civilian Award "Ekushey Padak-2012" for his superb contribution in the field of Science and Technology and highest National Literary Award "Bangla Academy Puroskar-2012" for his splendid achievement in contemporary literature.

Shelving Recommendation
CARDIOLOGY

ISBN 978-93-5270-288-6

9 789352 702886

Buy from ejaypee

JAYPEE BROTHERS