website www.jaypeebrothers.com, for detailed information on radiology books, visit our website www.jaypeebrothers.com

Celebrating 50
Passion, Quality and Innovation in Healthcare Publishing

Differential Diagnosis in RADIOLOGY





THIRD EDITION

Sumeet Bhargava
Satish K Bhargava

JAYPEE

Differential Diagnosis in

RADIOLOGY

Third Edition

Sumeet Bhargava
MBBS DNB (Radiodiagnosis) FCGP FIAMS FICRI FIMSA MNAMS
Formerly Associate Professor
Department of Radiodiagnosis and Imaging
Rama Medical College and Superspecialty Hospital
Ghaziabad, Uttar Pradesh, India

Satish K Bhargava
MD (Radiodiagnosis) MD (Radiotherapy) DMRD FICRI FIAMS FCCP FUSI FIMSA FAMS
Formerly Professor and Head
Department of Radiology and Imaging
School of Medical Sciences and Research
Sharda Hospital, Sharda University
Greater Noida
Professor and Head
Department of Radiology and Imaging
University College of Medical Sciences (University of Delhi)
and Guru Teg Bahadur Hospital
New Delhi
Head, Department of Radiology and Imaging
JN Medical College, Aligarh Muslim University
Aligarh, Uttar Pradesh, India

JAYPEE BROTHERS

JAYPEE BROTHERS MEDICAL PUBLISHERS
The Health Sciences Publisher
New Delhi | London | Panama

Contents

1. Chest 1

- Lesions of Thoracic Inlet 1
  Satish K Bhargava, Rajeev Chaturvedi, Amit Sahu
- Cystic Lymphangioma 6
  Sumeet Bhargava, Satish K Bhargava
- Solid with Fat Density 6
  Sumeet Bhargava, Satish K Bhargava
- Solid without Fat Density 6
  Sumeet Bhargava, Satish K Bhargava
- Mediastinal Masses 7
  Satish K Bhargava, Nidhi Bhargava
- Pleuropericardial Cyst 8
  Sumeet Bhargava, Satish K Bhargava
- Differential Diagnosis of Soft Tissue Lesions in Right Anterior Cardiophrenic Angle 8
  Sumeet Bhargava, Satish K Bhargava
- Middle Mediastinal Masses 9
  Sumeet Bhargava, Satish K Bhargava
- Posterior Mediastinal Masses 10
  Sumeet Bhargava, Satish K Bhargava
- Hiatus Hernia 10
  Sumeet Bhargava, Satish K Bhargava
- Esophageal Lesions 10
  Sumeet Bhargava, Satish K Bhargava
- Paravertebral Lesions 10
  Sumeet Bhargava, Satish K Bhargava
- Differential Diagnosis of Superior Mediastinal Masses 11
  Sumeet Bhargava, Satish K Bhargava
- Differential Diagnosis of Anterior Mediastinal Masses 14
  Shuchi Bhatt, Rajul Rastogi, Sumeet Bhargava
- Anterior Mediastinal Mass 16
  Satish K Bhargava, Pardeep Kumar
- Middle Mediastinal Mass 16
  Sumeet Bhargava, Satish K Bhargava
- Lymph Nodes 17
  Sumeet Bhargava, Satish K Bhargava
- Differential Diagnosis of Posterior Mediastinal Masses 19
  Pushpender Gupta, Satish K Bhargava

JAYPEE BROTHERS

- Chest Wall Abnormalities 21
  Rajul Rastogi, Vinita Rathi
- Superior Rib Notching 22
  Shuchi Bhatt, Pardeep Kumar
- Inferior Rib Notching 24
  Satish K Bhargava, Nidhi Bhargava
- Elevation of Diaphragm 25
  Amit Sahu, Nidhi Bhargava, Shuchi Bhatt
- Pneumomediastinum 27
  Nidhi Bhargava, Satish K Bhargava
- Lung Tumors 27
  Satish K Bhargava, Nidhi Bhargava
- Hilar Enlargement 29
  HM Kansal, Nidhi Bhargava, Satish K Bhargava
- Apical Shadows 29
  Sumeet Bhargava, Satish K Bhargava
- Calcification on Chest Radiograph 29
  Satish K Bhargava, Nidhi Bhargava
- Air-Fluid Levels on Chest X-ray 31
  Satish K Bhargava, Nidhi Bhargava
- Cavitating Pulmonary Lesions 32
  Amit Sahu, Nidhi Bhargava, Satish K Bhargava
- Mass within Cavity 32
  Nidhi Bhargava, Satish K Bhargava
- Cavitating Pulmonary Lesions 32
  Pardeep Kumar, Rajul Rastogi, Satish K Bhargava
- Trauma 35
  Sumeet Bhargava, Satish K Bhargava
- Lucent Lung Lesions 35
  Nidhi Bhargava, Satish K Bhargava
- Solitary Pulmonary Nodule 36
  Nidhi Bhargava, Shuchi Bhatt
- Solitary Pulmonary Nodule 37
  Satish K Bhargava, HM Kansal, Sumeet Bhargava
- Pulmonary Edema on the Opposite Side to a Pre-existing Abnormality 42
  Nidhi Bhargava, Rajul Rastogi
- Miliary Shadowing 44
  HM Kansal, Satish K Bhargava, Sumeet Bhargava
- Miliary Shadowing (0.5–2 mm) 46
  Satish K Bhargava, Nidhi Bhargava, Sumeet Bhargava
- Multiple Opacities 47
  Sumeet Bhargava, Nidhi Bhargava, Shuchi Bhatt
- Complete Opaque Hemithorax 48
  Sumeet Bhargava, Nidhi Bhargava, Vinita Rathi

JAYPEE BROTHERS

- Opaque Hemithorax 48
  Satish K Bhargava, Pushpender Gupta, HM Kansal
- Hypertransradiant Lung Field 50
  Sumeet Bhargava, Satish K Bhargava, Anubhav Sarikwal
- Hypertranslucent Lung Field 53
  Nidhi Bhargava, Sumeet Bhargava
- Honeycomb Lung 54
  Sumeet Bhargava, Nidhi Bhargava, Satish K Bhargava
- Honeycomb Pattern 55
  Satish K Bhargava, Vinita Rathi, Sumeet Bhargava
- Asbestosis 56
  Sumeet Bhargava, Satish K Bhargava
- Pleural Diseases or Lesions 57
  Rajul Rastogi, Sumeet Bhargava
- Pleural Fluid 61
  Shuchi Bhatt, Nidhi Bhargava
- Pleural Tumors 62
  Nidhi Bhargava, Sumeet Bhargava, Amit Sahu, Satish K Bhargava
- Pleural Calcification 62
  Sumeet Bhargava, HM Kansal, Rajeev Chaturvedi, Satish K Bhargava
- High Resolution CT-Pattern of Parenchymal Disease 63
  Rajul Rastogi, Nidhi Bhargava, Satish K Bhargava
- Cardiophrenic Angle Mass 63
  Sumeet Bhargava, Satish K Bhargava, HM Kansal

2. Breast: Mammographic Differential Diagnosis 66
Sumeet Bhargava, Rajul Rastogi, Satish K Bhargava, Pushpender Gupta

- Density of Lesion on Mammogram 66
  Sumeet Bhargava, Satish K Bhargava
- Margins of Lesion 66
  Sumeet Bhargava, Satish K Bhargava
- Circumscribed Radiolucent Lesion 66
  Sumeet Bhargava, Satish K Bhargava
- Mixed Density Lesions 66
  Sumeet Bhargava, Satish K Bhargava
- Radiopaque (Soft Tissue Density Lesion) 68
  Sumeet Bhargava, Satish K Bhargava
- Circumscribed Malignant Lesions (Circumscribed Carcinoma) 70
  Sumeet Bhargava, Satish K Bhargava
- Breast Calcification Types 72
  Sumeet Bhargava, Satish K Bhargava
- Carcinoma 76
  Sumeet Bhargava, Satish K Bhargava .....

JAYPEE BROTHERS

3. Cardiovascular System 77

- Differential Diagnosis of Cardiovascular Disorders 77
  Sumeet Bhargava, Satish K Bhargava, Rajul Rastogi
- Invisible Main Pulmonary Artery 77
  Sumeet Bhargava, Satish K Bhargava
- Pulmonary Arterial Hypertension 78
  Sumeet Bhargava, Satish K Bhargava
- Enlarged Left Ventricle 79
  Sumeet Bhargava, Satish K Bhargava
- Enlarged Left Atrium 80
  Rajul Rastogi, Satish K Bhargava, Sumeet Bhargava
- Dilatation of Pulmonary Trunk 82
  Rajul Rastogi, Satish K Bhargava, Sumeet Bhargava
- Enlargement Aorta 82
  Sumeet Bhargava, Satish K Bhargava
- Small Aorta 83
  Sumeet Bhargava, Satish K Bhargava
- Enlarged Right Atrium 83
  Sumeet Bhargava, Satish K Bhargava
- Enlarged Right Ventricle 85
  Sumeet Bhargava, Satish K Bhargava
- Right Aortic Arch 85
  Rajul Rastogi, Satish K Bhargava, Sumeet Bhargava
- Pulmonary Venous Hypertension 87
  Rajul Rastogi, Satish K Bhargava, Sumeet Bhargava
- Enlarged Superior Vena Cava 87
  Sumeet Bhargava, Satish K Bhargava
- Cardiac Calcifications 88
  Sumeet Bhargava, Satish K Bhargava
- Cardiac Valve Calcifications 88
  Amit Sahu, Sumeet Bhargava, Satish K Bhargava
- Situs 89
  Sumeet Bhargava, Satish K Bhargava
- Cyanotic Heart Disease 89
  Sumeet Bhargava, Satish K Bhargava

4. Soft Tissue Lesions 91

Sumeet Bhargava, Satish K Bhargava, Shuchi Bhatt

- Differential Diagnosis of Soft Tissue Lesions 91
- Soft Tissue Ossification 92
- Linear Calcification of Soft Tissues 93
- Parasitic Calcification 94
- Areas of Decreased Density 94

JAYPEE BROTHERS

- Periarticular Soft Tissue Calcification 96
- Generalized Calcinosis 97
- Sheet-like Calcification in Soft Tissue 97

5. Abdomen and Gastrointestinal Tract and Hepatobiliary System 98

- Dilated Esophagus 98
  Rajul Rastogi, Satish K Bhargava, Rajeev Chaturvedi
- Esophageal Carcinoma 100
  Rajul Rastogi, Rajeev Chaturvedi, Satish K Bhargava
- Thickened Mucosal Folds Esophagus and Stomach 103
  Ashish Verma, Shuchi Bhatt, Sumeet Bhargava
- Thickened Gastric Folds 104
  Sumeet Bhargava, Satish K Bhargava
- Thickened Small Bowel 108
  Sumeet Bhargava, Satish K Bhargava
- Thickened Gastric Folds 110
  Rajul Rastogi, Satish K Bhargava, Sumeet Bhargava
- Thickened Duodenal Folds 111
  Amit Sahu, Rajul Rastogi, Satish K Bhargava, Sumeet Bhargava
- Massively Dilated Stomach 112
  Satish K Bhargava, Rajul Rastogi, Sumeet Bhargava
- Target Lesions in Stomach on Barium Study 112
  Sumeet Bhargava, Satish K Bhargava, Rajul Rastogi
- Gas in Gastric Wall 113
  Satish K Bhargava, Rajul Rastogi, Sumeet Bhargava
- Cobblestone Duodenal Cap on Barium Study 113
  Satish K Bhargava, Rajul Rastogi, Sumeet Bhargava
- Dilated Duodenum/Obstruction of Duodenum 113
  Rajul Rastogi, Sumeet Bhargava, Satish K Bhargava
- Dilated Small Bowel/Jejunal and Ileal Obstruction 114
  Sumeet Bhargava, Rajul Rastogi, Shuchi Bhatt
- Strictures Small Bowel 114
  Rajul Rastogi, Satish K Bhargava
- Small Intestinal Stricture 115
  Anubhav Sarikwal, Sumeet Bhargava
- Thickened Folds in Small Bowel 118
  Rajul Rastogi, Shuchi Bhatt, Sumeet Bhargava
- Thickened Small Bowel Folds with Gastric Abnormality 119
  Rajul Rastogi, Sumeet Bhargava, Satish K Bhargava
- Nodular Appearance of Small Bowel 119
  Rajul Rastogi, Sumeet Bhargava, Satish K Bhargava
- Malabsorption 119
  Satish K Bhargava, Rajul Rastogi, Sumeet Bhargava
- Protein Losing Enteropathy 124
  Satish K Bhargava, Rajul Rastogi, Sumeet Bhargava

JAYPEE BROTHERS

- Pathologic Lesions in Terminal Ileum 124
  Satish K Bhargava, Rajul Rastogi, Sumeet Bhargava
- Colonic Polyps 125
  Satish K Bhargava, Rajul Rastogi, Sumeet Bhargava
- Colonic Polyps 126
  Sumeet Bhargava, Satish K Bhargava
- Colonic Strictures/Narrowing 127
  Rajul Rastogi, Sumeet Bhargava, Satish K Bhargava
- Pneumatosis Intestinalis 128
  Rajul Rastogi, Sumeet Bhargava, Satish K Bhargava
- Megacolon in Adults 129
  Rajul Rastogi, Satish K Bhargava
- Thumbprinting in Colon 129
  Rajul Rastogi, Sumeet Bhargava, Satish K Bhargava
- Aphthous Ulcers 129
  Rajul Rastogi, Sumeet Bhargava, Satish K Bhargava
- Anterior Indentation of Rectosigmoid Junction 130
  Rajul Rastogi, Sumeet Bhargava, Satish K Bhargava
- Widening/Enlargement of Presacral/Retrorectal Space 130
  Sumeet Bhargava, Rajul Rastogi, Satish K Bhargava
- Cystic Mesenteric Masses 131
  Sumeet Bhargava, Rajul Rastogi, Satish K Bhargava
- Nonvisualization of Gallbladder on Ultrasound 131
  Rajul Rastogi, Sumeet Bhargava
- Gas in Biliary Tree 131
  Rajul Rastogi, Sumeet Bhargava, Satish K Bhargava
- Gas in Portal Venous 131
  Rajul Rastogi, Sumeet Bhargava, Satish K Bhargava
- Diffuse Hepatomegaly 132
  Rajul Rastogi, Sumeet Bhargava, Satish K Bhargava
- Hepatic Calcification 132
  Amit Sahu, Rajul Rastogi, Sumeet Bhargava, Satish K Bhargava
- Primary Hepatic Masses 133
  Rajul Rastogi, Sumeet Bhargava, Satish K Bhargava
- Neonatal Obstructive Jaundice 134
  Rajul Rastogi, Sumeet Bhargava, Satish K Bhargava
- Fetal/Neonatal Hepatic Calcification 134
  Rajul Rastogi, Sumeet Bhargava, Satish K Bhargava
- Diffusely Hypoechoic Liver 135
  Rajul Rastogi, Sumeet Bhargava, Satish K Bhargava
- Diffusely Hyperechoic Liver (Bright Liver) 135
  Rajul Rastogi, Sumeet Bhargava, Satish K Bhargava
- Focal and Hyperechoic Hepatic Lesions 135
  Rajul Rastogi, Satish K Bhargava

JAYPEE BROTHERS

- Focal, Hypoechoic and Hepatic Lesions 135
  Sumeet Bhargava, Satish K Bhargava, Rajul Rastogi
- Periportal Hyperechogenicity 135
  Sumeet Bhargava, Satish K Bhargava, Rajul Rastogi
- Thickened Gallbladder Wall 136
  Sumeet Bhargava, Satish K Bhargava, Rajul Rastogi
- Focal Hypodense Lesions on NECT Liver 136
  Satish K Bhargava, Sumeet Bhargava, Rajul Rastogi
- Hyperperfusion Abnormalities of Liver 137
  Satish K Bhargava, Rajul Rastogi, Sumeet Bhargava
- Hepatic Tumors with Vascular "Scar" 137
  Satish K Bhargava, Rajul Rastogi, Sumeet Bhargava
- Diffusely Hypodense Liver on NECT 137
  Satish K Bhargava, Rajul Rastogi, Sumeet Bhargava
- Splenomegaly 137
  Sumeet Bhargava
- Splenic Calcification 138
  Rajul Rastogi, Sumeet Bhargava, Satish K Bhargava
- Hyperechoic Splenic Lesion 138
  Rajul Rastogi, Sumeet Bhargava, Satish K Bhargava
- Focal Hypoattenuating Lesions in Spleen 138
  Rajul Rastogi, Sumeet Bhargava, Satish K Bhargava
- Pancreatic Calcification 138
  Rajul Rastogi, Sumeet Bhargava, Satish K Bhargava
- Pancreatic Masses 139
  Satish K Bhargava, Pushpender Gupta, Pardeep Kumar
- Focal Pancreatic Masses 141
  Rajul Rastogi, Sumeet Bhargava, Satish K Bhargava
- Adrenal Mass 142
  Rajul Rastogi, Sumeet Bhargava, Satish K Bhargava
- Adrenal Calcification 142
  Rajul Rastogi, Sumeet Bhargava, Satish K Bhargava
- Extraluminal Intra-abdominal Gas 142
  Rajul Rastogi, Sumeet Bhargava, Satish K Bhargava
- Pneumoperitoneum 143
  Sumeet Bhargava, Anubhav Sarikwal, Shuchi Bhatt
- Pneumoperitoneum 145
  Rajul Rastogi, Sumeet Bhargava, Satish K Bhargava
- Gasless Abdomen 146
  Rajul Rastogi, Sumeet Bhargava, Satish K Bhargava
- Ascites 146
  Rajul Rastogi, Sumeet Bhargava, Satish K Bhargava
- Abdominal Mass in Neonate 147
  Rajul Rastogi, Sumeet Bhargava

JAYPEE BROTHERS

- Abdominal Mass in Child 148
  Sumeet Bhargava, Satish K Bhargava, Rajul Rastogi
- Intestinal Obstruction in Neonate 149
  Sumeet Bhargava, Rajul Rastogi, Satish K Bhargava
- Abnormalities of Bowel Rotation 150
  Sumeet Bhargava, Rajul Rastogi, Satish K Bhargava
- Intra-abdominal Calcification in Neonate 150
  Sumeet Bhargava, Rajul Rastogi, Satish K Bhargava
- Hematemesis 151
  Sumeet Bhargava, Satish K Bhargava, Rajul Rastogi
- Dysphagia in Adults 151
  Sumeet Bhargava, Satish K Bhargava, Rajul Rastogi
- Neonatal Dysphagia 152
  Sumeet Bhargava, Satish K Bhargava, Rajul Rastogi
- Pharyngeal/Esophageal Diverticula 152
  Sumeet Bhargava, Satish K Bhargava, Rajul Rastogi
- Esophagitis/Esophageal Ulcers 153
  Rajul Rastogi, Sumeet Bhargava, Satish K Bhargava
- Esophageal Strictures 155
  Satish K Bhargava, Rajul Rastogi
- Tertiary Contractions in Esophagus 155
  Rajul Rastogi, Sumeet Bhargava, Satish K Bhargava
- Gastric Masses and Filling Defects 156
  Sumeet Bhargava, Satish K Bhargava, Rajul Rastogi
- Linitis Plastica 157
  Rajul Rastogi, Shuchi Bhatt, Sumeet Bhargava
- Gastrocolic Fistula 159
  Rajul Rastogi, Satish K Bhargava
- Retroperitoneal Fibrosis 159
  Sumeet Bhargava, Shuchi Bhatt, Satish K Bhargava
- Mass of Iliopsoas Compartment 160
  Satish K Bhargava, Sumeet Bhargava, Ashish Verma
- Anatomy of Liver, Bile Ducts and Pancreas 161
  Sumeet Bhargava
- Congenital Gallbladder Anomalies 164
  Sumeet Bhargava, Satish K Bhargava
- Inflammatory Bowel Disease 166
  Satish K Bhargava, Pushpender Gupta, Shuchi Bhatt, Pardeep Kumar

6. Skeletal System and Joints 172

- Abnormal Skeletal Maturation 172
  Sumeet Bhargava, Satish K Bhargava, Rajul Rastogi
- Short Limb Skeletal Dysplasia 173
  Satish K Bhargava, Rajul Rastogi, Sumeet Bhargava

JAYPEE BROTHERS

- Short Spine Skeletal Dysplasia 174
  Sumeet Bhargava, Satish K Bhargava, Rajul Rastogi
- Lethal Neonatal Dysplasia 175
  Satish K Bhargava, Rajul Rastogi
- Dumbbell-Shaped Long Bones 175
  Satish K Bhargava, Rajul Rastogi
- Mucopolysaccharidoses and Mucolipidosis 175
  Satish K Bhargava, Rajul Rastogi
- Mucolipidoses 176
  Sumeet Bhargava, Satish K Bhargava, Rajul Rastogi
- Generalized Osteosclerosis 176
  Satish K Bhargava, Rajul Rastogi
- Sclerotic Bone Lesions 176
  Satish K Bhargava, Rajul Rastogi, Sumeet Bhargava
- Bone Sclerosis Associated with Periosteal Reaction 179
  Satish K Bhargava, Rajul Rastogi
- Solitary Sclerotic Lesion with Lucent Center 180
  Satish K Bhargava, Rajul Rastogi
- Coarse Trabecular Pattern of Bone 180
  Satish K Bhargava, Rajul Rastogi
- Characteristics of Metastatic Lesions to the Primary Tumors 180
  Sumeet Bhargava, Satish K Bhargava
- Childhood Tumors Metastasizing to Bone 180
  Satish K Bhargava, Rajul Rastogi
- Bubbly Bone Lesions 180
  Satish K Bhargava, Rajul Rastogi
- Primary Bone Tumors: Clinical Features, Site of Predilection, and Radiologic Presentation 182
  Satish K Bhargava, Rajul Rastogi, Sumeet Bhargava
- Radiologic Characteristics of Benign and Malignant Bone Lesions 182
  Satish K Bhargava, Rajul Rastogi
- Subarticular Lytic Bone Lesion 183
  Satish K Bhargava, Rajul Rastogi, Sumeet Bhargava
- Osteolytic Defects in the Medulla 184
  Satish K Bhargava, Rajul Rastogi
- Lucent Bone Lesion Containing Bone/Calcium 187
  Satish K Bhargava, Rajul Rastogi
- Common Lytic Bone Lesions 188
  Satish K Bhargava, Rajul Rastogi
- Location of Some Common Neoplasms/Lesions 188
  Satish K Bhargava, Rajul Rastogi
- Septated Bone Lesions 189
  Satish K Bhargava, Rajul Rastogi
- Moth-Eaten Bone 189
  Satish K Bhargava, Rajul Rastogi

JAYPEE BROTHERS

- Osteopenia 190
  Satish K Bhargava, Rajul Rastogi
- Periosteal Reactions: Types and Conditions 192
  Sumeet Bhargava, Satish K Bhargava, Rajul Rastogi
- Types of Periosteal Reactions 193
  Satish K Bhargava, Rajul Rastogi
- Periosteal Reaction in Childhood 194
  Satish K Bhargava, Rajul Rastogi
- Hypertrophic Osteoarthropathy 195
  Satish K Bhargava, Rajul Rastogi
- Bone Dysplasias: Associated with Multiple Fractures 196
  Sumeet Bhargava, Satish K Bhargava, Rajul Rastogi
- Excessive Callus Formation 196
  Rajul Rastogi, Sumeet Bhargava, Satish K Bhargava
- Bone within Bone Appearance 196
  Rajul Rastogi, Sumeet Bhargava, Satish K Bhargava
- Fatigue Fractures 196
  Rajul Rastogi, Sumeet Bhargava, Satish K Bhargava
- Pseudoarthrosis 197
  Rajul Rastogi, Sumeet Bhargava, Satish K Bhargava
- Irregular/Stippled Epiphysis 197
  Amit Sahu, Rajul Rastogi, Sumeet Bhargava, Satish K Bhargava
- Avascular Necrosis/Osteonecrosis/Aseptic Necrosis 198
  Rajul Rastogi, Sumeet Bhargava, Satish K Bhargava
- Solitary Radiolucent Metaphyseal Bands 199
  Sumeet Bhargava, Rajul Rastogi, Satish K Bhargava
- Solitary Dense Metaphyseal Band 200
  Rajul Rastogi, Satish K Bhargava
- Alternating Radiolucent/Dense Metaphyseal Bands 200
  Sumeet Bhargava, Rajul Rastogi, Satish K Bhargava
- Dense Vertical Metaphyseal Lines 200
  Rajul Rastogi, Satish K Bhargava
- Frayed Metaphysis 200
  Rajul Rastogi
- Cupping of Metaphysis 200
  Rajul Rastogi, Satish K Bhargava
- Erlenmeyer Flask Deformity 200
  Rajul Rastogi, Sumeet Bhargava, Satish K Bhargava
- Erosion of Medial Metaphyses of Proximal Humerus 201
  Rajul Rastogi, Satish K Bhargava
- Abnormality Related to Clavicles 201
  Rajul Rastogi, Sumeet Bhargava, Satish K Bhargava
- Rib Lesions 201
  Rajul Rastogi, Satish K Bhargava

JAYPEE BROTHERS

- Rib Notching 202
  Rajul Rastogi, Sumeet Bhargava, Satish K Bhargava
- Abnormal Shape, Size, and Density of Ribs 202
  Rajul Rastogi, Sumeet Bhargava, Satish K Bhargava
- Madelung Deformity 202
  Rajul Rastogi, Sumeet Bhargava, Satish K Bhargava
- Carpal Fusion 203
  Rajul Rastogi, Satish K Bhargava
- Abnormal Digits 203
  Rajul Rastogi, Satish K Bhargava
- Abnormal Thumb 204
  Rajul Rastogi, Satish K Bhargava
- Lytic Lesion in Digits 204
  Rajul Rastogi, Satish K Bhargava
- Acro-Osteal Changes 204
  Rajul Rastogi, Sumeet Bhargava, Satish K Bhargava
- Monoarthritis 205
  Rajul Rastogi, Satish K Bhargava
- Arthritis with Periostitis 206
  Rajul Rastogi, Satish K Bhargava
- Arthritis with Demineralization 206
  Rajul Rastogi, Sumeet Bhargava, Satish K Bhargava
- Arthritis without Demineralization 207
  Rajul Rastogi, Sumeet Bhargava, Satish K Bhargava
- Arthritis with Preserved/Widened Joint Space 207
  Rajul Rastogi, Sumeet Bhargava, Satish K Bhargava
- Enlarged Femoral Intercondylar Notch 208
  Rajul Rastogi, Sumeet Bhargava, Satish K Bhargava
- Plantar Calcaneal Spur 208
  Sumeet Bhargava, Rajul Rastogi, Satish K Bhargava
- Chondrocalcinosis 208
  Sumeet Bhargava, Rajul Rastogi, Satish K Bhargava
- Ankylosis of Interphalangeal Joints 208
  Rajul Rastogi, Sumeet Bhargava, Satish K Bhargava
- Enthesiopathy 208
  Rajul Rastogi, Sumeet Bhargava, Satish K Bhargava
- Sacroiliitis 208
  Rajul Rastogi, Satish K Bhargava
- Protrusio Acetabuli 209
  Sumeet Bhargava, Rajul Rastogi, Satish K Bhargava
- Widening of Symphysis Pubis (Diastasis) 210
  Rajul Rastogi, Sumeet Bhargava, Satish K Bhargava
- Fusion of Symphysis Pubis 210
  Rajul Rastogi, Sumeet Bhargava, Satish K Bhargava

JAYPEE BROTHERS

- Radiographic Findings in Degenerative, Inflammatory, and Neuropathic Arthritis 210
  Rajul Rastogi, Satish K Bhargava
- Comparative Features of Seronegative Spondyloarthritides D/D of Dwarfism 210
  Rajul Rastogi, Satish K Bhargava
- Dysplasias 212
  Sumeet Bhargava, Satish K Bhargava
- Thanatophoric Dwarfism 213
  Sumeet Bhargava, Satish K Bhargava
- Mesomelic Dwarfism 213
  Sumeet Bhargava, Satish K Bhargava
- Acromesomelic Dwarfism 213
  Sumeet Bhargava, Satish K Bhargava
- Acromelic Dwarfism 213
  Sumeet Bhargava, Satish K Bhargava
- Sclerotic Lesions of Bone 214
  Ashish Verma, Sumeet Bhargava
- Lytic Lesions in Bone 217
  Satish K Bhargava, Shuchi Bhatt
- Differential Diagnosis of Generalized Osteoporosis 222
  Sumeet Bhargava, Satish K Bhargava
- Solitary Dense Vertebra 225
  Pushpender Gupta, Satish K Bhargava
- Acro-Osteolysis 226
  Vinita Rathi, Sumeet Bhargava
- Sacroiliitis 227
  Satish K Bhargava
- Arthritis Involving Spinal Column 228
  Sumeet Bhargava, Satish K Bhargava
- Bone Cyst 230
  Satish K Bhargava, Anubhav Sarikwal

7. Urogenital System 235

- Adult and Neonatal Kidney: Differences 235
  Sumeet Bhargava, Satish K Bhargava
- Smooth and Small Kidneys 235
  Rajul Rastogi, Satish K Bhargava
- Small, Smooth, and Unilateral Kidneys 235
  Sumeet Bhargava, Satish K Bhargava
- Small, Smooth, and Bilateral Kidneys 237
  Sumeet Bhargava, Satish K Bhargava
- Small and Smooth Kidneys 237
  Shuchi Bhatt, Ashish Verma

JAYPEE BROTHERS

- Small and Smooth Kidneys 239
  Sumeet Bhargava, Satish K Bhargava
- Small and Irregular Kidneys 239
  Satish K Bhargava, Rajul Rastogi
- Large and Smooth Kidneys 241
  Sumeet Bhargava, Rajul Rastogi, Satish K Bhargava
- Bilateral Large Smooth Kidneys 243
  Sumeet Bhargava, Satish K Bhargava
- Extraskeletal Features 244
  Sumeet Bhargava, Satish K Bhargava
- Leukemia 245
  Sumeet Bhargava, Satish K Bhargava
- Acute Interstitial Nephritis 245
  Sumeet Bhargava, Satish K Bhargava
- Autosomal Recessive (Infantile) Polycystic Kidney Disease 245
  Sumeet Bhargava, Satish K Bhargava
- Nephromegaly Associated with Cirrhosis, Hyperalimentation, and Diabetes Mellitus 246
  Sumeet Bhargava, Satish K Bhargava
- Nonvisualization of a Kidney during Excretion Urography 246
  Satish K Bhargava
- Dilated Calyx and Dilated Ureter 249
  Amit Sahu, Pardeep Kumar, Shuchi Bhatt
- Dilated Ureter and Calyces 249
  Sumeet Bhargava, Satish K Bhargava
- Dilated Calyx 250
  Sumeet Bhargava, Satish K Bhargava
- Gas in Urinary Tract 252
  Satish K Bhargava, Sumeet Bhargava
- Loss of Renal Outline on Plain Film 252
  Sumeet Bhargava, Satish K Bhargava
- Renovascular Hypertension 254
  Sumeet Bhargava
- Renal Calcification 255
  Sumeet Bhargava, Satish K Bhargava
- Renal Mass 257
  Sumeet Bhargava, Satish K Bhargava, Pushpender Gupta
- Abscess Typical Imaging Features 262
  Sumeet Bhargava, Satish K Bhargava
- Cystic Disease of Kidneys 262
  Sumeet Bhargava, Satish K Bhargava
- Carcinoma of the Bladder 266
  Rajul Rastogi, Sumeet Bhargava, Satish K Bhargava

JAYPEE BROTHERS

- Bladder Outflow Obstruction 267
  Rajul Rastogi, Shuchi Bhatt
- Testicular Tumors 271
  Rajul Rastogi, Shuchi Bhatt
- Seminal Vesicle Calcification 273
  Anubhav Sarikwal, Satish K Bhargava
- Differential Diagnosis of Abnormal Nephrograms 274
  Sumeet Bhargava, Mamta Motla, Shuchi Bhatt
- Filling Defect in the Bladder 274
  Mamta Motla, Satish K Bhargava
- Carcinoma Prostate 274
  Satish K Bhargava, Anubhav Sarikwal
- The Prostate 279
  Sumeet Bhargava, Shuchi Bhatt
- Differential Diagnosis of Adrenal Mass 282
  Sumeet Bhargava, Satish K Bhargava
- Painless Hematuria 284
  Satish K Bhargava, Ashish Verma

8. Head, Neck, and Spine 287

- Lucency in the Skull Vault: Without Sclerosis 287
  Sumeet Bhargava, Satish K Bhargava
- Lucency in the Skull Vault: With Surrounding Sclerosis 288
  Sumeet Bhargava, Satish K Bhargava
- Thickening of the Skull Vault 289
  Vinita Rathi, Sumeet Bhargava
- Generalized Increase in Density of Skull Vault 290
  Sumeet Bhargava, Satish K Bhargava
- Metabolic 291
  Sumeet Bhargava, Satish K Bhargava
- Localized Increase in Density of the Skull Vault 292
  Sumeet Bhargava, Satish K Bhargava
- Destruction of Petrous Bone (Apex) 293
  Sumeet Bhargava, Satish K Bhargava
- Basilar Invagination 294
  Sumeet Bhargava, Satish K Bhargava
- Hair on End Skull Vault 295
  Rajul Rastogi, Satish K Bhargava
- Multiple Wormian Bones 296
  Sumeet Bhargava, Satish K Bhargava
- Posterior Fossa Cysts and Cysts-like Masses 297
  Sumeet Bhargava, Satish K Bhargava
- Enlarged Sylvian Fissure/Midline Cranial Fossa of CSF Density 297
  Sumeet Bhargava, Amit Sahu, Satish K Bhargava

JAYPEE BROTHERS

- Skull Base and Cavernous Sinus 298
  Sumeet Bhargava, Satish K Bhargava
- Central Skull Base Lesions 300
  Sumeet Bhargava, Satish K Bhargava
- Cerebellopontine Angle Masses 301
  Sumeet Bhargava, Amit Sahu, Satish K Bhargava
- Suprasellar Mass 303
  Sumeet Bhargava, Satish K Bhargava
- Sellar and Suprasellar Masses 305
  Sumeet Bhargava, Satish K Bhargava
- Pituitary Apoplexy 306
  Sumeet Bhargava, Satish K Bhargava
- Aneurysm 307
  Sumeet Bhargava, Satish K Bhargava
- Rathke's Cleft Cyst 307
  Sumeet Bhargava, Satish K Bhargava
- Arachnoid Cyst 307
  Sumeet Bhargava, Satish K Bhargava
- Epidermoid and Dermoid 307
  Sumeet Bhargava, Satish K Bhargava
- Teratoma 308
  Sumeet Bhargava, Satish K Bhargava
- Germinoma (Atypical Teratoma) 308
  Sumeet Bhargava, Satish K Bhargava
- Visual Pathway Glioma 308
  Sumeet Bhargava, Satish K Bhargava
- Chordoma 308
  Sumeet Bhargava, Satish K Bhargava
- Neurosurgeon's Queries 308
  Sumeet Bhargava, Satish K Bhargava
- Expanded Pituitary Fossa 308
  Sumeet Bhargava, Satish K Bhargava
- Ring Enhancing Lesions on Contrast-enhanced Computed Tomography 310
  Sumeet Bhargava, Satish K Bhargava
- Superior Orbital Fissure Enlargement 311
  Sumeet Bhargava, Satish K Bhargava
- Neoplasm 313
  Sumeet Bhargava, Satish K Bhargava
- Temporal Bone Sclerosis 314
  Sumeet Bhargava, Satish K Bhargava
- Intervertebral Disk Space Calcification 316
  Satish K Bhargava, Sumeet Bhargava
- Ivory Vertebral Body 317
  Sumeet Bhargava, Satish K Bhargava

JAYPEE BROTHERS

- Atlantoaxial Subluxation 318
  Sumeet Bhargava, Satish K Bhargava
- Posterior Scalloping of Vertebral Body 318
  Sumeet Bhargava, Satish K Bhargava
- Anterior Scalloping of Vertebral Bodies 319
  Sumeet Bhargava, Satish K Bhargava
- Anterior Vertebral Body Beaks 320
  Sumeet Bhargava, Satish K Bhargava
- Block Vertebra 321
  Sumeet Bhargava, Satish K Bhargava
- Enlarged Vertebral Body 322
  Sumeet Bhargava, Satish K Bhargava
- Solitary Collapsed Vertebra 322
  Sumeet Bhargava, Satish K Bhargava
- Multiple Collapsed Vertebrae 323
  Sumeet Bhargava, Satish K Bhargava
- Intraspinal Masses 325
  Sumeet Bhargava, Satish K Bhargava
- Differential Diagnosis of Posterior Fossa Cysts 327
  Sumeet Bhargava, Satish K Bhargava
- Enlarged Optic Foramen 328
  Pardeep Kumar, Satish K Bhargava, Rajul Rastogi
- Bare Orbit/Hypoplasia of Greater Wing of Sphenoid 329
  Rajul Rastogi, Shuchi Bhatt
- Orbital Hyperostosis 331
  Rajul Rastogi, Sumeet Bhargava
- Cephaloceles 332
  Sumeet Bhargava, Satish K Bhargava
- Pathological Intracranial Calcification 333
  Rajul Rastogi, Shuchi Bhatt
- Vascular Lesions 335
  Sumeet Bhargava, Satish K Bhargava
- J-Shaped Sella 336
  Sumeet Bhargava
- Cerebellar Malformations 338
  Pardeep Kumar, Satish K Bhargava
- Demyelinating Disorders 339
  Amit Sahu, Anubhav Sarikwal, Satish K Bhargava
- Demyelination 339
  Sumeet Bhargava, Satish K Bhargava
- Infectious 340
  Sumeet Bhargava, Satish K Bhargava
- Human Immunodeficiency Virus Encephalopathy 341
  Sumeet Bhargava, Satish K Bhargava

JAYPEE BROTHERS

- Dysmyelination (Leukodystrophies) 342
  Sumeet Bhargava, Satish K Bhargava
- MELAS Syndrome 344
  Sumeet Bhargava, Satish K Bhargava
- MERRF Syndrome 344
  Sumeet Bhargava, Satish K Bhargava
- Leukodystrophies: Distinctive Features 344
  Sumeet Bhargava, Satish K Bhargava
- Prevertebral Soft Tissue Thickening 344
  Sumeet Bhargava, Satish K Bhargava
- Nasopharyngeal Masses 346
  Sumeet Bhargava, Satish K Bhargava
- Laryngeal Masses 348
  Satish K Bhargava, Anubhav Sarikwal
- Orbital Masses 349
  Rajul Rastogi, Satish K Bhargava
- Cavernous Hemangioma (Encapsulated Venous Malformation) 351
  Sumeet Bhargava, Satish K Bhargava
- Metastatic Tumors 351
  Sumeet Bhargava, Satish K Bhargava
- Miscellaneous 351
  Sumeet Bhargava, Satish K Bhargava
- Orbital Pseudotumor (Idiopathic Orbital Inflammation) 352
  Sumeet Bhargava, Satish K Bhargava
- Ocular Masses 353
  Sumeet Bhargava, Satish K Bhargava
- Intraorbital Calcification 353
  Sumeet Bhargava, Satish K Bhargava
- Inner Ear Masses 355
  Sumeet Bhargava, Satish K Bhargava
- Methods of Imaging 356
  Sumeet Bhargava, Satish K Bhargava
- Middle Ear Masses 357
  Sumeet Bhargava, Satish K Bhargava
- External Acoustic Masses 359
  Rajul Rastogi, Sumeet Bhargava, Satish K Bhargava
- Intramedullary Lesions 361
  Sumeet Bhargava, Amit Sahu, Rajeev Chaturvedi, Satish K Bhargava
- Intradural Extramedullary Masses 363
  Satish K Bhargava, Pushpender Gupta
- Extradural Extramedullary Lesion 366
  Rajul Rastogi, Shuchi Bhatt
- Differential Diagnosis of Floating Tooth 369
  Sumeet Bhargava, Satish K Bhargava .....

JAYPEE BROTHERS

- Cysts of Jaw 371
  Sumeet Bhargava, Ashish Verma, Satish K Bhargava
- Loss of Lamina Dura of Teeth 372
  Rajul Rastogi, Vinita Rathi
- Opaque Maxillary Antrum 375
  Rajul Rastogi, Satish K Bhargava
- Thyroid Lesions 376
  Rajul Rastogi, Shuchi Bhatt
- Decreased or No Uptake of Radiotracer 380
  Sumeet Bhargava, Satish K Bhargava

9. Obstetrics and Gynecology 383

- Ultrasound Characteristics of Abnormal Gestation Sac 383
  Sumeet Bhargava, Satish K Bhargava
- Differential Diagnosis between Blighted Ovum and Pseudogestation of Ectopic Pregnancy 383
  OP Sharma
- Differential Diagnosis between Ectopic Pregnancy, Abortion in Progress (Early Gestation) and Nabothian Cysts 383
  OP Sharma
- Differential Diagnosis between Partial Mole, Intrauterine Fetal Death with Hydropic Placental Degeneration, and Twin Pregnancy (Mole and Fetus) 384
  OP Sharma
- Differential Diagnosis between Pelvic Masses, Extruded Fetal Parts with Uterine Perforation and Ectopic Pregnancy (Postpartum/Intervention) 384
  OP Sharma, Rajul Rastogi
- Differential Diagnosis of a Presacral Fetal Mass 384
  OP Sharma, Rajul Rastogi
- Fetal Neck Masses 386
  OP Sharma, Rajul Rastogi
- Differential Diagnosis of Fetal Renal Cystic Diseases 386
  OP Sharma, Rajul Rastogi
- Differential Diagnosis of various Fetal Anterior Abdominal Wall Defects 386
  OP Sharma
- Differential Diagnosis between Renal Cysts and Hydronephrosis 386
  OP Sharma, Rajul Rastogi
- Differential Diagnosis of Cystic Adnexal Masses 386
  OP Sharma, Rajul Rastogi
- Differential Diagnosis of Ovarian Masses 388
  Ashish Verma, Sumeet Bhargava, Satish K Bhargava
- Differential Diagnosis of Benign and Malignant Ovarian Masses 388
  OP Sharma

JAYPEE BROTHERS

- Differential Diagnosis of Cystic Abdominal Masses 388
  OP Sharma
- Differential Diagnosis of Non-gynecological Pelvic Lesions 389
  Ashish Verma, Sumeet Bhargava, Satish K Bhargava
- Differential Diagnosis of Postoperative Pelvic Mass 389
  Sumeet Bhargava, Satish K Bhargava
- Differential Diagnosis of Ovarian Adnexal Mass 390
  Sumeet Bhargava, Satish K Bhargava
- Differential Diagnosis of Ovarian Adnexal Mass of Ovarian Masses 390
  Sumeet Bhargava, Satish K Bhargava
- Sonographic Classification of Adnexal Masses 391
  Ashish Verma, Sumeet Bhargava, Satish K Bhargava
- Absent Intrauterine Pregnancy with Positive Pregnancy Test 392
  Ashish Verma, Sumeet Bhargava, Satish K Bhargava, Rajul Rastogi
- Differential Diagnosis of Thickened Placenta 393
  Ashish Verma, Sumeet Bhargava, Satish K Bhargava, Rajul Rastogi
- Ultrasound Signs of Chromosomal Abnormality 394
  Ashish Verma, Sumeet Bhargava, Satish K Bhargava, Rajul Rastogi
- Differential Diagnosis of Enlarged Uterus 396
  Ashish Verma, Sumeet Bhargava, Satish K Bhargava, Rajul Rastogi
- Cystic Structures in Fetal Abdomen 396
  Satish K Bhargava, Sumeet Bhargava, Ashish Verma, Rajul Rastogi
- Differential Diagnosis of Fetal Hydrops 397
  Satish K Bhargava, Sumeet Bhargava, Ashish Verma, Rajul Rastogi
- Differential Diagnosis of Fetal Brain and Head Abnormalities 398
  Satish K Bhargava, Ashish Verma, Rajul Rastogi, Sumeet Bhargava
- Differential Diagnosis of Brain and Head Abnormality 399
  Satish K Bhargava, Ashish Verma, Rajul Rastogi, Sumeet Bhargava
- Differential Diagnosis of Thickened Endometrium 400
  Sumeet Bhargava, Satish K Bhargava, Ashish Verma
- USG Signs in Abortions/Miscarriage 401
  Satish K Bhargava, Ashish Verma
- Differential Diagnosis of Fetal Causes of Abnormality in Liquor Volume 402
  Satish K Bhargava, Ashish Verma
- Differential Diagnosis of Gas in the Genital Tract 404
  Satish K Bhargava, Ashish Verma
- Differential Diagnosis of Fetal Intra-abdominal Calcification 405
  Satish K Bhargava, Ashish Verma
- Differential Diagnosis of Fetal Thoracic Abnormalities 406
  Satish K Bhargava, Ashish Verma

Index 409

JAYPEE BROTHERS

Chapter 4

Soft Tissue Lesions

DIFFERENTIAL DIAGNOSIS OF SOFT TISSUE LESIONS

Increased Heel Pad Thickness or Heel Pad Sign (Flowchart 4.1)

- Normal < 21 mm
- Males > 23 mm
- Females > 21.5 mm.

Acromegaly

- Osseous enlargement, flared ends of long bones.
- Spade-like hands, widening of terminal tufts, prognathism, enlargement of paranasal sinuses, sellar enlargement.
- Posterior scalloping of vertebrae.

Myxedema

- Clinical features—fatigue, lethargy, constipation, cold intolerance, stiffening of muscles.
- Dull, expressionless facies, periorbital puffiness.
  - Calvarial thickening, wedging of dorsolumbar vertebrae, coxa vara.

Peripheral Edema

- Edema due to any reason will increase the heel pad thickness (Fig. 4.1).

Obesity

- Especially in children—heel pad is thick, because of fat deposition.

Epanutin Eptoin Therapy

- Erythematous eruptions, gingival hyperplasia may occur.

Infection/Injury

- Due to pus collection or hematoma formation, heel pad thickness may be increased.
- Increased heel pad thickness.

Mnemonic: MADCOP

- **M:** myxedema
- **A:** acromegaly
- **D:** phenytoin therapy
- **C:** callus
- **O:** obesity
- **P:** peripheral edema.

Flowchart 4.1: Increased heel pad thickness.

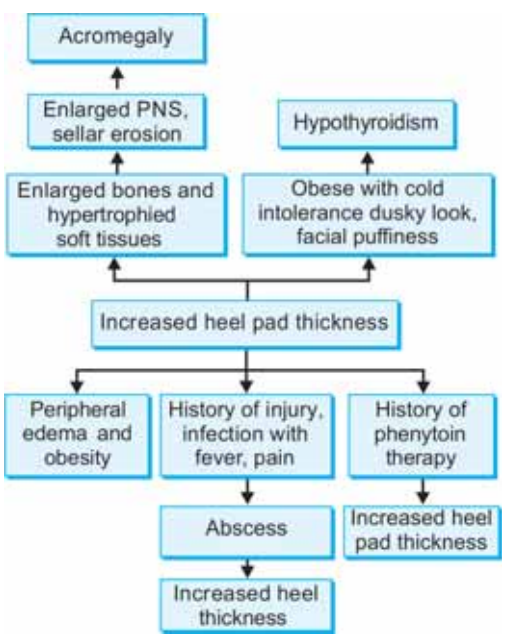

(PNS: Peripheral nervous system)

JAYPEE BROTHERS



Fig. 4.1: Heel pad thickness is measured as shortest perpendicular distance from the lowest point of the calcaneal tuberosity to the plantar surface.

SOFT TISSUE OSSIFICATION

Leading to Formation of Trabecular Bone

- Myositis ossificans
- Burns
- Paraplegia
- Liposarcoma
- Parosteal osteosarcoma
- Congenital myositis ossificans progressiva
- Tumoral calcinosis
- Surgical scar.

Myositis Ossificans

- Benign solitary self-limiting ossifying soft tissue mass typically occurring in skeletal muscle
- Adolescents, young athletic adults
- Located in large muscles of extremities in 80%
- Well-defined partially ossified soft tissue mass after 6–8 weeks
- Radiolucent zone separating lesion from bone
- Periphery more denser than center.

Liposarcoma

- Second most common soft tissue sarcoma in adults
- Age: 5th-6th decade
- Usually painless, mass located in trunk, lower extremity–upper extremity, head and neck
- Amorphous calcification.

Parosteal Osteosarcoma

- Large lobulated cauliflower-like homogeneous ossific mass extending away from cortex
- Large soft tissue component with osseous and cartilaginous elements
- Periphery is less dense than center
- Located commonly at posterior aspect of distal femur, either end of tibia, proximal humerus and fibula.

Burns

- Ossification in relation to joints, commonly hips, elbows and shoulders
- May occur at sites distal to injury
- The cause is unknown.

Paraplegia

- Occurs in adults with spinal lesions and children with spinal dysraphism
- Particularly in relation to pelvis
- Woolly appearance.

Congenital Myositis Ossificans Progressiva

- Autosomal dominant or primary mutation
- Ossification in perimuscular fascia, not in muscles
- Sheets of bone in neck, thorax, and limb
- Abnormally short metacarpal of thumb and metatarsal of big toe.

Tumoral Calcinosis

- Masses of bones in soft tissue near joints
- May cause discomfort and limitation of movement.

Surgical Scar

- True bone may form away from any preexisting bone structure or periosteum.

JAYPEE BROTHERS

LINEAR CALCIFICATION OF SOFT TISSUES

Arterial

- Diabetes
  - Occurs commonly in calf-region
  - Associated diabetic nephropathy or cystopathy.
- Hyperparathyroidism
  - Calcification in arterial tunica media
  - Cornea, vessels, and periarticular region
  - Chondrocalcinosis
  - Associated bone erosions, brown tumors.
- Werner's syndrome
- Atheroma (Fig. 4.2)
  - Plaque-like calcification, linear calcification of walls.
  - Commonly femoral and popliteal arteries.

Venous

- Thrombosed veins
  - Phleboliths are present.
- Varicose veins.

Nerves

- Leprosy
  - Areas of calcification, reticulated pattern.
  - Joint space preserved.
  - Absorption of nasal spine, alveolar ridge.
  - Neurotrophic joints.
- Neurofibromatosis
  - Soft tissue masses.
  - Optic nerve gliomas.
  - Ribbon ribs, sphenoid dysplasia, and pseudoarthrosis.

Ligamentous (Fig. 4.3)

- Tendinitis
  - Pellegrini-Stieda lesion—calcification of medial collateral ligament of knee.
- Ankylosing spondylitis (Fig. 4.4)
  - Posterior longitudinal/anterior longitudinal ligament calcification.
- Fluorosis (Figs 4.5 and 4.6)
  - Sacrotuberous and sacrospinous ligamentous calcification, increased bone density
  - Interosseous membrane calcification.
- Alkaptonuria
  - Calcification in paravertebral soft tissues and tendon insertion
  - Disk calcification
  - Massive osteophytosis.

JAYPEE BROTHERS

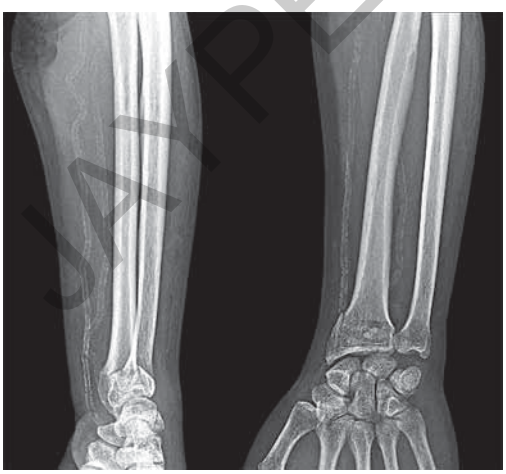

Fig. 4.2: Anteroposterior and lateral radiographs of forearm show arterial calcification.



Fig. 4.3: Anteroposterior radiograph of ankle shows soft tissue ligamentous calcification adjacent to lateral malleolus.

PARASITIC CALCIFICATION (TABLE 4.1)

Cysticercus Cellulosae (Figs. 4.7 and 4.8)

- Calcified cysts produce oval shadow 10–15 mm long and 2–3 mm broad with a translucent center
- Number of cysts usually in hundreds
- Arranged in direction of muscle fibers
- May be associated with cysts in brain.



Fig. 4.4: Lateral radiograph of dorsolumbar (DL) spine in ankylosing spondylitis shows anterior longitudinal ligament calcification.

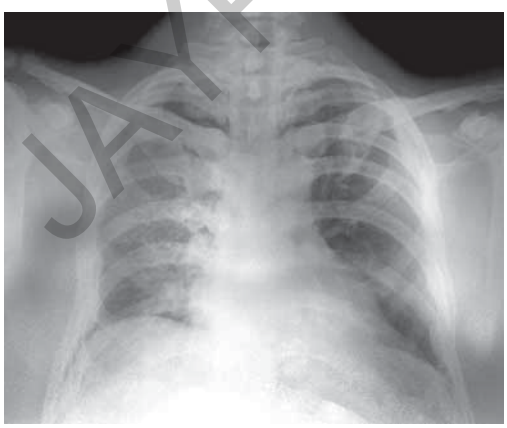

Fig. 4.5: Posteroanterior radiograph of chest shows diffuse osteosclerosis in fluorosis.



Fig. 4.6: Anteroposterior radiograph of pelvis shows calcification in bilateral sacrotuberous ligament and osteosclerosis of lower lumbar spine in fluorosis.

Loiasis (Calabar Swelling)

- Caused by microfilaria
- Found in subcutaneous tissues and undergoes calcification after death
- Commonly in hands, in web spaces
- Coiled thread-like opacities with amorphous calcification.

Guinea Worm

- Calcifies after its death.
- Elongated or coiled strip of calcium density.
- May be crushed by muscle action into a round irregular mass.

Armillifer Armillatus

- Curved in one plane (comma-shaped)
- Chest and abdomen.

AREAS OF DECREASED DENSITY

Fat

- Lipomas
- Normal sites
  - In front of lower end of humerus, below patella (Fig. 4.9), in front of Achilles tendon.
- Lipohemarthrosis
  - Following fractures
  - Particularly around knees and shoulders.

JAYPEE BROTHERS

Table 4.1: Periarticular soft tissue calcification.

Features	*Gout*	*Sarcoidosis*	*Secondary HPT*	*Hyper-vitaminosis D*	*Synovial osteochondro-matosis*	*Synovioma*
Age	> 40 years	20–40 years	–	–	20–50 years	20–50 years
Type of calcification	Large nodular calcification in gouty tophi	–	Periarticular, arterial walls, chondrocalci-nosis, viscera	Metastatic calcinosis in periarticular areas—putty-like premature falx calcification	Multiple calcified bodies	Large sphenoid well-defined soft tissue mass with amorphous calcification
Site	Hands and feet, 1st MTP most common ear > bones, tendons and bursae	Small bones of hands and feet	Around hip, knee, shoulder, wrist	Periarticular + arterial walls + nephrocalcinosis	Large joints knee > elbow > hip > shoulder > ankle	Knee most common, hip ankle, elbow, wrist, hands, feet
Bone changes	Punched out lytic bone lesions, mouse bite erosions with overhanging margins joint space is preserved	Reticulated lace- like trabecular pattern in middle and distal phalanges with cystic lesions acro-osteolysis	Osteosclerosis, especially axial skeleton, pelvis, ribs, clavicles, Rugger-Jersey spine	Cortical + trabecular dense calvaria widening of provisional zone of calcification	Pressure erosion of bone or secondary degenerative changes widening of joint space and accumulation of loose bodies	Periosteal reaction, bone remodeling due to pressure invasion of cortex and juxta-articular osteopenia
For	Dermatomyositis Scleroderma Tumoral Calcinosis	} Refer to generalized calcinosis.				

(HPT: Hyperparathyroidism; MTP: Metatarsophalangeal)

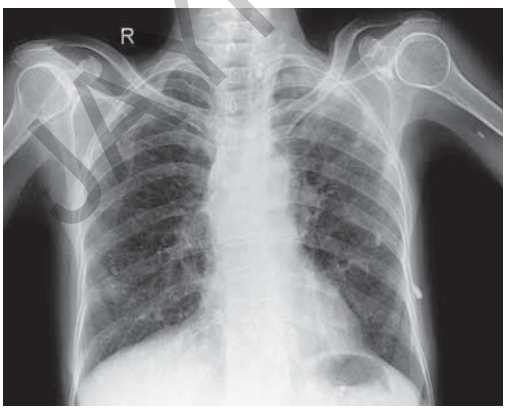

Fig. 4.7: Posteroanterior radiograph of chest shows multiple oval calcifications in soft tissues in cysticercosis.



Fig. 4.8: Lateral radiograph of skull shows multiple calcified lesions in neurocysticercosis.

JAYPEE BROTHERS



Fig. 4.9: Lateral radiograph of knee joint shows infrapatellar lipoma.



Fig. 4.10: Anteroposterior radiograph of foot shows aeroceles in soft tissues in gas gangrene.

Gas

- Hernias
  - Containing intestine
  - Seen below inguinal ligament or in scrotum.
- Air entering from outside
  - Air bubbles near compound fractures.
  - Fractures of peripheral nervous system (PNS)—air in facial soft tissues.
  - Soft tissues of chest from lungs—after rib fractures, laceration of lung, thoracocentesis or after surgery.
  - From mediastinum.
- Lower abdominal wall or thigh—following rupture of pelvic abscess or after perforation of a hollow viscus.
- Gas formed in tissues (Figs. 4.10 and 4.11)
  - Infection in diabetes, by *Clostridium welchii.*
  - Anerobic myositis.



Fig. 4.11: Anteroposterior radiograph of abdomen shows aeroceles with air fluid level in right lumbar region in right paracolic abscess.

PERIARTICULAR SOFT TISSUE CALCIFICATION

Inflammatory

- Scleroderma
- Dermatomyositis
- Gout.

Degenerative

- Calcium pyrophosphate dihydrate deposition disease.

Renal Failure

- Secondary hyperparathyroidism.

JAYPEE BROTHERS

Table 4.2: Sheet-like calcification.

Features	*Congenital myositis ossificans progressiva*	*Dermatomyositis*
Type	Autosomal dominant	Inflammatory myopathy
Calcification	In perimuscular fascia and not in muscles	Necrosis, fibrosis and calcification in muscles
Parts commonly affected	Sheets of bone in neck, thorax and limbs	Extremities, elbows, knees, hands abdominal wall and chest wall
Age	Early childhood	5–15 years and 50–60 years
Bone changes	Short metacarpal of thumb and metatarsal of big toe + abnormality of vertebrae	Pointing and resorption of terminal tufts

Hypercalcemia

- Sarcoidosis
- Hypervitaminosis D
- Milk alkali syndrome.

Neoplastic

- Synovial osteochondromatosis
- Synovioma.

Idiopathic

- Tumoral calcinosis.

GENERALIZED CALCINOSIS

- Collagen vascular disorders
  - Scleroderma
  - Dermatomyositis
- Idiopathic tumoral calcinosis
- Idiopathic calcinosis universalis.

Scleroderma

- Calcinosis of skin
- Raynaud's phenomenon
- Esophageal dysmotility
- Sclerodactyly
- Telangiectasia.

Dermatomyositis

Inflammatory myopathy with linear and confluent calcifications in soft tissues.

- Pointing and resorption of terminal tufts
- Respiratory muscle weakness
- Dysphagia.

Idiopathic Tumoral Calcinosis

- Progressive large nodular juxta-articular calcified soft tissue masses
- Normal serum calcium and phosphorus and no metabolic/renal or collagen disease
- Diaphyseal periosteal reaction with patchy areas of calcification in medullary cavity
- Calcinosis cutis.

Idiopathic Calcinosis Universalis

- Children and young adults
- Plaque-like calcium deposits in skin and subcutaneous tissues
- Sometimes in tendons and muscles
- No true bone formation.

SHEET-LIKE CALCIFICATION IN SOFT TISSUE (TABLE 4.2)

- Congenital myositis ossificans progressiva.
- Dermatomyositis.

JAYPEE BROTHERS

for detailed information on radiology books, visit our website www.jaypeebrothers.com, for detailed information on radiolo

Differential Diagnosis in RADIOLOGY

With a lot of appreciation and an ever-increasing demand from the radiologists, practicing physicians and postgraduate students from India and abroad, a large number of figures and texts have been added to provide a concise, handy and clear reference, and in-depth knowledge of the various radiographs in terms of salient features of the various disease entities to arrive at a correct diagnosis. This will definitely help the physicians, surgeons and radiologists in their day-to-day practice and the residents for their systematic approach to arrive at a correct diagnosis.

Sumeet Bhargava MBBS DNB (Radiodiagnosis) FCGP FIAMS FICRI FIMSA MNAMS was awarded honors and gold medals in various subjects during his MBBS studies. He was trained at Diwan Chand Satyapal Aggarwal Imaging Center, Rajiv Gandhi Super Specialty Hospital, All India Institute of Medical Sciences (AIIMS), University College of Medical Sciences (UCMS), and GTB Hospital, New Delhi, India. He has published 35 research papers, both in the national and international journals, besides contributing many chapters in the textbooks. He is a life member of National Academy Sciences (NAMS) and International Medical Science Academy (IMSA). He has been conferred with Dr N Ram Das Best Research Paper Award of Indian College of Radiology and Imaging, 2009. Due to his extensive academic contribution, he has been awarded Fellowship of the College of General Practitioners, 2010; M/s German Remedies Travelling Fellowship in Radiodiagnosis and Imaging of the Institute of Clinical Research (ICRI), 2011; Fellowship of Indian College of Radiology and Imaging and Fellowship of IMA Academy of Medical Specialties, 2001.

Satish K Bhargava MD (Radiodiagnosis) MD (Radiotherapy) DMRD FICRI FIAMS FCCP FUSI FIMSA FAMS was Head, Department of Radiology and Imaging at School of Medical Sciences and Research, and Sharda Hospital, Sharda University, Greater Noida, Uttar Pradesh, India; and was Head, Department of Radiology at University College of Medical Sciences (Delhi University), New Delhi and JN Medical College, Aligarh Muslim University, Aligarh. He was an advisor to the set-up of the Department of Radiology at BP Koirala Institute of Health Sciences (BPKIHS), Dharan, Nepal. He has also established the Department of Radiology at UCMS, New Delhi. Professor Bhargava has not only authored many textbooks and contributed more than 325 research papers in various national and international journals, but also he has been an excellent teacher. Due to his wide academic contribution, he has been awarded Sir JC Bose Memorial Oration Award, Distinguished Medical Teachers Award, BC Roy Award, Brig SK Majumdar Oration Award, Swami Vivekanand Oration Award, Prithvinath Bhargava Memorial Oration Award, GEMS International Award, and Excellent Teacher Award by National Board of Examination, Ministry of Health and Family Welfare, Government of India. He has also served as the Chairman, Board of Research Studies (University of Delhi), Delhi. Dr Bhargava has uniquely contributed in the field of medical sciences in his Hindi books such as *Vikiran Vigyan* and *Cancer ke Tathya*. In recognition of his contribution for his books in Hindi, he has been awarded Maulik Hindi Pustak Puraskar by the Ministry of Health and Family Welfare, Government of India. He has served as the Secretary as well as the Chairman of the Indian College of Radiology and Imaging and was also the National President of the Indian Radiological and Imaging Association.

Available at all medical bookstores
or buy online at www.jaypeebrothers.com



JAYPEE BROTHERS
Medical Publishers (P) Ltd.
www.jaypeebrothers.com

Join us on facebook.com/JaypeeMedicalPublishers

Shelving Recommendation
RADIOLOGY

