aypeebrothers.com, for detailed information on dermatology books, visit our website www.jaypeebrothers.com, for detailed information on dermatology books, visit our website www.jaypeebrothers.com

Get Full Access
with added features at
emedicine360.com



Moschella & Hurley's

OGY

Volume 2

H EDITION

Editor

ar K Rao



aypeebrothers.com, for detailed information on dermatology books, visit our website www.jaypeebrothers.com, for detailed information on dermatology books, visit our website www.jaypeebrothers.com

Get Full Access
with added features at
emedicine360.com



Moschella & Hurley's

DERMATOLOGY

Volume 1



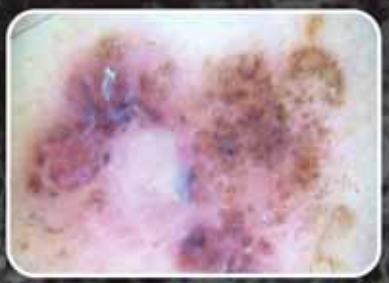

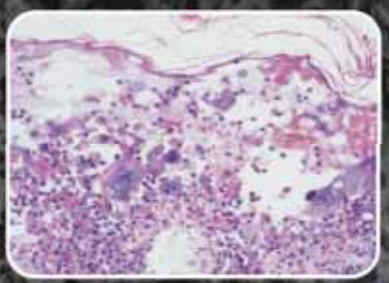

FOURTH EDITION

Editor

Babar K Rao



Moschella and Hurley's Dermatology

Fourth Edition

Volume 1

Editor

Babar K Rao MD FAAD
Director and Professor
Center for Dermatology
Department of Pathology
Rutgers Robert Wood Johnson Medical School
New Brunswick, NJ, USA

Adjunct Clinical Associate Professor
Department of Dermatology
Weill Cornell Medicine
New York, NY, USA

JAYPEE BROTHERS

JAYPEE BROTHERS MEDICAL PUBLISHERS
The Health Sciences Publisher
New Delhi | London

Contents

Volume 1

SECTION 1: BASIC SCIENCES

1. **Structure and Function of Skin Development, Morphology, and Physiology** 3
   Animesh A Sinha, John Hassani, Alison Treichel, Thomas W Chu
2. **Immunology** 37
   Animesh A Sinha, Carlos Linares, Alba Posligua, Tinatin Kiguradze

SECTION 2: PRINCIPLES OF CLINICAL DIAGNOSIS

3. **Clinical Reaction Patterns** 57
   Frank C Victor, Susan Burgin
4. **Principles of Dermoscopy** 60
   Stefano Caccavale, Amalia Lupoli, Vincenzo Piccolo, Teresa Russo, Giuseppe Argenziano
5. **Principles of Non-invasive Diagnostic Techniques in Dermatology** 75
   Cristian Navarrete-Dechent, Cristian Fischer, Eric Tkaczyk, Manu Jain

SECTION 3: DERMATOPATHOLOGY

6. **Laboratory Techniques for Dermatopathology** 97
   Rita N Sokkar, Manuel Valdebran, Michele Van Hal, Jisun Cha
7. **Fundamentals of Dermatopathology** 112
   Robert Duffy, Robin Burger, Amira Elbendary, Manuel Valdebran, Jisun Cha
8. **Dermatopathology: An Approach to Skin Inflammation** 125
   Attiya Haroon, Babar K Rao

SECTION 4: DISORDERS OF IMMUNITY, HYPERSENSITIVITY AND INFLAMMATION

9. **Anaphylaxis and Angioedema** 141
   Margitta Worm, Linus Grabenhenrich, Sabine Dölle, Paola Chamorro
10. **Urticaria** 152
    Anuradha Bishnoi, Davinder Parsad
11. **Transplant Dermatology** 165
    Nicole Reusser Bender, Edit Olasz-Harken
12. **Graft-versus-host Disease** 177
    Ann M John, Babar K Rao
13. **Immunodeficiency Syndromes (except HIV)** 184
    Danielle Tartar

JAYPEE BROTHERS

14. Granulomatous Diseases 200
Julia A Benedetti

15. Low-dose Cytokine Therapy in Dermatology 213
Torello Lotti

SECTION 5: DRUG REACTIONS

16. Drug Eruptions 221
Megan P Couvillion, Virginia A Tracey, Bradley Saylors, Larry Millikan, Erin Boh

17. Erythema Multiforme, Stevens-Johnson Syndrome and Toxic Epidermal Necrolysis 232
Christina M Ring, Robert A Schwartz

18. Erythroderma 247
Sandipan Dhar, Amrinder Jit Kanwar

19. Figurate Erythemas 256
Andrew J Peranteau, Ashley Eryn Pezzi, Tiffany Hinojosa, Stephen K Tyring

SECTION 6: VESICULOBULLOUS DISEASES

20. Autoimmune Vesiculobullous Disorders 267
Julie B Zang

21. Nonautoimmune Bullous Diseases 287
Heather Holahan, Babar K Rao

SECTION 7: ECZEMATOUS DERMATITIS

22. Atopic Dermatitis 297
Diana W Bartenstein, Elena B Hawryluk

23. Allergic and Irritant Contact Dermatitis 312
Mohsin Malik, Amy Pappert, Babar K Rao

24. Other Eczemas 323
Rashmi Sarkar, Jaspriya Sandhu

SECTION 8: PAPULOSQUAMOUS DISORDERS

25. Psoriasis 335
Caleb Jeon, Nakamura M, Singh R, Wilson Liao, Bhutani T, Koo J, Lebwohl M

26. Papulosquamous Eruptions and Exfoliative Dermatitis 350
Sekhon S, Zhu H, Benjamin Farahnik, Bhutani T, Koo J, Lebwohl M

SECTION 9: OTHER DERMATOSES

27. Eosinophilic Dermatoses 367
Collin Blattner, William Lear, John Young III

28. Neutrophilic Dermatoses 376
Collin Blattner, William Lear, Benjamin Perry, John Young III

JAYPEE BROTHERS

29. **Pregnancy-related Dermatoses** 396
Collin Blattner, Melissa Danesh, William Lear, John Young III

30. **Dermatoses due to Physical Factors and Occupation** 405
Dillon Nussbaum, Adam Friedman

SECTION 10: PHOTOSENSITIVITY

31. **Skin Types and the Physiology of Tanning and Sunburn** 419
Basia Michalski, Edit Olasz-Harken

32. **Photodermatoses** 429
Marwa Abdallah, Mahmoud Abdallah

SECTION 11: CONNECTIVE TISSUE DISEASES

33. **Lupus Erythematosus** 451
Jose Dario Martinez, Dionicio Angel Galarza, Jesus Alberto Cardenas, Miryam Eguia

34. **Dermatomyositis** 465
Fermin Jurado Santa Cruz

35. **Scleroderma** 482
Sara Hogan, Anthony Fernandez

36. **Other Rheumatologic Disorders with Cutaneous Manifestations** 497
Jose Dario Martinez, Magda Arredondo, Jesus Alberto Cardenas

SECTION 12: VASCULITIS, VASCULOPATHY AND ULCERS

37. **Approach to Purpura and Microvascular Occlusive Syndromes** 513
Connie R Shi, Vinod E Nambudiri

38. **Vasculitis** 528
Rohini Shantharam, Jacob Berman, Allireza Alloo

39. **Other Vascular Disorders** 540
Ryan Karmouta, Vinod E Nambudiri

40. **Vascular Malformations** 550
Sophie Vadeboncoeur, Marilyn G Liang

41. **Cutaneous Ulcers and Wound Care** 569
Jose Contreras-Ruiz, Adriana Lozano-Platonoff, Paula Torres-Camacho

SECTION 13: DISORDERS OF THE DERMIS AND SUBCUTANEOUS TISSUE

42. **Disorders of Collagen, Elastin and Ground Substance** 587
Emily M Altman

43. **Diseases of Subcutaneous Tissue** 620
Sandipan Dhar, Ann M John, Amrinder Jit Kanwar

JAYPEE BROTHERS

SECTION 14: PIGMENTATION DISORDERS

44. Introduction to the Biology of the Pigmentary System 635
Šitum Mirna, Bulat Vedrana, Goren Andy, Kazandjieva Jana, Guleva Dimitrina, Kovacevic Maja, Lotti Torello

45. Disturbances of Melanin Pigmentation 648
Miroslava Kadurina, Kristina Semkova, Šitum Mirna, Kovacevic Maja, Kolić Maja, Guleva Dimitrina, Lotti Torello

SECTION 15: PEDIATRIC DERMATOLOGY

46. Transient Benign Conditions of the Neonate and Infant 677
Caitlin Gilman, Vikash S Oza

47. Diaper Dermatitis 687
Helen T Shin

48. Vascular Tumors 690
A Yasmine Kirkorian

49. Genodermatoses 701
Neha Rajpal, Kalyani Marathe

50. Other Inflammatory Dermatoses in Children 725
Emily M Berger

SECTION 16: DISEASES OF SEBACEOUS, APOCRINE AND ECCRINE GLAND

51. Acne and Acneiform Dermatoses 731
Maressa C Criscito, Jisun Cha

52. Folliculitis and the Follicular Occlusion Tetrad 746
Nikhil Dhingra, Tamara Lazic Strugar

53. Rosacea and Perioral Dermatitis 756
Noelani González, Tamara Lazic Strugar

54. Diseases of the Eccrine Glands 763
Steven Eilers, Radhika Shah, Eun J Kwon

55. Diseases of the Apocrine Sweat Glands 782
Vijay Vanchinathan, Eun J Kwon

SECTION 17: HAIR DISORDERS

56. Cicatricial Alopecia 791
Valerie D Callender, Nicole E Rogers, DiAnne S Davis

57. Non-scarring Alopecias 809
Rosalynn RZ Conic, Jessica Lin, Natasha Mesinkovska

58. Hypertrichosis 821
Kristen Elkins, Margit Juhasz, Joseph Zikry, Natasha Mesinkovska

JAYPEE BROTHERS

59. **Hirsutism** 833
Faezeh T Liasi, Lance W Chapman, Natasha Mesinkovska

60. **Hair Shaft Abnormalities** 842
Brandon E Cohen, Nada Elbuluk

SECTION 18: DISORDERS OF THE NAILS

61. **Disorders of the Nails** 851
Shari R Lipner, Mary Laird, Kristen Lo Sicco

SECTION 19: DISORDERS OF THE ORAL CAVITY

62. **Disorders of the Oral Cavity** 879
Katerina Damevska, Snejina Vassileva, Grisha Mateev, Kossara Drenovska, Lence Neloska, Valeria Mateeva, Martin Shahid, Torello Lotti

SECTION 20: NON-INFECTIOUS DISEASES OF THE MALE AND FEMALE GENITALIA

63. **Non-infectious Male Genital Dermatology** 919
Alok Vij

64. **Non-venereal Diseases of the Female Genitalia** 930
Melissa M Mauskar, Christina N Kraus

Volume 2

SECTION 21: PSYCHOCUTANEOUS DISORDERS AND NEUROGENIC SKIN DISEASE

65. **Psychodermatology** 945
Katerina Damevska, Mirna Situm, Katlein França, Sanja Manchevska, Maja Vurnek Zivkovic, Marija Buljan, Torello Lotti

66. **Pruritus: Pathophysiology and Clinical Aspects** 957
Shahyan Rehman, Jeffrey D Bernhard, Sarina B Elmariah

67. **Flushing** 986
Azeen Sadeghian, Jordan Brooks, Brittany Stumpf, Erin Boh

SECTION 22: DISORDERS OF NUTRITION AND METABOLISM

68. **Nutrition and Diet in Dermatology** 999
Tara Bronsnick, Era Murzaku, Babar K Rao

69. **Cutaneous Mucinoses and Amyloidosis** 1007
Mahin Alamgir

70. **Disorders of Metabolism** 1019
Mahin Alamgir

JAYPEE BROTHERS

SECTION 23: THE SKIN IN SYSTEMIC DISEASES

71. Cutaneous Manifestations of Systemic Diseases 1033
Mahin Alamgir

SECTION 24: BACTERIAL AND RICKETTSIAL INFECTIONS

72. Fundamental Cutaneous Microbiology 1077
Roxanna Arakozie, Soham Chaudhari, Collin Blattner, John Young III

73. Bacterial Infections of the Skin 1088
Gina Francisco, Rosa Mateus

74. Mycobacterial Infections 1118
Christina Wong, Kenneth Tomecki

75. Rickettsial Diseases and Other Arthropod-borne Infections 1130
Gina Francisco, Jacqueline Marrugo, Gonzalo Marrugo

SECTION 25: VIRAL INFECTIONS

76. Viral Diseases 1143
Cynthia L Chen

77. Herpes Simplex Virus 1146
Paola Chamorro, Andrew Avarbock

78. Varicella Zoster Virus 1155
Anuradha Bishnoi, Davinder Parsad

79. Poxviruses and Kawasaki Disease 1165
Ashley Keyes

80. Human Papillomavirus Infection 1173
Xing-Hua Gao, Yang Yang, Yuxiao Hong, Wei Huo

81. Viral Exanthems 1188
George I Varghese

82. Human Immunodeficiency Virus 1199
Pooja Virmani, Michael A Marchetti

SECTION 26: SUPERFICIAL AND DEEP MYCOSES

83. Superficial and Subcutaneous Mycoses 1215
Jennifer Abrahams, George W Elgart

84. Candidiasis 1233
Jennifer Abrahams, George W Elgart

85. Deep Mycoses 1244
Jennifer Abrahams, George W Elgart

JAYPEE BROTHERS

SECTION 27: SEXUALLY TRANSMITTED DISEASES

86. Non-treponemal Sexually Transmitted Diseases 1263
Shesly Jean-Louis, Brian W Morrison, Jose A Jaller

87. Treponematoses 1277
Shesly Jean-Louis, Brian W Morrison, Ariel E Eber, Marina Perper, Nicholas Fiumara

SECTION 28: PARASITES, ARTHROPODS, HAZARDOUS ANIMALS, AND TROPICAL DERMATOLOGY

88. Parasites, Arthropods, and Hazardous Animals of Dermatologic Significance 1291
Amira Elbendary, Manuel Valdebran, Lauren Boudreaux, Collin Blattner, Dirk M Elston

SECTION 29: TUMORS OF THE SKIN

89. Benign Epithelial Lesions 1311
Giovanni Pellacani, Marco Manfredini

90. Cysts 1319
Raheel Zubair, Omar Noor

91. Non-melanoma Epithelial Skin Cancers 1325
Giovanni Pellacani, Marco Manfredini

92. Adnexal Neoplasms 1335
Christine Ahn, Andressa Costa, Omar Sangueza

93. Benign Melanocytic Nevi and Neoplasms 1355
Neeta Malviya, Brian Scott, Alexander Marzuka, Stephanie Savory

94. Melanoma: Biological Knowledge and Prognostic Factors 1370
Marco Manfredini, Giovanni Pellacani

95. Vascular Neoplasms 1384
Christine Ahn, Andressa Costa, Omar Sangueza

96. Fibrous and Fibrohistiocytic Proliferations 1400
Audrey Rutherford, Donald A Glass II

97. Mastocytosis 1416
Andrew J Peranteau, Yun Tong, Ramya Vangipuram, Stephen K Tyring

98. Muscle, Adipose, and Cartilaginous Neoplasms 1427
Sophia Delano

99. Neural and Neuroendocrine Tumors 1437
Lauren Boshnick, Sairah Khokher, Ashleigh Briody

100. Histiocytoses 1450
Hannah Song, Jennifer Huang

101. Xanthomas 1463
Juliana Berk-Krauss, Tracey Nicole Liebman

JAYPEE BROTHERS

SECTION 30: TUMORS OF THE LYMPHORETICULAR SYSTEM

102. Cutaneous T-cell Lymphomas **1477**
Goff HW

103. Cutaneous B-cell Lymphoma **1501**
Enos Tyler, Goff HW

SECTION 31: DERMATOLOGIC SURGERY

104. Dermatologic Surgery **1515**
Eric Millican, Rachel Redenius, William G Stebbins

105. Surgical Instruments **1534**
Collin Blattner, Cory Maughan, Benjamin Perry, William Lear

106. Wound Closure **1553**
Dalee M Zhou, Anthony M Rossi, Erica H Lee

107. Electrosurgery **1569**
Lilia Correa-Selm, Bahar F Firoz

108. Anatomy of the Head and Neck **1578**
Joshua Farhadian, Bradley S Bloom, Jeremy Brauer

109. Nerve Blocks **1596**
Abigail Waldman, Michael Pelster, Murad Alam

110. Local Anesthetics **1602**
Dalee M Zhou, Anthony M Rossi, Erica H Lee

111. Surgery Section **1610**
Marina Perper, Rachel A Fayne, Ariel E Eber, Keyvan Nouri

112. Wound Healing and Surgical Dressings **1627**
Emily Newsom, Karen Connolly, Kishwer Nehal

113. Surgery of the Nail **1638**
Ann M John, Bahar F Firoz

114. Lip Reconstruction **1651**
Janet Y Li, Jo Cooke-Barber, Vineet Mishra

115. Surgical Complications **1667**
Garrett Vick, Vineet Mishra

SECTION 32: PHYSICAL MODALITIES OF THERAPY

116. Phototherapy **1687**
N Raboobee

117. Photodynamic Therapy **1702**
Ashwin Ganti, Gabrielle R Vinding, Annie Wang, John Strasswimmer, Thanh Nga Tran

118. Laser Treatment **1709**
Jihee Kim, Thanh Nga Tran, Ju Hee Lee

JAYPEE BROTHERS

119. Cryosurgery **1725**
Julia May, Allyson Tank, Manas Deolankar, Carl F Schanbacher

120. Radiotherapy **1731**
Aaron Wallace, Manas Deolankar, Julia May, Yen-Lin Chen, John Strasswimmer, Thanh Nga Tran

SECTION 33: COSMETIC SURGERY

121. Introduction to Skin Aging **1747**
Doris Day

122. Injectable Fillers **1757**
Guillermo Antonio Guerrero-Gonzalez, Ocampo-Candiani J

123. Neurotoxins in Aesthetic Medicine **1768**
Patricia K Farris, Leah G Jacobs

124. Current Concepts and Techniques in Liposuction Surgery **1779**
Khan AJ

125. Hair Transplantation **1791**
Shannon Watkins, Marc Avram

126. Chemical Peeling **1803**
Bucay VW

127. Lasers **1823**
Mussarrat Hussain, Dendy Engelman, Khalil Khatri

128. Sclerotherapy for Telangiectasia and Endovenous Ablation **1841**
Joshua Farhadian, Julie Karen

SECTION 34: DERMATOLOGIC CARE OF SEXUAL AND GENDER MINORITY PATIENTS

129. Dermatologic Care of Sexual and Gender Minority Patients **1853**
Andy Nguyen, Sarah T Arron, Kara Sternhell-Blackwell

SECTION 35: DERMATOLOGIC CARE IN MASSIVE INFECTIOUS, CHEMICAL, AND NUCLEAR DISASTERS

130. Dermatologic Care in Massive Infectious, Chemical, and Nuclear Disasters **1867**
Radhika Srivastava, Babar K Rao, Allison Weiffenbach

Index *1881*

JAYPEE BROTHERS

CHAPTER

89 Benign Epithelial Lesions

Giovanni Pellacani, Marco Manfredini

JAYPEE BROTHERS

INTRODUCTION

Benign skin tumors are alike in that they generally show a high degree of structural differentiation and usually are composed of relatively well-differentiated cells. In general, the growth of these lesions is slow and expansile in nature and metastases do not occur. Benign tumors of surface epidermis result from proliferation of the surface epidermal cells. In some lesions, there may also be a prominent connective tissue proliferation.

SEBORRHEIC KERATOSES

Seborrheic keratoses (SKs) represent the most common skin lesions that occur in older individuals, usually appearing in the fifth decade of life. They are more common in those inhabiting a temperate climate at this age, but may develop at an earlier age in those living in tropical regions. There is little tendency to spontaneously disappear and new lesions may continue to appear for many years. Males and females are equally affected. Although extremely common, the epidemiology is not well characterized in most populations, even though some studies estimate that 70 to 100% of subjects older than 50 years are affected. The total number and size of SKs has also been shown to increase with age. Most lesions are found on the trunk with a smaller number on the limbs, head and neck.[1–3] The rapid development of large numbers of SKs can occur in patients with an inflammatory dermatosis or in association with underlying malignancies where it is known as the sign of Leser–Trélat.[4–6] The neoplasms most commonly associated with this skin manifestation include stomach and colon cancer and in some patients it may be associated with the development of acanthosis nigricans. Recently, some new molecular insights into SK etiology have emerged with the identification of several mutations in FGFR3 and PIK3CA genes.[2,3,6] The histologic features of SKs were described in 1926 by Freudenthal.

Diagnosis

SKs often arise as a slightly hyperpigmented macule of the hands or face, and may remain superficial for a long period (solar lentigo). At this early stage, it may be difficult to distinguish superficial SKs from lentigo maligna and pigmented actinic keratosis (AK). As the lesion grows, it can become pedunculated or acanthotic, smooth-surfaced, domed and heavily pigmented, with plugged follicular orifices on the surface, giving an almost cerebriform appearance (Figs. 89.1A to C). Most SKs have fewer hairs than the skin they arise from. The most common appearance is that of a very superficial verrucous plaque which appears to be stuck on the epidermis, varying from dirty yellow to black in color and having loosely adherent, greasy keratin on the surface. They can be itchy, and irritation or infection causes swelling, sometimes bleeding, oozing and crusting, and a deepening of the color.[3–5] There are several different histologic variants of SKs. These have been designated as acanthotic, hyperkeratotic or papillomatous, adenoidal (reticulated), clonal, macular or incipient, pedunculated and irritated or inflamed. These variants demonstrate a characteristic pattern of growth—basal and squamous proliferation with hyperkeratosis, papillomatosis and horn pseudocyst production. HPVs have been detected in some SKs but are not believed to be causative. SKs have been found in association with benign and malignant lesions. Basal cell carcinoma (BCC), squamous cell carcinoma (SCC), eccrine porocarcinoma, melanoma, keratoacanthoma, adenocarcinoma, nevus sebaceus, Bowen's disease, primary cutaneous ganglioneuroma and bowenoid transformation have been described in association with SKs.

Dermatoscopy

Dermatoscopy is useful in the differential diagnosis of SK. Fissures and ridges give a cerebriform, or brain-like, appearance. The histopathological correlation of fissures and ridges is a papillomatous surface of the epidermis.

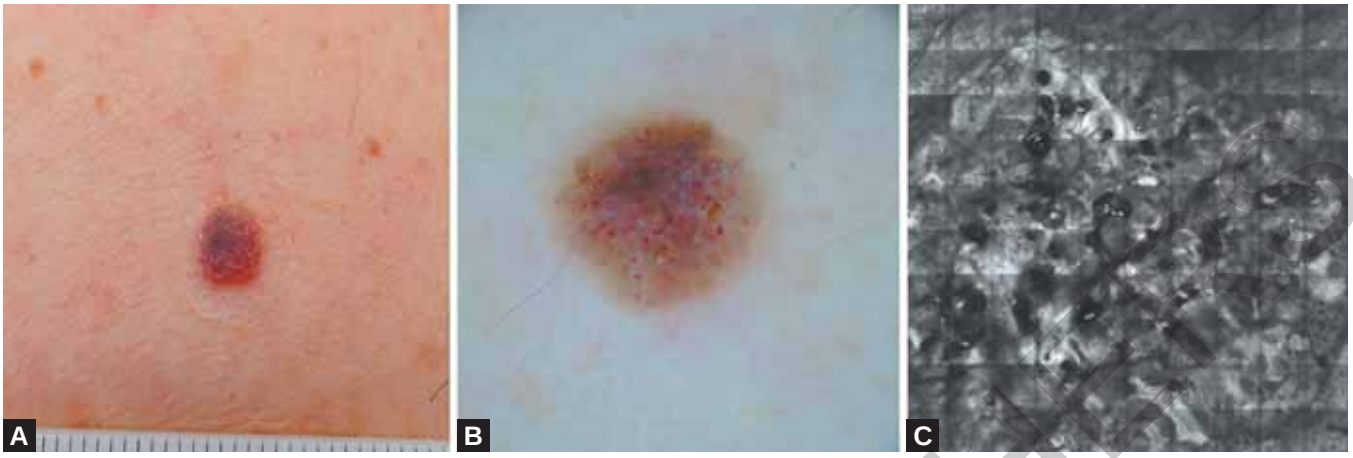

Figs. 89.1A to C: Clinical (A), dermatoscopic (B) and reflectance confocal microscopy (C) images of a pigmented SK.

Hairpin vessels are defined as two parallel linear vessels forming a half-looped or hairpin-like structure.[4–5] The vessels are often surrounded by a white halo when seen in such keratinocytic neoplasms as SK and viral warts. Comedo-like openings are round-to-oval clefts containing a keratin plug that is generally dark brown, gray or black. The term "crypts" is commonly used when the size of the clefts are large. Milia-like cysts are round, well circumscribed, white-to-yellowish opalescent structures that histopathologically correspond to intraepidermal cysts. Several clinical and dermatoscopy variants have been described.[1]

Acanthotic Type

In the acanthotic type of SK, the epidermis is markedly thickened, broad and composed of basaloid cells. Horn pseudocysts are present and may be very large. As the most common SK, the acanthotic type shows such typical dermatoscopic SK findings. However, this subtype may be difficult to diagnose in highly pigmented lesions because dermatoscopic findings become masked by melanin deposition. Irritation or prior trauma may also render dermatoscopic findings atypical.[1]

Hyperkeratotic Type

Hyperkeratosis and papillomatosis of the epidermis are pronounced in the hyperkeratotic type of SK. The stratum corneum is loosely laminated and interdigitated. The base of the lesion is flat. There is usually some hyperpigmentation along the basal layer. Stucco keratoses are probably variants of hyperkeratotic SKs. The clinical differential diagnosis of hyperkeratotic type SK includes viral warts, solar keratosis and SCC. Dermatoscopic examinations that specifically focus on areas with minimal hyperkeratosis are encouraged to identify fissures and ridges reflecting the remarkable papillomatous change of the epidermis. When accompanied with comedo-like openings and milia-like cysts, the diagnosis of hyperkeratotic type SK is more probable than that of viral warts, solar keratosis or SCC.[1]

Reticulated Type

In the reticulated type of SK, thin tracts of basaloid tumor cells extend from the epidermis to the dermis while forming a reticular architecture. Reticulated type SK is considered to have a close clinical and histopathological relationship with solar lentigo, and comparable findings for solar lentigo and early SK may be observed under dermatoscopic.[1]

Clonal Type

In clonal type SK, well-circumscribed nests of basaloid tumor cells often containing melanin deposits proliferate in the epidermis. When observed dermatoscopically the pigmented intraepidermal nests appear as globule-like structures and are almost indistinguishable from the blue-gray globules of BCC and the dots/globules of melanocytic lesions. The presence of comedo-like openings and milia-like cysts together with sharp lesion demarcation were reportedly helpful to diagnose clonal type SK. In the non-pigmented variety, the presence of polymorphous vessels that are glomerular, linear, irregular and dotted along with a "white network" have been reported.[1] Within the acanthotic epidermis are "clones" of basaloid epidermal cells surrounded by otherwise unremarkable

JAYPEE BROTHERS

keratinocytes. This pattern is termed the Borst–Jadassohn phenomenon and may be seen in other cutaneous tumors.

Irritated Type

Numerous squamous eddies and downward proliferation of the epidermis are two histopathological characteristics of irritated type SK lesions. Irritated type SK tends not to exhibit the typical dermatoscopic findings of SK, such as comedo-like openings, milia-like cysts or monomorphous vascular patterns of hairpin vessels. Instead, small, round, pinkish structures on a white background are the typical dermatoscopic findings of this SK subtype believed to correspond to dilated vessels in the dermal papillae surrounded by acanthotic tumor cells.[1]

Regressing SK

This condition is generally regarded as lichenoid keratosis (LK) or lichen planus-like keratosis. It is histopathologically characterized by a lichenoid reaction, namely, band-like infiltration of inflammatory cells in the upper dermis, pigment incontinence and individual degenerated keratinocytes in the epidermis. Dermatoscopically LK exhibits a granular pattern typified by regularly distributed, coarse, blue-grayish or brownish-gray dots. We also have showed that the granular pattern dots in the LK lesion histopathologically corresponded to melanin granules in the dermis, owing to pigment incontinence. Longitudinal dermatoscopic observation revealed that while areas displaying the granular pattern gradually increased, those with common dermatoscopic findings of SK, such as comedo-like openings, milia-like cysts, fissures and ridges, and hairpin vessels became decreased in regressing SK lesions. These observations suggest that some forms of LK may represent SK in the process of regression. It should be noted that a granular pattern alone is insufficient for the diagnosis of regressing SK; LK also indicates other regressing cutaneous neoplasms, including solar lentigo, Bowen's disease and melanoma.[1]

Melanoacanthoma

Melanoacanthoma was initially described by Bloch in 1927 and named in 1960 by Mishima and Pinkus. Whereas cutaneous lesions are almost exclusively restricted to Caucasians, oral melanoacanthomas are present mostly in black women. Melanoacanthomas are well demarcated, slightly raised and usually solitary and arise on the head, neck, abdomen and extremities. Melanoacanthoma is a heavily pigmented variant of SK histopathologically characterized by increased large, dendritic, melanin-rich melanocytes throughout the tumor. The heavy pigmentation of melanoacanthoma masks dermatoscopic findings, rendering it almost impossible to differentiate this condition from melanoma and other pigmented skin lesions. Although the presence of typical dermatoscopic SK features were helpful for diagnosis in past cases, however, histopathological examination was deemed mandatory to exclude melanoma.[1]

Reflectance Confocal Microscopy

With reflectance confocal microscopy (RCM), SK displays a regular honeycomb pattern of the epidermis and densely packed, round to polymorphous, well-circumscribed dermal papillae at the dermoepidermal junction (polycyclic papillary contours), features suggestive of a benign neoplasm. RCM features indicating the diagnosis of SK include: epidermal projections, keratin-filled invaginations at the lesion surface; corneal pseudocysts at epidermal layers; melanophages and dilated round and linear blood vessels in the papillary dermis.

Optical Coherence Tomography

Several non-invasive skin imaging techniques have emerged in recent years aiming for a higher accuracy in *in vivo* diagnosis. These include dermatoscopy, RCM and optical coherence tomography (OCT), which provides a fast morphological imaging and a penetration depth into the skin that allows discrimination of architectural patterns in the epidermis and both the papillary and reticular dermis. OCT shows multiple pseudofollicular openings, acanthosis, papillomatosis, basal hyperpigmentation and a visible dermal–epidermal junction.

Treatment

Laser ablation (CO_2) gives the best results in relation to safety, low recurrence rate and aesthetic outcome. Other treatments are represented by the removal with a small sharp curette that leaves a flat surface which becomes covered by normal epidermis in a week. Cautery or diathermy should be used as little as possible to avoid scarring. Satisfactory results can be obtained by freezing briefly, a technique especially suitable for large superficial lesions, or by carefully painting the surface with pure trichloracetic acid and repeating if the full thickness is not removed on the first occasion. They tend to recur and multiple treatments may be necessary.

JAYPEE BROTHERS

EPIDERMAL NEVI

Epidermal nevi (EN) are hamartomas of the epidermis or its appendages that may be associated with different syndromes. Epidermal nevi present as papules, nodules and patches of verrucous epidermal hyperkeratosis. They may be isolated, linear, zosteriform or whorled. Most lesions are different shades of brown but may also be gray, black or flesh colored. Comedo-like plugs and filiform hyperkeratosis have also been described. Inflammation or irritation is usually confined to traumatized epidermal nevi. Most lesions are asymptomatic, but mild pruritus may occur.[7–9] They are often isolated lesions that are present at birth or arise within the first few years of life. They originate from epidermal keratinocytes (keratinocytic epidermal nevus) or the pilosebaceous unit (organoid epidermal nevus).

Verrucous Epidermal Nevi

Verrucous epidermal nevi are congenital, non-inflammatory cutaneous hamartomas composed of keratinocytes. They are distinct from inflammatory, acantholytic and porokeratotic epidermal nevi, from sebaceous nevi, and from epidermal nevi derived from skin appendages. Their prevalence in adults is probably 0.1 to 0.5%, and they occur equally in males and females. They are divided into epidermolytic and non-epidermolytic types. The epidermolytic lesions are essentially a mosaic caused by a clone of cells expressing a mutation in one of the bullous ichthyosiform erythroderma (BIE) genes *KRT1* and *KRT10*. In young children they appear as slightly pigmented velvety or warty streaks or plaques. With age, they darken and the surface becomes more verrucous, sometimes with an erythematous base. Flexural lesions may become macerated and foul smelling, causing discomfort and psychological problems. Epidermolytic verrucous epidermal nevi show hyperkeratosis, acanthosis and papillomatosis with epidermolytic hyperkeratosis[5] identical to that seen in BIE. Epidermolytic and non-epidermolytic verrucous epidermal nevi are sometimes indistinguishable except on histology. Their lack of inflammation, presence at birth, warty, brown appearance and persistence distinguish them from most other types of epidermal nevus. They may be confused with linear viral warts, particularly filiform or digitate warts on the neck, scalp or body folds.

Epidermal Nevus Syndromes

The epidermal nevus syndromes (ENSs) are characterized by the association of epidermal nevi with abnormalities of the skin, skeletal system, central nervous system, eyes and cardiovascular system, as well as with malignant conditions. Many different kinds of ENSs are known, including Schimmelpenning syndrome, Proteus syndrome, congenital hemidysplasia with ichthyosiform erythroderma and limb defects (CHILD) syndrome, nevus comedonicus syndrome, Becker nevus syndrome, phakomatosis pigmentokeratotica, *PTEN*-associated nevus and Gobello syndrome, originating from different genetic mechanisms.[3,8,9] By definition, all ENSs reflect mosaicism. Many of them exclusively occur sporadically, but hereditary traits do likewise exist.

Schimmelpenning syndrome is characterized by nevus sebaceus and defects of the brain, eyes or bones. The phenotype was comprehensively described in 1957 by Gustav Schimmelpenning. Remarkably, in the associated EN, sebaceous hyperplasia may be minimal or even absent for two reasons: first, the sebaceous glands tend to be underdeveloped before puberty because of absence of stimulating hormone; second, sebaceous hyperplasia may be minimal or even absent in those parts of a sebaceous nevus that are localized outside of the head and neck. For differential diagnosis, various other ENSs should be considered, such as phacomatosis pigmentokeratotica (PPK), nevus comedonicus syndrome and Proteus syndrome.

PPK is characterized by a co-occurrence of nevus sebaceus that is usually rather large and a papular nevus spilus [speckled lentiginous nevus (SLN) of the papular type]. It is important to realize that in neonates and infants, the associated SLN may merely be noted in the form of a large café-au-lait macule, whereas the typical papular and macular speckles will develop later in life.

Nevus comedonicus syndrome was delineated in 1978 by Engber. It is characterized by a combination of nevus comedonicus with ipsilateral ocular, skeletal or neurologic defects. By way of exception, the extracutaneous anomalies may also be localized contralaterally.

Angora hair nevus is characterized by rather broad, band-like areas covered with long, smooth, white hair resembling angora hair and growing out from dilated follicular pores. Additional features may include frontal bossing, macrostomia, malformed ears and ocular defects.

Becker nevus syndrome is defined by the presence of a Becker nevus in association with other cutaneous anomalies and muscular or skeletal defects. The phenotype usually occurs sporadically. Becker nevus is an organoid EN characterized by one or more hyperpigmented patches that, in contrast to most other ENs, do not follow the lines of Blaschko but are instead arranged in a checkerboard

JAYPEE BROTHERS

pattern. The nevus has bizarre outlines reminiscent of an archipelago. Histopathologic examination shows an augmentation of smooth muscle fibers. It is said that Becker nevus preponderantly involves the upper half of the thorax, but all regions of the body may be affected. Breast hypoplasia is often present in this type of syndrome. Other ENSs are characterized by the coexistence of nevus sebaceus and papular nevus spilus in phacomatosis pigmentokeratotica; ipsilateral cataract is present in nevus comedonicus syndrome; cerebriform plantar changes are present in Proteus syndrome; *PTEN* mutations are found in type 2 segmental Cowden disease; and lateralization and *NSDHL* mutations are present in CHILD syndrome.

Inflammatory Linear Verrucous Epidermal Nevus

The inflammatory linear verrucous epidermal nevus (ILVEN) is believed to be a variant of an epidermal nevus and was first reported by Unna in 1896. These lesions arise early in life (half by 6 months of age), although onset during adulthood has also been reported. They can thus be distinguished from nevoid variants of inflammatory dermatoses which occur later and often resolve, including linear lichen planus, nevoid psoriasis, lichen striatus and adult Blaschkitis. The legs and thighs are most commonly involved, but the lesions may also be seen on the arms, buttocks, groin, and genitalia. Females are more often affected than males. A generalized variant and familial occurrence have been described. Intense pruritus is common. Inflammatory linear verrucous epidermal nevi begin as flesh colored to red papules that arise in a linear fashion. The papules become dark red to brown with scaling and crusting. A tendency to follow Blaschko's lines may be present. They may clinically resemble eczematous dermatitis or psoriasis and may develop a lichenoid appearance. Controversy exists as to whether ILVEN represents a mosaic form of psoriasis vulgaris. The epidermis shows exaggerated rete ridges with hyperkeratosis and parakeratosis. There may be a sharp demarcation between the areas of parakeratosis with a decreased to absent granular layer and orthohyperkeratosis with an intact or accentuated granular layer. This alternating type of pattern is characteristic of that seen in ILVEN. There is acanthosis with psoriasiform changes, mild to moderate papillomatosis, and an even elongation of the rete ridges.

CLEAR CELL ACANTHOMA

These lesions, also known as pale cell acanthomas, were first described in 1962 by Degos et al. Clear cell acanthoma is relatively uncommon, the sexes are equally affected, and the cause is unknown. Upregulation of keratinocyte growth factor, a growth factor prominent in psoriasis, has been described in clear cell acanthomas. The lesion is usually solitary.[3,10] It is a slightly elevated to dome-shaped plaque or nodule with an abrupt margin and a wafer-like scale adherent at the periphery, which leaves a moist or bleeding surface when removed. The color varies from pink to brown, but is most characteristically red with vascular puncta and it blanches on diascopy (Figs. 89.2A to C). It varies from 3 to 20 mm in diameter and occurs most commonly on the lower limbs. The duration may be of many years and there are usually no symptoms. The diagnosis can be suspected on the clinical evidence. The lesion

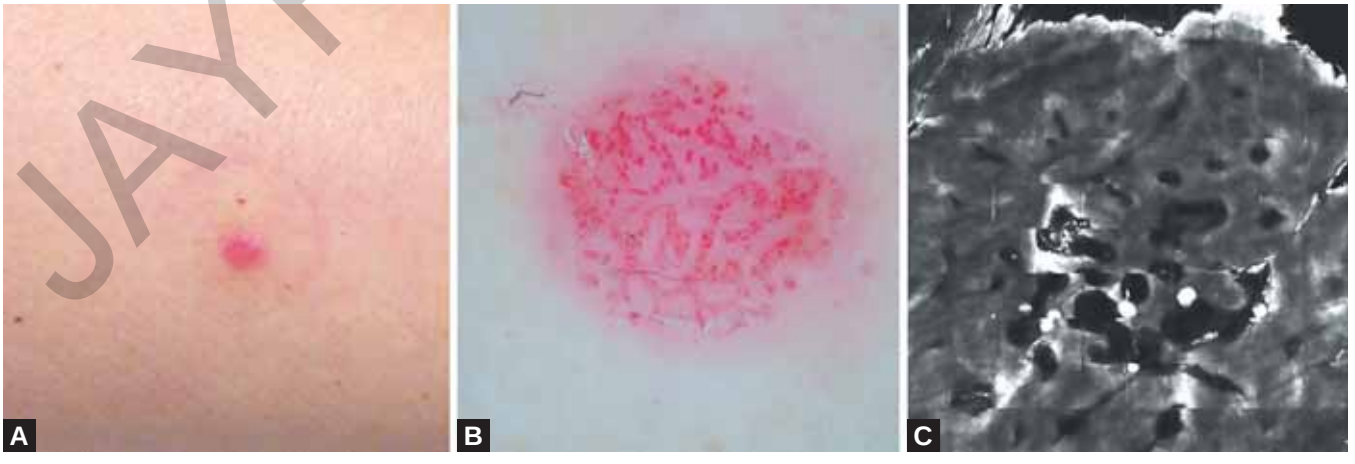

Figs. 89.2A to C: Clinical (A), dermatoscopic (B) and reflectance confocal microscopy (C) images of a clear cell acanthoma.

JAYPEE BROTHERS

may be mistaken for a BCC, histiocytoma, SK or pyogenic granuloma. The epidermis is acanthotic with clear cell changes, which are readily demarcated from adjacent normal epidermis. Pale cells are polyhedral and larger than normal keratinocytes. They are also periodic acid-Schiff (PAS) positive and diastase sensitive, indicating the presence of glycogen. Mitoses are few, and significant atypia is uncommon. Spongiosis is present. Rete ridges are elongated, occasionally in a psoriasiform manner, and may show fusion. A collarette is seen at the margins of the lesion. The granular layer is absent, and infiltrating neutrophils are seen.

Dermatoscopy

Dermatoscopy is very useful for the diagnosis of this type of neoplasm. Despite the difficult clinical recognition, clear cell acanthoma shows dermatoscopically a stereotypical and specific appearance represented by dotted vessels distributed linearly like strings of pearls.[10] The frequent presence of the same suggestive string of pearls pattern can be observed also in some rare histopathological variants (e.g. Agminated clear cell acanthoma), allowing a confident diagnosis of the tumor.

Reflectance Confocal Microscopy

RCM images at the spinous layer level show well-defined papular lesion with an acanthotic epidermis edged by a highly refractile collarette structure. At the dermal–epidermal junction level the tips of the dermal papillae appeared as large, dark, irregular spaces, corresponding to pinpoint or globular vessels on dermatoscopy and with dilated capillaries and glomeruloid blood vessels in the upper dermis on histology. Blood vessels can be also seen as convoluted, black luminal or tubular structures located at the level of the papillary dermis and filled by variably reflecting moving cells during the live examination.[10]

KERATOACANTHOMA

Keratoacanthoma is a rapidly evolving tumor of the skin, composed of keratinizing squamous cells originating in pilosebaceous follicles and resolving spontaneously if untreated. They were initially described in 1889 by Sir Jonathan Hutchinson as a "crateriform ulcer of the face" and today are believed to represent a low-grade SCC. They are also known as molluscum sebaceum.[11–14] Most keratoacanthomas arise as solitary lesions in sun-exposed sites, however, different clinical syndromes are associated with these tumors. It is relatively uncommon and males are affected about three times more often than females. The adjusted age distribution shows that it is most frequent in middle life and does not increase in incidence in old age, unlike BCC and SCC. These tumors are believed to arise secondary to long-standing solar damage because they originate in sun-exposed areas and their occurrence parallels increased UV exposure. However, chemical tumorigenesis has been demonstrated in animals and human tumors have developed after exposure to tar, pitch and podophyllin. Viral causes have also been postulated and HPV has been found in some lesions that are thought to begin in hair follicles. The first evidence of keratoacanthoma is a firm, rounded, flesh-colored or reddish papule, which may resemble molluscum contagiosum or, if keratotic, a viral wart. The patient rarely seeks advice at this stage. There is then a rapid growth phase and in a few weeks it may become 10 to 20 mm across. There is no infiltration at the base. The epidermis over the nodule is smooth and shiny; the lesion is skin colored to red with telangiectases just beneath the surface. The center contains a horny plug or is covered by a crust which conceals a keratin-filled crater. As the lesion matures, the accumulating keratin expands the outermost part making the edge overhang the base somewhat, but the radial symmetry is usually well preserved. The keratin may project like a horn or it may soften and break down. Spontaneous resolution is achieved by the epidermal covering receding toward the base and the horny core being shed. The base is revealed as irregular and puckered and the edge may remain as soft but thickened epidermis, either as a continuous rim or a series of tags. In most cases, the tumor presents as a solitary lesion. Multiple or recurrent tumors are more likely to be present in several circumstances and an association to Muir-Torre Syndrome is an important feature that has to be considered. The histological features vary with the stage of evolution and if an adequate specimen is not submitted, it may be impossible for the reporting pathologist to confidently rule out early invasive SCC. The early lesion is composed of a mass of rapidly multiplying squamous cells. These are large and rather pale with vesicular nuclei, prominent nucleoli and frequent mitoses. Hyperchromatic cells, atypical mitotic figures, individual cell keratinization and other evidence of loss of polarity may be found. Of note, keratoacanthoma is a common adverse effect of Vemurafenib therapy for BRAF-mutated advanced melanoma patients. The average time of onset for keratoacanthomas and other squamoproliferative lesions is approximately 3 months after the start of the BRAF inhibitor (BRAFi) target therapy. Interestingly, among patients who receive the combination of BRAFi and MEK

JAYPEE BROTHERS

inhibitors, the development of SCC or keratoacanthoma is significantly less frequent compared to patients that receive BRAFi monotherapy.[14]

Treatment

The end result of leaving the tumor to regress is usually a rather unsightly scar. Curettage and coagulation of the base, or excision and suture, are possible but are not recommended. Surgical excision is the best therapeutic option, especially if the diagnosis is in doubt, because curetted specimens yield poor sections.[15,16]

ACROCHORDON OR FIBROEPITHELIAL POLYPS

These lesions, that are commonly named also "skin tags," are very common, particularly in women at menopause or later. They are frequently found together with SKs. The lesions are pedunculated and may have a long stalk. They vary in size and are about 2 mm in diameter on average. They are round, soft and inelastic. The color may be unchanged, but they are frequently hyperpigmented.[3,17,18] The most common site is on the sides of the neck, where they may be mixed with typical small, sessile, SKs. When more profuse, they can extend on to the face or down to the back and chest. Similar lesions may be found in and around the axillae and groins. Of note fibroepithelial polyps can be associated with diabetes and metabolic syndrome. Anal skin tags may be the first clue to the diagnosis of CD. Fibroepithelial polyps with dense collagenous stroma are often designated fibroma. These lesions are digitate or polypoid with a collagenous core that varies from loosely textured to densely sclerotic collagen. Ectatic thin-walled vessels are common. Those polyps with a core of dense sclerotic collagen are often diagnosed as fibromas. Polyps containing significant amounts of adipose tissue are often designated soft fibromas, or even, mistakenly, nevus lipomatosus superficialis. The epidermis may be unremarkable or show features of lichen simplex chronicus, the result of rubbing by the patient or friction from clothing. Many fibroepithelial polyps show epithelial changes similar to SK, including acanthosis with horn cysts.[1,17]

OTHER BENIGN EPITHELIAL LESIONS

Pilonidal Disease

Pilonidal disease, consisting of cysts, sinus tracts or abscesses, arises in the sacrococcygeal region and is more common in men. Sacrococcygeal pilonidal disease is a chronic, well-recognized entity, characterized by the recurrent formation of an abscess or draining sinus over the sacrococcygeal area. It is one of the most common surgical problems. They may be congenital or acquired, and two theories of origin have been proposed. One school of thought is that pilonidal cysts are developmental abnormalities, but others believe the cysts are acquired and result from penetration of hairs into the skin, which induces the formation of a sinus or cyst. Rarely, chronic inflammation and recurrent disease leads to malignant transformation, most commonly to SCC.

REFERENCES

1. Minagawa A. Dermoscopy-pathology relationship in seborrheic keratosis. J Dermatol 2017;44:518–24.
2. Heidenreich B, Denisova E, Rachakonda S, et al. Genetic alterations in seborrheic keratoses. Oncotarget 2017;8:36639–49.
3. Quinn AG, Perkins W. Non-melanoma skin cancer and other epidermal skin tumours, in Rook's Textbook of Dermatology, Eighth Edition (eds T. Burns, S. Breathnach, N. Cox and C. Griffiths), Wiley-Blackwell, Oxford, UK. 2010.
4. Squillace L, Cappello M, Longo C, et al. Unusual dermoscopic patterns of seborrheic keratosis. Dermatol 2016;232:198–202.
5. Chen TY, Morrison AO, Cockerell CJ. Cutaneous malignancies simulating seborrheic keratoses: an underappreciated phenomenon? J Cutan Pathol 2017;44:747–8.
6. Agustí J, Bella-Navarro R, García-García AB, et al. Familial seborrhoeic keratosis associated with multiple "pure reticulated acanthomas" and infundibulocystic basal cell carcinomas. Br J Dermatol 2017;177(6):1654–63. doi: 10.1111/bjd.15736. Epub 2017 Dec 7.
7. Happle R. The group of epidermal nevus syndromes Part I. Well defined phenotypes. J Am Acad Dermatol 2010;63:1–22.
8. Tadini G, Rossi LC, Faure E, et al. A second case of Gobello nevus syndrome. Case Rep Dermatol 2016;8:85–90.
9. Boyd AS. Tumors of the epidermis, in dermatopathology: Third Edition (eds Raymond L. Barnhill, A. Neil Crowson, Cynthia M. Magro, Michael W. Piepkorn) McGraw-Hill Education/Medical; 3 edition. 2010.
10. Ardigo M, Buffon RB, Scope A, et al. Comparing in vivo reflectance confocal microscopy, dermoscopy, and histology of clear-cell acanthoma. Dermatol Surg 2009; 35:952–9.
11. Zalaudek I, Bonifazi E, Ferrara G, et al. Keratoacanthomas and spitz tumors: are they both "self-limiting" variants of malignant cutaneous neoplasms? Dermatol 2009;219:3–6.
12. Manfredini M, Longo C, Ferrari B, et al. Dermoscopic and reflectance confocal microscopy features of cutaneous squamous cell carcinoma. J Eur Acad Dermatol Venereol 2017;31(11):1828–33.

JAYPEE BROTHERS

13. Ponti G, Manfredini M, Pellacani G, et al. Role of microsatellite instability, immunohistochemistry and mismatch repair germline aberrations inimmunosuppressed transplant patients: a phenocopy dilemma in Muir-Torre syndrome. Clin Chem Lab Med 2016;54:1725–31.
14. Ponti G, Pellacani G, Tomasi A, et al. Skeletal stigmata as keys to access to the composite and ancient Gorlin-Goltz syndrome history: The Egypt, Pompeii and Herculaneum lessons. Gene 2016;589:104–11.
15. Sinha R, Larkin J, Gore M, et al. Cutaneous toxicities associated with vemurafenib therapy in 107 patients with BRAF V600E mutation-positive metastatic melanoma, including recognition and management of rare presentations. Br J Dermatol 2015;173:1024–31.
16. Watchorn RE, Thomas S, Miller C, et al. Keratoacanthoma management: results of a survey of UK dermatologists and surgeons. Br J Dermatol 2018;178(1):e49–e50.
17. Hui ES, Yip BH, Tsang KW, et al. Association between multiple skin tags and metabolic syndrome: a multicentre cross-sectional study in primary care. Diabetes Metab 2016;42:126–9.
18. Lee JA, Khodaee M. Enlarging, pedunculated skin lesion. Acrochordon. Am Fam Physician 2012;85:1191–2.

JAYPEE BROTHERS

for detailed information on dermatology books, visit our website www.jaypeebrothers.com, for detailed information on dermatology books, visit our website www.jaypeebrothers.com, for detailed inform

Moschella & Hurley's

DERMATOLOGY

Salient Features

- Provides a comprehensive summary of dermatological conditions, established diagnostic techniques, surgical, laser, and other procedures
- Experts from around the globe contributed so that readers can benefit from their knowledge and experience
- An excellent resource for practicing dermatologists, resident physicians, and students
- While keeping it up-to-date and easy-to-read, the authors were conscientious of not making it too digital
- Contains a special focus on dermatologic surgery and cosmetic procedures
- Includes a summary of noninvasive diagnostic tools in dermatolog
- Discusses simple and practical approaches to clinical pattern analysis, and is the first text to include a discussion on the role of a dermatologist in biological, chemical, and nuclear disasters
- May be the first dermatology textbook to have a chapter focusing on care for the lesbian, gay, bisexual, and transgender (LGBT) community.



Babar K Rao MD FAAD is the Director and Professor, Center for Dermatology, Department of Pathology at Rutgers Robert Wood Johnson Medical School, New Brunswick, NJ, USA. He is an Adjunct Clinical Associate Professor of Dermatology at Weill Cornell Medicine, New York, NY, USA. He moved to St John's Institute of Dermatology, London, UK where he attained a diploma in Dermatology followed by a year of research in Dermatopathology. Thereafter, he completed fellowships at UT Southwestern, Boston University, and New York University. He completed his Dermatology residency at Weill Cornell Medical College followed by a Dermatopathology fellowship at Rutgers New Jersey Medical School, Newark, NJ, USA. He obtained his first academic position as an Assistant Professor of Dermatology at Rutgers Robert Wood Johnson Medical School where he subsequently started a residency program and eventually a Department of Dermatology of which he served as the first Chair. He is board-certified in Dermatology and Dermatopathology and a globally renowned expert of Reflectance Confocal Microscopy (RCM). In addition to his significant clinical research, publications, and presentations related to RCM, he has over one hundred publications in dermatological journals and is an internationally known speaker in noninvasive diagnostic tools and pigmentary disorders.

Available at all medical bookstores
or buy online at www.jaypeebrothers.com

JAYPEE BROTHERS
Medical Publishers (P) Ltd.
www.jaypeebrothers.com

Join us on facebook.com/JaypeeMedicalPublishers

Shelving Recommendation
DERMATOLOGY

ISBN 978-93-5270-358-6