ur website www.jaypeebrothers.com, for detailed information on ophthalmology books, visit our website www.jaypeebrothers.com

Celebrating 50 YEARS
Passion, Quality and Innovation in Healthcare Publishing

Gems of Ophthalmology

CATARACT SURGERY

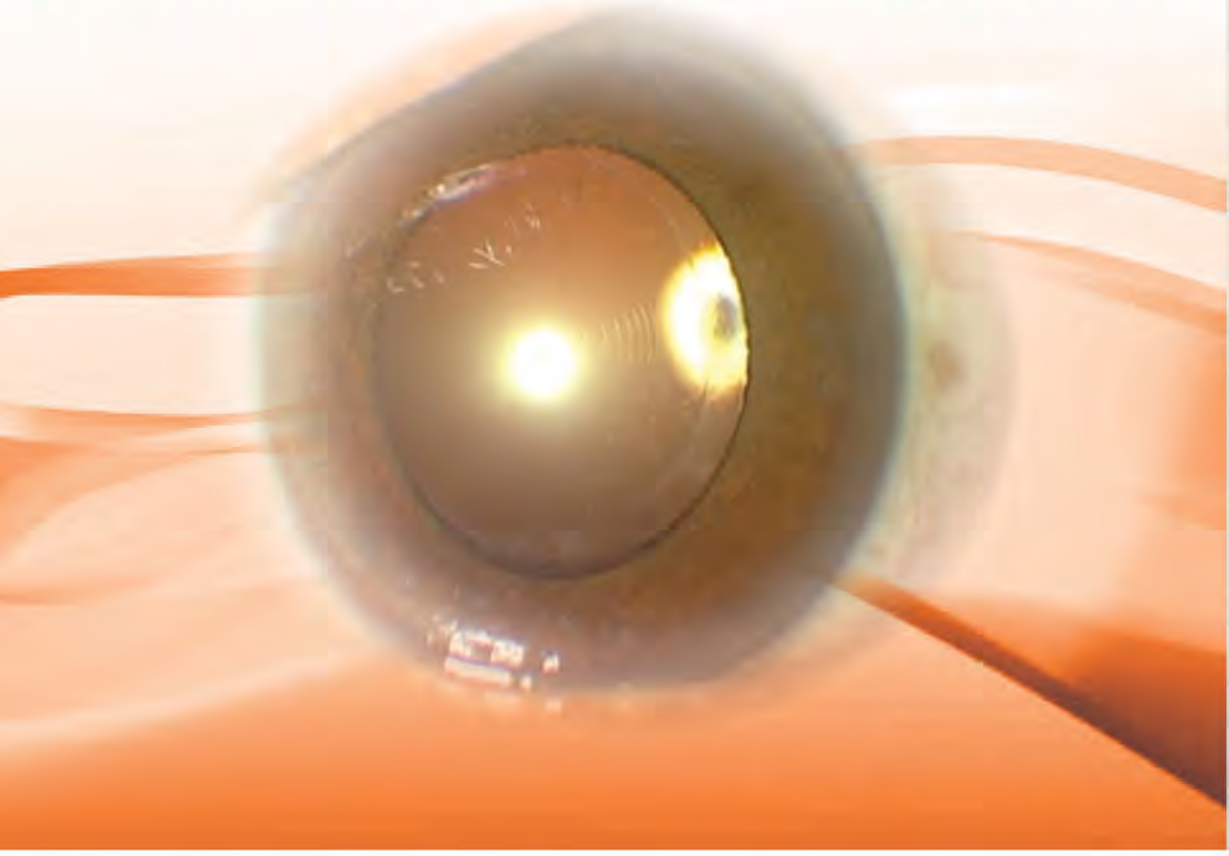

HV Nema
Nitin Nema

JAYPEE

Contents

1. Manual Small-incision Cataract Surgery: Techniques **1**
Manas Nath, Ashish Khodifad, Rengaraj Venkatesh

- *Technique 2*
- *Ocular Anesthesia 2*
- *Peribulbar Anesthesia 4*
- *Sub-Tenon's Anesthesia 5*
- *Bridle Suture 5*
- *Conjunctival Flap 6*
- *Sclerocorneal Tunnel Construction 6*
- *Capsular Opening 11*
- *Capsulorhexis 12*
- *Envelope Technique 14*
- *Can-Opener Technique 14*
- *Hydroprocedures 15*
- *Nucleus Management 17*
- *Cortex Aspiration 21*
- *Intraocular Lens Implantation 24*
- *Wound Closure 24*
- *Pre- and Postoperative Medications 24*

2. Clear Corneal Cataract Incisions **28**
I Howard Fine, Richard S Hoffman

- *History 28*
- *Indications 31*
- *Classifications 32*
- *Controversies 33*
- *Preoperative Evaluation 35*
- *Techniques 35*
- *Intraoperative/Postoperative Complications 39*
- *Postoperative Clinical Course and Outcomes 41*

3. Principles and Paradigms of Pediatric Cataract Surgery and Intraocular Lens Implantation **46**
Suresh K Pandey, M Edward Wilson, Jagat Ram, Liliana Werner, David J Apple

- *Diagnosis of Pediatric Cataracts 46*
- *Cataract Surgery in Children 49*
- *Surgical Techniques 63*

4. Capsular Dye-enhanced Cataract Surgery **111**
Suresh K Pandey, Liliana Werner, David J Apple

- *Dye-enhanced Anterior Capsulorhexis 112*
- *Dye-enhanced Phacoemulsification 127*
- *Dye-enhanced Posterior Capsulorhexis 133*

5. Posterior Polar Cataract **147**
Arup Chakrabarti, Meena Chakrabarti
- *Pathogenesis 147*
- *Inheritance and Genetics 148*
- *Classification 148*
- *Clinical Features 148*
- *Management 152*
- *Management of the Posterior Capsule 159*
- *Nucleus Drop in Posterior Polar Cataract 160*
- *Intraocular Lens Implantation 160*
- *Posterior Polar Cataract with Spontaneous Dislocation of Nucleus 161*
- *Surgery for Posterior Polar Cataract in Children 162*

6. Multifocal Intraocular Lenses **167**
Frank Joseph Goes
- *Tecnis Zm900 168*
- *Selection of Patients 169*
- *Patient Expectations 170*
- *Preoperative Testing 171*
- *Surgical Technique 172*
- *Implantation Technique of Tecnis or ReZoom 172*
- *Refractive Lens Exchange Customizing–Mixing and Matching Tecnis–ReZoom 174*
- *Results 175*

7. Advances in Intraocular Lenses **179**
Mohan Rajan, Sujatha Mohan, Amrutha Padhaye, Moulindu Paul
- *Multifocal Intraocular Lenses 180*
- *Why Accommodative Lenses? Why Not Multifocals? 186*
- *Newer Exciting Lenses 197*
- *Intraocular Lenses of the Future 203*

8. Present Status of Phakic Intraocular Lenses in Modern Refractive Surgery **205**
Jorge L Alió, Jaime Javaloy
- *Introduction: What is the Role of Phakic Intraocular Lenses in Today's Refractive Surgery? 205*
- *Diagnostic Methods for a Modern Phakic IOL Indication as a Surgical Proposal 209*
- *Phakic Intraocular Lens Types Available on the Market 216*

9. Intraocular Lens Power Calculation **240**
Himanshu Shekhar, Rajesh Sinha, Jeewan S Titiyal
- *Intraocular Lens Power Formulae 241*
- *Optical Biometry 248*
- *Intraocular Lens Power Calculation in Special Situations 250*

10. Scleral Fixated Intraocular Lens **255**
Naresh Babu, Supreet Singh Juneja
- *Sutures 256*

11. Recent Advances in Anterior Capsulotomy 265
Arup Chakrabarti
- ***Zepto Precision Pulse Capsulotomy*** *266*
- *Equipment 267*
- *Technique 269*
- *Study Results 270*
- *Advantages of Zepto Precision Pulse Capsulotomy 272*
- ***Capsulaser*** *273*
- ***Aperturectc™ Continuous Thermal Capsulotomy™ System*** *278*
- ***Verus Ophthalmic Caliper (Mile High Ophthalmics, Denver, Co, United States)*** *281*
- *Handling of the Device 282*

12. Phacoemulsification in White Cataracts 286
Rohit Om Prakash, Shruti Mahajan, Tushya Om Prakash
- *Classification 286*
- *Pathophysiology 287*
- *Clinical Presentation of White Cataracts 288*
- *Preoperative Workup 288*
- *Management 289*
- *Complications 297*

13. Terminal Chop: New Technique for Full Thickness Nuclear Segmentation in Hard Cataract 301
Rajendra Prasad, Anurag Badhani, Geetika Badhani
- *Mechanics of Terminal Chop 302*
- *Technique 306*
- *Results and Discussion 308*
- *Advantages of Terminal Chop 310*

14. Small Pupil Phacoemulsification 314
Rohit Om Prakash, Shruti Mahajan, Tushya Om Prakash
- *Etiology 314*
- *Relevant History 314*
- *Preoperative Evaluation 315*
- *Preoperative Dilatation of Small Pupil 315*
- *Decision-Making for the Use of Dilating Aids 316*
- *Intraoperative Floppy Iris Syndrome 324*

15. Phacoemulsification in Uveitic Cataract 328
Pradeep Venkatesh, Parul Sony, Sat Pal Garg
- *Preoperative Examination 329*
- *Investigations 329*
- *Preoperative Treatment 330*

16. Phacoemulsification in Eyes with Corneal Diseases 337
Bela Kamboj, Murali K Aasuri
- *Preoperative Evaluation 338*
- *Choice of Incision Site 338*
- *Maintenance of Anterior Chamber and Protection of Endothelium 338*
- *Ophthalmic Viscosurgical Devices 339*

- *Irrigating Solution 339*
- *Capsulorhexis 340*
- *Phacoemulsification 340*
- *Microscope Alignment 341*
- *Bullous Keratopathy 342*
- *Epithelial Irregularity 343*
- *Limbal Pathologies 343*
- *Keratoconus and Postkeratorefractive Surgery Eyes 343*

17. Phacoemulsification in Vitrectomized Eyes 345
Arup Chakrabarti, Meena Chakrabarti, Valsa Stephen, Sonia Rani John
- *Risks in Vitrectomized Eyes 345*
- *Preoperative Considerations 347*
- *Intraocular Lens Power Considerations 348*
- *Choice of Intraocular Lens 350*
- *Preoperative Patient Counseling 351*
- *Surgical Strategy for Phacoemulsification in Vitrectomized Eyes 352*
- *Postoperative Management 355*
- *Complications 357*

18. Management of Subluxated Lenses 360
Shreesh Kumar, PD Ramamurthy
- *Etiology 360*
- *Management 362*
- *Discussion 371*

19. Dropped Nucleus or Nuclear Fragments: Complication of Phacoemulsification 374
H Verbraeken
- *Incidence of Dropped or Diving Nucleus 374*
- *What Should the Cataract Surgeon Do? 375*
- *Possible Complications of Dislocated Lens Fragments 375*
- *An Unsolved Question: The Best Timing for Pars Plana Vitrectomy 377*
- *Techniques of Pars Plana Vitrectomy for Dislocated Lens Fragments 378*
- *Visual Prognosis 379*

20. Posterior Capsular Opacification 381
Vijay Kumar Sharma, Neelam Runda, Rajesh Sinha
- *Incidence 381*
- *Risk Factors 381*
- *Age 382*
- *Surgical Technique 382*
- *Intraocular Lens Material 382*
- *Intraocular Lens Design 383*
- *Types of Cataract 383*
- *Coexisting Disease 383*

- *Types and Mechanism of Posterior Capsular Opacification Development* 383
- *Quantification and Grading* 384
- *Management* 385
- *Prevention* 386
- *Surgical Technique* 387
- *Intraocular Lens Design and Material* 387
- *Chemotherapy* 388

21. Primary Posterior Capsulorhexis in Adults **391**
Albert Galand

22. Femtosecond Laser-assisted Cataract Surgery–1 **396**
Mahipal S Sachdev, Gitansha Sachdev
- *Currently Available Platforms* 396
- *Procedure* 397
- *Advantages over Conventional Phacoemulsification* 399
- *Techniques for Improved Outcomes* 400
- *Femtosecond Laser in Challenging Cases* 401

23. Femtosecond Laser-assisted Cataract Surgery–2 **406**
Soumya Ganesh Nanaiah, Sudeep Das, Mathew Kurian Kummelil, Rohit Shetty
- *Basic Science* 406
- *Nomenclature* 407
- *Preoperative Evaluation* 407
- *Planning* 410
- *Technique* 410
- *Contraindications* 413
- *Complications Unique to Femtosecond Laser-assisted Cataract Surgery* 413
- *Advantages* 414
- *Disadvantages* 415
- *Comparison of Femtosecond Laser-assisted Capsulotomy with Manual Capsulorhexis* 416

24. Secondary Intraocular Lens Implantation **420**
Piers Percival
- *Indications* 420
- *Contraindications* 420
- *Preoperative Assessment* 421
- *Operative Procedures* 421

25. Malpositioned Intraocular Lenses **433**
Jagruti P Desai, Abhay R Vasavada
- *Incidence* 433
- *Symptomatology* 434
- *Diagnosis* 434
- *Anterior Chamber Lenses* 435
- *Posterior Chamber Lenses* 436
- *Management* 446

26. Postoperative Endophthalmitis: An Update **454**
Lalit Verma, Arindam Chakravarti
- *Incidence 454*
- *Classification 455*
- *Etiology 455*
- *Clinical Features 456*
- *Case Situations and Studies 457*
- *Fungal Endophthalmitis 461*
- *Chronic Endophthalmitis 464*
- *Prevention and Prophylaxis 468*
- *Newer Intravitreal Antibiotics 473*
- *What to do in Case of Infection? 478*
- *What to do in Cluster Infections or Outbreak 478*
- *Legal Issues Related to Endophthalmitis 478*

27. Toxic Anterior Segment Syndrome: An Update **481**
Kamaljeet Singh, Arshi Misbah
- *Epidemiology 481*
- *Etiology 482*
- *Clinical Features 484*
- *Prevention 486*
- *Treatment 488*
- *Clinical Outcome and Prognosis 488*

Index *491*

CHAPTER 3

Principles and Paradigms of Pediatric Cataract Surgery and Intraocular Lens Implantation

Suresh K Pandey, M Edward Wilson, Jagat Ram, Liliana Werner, David J Apple

JAYPEE BROTHERS

INTRODUCTION

Congenital, early developmental and traumatic cataracts are common ocular ailments and represent an important cause of visual impairment in childhood.[1] Managing cataracts in children remains a challenge; treatment is often difficult, tedious, and requires a dedicated team effort by the parents, pediatrician, surgeon, anesthesiologist, orthoptist, and community health workers. The surgeon plays a significant role in achieving a good visual outcome following the treatment of childhood cataracts.[2] This chapter will focus on the management of pediatric cataracts with an emphasis on the various surgical techniques, intraocular lens (IOL) implantation, and postoperative complications.

DIAGNOSIS OF PEDIATRIC CATARACTS

Congenital, developmental, and traumatic cataracts can have different morphological characteristics (Box 3.1 and Figs. 3.1 to 3.5). These have extensively been reviewed by several authors.[3-5] A thorough ocular and systemic examination is mandatory in every child for the accurate diagnosis of the type of cataract. Ocular examination should include the visual acuity assessment, ocular motility, pupillary response, and posterior segment evaluation. When feasible, biomicroscopic examination of the anterior segment should be performed to evaluate the size, density, and location of cataract in order to plan the surgical procedure and to determine the visual outcome. Fundus examination should be carried out after pupillary dilatation. A-scan ultrasound helps to measure the axial length for calculating the IOL power and monitoring the globe elongation postoperatively. For an eye with total

BOX 3.1: Characteristics of pediatric cataracts.

Congenital/Developmental

Total/Diffuse

- Uncommon; Rubella cataracts, bilateral, variable visual prognosis

Anterior Polar

- Unilateral or bilateral, sporadic, opacity <3 mm, usually nonprogressive, good visual prognosis

Lamellar/Zonular

Bilateral, partial, opacity 5–6 mm, good visual prognosis

Nuclear

Autosomal dominant in many, bilateral (80%), nonprogressive, opacity 3.5 mm, moderate visual prognosis

Posterior lentiglobus

Unilateral, good visual prognosis

Persistent hyperplastic primary vitreous

Unilateral, sporadic and progressive, poor visual prognosis (when posterior segment involvement present)

Traumatic

- Total/diffuse
- Anterior subcapsular
- Posterior subcapsular
- Intumescent
- Ruptured anterior capsule with flocculent lens matter in anterior chamber
- Partially absorbed

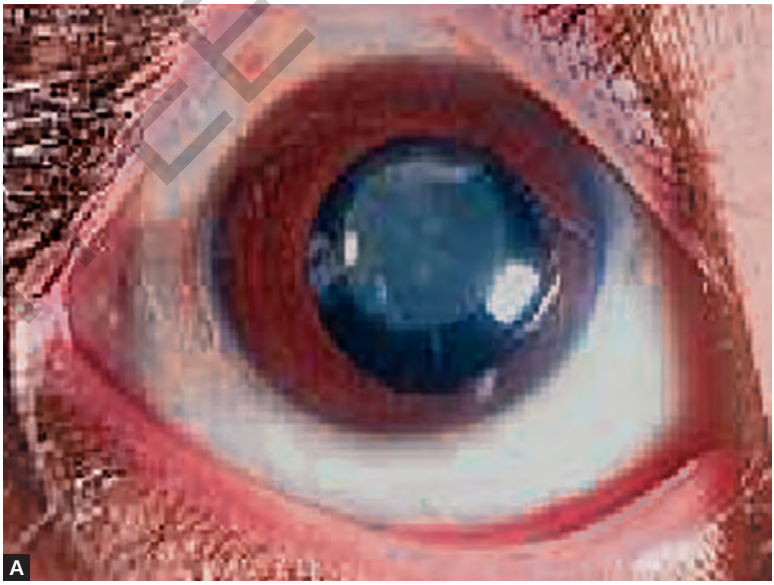

Fig. 3.1A

JAYPEE BROTHERS

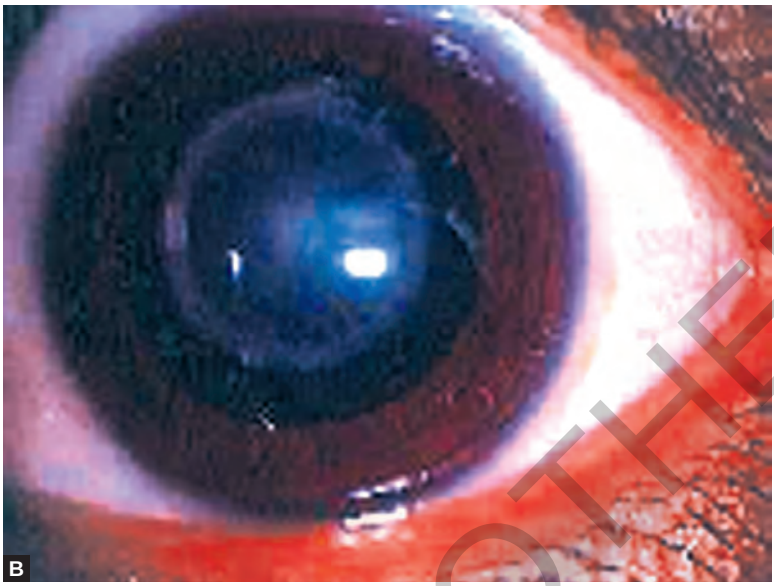



Figs. 3.1B and C

Figs. 3.1A to C: Slit-lamp photographs of zonular cataracts, taken from 3 different cases. Note that the lenticular opacity is occupying the central visual axis.

cataract, a B-scan evaluation is useful for detection of vitreoretinal pathology. A history from the parents is useful to determine whether the cataract could be congenital, developmental, or traumatic in origin. One must ascertain if there is any history of maternal drug use, infection, or exposure to radiation during pregnancy. Each child should be thoroughly examined by a pediatrician to rule out systemic associations, anomalies, or congenital rubella. This is essential as the cataract surgery in children is usually performed under general anesthesia.

JAYPEE BROTHERS

CATARACT SURGERY IN CHILDREN

How does Pediatric Cataract Surgery Differ from Adult?

Difficulties are encountered during preoperative, intraoperative, and postoperative periods. Preoperative difficulties include late diagnosis, associated conditions like prematurity, and systemic disorders. Risk factors for general anesthesia need a serious consideration. Intraoperative difficulties are caused as a result of smaller size of the eye, sometimes poorly dilating pupil, highly elastic anterior capsule, low scleral rigidity, and dense vitreous giving rise to raised



Figs. 3.2A and B

JAYPEE BROTHERS



Fig. 3.2C

Figs. 3.2A to C: Clinical photographs showing 3 different examples of bilateral total infantile cataracts. As opposed to the usual age-related cataract of adults, untreated cataracts of childhood are especially unfortunate since the individual is often doomed to immediate long-term suffering. An early surgical intervention and prompt optical rehabilitation is mandatory in order to prevent irreversible deprivational amblyopia: (A) Bilateral total cataract in a 2-month-old male child; (B) Bilateral total cataract in a 5-month-old male child; (C) Bilateral total cataract in a 9-month-old female child.

intravitreal and intralenticular pressure. Postoperative examination requires repeated short anesthesia. Propensity for increased postoperative inflammation and capsular opacification, a refractive state that is constantly changing due to growth of the eye, difficulty in documenting anatomic and refractive changes due to poor compliance, and a tendency to develop amblyopia are the factors that make the cataract surgery in the child different from that in the adult.[6-11]

In sharp contrast to the treatment of adult cataracts, the timing of cataract surgery in children is of paramount importance. It affects the visual result to a much greater extent than the surgical technique or method of postoperative optical correction utilized by the surgeon. In a young child, a cataract blurs the image received by the retina and disrupts the development of the visual pathways in the central nervous system. In addition to causing amblyopia, visual deprivation can disrupt the process of "emmetropization". Abnormal axial growth has been reported even in the absence of amblyopia as a result of the effects of unequal visual inputs to the two eyes.

Despite these differences, the improved surgical techniques, that are largely a reflection of the adult cataract surgery, and the advances in postoperative optical rehabilitation have significantly improved the prognosis of cataract surgery in children.[12]

JAYPEE BROTHERS

Indications for Treatment

In order to avoid the development of deprivational amblyopia, prompt diagnosis and treatment are necessary for visually significant cataract in neonate, infants, or toddler.[13] Indications for surgery in these eyes include: cataracts of more than 3 mm in diameter (visually significant), dense nuclear cataracts, cataracts obstructing the examiner's view of fundus or preventing



Figs. 3.3A and B

JAYPEE BROTHERS



Fig. 3.3C

Figs. 3.3A to C: Examples of unilateral total pediatric cataracts in 3 different children: (A) Unilateral congenital cataract in a 2-month-old male child. Note the convergent squint in the left eye probably secondary to deprivational amblyopia; (B) Unilateral traumatic cataract in a 2-year-old male child; (C) Unilateral developmental cataract in a 5-year-old female child.

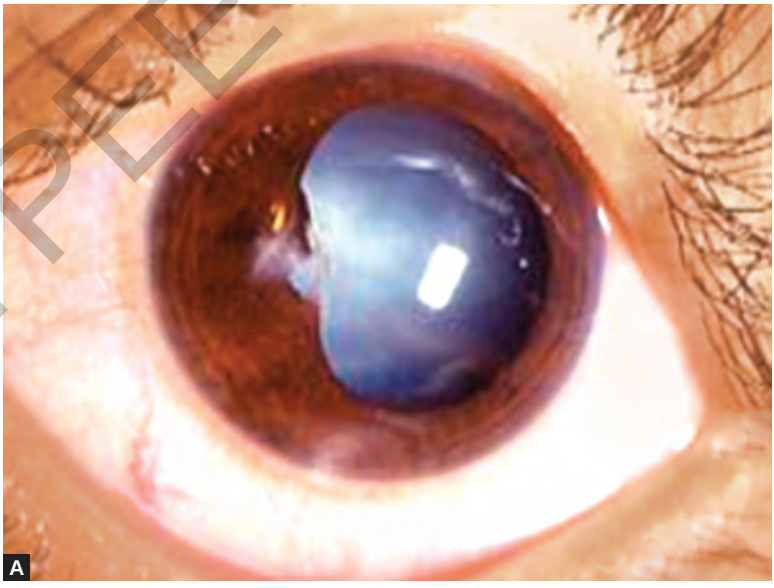

Fig. 3.4A

JAYPEE BROTHERS



Fig. 3.4B

Figs. 3.4A and B: Pediatric uniocular cataracts following blunt and penetrating trauma: (A) Slit-lamp photograph of the anterior segment of a 6-year-old male child showing traumatic cataract after blunt trauma (fire cracker injury). Note the formation of a posterior synechia at 3 o'clock position; (B) Slit-lamp photograph of the anterior segment of a 7- year-old female child after the repair of penetrating (bow and arrow) injury. Note the formation of a traumatic cataract associated with an irregular pupil.



Fig. 3.5: Bilateral congenital cataract in a 10-year-old male child associated left convergent squint. Note the associated ocular anomalies (microphthalmos and microcornea).

JAYPEE BROTHERS

refraction of patient, if the contralateral cataract has been removed, and cataracts associated with strabismus and/or nystagmus.[8,9,14-16]

When children beyond infancy present with dense, central opacities of uncertain duration and Snellen visual acuity cannot be accurately measured, surgery is indicated within a few weeks of detection. Nonsurgical methods as pharmacological pupillary dilation can be useful to manage partial cataracts.

The threshold for surgical removal of a partial cataract in a child capable of Snellen visual acuity has often been stated to be 20/70 or 20/80. The use of vision charts, e.g. Lea Hyvarinen symbol charts, is extremely useful in assessment of the visual status in a young child unable to read. However, individual judgments need to be made (especially in children too young for Snellen visual acuity testing) based on documented progression of the partial cataract and on the child's visual functioning, visual needs, and expected best visual outcome. When possible, low contrast sensitivity testing may provide a helpful guideline for deciding either the need of cataract surgery or treatment for posterior capsule opacification (PCO).

Optical Rehabilitation

Correction of pediatric aphakia can be accomplished with spectacles, contact lenses, epikeratophakia, or IOL implants[17-19] (Figs. 3.6 and 3.7). Currently, the contact lenses (in infants) and IOLs (in older children) are preferred. In infants, whichever method of optical correction is chosen, it is important to get a reasonably well-focused image on the retinas as early as possible.

Aphakic Glasses

Spectacle correction is safest and their power can be readily changed to compensate for ocular growth. They can be worn at any age and are not unduly expensive. Their magnifying effect may improve the child's acuity and make microphthalmic eyes appear normal size. Spectacles can be the only form of optical correction that is available in a community and most children using contact lenses should have a pair of aphakic glasses as a spare, when they are not able to use contact lenses. A child wearing contact lenses, or with an IOL, will need bifocals if his or her acuity is not good enough. Spectacles, however, have the disadvantage of poor cosmesis and inferior optics (Fig. 3.6). They cause alteration in the peripheral field of vision by inducing distortion and prismatic effects. An infant's ear and nose are often too insubstantial to support aphakic glasses. In addition, obtaining centration with heavy aphakic glasses is difficult and the optical center of the lens does not move with the eye. Although they provide a satisfactory correction for many children with bilateral aphakia, aphakic spectacles are generally not suitable for children with unilateral aphakia because of marked retinal image size disparity (approximately 30% magnification).

JAYPEE BROTHERS



Fig. 3.6: Visual rehabilitation in an infant after bilateral cataract surgery using aphakic glasses. Thick and heavy aphakic glasses are not suitable for the infant's nose and facial structure. They are also cosmetically inferior to other modalities (contact lenses/IOLs) of optical corrections.

Contact Lenses

There are three choices of contact lens type for pediatric patients: the hard lens, including polymethylmethacrylate (PMMA) and rigid gas-permeable (RGP) lenses (Fig. 3.7), the hydrogel extended-wear or daily wear lens, and the silicone lens. Most of the problems of aphakic spectacles can be overcome by the use of contact lenses; their power can also be easily adjusted according to the growth of the eye.[20,21]

The RGP contact lenses have the advantage of low cost and can be customized with regard to the power and base curve. Their disadvantage is that they must be removed daily and are more difficult for the parents to insert. The hydrogel or soft contact lenses have comfort as their main advantage. These lenses are tolerated in a wide range of base curvatures, and thus they are easily fitted. However, insertion difficulties coupled with instability and fragility lead to high damage and lens loss rates. Extended wear poly-HEMA lenses have proven to be the lenses of choice for children with unilateral aphakia. They are fairly stable with reduced lens loss rates.

Silicone contact lenses (Silsoft, Bausch & Lomb, Rochester, NY, United States) combine the best features of hard and soft lenses. They are reported to mask up to 2 diopters (D) of astigmatism in the adult. Like the hard lenses, they are easy to handle, have a relatively low loss rate, and can be fitted using either measurement or trial techniques. Most children under the age of 1 year can be fitted with a lens of 7.50 base curve. Older children are most often fit with a base

JAYPEE BROTHERS

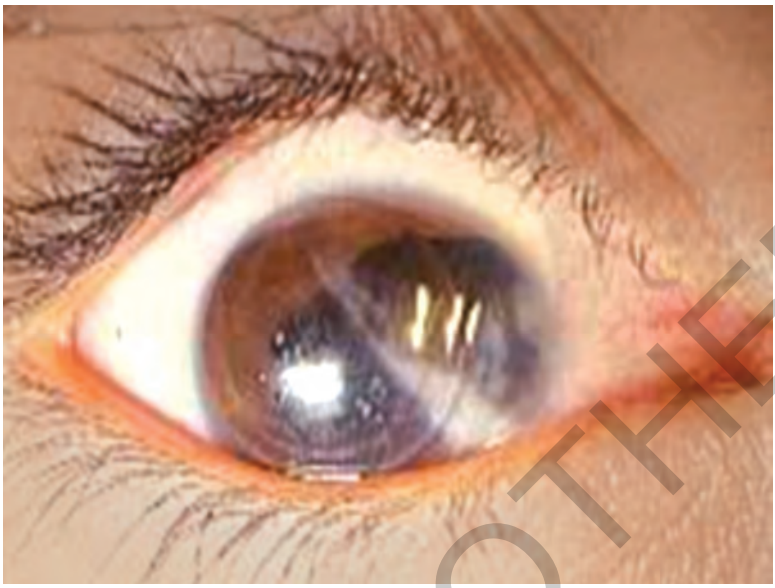

Fig. 3.7: Use of rigid gas permeable (RGP) contact lens for aphakic correction after surgery for traumatic cataracts in a 9-year-old child. Note the traumatic corneal scar inferonasally extending from 7 o'clock to 1 o'clock and a large sector iridectomy from 4 o'clock to 10 o'clock. The visual acuity of the eye was 20/40 with the RGP contact lens (*Courtesy:* Ashok Sharma, Chandigarh, India).

curve of 7.70. A fluorescein pattern may be used during the fitting sequence as needed. Lens movement with blinking is the most critical and important factor to evaluate during fitting. If too much movement is seen, a steeper lens can be tried. If little or no movement is seen, a flatter lens is indicated.

Unique problems facing the fitting of contact lenses in young aphakic children include their small eyes, steep corneas, and high hyperopia. Their continuously changing refraction, primarily related to an increasing axial length and progressive corneal flattening, provides an additional challenge. Repeated insertion and removal of a contact lens can be psychologically traumatic to the child. The major disadvantage of contact lenses for the correction of aphakia is the frequency of lens loss.[10] In addition to lens loss, noncompliance is a major problem particularly in children using contact lenses for correction of monocular aphakia. Assaf et al.[22] reported that only 44% of children with unilateral aphakia were wearing their contact lens during their follow-up visits. Loss of lenses, conjunctival erythema, and poor fit were reasons for noncompliance in these cases. With noncompliance, comes increased amblyopia and sensory strabismus. Other problems associated with contact lens use, more commonly encountered in developing country patients, who often come from rural communities with poor socioeconomic and educational background, include infective keratitis, corneal vascularization, hypoxic corneal ulcerations, and red eye without ulcerations.[23]

JAYPEE BROTHERS

Epikeratophakia

Epikeratophakia was introduced in the early 1980s as an alternative means of optically correcting aphakic eyes. It is a refractive corneal surgical technique in which a lathed lamellar corneal disk is sutured to the front surface of the recipient's cornea after the removal of the recipient's epithelium. Epikeratophakia corrects the refractive error by changing the anterior curvature of the cornea. Advantages of this technique are that no damage occurs to the recipient's central cornea, it is reversible, entirely extraocular, and may be employed with cataract extraction or as a secondary procedure. Problems like graft failure due to persistent epithelial defects, infections, or mechanical trauma are common with this technique. In addition, sutures must be removed after 3 weeks, often necessitating another anesthetic procedure. Amblyopia therapy is generally delayed until 4–6 weeks after the initial operation. Epikeratophakia for correcting pediatric aphakia has fallen into disuse due to the difficulty in achieving the target refracting power and the prolonged haziness of the host–donor interface.

Intraocular Lens Implantation

Problems such as contact lens intolerance, downward displacement of the lens with induced vertical diplopia, aniseikonia (approximately 6% with contact lenses), and traumatic corneal scars have prompted some investigators to advocate IOL implants for pediatric aphakia. IOL implantation in children during the early years of implant use in adults resulted in frequent complications secondary to poor lens design and poor quality control and also due to lack of refinement in the surgical technique.[24-42] There continues to be some hesitation of some ophthalmologists to implant IOLs in the pediatric population because of fear of the long-term effects of synthetic material, the changing refractive status of the developing eye, and the increased inflammatory response that occurs in pediatric eyes. As late as 1991, IOL implantation in children was not well accepted, especially by the pediatric ophthalmic community. However, the 1990s brought major improvements in IOL designs and surgical techniques better suited for children's eyes. In 1994, 46% of 234 pediatric ophthalmologists responding to a survey conducted by Wilson et al.[43] indicated that they were implanting IOLs in children. In addition, 27% of 1,039 other ophthalmologists were implanting IOLs in pediatric patients. The numbers are undoubtedly greater today. Many surgeons who remained skeptical in the recent past have now become advocates of selective IOL use in children. A growing number of case series have now been published supporting the safety and effectiveness of IOLs for children beyond infancy.[44-116]

Why are Intraocular Lenses Preferred for Pediatric Cataract Surgery?

Several reasons can be cited for the increased use of IOLs in children. The three most important reasons are as follows:

First, appropriately sized (11.5–12.0 mm), more flexible implants made from PMMA and acrylic foldable materials are now available and can be inserted

JAYPEE BROTHERS

for detailed information on ophthalmology books, visit our website www.jaypeebrothers.com, for detailed information on ophthalmo

Gems of Ophthalmology
CATARACT SURGERY

Salient Features

- Describes the basic techniques of clear corneal incision and small incision cataract surgery.
- Elaborates intricacies of pediatric cataract surgery.
- Guides surgeons how to perform phacoemulsification in difficult situation—small pupil, white cataract, hard cataract, uveitic cataract, posterior polar cataract, subluxated lens, etc.
- Directs how to manage complications—posterior capsular opacification, dropped nucleus, loss of capsular support, toxic anterior-segment syndrome (TASS), endophthalmitis, etc.
- Advances in IOLs, anterior capsulotomy, and femtosecond laser-assisted cataract surgery.



HV Nema MS has a distinguished academic career and is well-known for teaching, research and publications. He has served as a Consultant Editor/Advisory Editor to Indian Journal of Ophthalmology, Afro–Asian Journal of Ophthalmology and Indian Journal of Optometry. He has published more than 6 dozen papers in the national and international journals. He is an established author in the field of ophthalmology. *Ophthalmic Syndromes* (Butterworth, London, UK, 1973) and *Textbook of Ophthalmology* (6th ed. 2012, Jaypee Brothers Medical Publishers, New Delhi, India) are some of his popular books. He has edited 13 volumes of *Recent Advances in Ophthalmology*, 3 editions of *Diagnostic Procedures in Ophthalmology* and *Eye in Systemic Disorders* (Wiley India) which were well-received by readers and favorably reviewed in Indian and international journals. He has delivered guest-lectures in many universities.



Nitin Nema MS DNB is a Professor of Ophthalmology at Sri Aurobindo Medical College and PG Institute, Indore, Madhya Pradesh, India. He is an experienced Vitreoretinal surgeon. He did his Fellowship from Aravind Eye Hospital and PG Institute, Madurai, Tamil Nadu. He gained clinical and research experience from the University of Illinois at Chicago, and the University of Wisconsin at Madison in the USA. He was awarded a Fellowship by the All India Ophthalmological Society to work on a Project on Uveitis at Sankara Nethralaya, Chennai, Tamil Nadu. He was awarded Dr Mohan Lal Gold Medal for the best paper by UP State Ophthalmological Society. He had authored (in collaboration with Dr HV Nema) 2 textbooks: *Anatomy of the Eye and Adnexa* (3rd edition) and *Textbook of Ophthalmology* (6th edition), and edited 12 volumes of *Recent Advances in Ophthalmology*, and 3 editions of *Diagnostic Procedures in Ophthalmology*.

Available at all medical bookstores
or buy online at www.jaypeebrothers.com

JAYPEE BROTHERS
Medical Publishers (P) Ltd.
www.jaypeebrothers.com

Join us on facebook.com/JaypeeMedicalPublishers

Shelving Recommendation
OPHTHALMOLOGY

ISBN 978-93-5270-401-9