ypeebrothers.com, for detailed information on dental books, visit our website www.jaypeebrothers.com, for detailed information on dental books

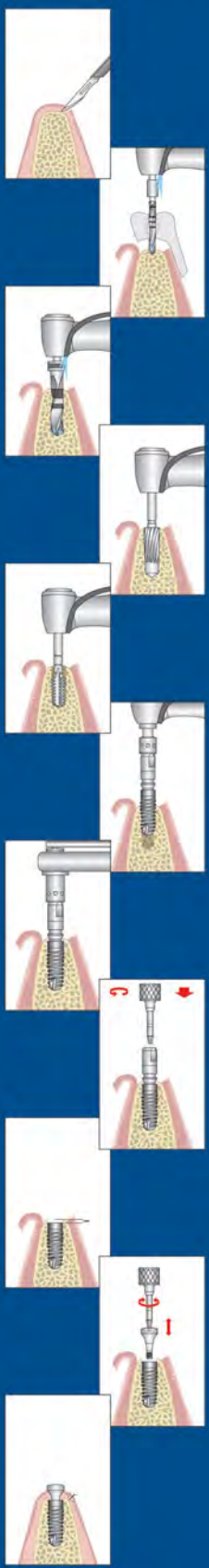

3RD EDITION

CLINICAL GUIDE TO ORAL IMPLANTOLOGY

STEP BY STEP PROCEDURES

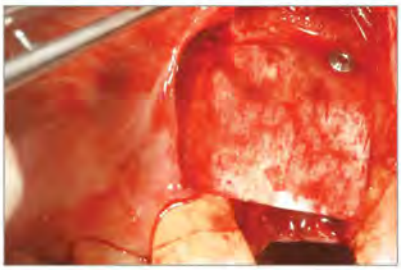



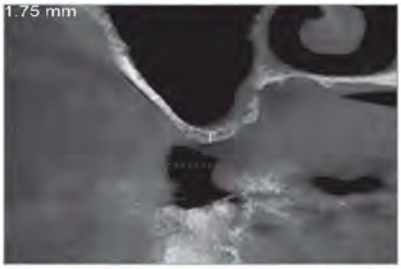



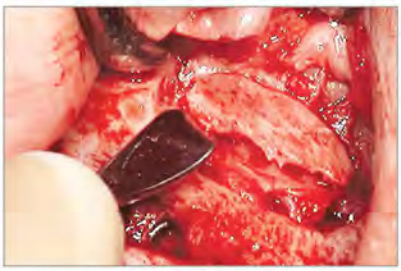



PROF. DR. POROUS S. TURNER
DR. FERZIN TURNER VAZIFDAR
DR. ASHDIN P. TURNER
MR. DANESH R. VAZIFDAR

JAYPEE

Contents

Chapter 1. Introduction to Implantology **1**

- What is Osseointegration? 2
- Bone Biology, Implant Healing and the Implant Tissue Interphase 5
- Osseointegration 6

Chapter 2. Diagnosis and Treatment Planning **7**

- Implant-Retained Fixed Bridges 8
- Implant-Retained Overdentures 10
- Single Tooth Restorations 12
- Planning Considerations 14
- Functional Considerations 14
- Aesthetic Considerations 15
- Study Cast and Diagnostic Set-up 16
- Implant Size, Number and Spacing 19
- Absolute medical Contraindications 19
- Relative Contraindications 19
- Patients on Biphosphonate Therapy 19
- Psychiatric Contraindications 19

Chapter 3. Basic Implant Surgery **21**

- Surgical Protocol 21
- Ankylos Implant Site Preparation 24
- Placement of an Ankylos Implant in Standard Posterior Sites: Step-by-step Procedures 26

Chapter 4. Impression Making for Implant Supported Prosthesis **40**

- Gingival Health 40
- Impression Technique 41
- Impression making for Implant Dupported Prosthesis 45

Chapter 5. Bone Regeneration **52**

- Bone Substitutes 53
- Case 1 54
- Case 2 58
- Case 3 61

Chapter 6. Sinus Grafting **69**

- Reconstruction of the Atrophic Posterior Maxilla 69
- Access Window to the Sinus Cavity 74
- Elevation of the Sinus Membrane 76
- Complications 80
- Case Report 81
- Discussion 94

Chapter 7. Crestal Sinus Floor Elevation **95**

- Surgical Technique 97
- Case 1 98
- Case 2 101
- Case 3 104

Chapter 8. Immediate Implantation and Provisionalization in the Anterior Maxilla **108**

- Crestal Bone Loss and the Biologic Width 108
- Case 1 111
- Case 2 116

Chapter 9. Implant Aesthetics **121**

- Case Report 124

Chapter 10. The Ankylos SynCone Concept **134**

- Immediately loaded Implant Supported Prosthesis with SynCone 134

Chapter 11. Complete Denture Stabilization Using Two Individual Implants **154**

- Case Report 155

Chapter 12. Challenging Implant Cases and Their Management **158**

- Case 1 158
- Treatment Plan 159
- Treatment 159
- Discussion 159
- Case 2 161
- Treatment Plan 161
- Treatment 161
- Discussion 163
- Case 3 167
- Discussion 173
- Case 4 174
- Treatment Plan 174
- Treatment 175
- Discussion 175

Chapter 13. Complications After Implant Placement **179**

- Case 1 179
- Case 2 182
- Case 3 184

Chapter 14. Principles of Suturing **186**

- Suturing Instruments 187
- Suturing Techniques 189
- Surgeon's Knot 195

Chapter 15. Subepithelial Connective Tissue Grafting for Implant Aesthetics **199**

- Modified Tunnel Technique to Thicken Mucosa Around Implants 200

Chapter 16. Maintenance of Implant Rehabilitated Patients **205**

- Importance of Oral Hygiene in Implant Patients 205
- Schedule for Maintenance of Implant Patients 207
- Abutment Connection 207
- Importance of Cessation of Tobacco Habits 207

Index *209*

Chapter 2

Diagnosis and Treatment Planning

JAYPEE BROTHERS

INTRODUCTION

The key to success of any dental treatment and more so with dental implant treatment is a well planned and preformed data-gathering process.

The treatment planning for implant supported prosthesis should begin with a clear idea of the end result which should fulfill the functional and aesthetic demands of the patient.

It is essential that all caries, endodontic lesions and periodontal diseases be treated before embarking on any implant treatment.

The minimal clinical examination should include the restorative status, periodontal screening, jaw relationship and occlusion.

The most convenient radiographic examination is the dental panoramic tomogram popularly known as OPG which stands for Ortho Pantomo Graphy (Fig. 2.1). This should be supplemented with intraoral radiographs for better image quality. Periapical radiographs should be considered for all heavily restored teeth, teeth with known or suspected endodontic problems and with periodontitis. Teeth with post-crowns should be carefully inspected for potential fracture of roots. Post-crown teeth as free-standing units may have a fair prognosis but should not be considered as abutment for fixed prosthodontics. Similarly, lateral incisors should not be considered as an abutment in a 4 unit fixed partial denture (Fig. 2.2).



Fig. 2.1: OPG view of patient.

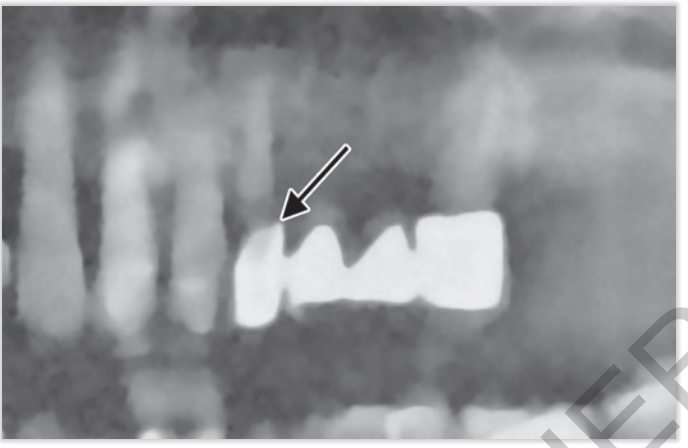

Fig. 2.2: Fracture of weak lateral incisor abutment.



Fig. 2.3A: Implant supported fixed bridge.

JAYPEE BROTHERS

The following type of implant retained restorations are possible:

- Fixed bridge (Figs. 2.3A and B)
- Over denture (Fig. 2.4)
- Single tooth restorations (Fig. 2.5).

IMPLANT-RETAINED FIXED BRIDGES

The prosthesis is similar in design to a conventional fixed bridge prosthesis constructed on natural teeth and can be screw retained or preferably cemented. Cantilevering fixed prosthesis more than one abutment anteriorly is not advised. However, in certain conditions, wherein we have multiple splinted implant abutments, it is possible to have 2 cantilevers in the non-functional anterior region (Figs. 2.6A and B).

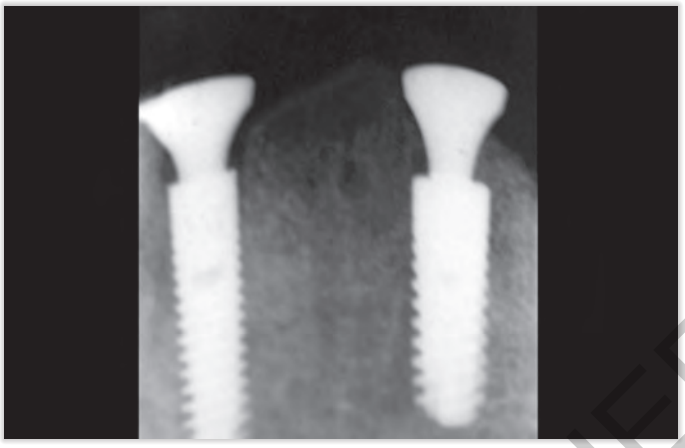

Fig. 2.3B: Radiographic view of implants before prosthetic rehabilitation.



Fig. 2.4: Intaglio view of complete overdenture supported by 3 Syncone abutments.



Fig. 2.5: Single implant supported crown on maxillary left canine.

JAYPEE BROTHERS

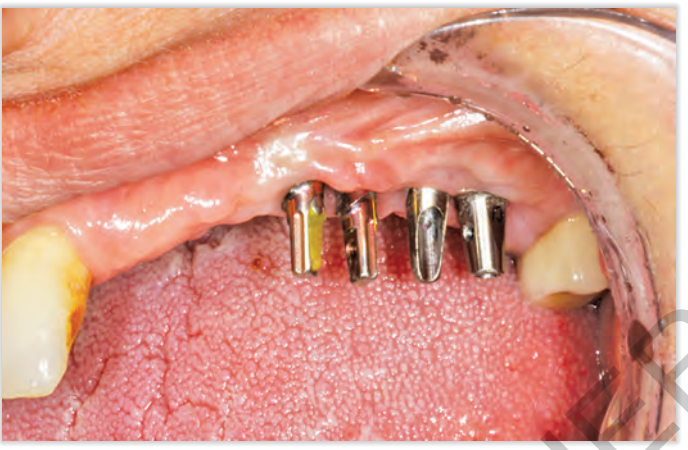

Fig. 2.6A: Four implants in the region of 24, 25, 26, 27.



Fig. 2.6B: Implant supported fixed restorations with 2 anterior cantilevers.

JAYPEE BROTHERS

IMPLANT-RETAINED OVERDENTURES

These are patient removable complete dentures usually with bar or ball attachment. In the mandible, it usually consists of two implants placed in the canine region with bar or ball attachments. Although it improves retention and stability of the lower denture, it is not the ideal solution, since, a mucosal-retained posterior causes continuous loss of bone in the posterior region. A better alternative is to have four implant abutments (Syncone abutments Dentsply Implants) with prefabricated Syncone caps in the denture (Figs. 2.7A and B).

Maxillary overdentures should also have minimum four implant abutments. However, in certain cases with improved implant abutment connections such as in the Ankylos system (Dentsply Implants), it is possible to work with only 3 implant abutments (Figs. 2.8A and B).

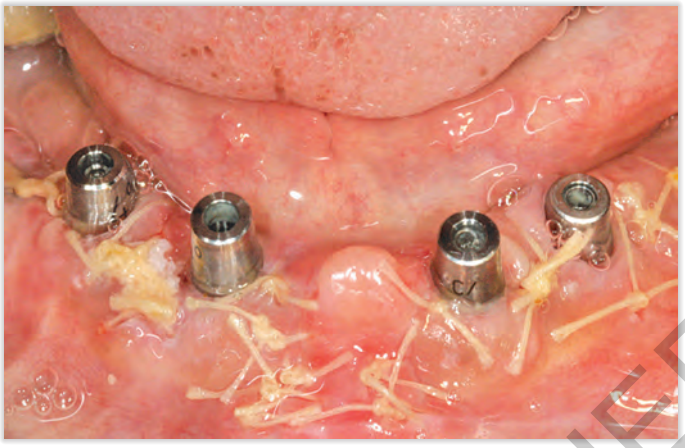

Fig. 2.7A: Ankylos implants with Syncone abutments on the day of surgery.

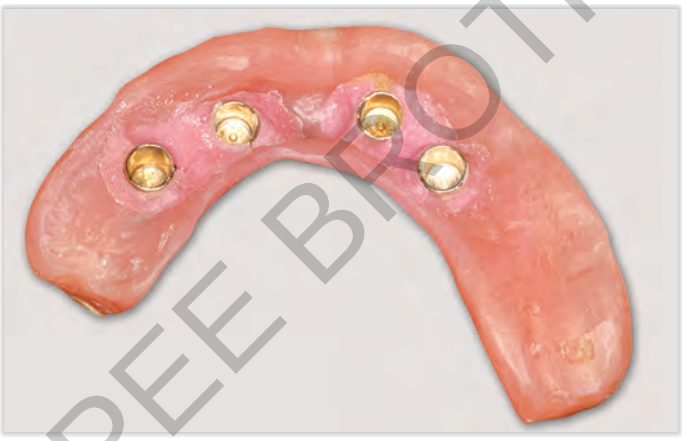

Fig. 2.7B: Four Syncone caps picked up in denture with self-cure acrylic on the day of surgery.

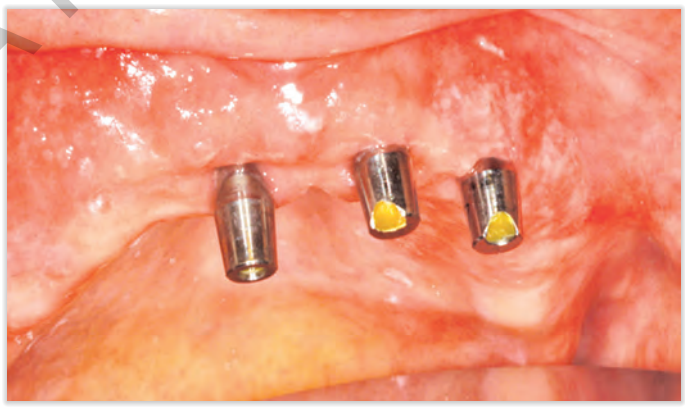

Fig. 2.8A: Three ankylos implants with 6° tapered Syncone abutments after a healing period of 3 months.

JAYPEE BROTHERS



Fig. 2.8B: Syncone caps with cast metal frame work incorporated in complete maxillary denture.

SINGLE TOOTH RESTORATIONS

Single tooth restorations are individual implant supported restorations not connected to other implants or natural teeth. They are usually cement retained to prefabricated abutments. In the anterior region, they enjoy high success rates. In posterior regions because of difference in size between missing tooth, and implant and the high masticatory forces, larger implants (5 mm or 6 mm) or two standard size implants (3.5 mm) are recommended. However, the authors have achieved high success rates with single (4.5 mm diameter) implants using the Ankylos system (Dentsply Implants) even in the posterior region (Figs. 2.9A and B).

The same may not be achievable with butt joint implant abutment systems (Figs. 2.9C and D)

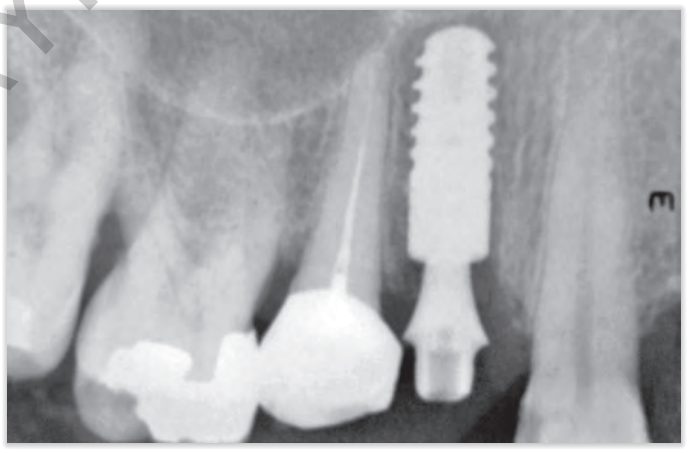

Fig. 2.9A: Ankylos implant with abutment on the day of surgery.

JAYPEE BROTHERS

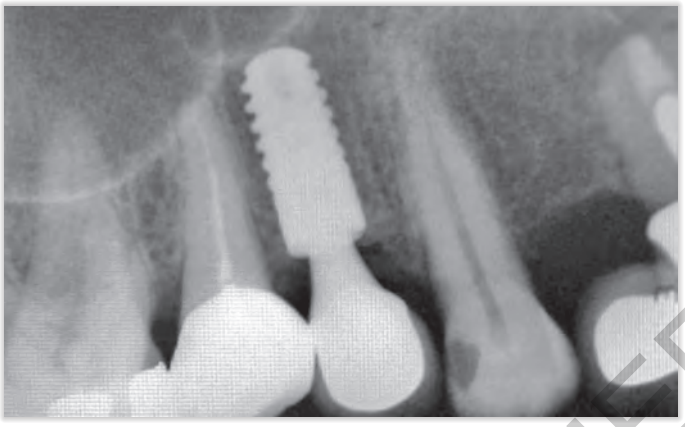

Fig. 2.9B: Ankylos implant after a loading period of 2 years. Note excellent crestal bone stability.

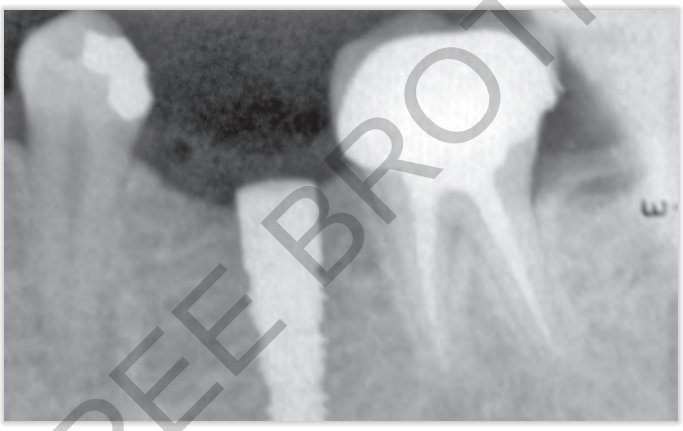

Fig. 2.9C: Implant placed on the day of surgery.

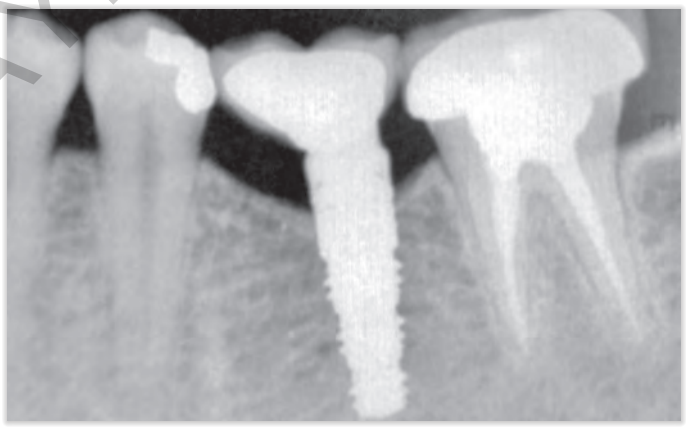

Fig. 2.9D: Same implant with butt joint implant abutment connection after 2 year. Note saucerization of the crestal bone.

JAYPEE BROTHERS



Fig. 2.10: Step in preparation of surgical stent.

PLANNING CONSIDERATIONS

Planning should commence keeping in mind the aesthetic and functional requirements of the patients. It should then proceed in more detail with intraoral examination, radiographic assessment, study cast, diagnostic wax-up and surgical stents (Fig. 2.10).

FUNCTIONAL CONSIDERATIONS

Inability to masticate food is a common complaint of patients who have lost their posterior teeth or who may be wearing removable dentures. The stability and retention of dentures can be improved by making them implant supported. If enough bone is present in the posterior region the patient can even opt for a fixed implant supported bridge instead of a removable denture (Figs. 2.11A and B).



Fig. 2.11A: Fixed implant supported prosthesis.

JAYPEE BROTHERS

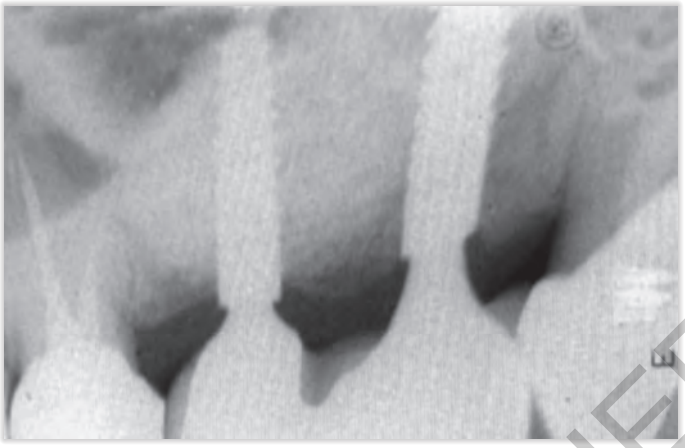

Fig. 2.11B: Radiographic view of the implant supported prosthesis done after lateral window sinus lift.



Fig. 2.12: Without provisional removable partial denture.

JAYPEE BROTHERS

AESTHETIC CONSIDERATIONS

In some patients, aesthetic consideration plays a important role. It is important to note the amount of coverage of the anterior teeth and the gingiva by the lips of the patient at rest and also during smiling. Patients exhibiting a high smile line in which more teeth and gingiva are visible during smiling extra care should be taken. The patient should be examined with and without the current removable or fixed provisional denture to asses facial contour, lip support, teeth position and how much of the teeth are visible during function (Figs. 2.12 and 2.13).

On evaluation of the edentulous ridge, the height, width, contour and deficiencies can be visibly seen and manually palpated to assess their quality for implantation. The presence of deficiencies especially on the labial and



Fig. 2.13: With provisional removable partial denture.

buccal aspects of the ridge are readily apparent. However, the exact width of the bony ridges underneath the thick soft tissue, especially the palatal fibrous tissues cannot be accurately determined by just palpation. Ridge mapping using especially designed calibrated calipers (Fig. 2.14A) or by using graduated periodontal probes or endodontic files with stoppers are highly recommended in absence of computerized tomograms[1] (Fig. 2.14B).

STUDY CAST AND DIAGNOSTIC SET-UP

Articulated study casts help the clinician in making detailed measurements of many factors which are to be considered in the treatment plan (Fig. 2.15).



Fig. 2.14A: Especially designed calibrated caliper.

JAYPEE BROTHERS



Fig. 2.14B: Ridge mapping done with the aid of endodontic file.



Fig. 2.15: Articulated study cast.

JAYPEE BROTHERS

The teeth to be replaced can be positioned on the cast by wax build ups using denture teeth. The diagnostic set-up therefore helps in determining the number and position of the implants to be placed and also the future prosthodontic rehabilitation. It also helps in determining the occlusal relationship with the opposing dentition. Once the diagnostic step is ready, it can be used to prepare a blow-down surgical stent (Fig. 2.16). The blow-down stent could also have radiopaque markers in areas where implants need to be placed. The patient then wears the stent with the markers and gets an panoramic radiograph taken (Figs. 2.17A and B).

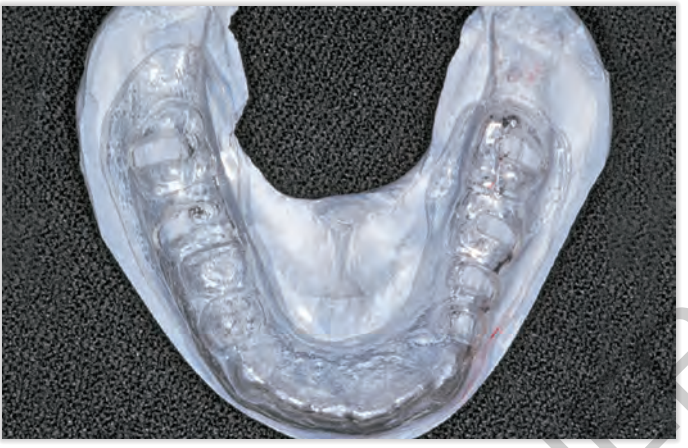

Fig. 2.16: Blown down surgical stent.



Fig. 2.17A: Stent with radiographic markers.

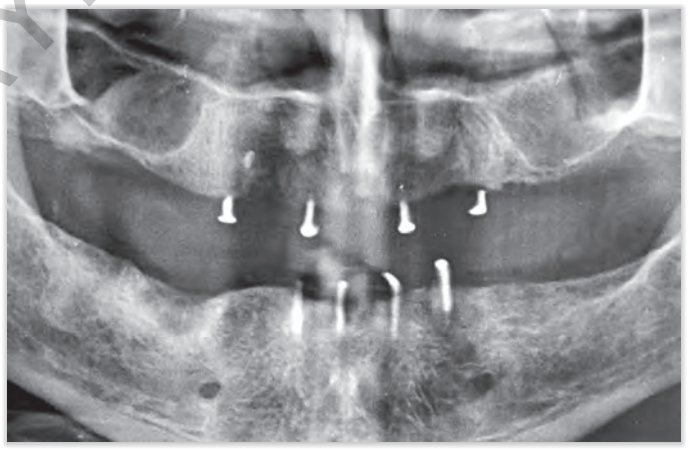

Fig. 2.17B: OPG showing radiographic markers.

JAYPEE BROTHERS

for detailed information on dental books, visit our website www.jaypeebrothers.com, for detailed information on dental books, visit our website w

About the Authors



Prof. Dr. Porus S. Turner

Prof. Dr. Porus S. Turner
Professor Emeritus, A.B. Shetty Institute of Dental Sciences, NITTE University, Mangaluru, Karnataka, India.
Past President and Accredited member of Indian Academy of Aesthetic and Cosmetic Dentistry.
Accredited by Dentsply Friadent, Germany to give 'ANKYLOS' system courses in India.
Principal faculty Dr. Turner speciality (CDE) courses.
30 Original Publications.
Contributor to Two Books.
Consultant to Bhabha Atomic Research Centre, Mumbai, India.
Consultant to Tata Institute of Fundamental Research Mumbai, India
International Speaker on Restorative Dentistry and Oral Implantology.
Accredited by Goethe University Gemany as a tutor for Master of Oral implantology Degree courses in India.
Conducts the very popular Oral Implantology courses under the auspices of the Indian Dental Association for the past five years.

Dr. Ferzin Turner Vazifdar

Dr. Ferzin T Vazifdar has specialized in Orthodontics and Aesthetic Implant Dentistry. Her extensive experience in dental technology, gives her synergistic advantage in restorative dentistry. She conducts a specialty dental practice in Mumbai and is a partner to ADARO Dental Laboratory.

Dr. Ashdin P. Turner

Dr. Ashdin P Turner has specialized in Prosthodontics and Aesthetic Implant Dentistry. He has published articles on "Implant Dentistry and Restorative Dentistry" and has lectured on the subjects, both in India and abroad.

Mr. Danesh R. Vazifdar

Mr. Danesh R Vazifdar has undergone training in Germany, Canada, Hong Kong and United States in dental technology and regularly gives courses in the subject. He runs a "State of the Art" commercial dental lab in Mumbai (ADARO Dental Laboratory) specializing in Implant supported prosthesis and CAD CAM Restorations.

Available at all medical bookstores or buy online at www.jaypeebrothers.com

JAYPEE BROTHERS
Medical Publishers (P) Ltd.
www.jaypeebrothers.com

Join us on facebook.com/JaypeeMedicalPublishers

Shelving Recommendation
DENTISTRY

ISBN 978-93-5270-427-9