ed information on PGMEE books, visit our website **www.jaypeebrothers.com,** for detailed information on PGMEE books, visit our website **www.jaypeebrothers.com**

ECG Analysis
Pathology
Radiology
Internal Medicine
Pediatrics
Dermatology
Surgery
Obstetrics and Gynecology
Ophthalmology
ENT
Orthopedics
Microbiology
PSM
Pharmacology
Forensic Medicine
Anatomy
Biochemistry
Physiology
Anesthesia
Psychiatry

*NEET Pattern Questions With Explanatory Answers*

# Final Edge

## Image-based Questions

**WHY SHOULD YOU BUY THIS BOOK?**

- High-resolution images to enable students to pick nuances of clinical diagnosis
- 90+ Electrocardiograms with interpretation tricks
- 100+ Histopathology slides including immunofluorescence slide interpretation
- 150+ Case based X-Rays
- 100+ CT/MRI based clinical questions on NEET Pattern
- Clinical questions with multi-disciplinary approach

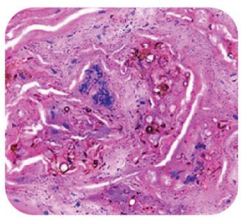



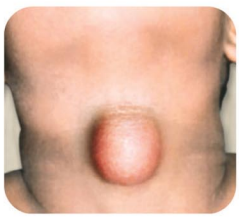

**Deepak Marwah**

**3rd Edition**

JAYPEE

# Contents


| | | |
|---|---|---|
| 1. | ECG Analysis | 1 |
| 2. | Pathology | 34 |
| 3. | Radiology | 99 |
| 4. | Internal Medicine | 144 |
| 5. | Pediatrics | 199 |
| 6. | Dermatology | 251 |
| 7. | Surgery | 298 |
| 8. | Obstetrics and Gynecology | 367 |
| 9. | Ophthalmology | 397 |
| 10. | ENT | 442 |
| 11. | Orthopedics | 472 |
| 12. | Microbiology | 507 |
| 13. | Preventive and Social Medicine | 569 |
| 14. | Pharmacology | 602 |
| 15. | Forensic Medicine | 626 |
| 16. | Anatomy | 652 |
| 17. | Biochemistry | 713 |
| 18. | Physiology | 730 |
| 19. | Anesthesia | 760 |
| 20. | Psychiatry | 782 |

# Most Recent Questions-Radiology

**1. Identify the given X-ray.** *(AIIMS Nov 2018)*

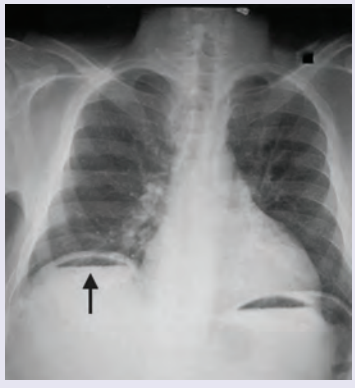

a. Pneumo-peritoneum
b. Emphysema
c. Diaphragmatic hernia
d. Diaphragmatic eventration

**2. Identify the type of investigation done.** *(AIIMS Nov 2018)*



a. Angiography
b. Myelography
c. Neurography
d. Fluoroscopy

**3. Identify the given X-ray image.** *(AIIMS Nov 2018)*



a. Cervical rib
b. Costochondritis
c. Fracture of 2nd rib
d. Spondylolisthesis

**4. A 75-year-female has chronic backache. X-ray spine is shown. What is the most likely diagnosis?** *(Recent NEET Pattern 2019)*



a. Pott's spine
b. Osteoporosis
c. Spondylolisthesis
d. Spondylodiscitis

1. (a) 2. (b) 3. (a) 4. (b)

JAYPEE BROTHERS

## Answers with Explanations

**1. Ans. (a) Pneumo-peritoneum**

*(Reference: Page 594: Grainger and Allison diagnostic radiology, 6th edition)*

The image shows gas under diaphragm which is a feature of pneumo-peritoneum.

Emphysema would have flattening of diaphragm. Diaphragmatic hernia would have loops of bowel in the chest. Diaphragmatic eventration is *unilateral elevated contour of diaphragm* due to incomplete muscularization of diaphragm.

**2. Ans. (b) Myelography**

*(Reference: Page 1287: Grainger and Allison diagnostic radiology, 6th edition)*

- The image shows contrast within the vertebral bodies is myelography.
- *Angiography* would obviously show vessels. *MR Neurography* is done using a 3-tesla MRI to identify the nerve roots. *Fluoroscopy* is done in the cath lab while performing coronary angiography where you can see the dye filling the coronaries.

**3. Ans. (a) Cervical rib**

*(Reference: Page 186: Grainger and Allison diagnostic radiology, 6th edition)*

The X-ray shows AP view of cervical spine with bilateral clavicles and bilateral cervical rib. In order to differentiate it from the transverse process of vertebrae trace it backwards. Remember the transverse process of T1 slants upwards while the *transverse process of C7 slants downwards.*

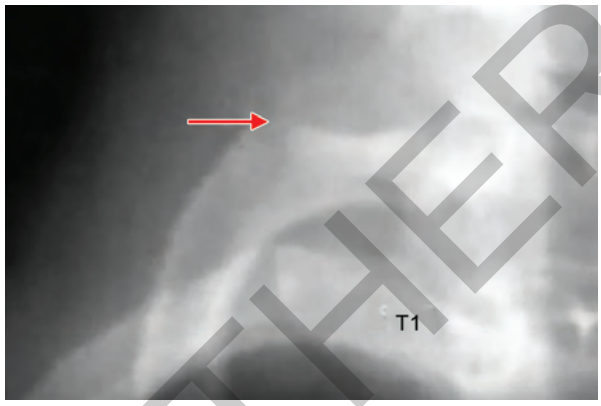


The arrow mark is arising from the body of seventh cervical vertebra and hence is the cervical rib. It leads to development of thoracic outlet syndrome.

**4. Ans. (b) Osteoporosis**

*(Reference: Page 3, Differential diagnosis in conventional radiology: 3rd edition)*

- The image shows X-ray of lumbo-sacral spine showing *codfish or fish mouth vertebra* with *irregularly reduced* intervertebral joint space. This is a feature of osteoporosis.
- The bone softening leads to exaggeration of the normal concavity of the superior and inferior surfaces of one or more vertebral bodies.

JAYPEE BROTHERS

CHAPTER

# 3

# Radiology

**1. A 6 month infant was brought with complaints of a failure to gain weight and a large head. On examination, increased head circumference, bounding pulses and features of heart failure were noted. On cranial auscultation loud cranial bruit was heard. MRI head shows?** *(Recent NEET Pattern 2018-19)*

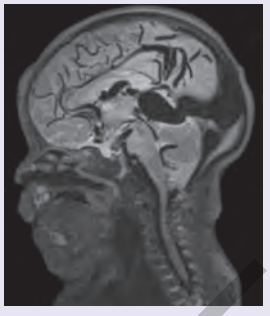

a. Vein of Galen formation
b. Arachnoid cyst
c. Arnold-Chiari malformation
d. Dandy-Walker syndrome

**2. Identify the marked structure in the CT abdomen section shown below?** *(Recent NEET Pattern 2018-19)*

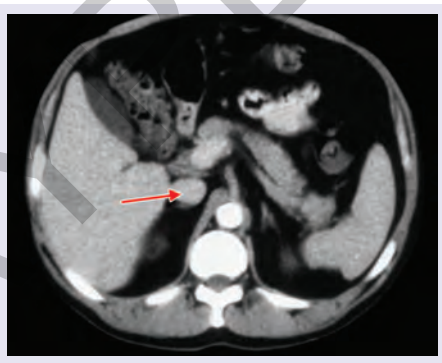

a. Aorta
b. Superior mesenteric artery
c. Inferior vena cava
d. Superior mesenteric vein

**3. A 65-year-old man presents with bone pains. X-ray Skull shows?** *(Recent NEET Pattern 2018-19)*

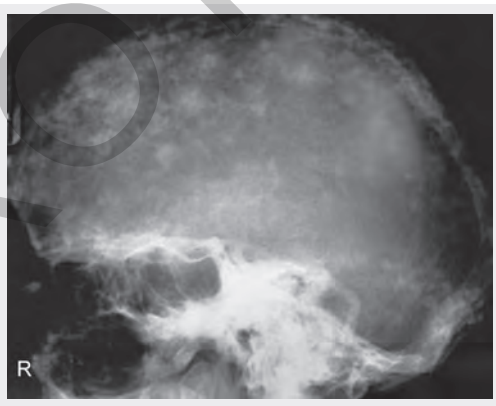


a. Paget's disease
b. Fibrous dysplasia
c. Histiocytosis-X
d. Multiple myeloma

**4. A 35-year-old male with history of 4 weeks of immobilization for fracture of femur develops sudden onset breathlessness and blood in sputum. CT angiography shows?** *(Recent NEET Pattern 2018-19)*

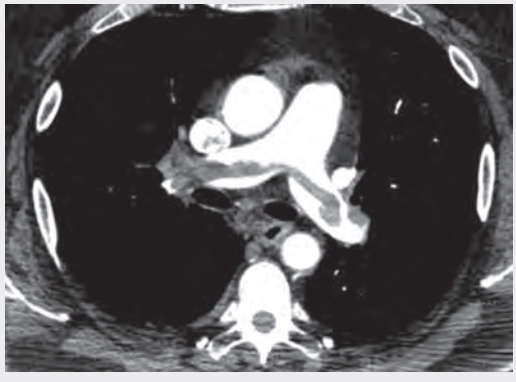

a. Acute cor-pulmonale
b. Pulmonary oedema
c. Aortic dissection
d. Fat embolism

1. (a) 2. (c) 3. (a) 4. (a)

JAYPEE BROTHERS

**5. A 9-year-old female child presents with history of headache and visual disturbances. X-Ray skull is shown below. What is the possible diagnosis?** *(Recent NEET Pattern 2018-19)*

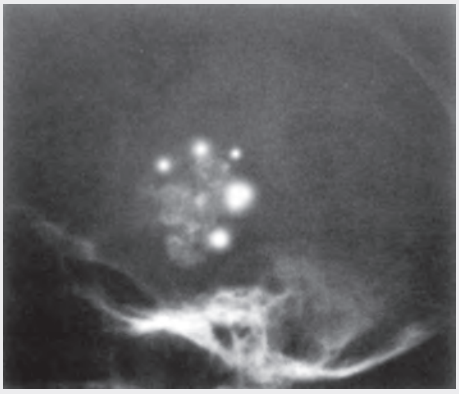

a. Hypothalamic hamartoma
b. Craniopharyngioma
c. Histiocytosis- X
d. Letterer-Siwe disease

**6. A 32-year-old lady presents with history of first trimester miscarriage and underwent HSG. The diagnosis is:** *(Recent NEET Pattern 2018-19)*



a. Unicornuate uterus
b. Bicornuate uterus
c. Uterus didelphys
d. Arcuate uterus

**7. Identify the structure shown in CT abdomen section.** *(Recent NEET Pattern 2018-19)*

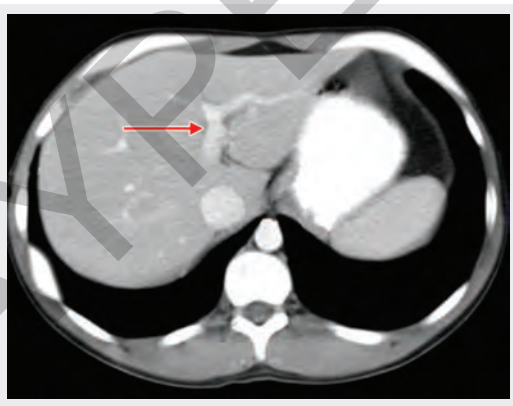

a. Inferior vena Cava
b. Portal vein
c. Splenic vein
d. Superior mesenteric vein

**8. The Gut blood vessel marked (Red arrow) in the angiogram is:** *(Recent NEET Pattern 2018-19)*

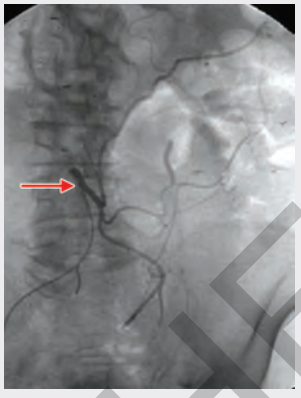

a. Superior mesenteric artery
b. Inferior mesenteric artery
c. Splenic artery
d. Gastroepiploic artery

**9. Comment on the arrow marked structure in CXR of an infant:** *(Recent NEET Pattern 2018-19)*

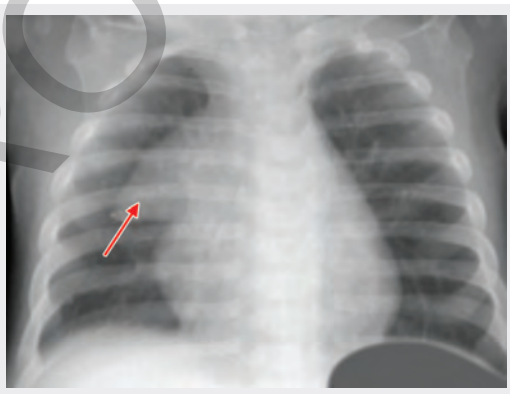

a. Lingular lobe pneumonia
b. Sail sign
c. Pneumothorax
d. Dextrocardia

**10. The digital subtraction angiography given below shows?** *(AIIMS Nov 2017)*

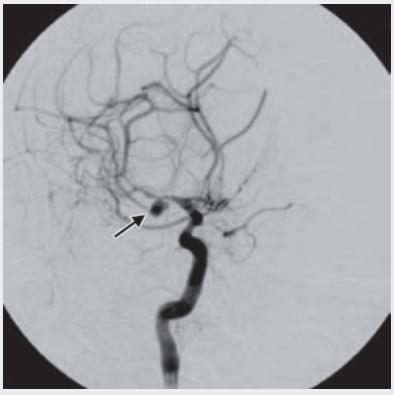

a. Intra-cranial pseudo-aneurysm
b. Carotid-cavernous fistula
c. Angiofibroma tumor blush
d. Vein of Galen malformation

5. (b) 6. (a) 7. (b) 8. (b) 9. (b) 10. (a)

JAYPEE BROTHERS

**11. Which is not a finding of the Chest X-ray shown below?** *(AIIMS May 2017)*

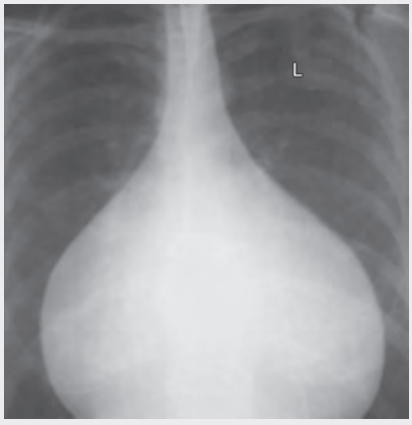


a. Narrow vascular pedicle
b. Pulmonary venous hypertension
c. Increased CT ratio
d. Acute cardiophrenic angle

**12. Comment on the diagnosis from the thyroid scan shown below.** *(AIIMS May 2017)*

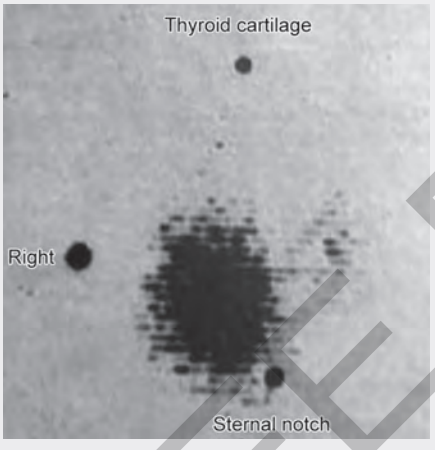


a. Papillary cancer thyroid
b. Hypersecreting adenoma
c. Grave's disease
d. Lateral aberrant thyroid

**13. Which of these is best for imaging the lesion removed from kidney of a 60-year-old man?**



a. USG
b. Helical CT
c. Helical CT with contrast
d. MRI

**14. Identify the image given below.**

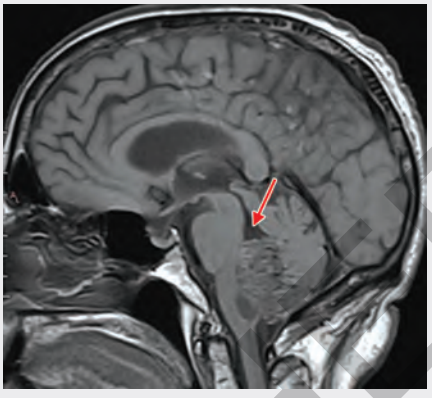

a. Lateral ventricle
b. Corpus callosum
c. 3rd ventricle
d. 4th ventricle

**15. Which of the following investigation must be performed before giving the agent shown to a patient?**




a. Serum creatinine
b. C3 levels
c. Urine specific gravity
d. Serum electrolytes

**16. The Lateral view X-ray lung shows:**

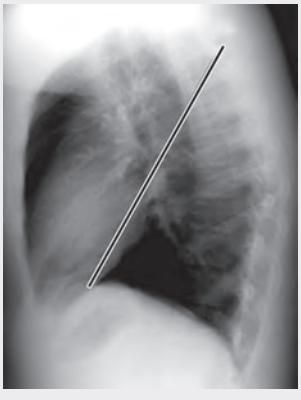

a. Major fissure
b. Minor fissure
c. Azygos fissure
d. Transverse fissure

11. (b) 12. (b) 13. (b) 14. (d) 15. (a) 16. (a)

JAYPEE BROTHERS

**17. Comment on the diagnosis of the image shown below.**

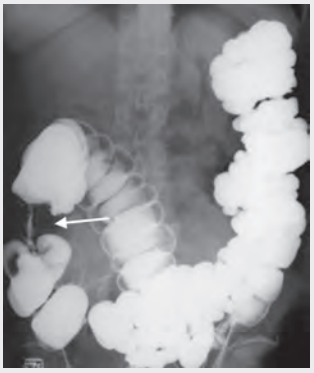

a. Apple core appearance
b. Claw sign
c. Coffee bean appearance
d. String sign of Kantor

**18. A patient has developed a disease shown below after receiving neck irradiation. Which is the best management for the patient?**

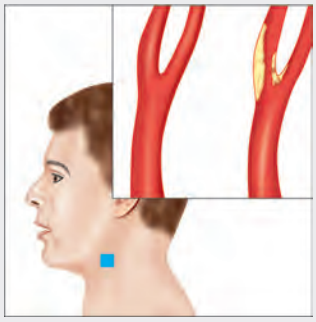

a. Low dose Aspirin
b. Carotid angioplasty and stenting
c. Carotid endarterectomy
d. Carotid bypass procedure

## Chest X-Ray

**19. A previously healthy patient, presents with dyspnea and low grade fever since 4 months. His lungs are clear. JVP is normal. ECG showed low voltage complexes. What is the possible diagnosis?**



a. Syphilitic aortic aneurysm
b. Hypertrophic cardiomyopathy
c. Rheumatic mitral stenosis
d. Tuberculous pericardial effusion

**20. Which is the most likely diagnosis based on this X-ray?** *(Recent NEET Pattern 2016-17)*



a. Hydatid cyst right lung
b. Right pleural effusion
c. Right hydropneumothorax
d. Perforated abdominal viscus

**21. What is the diagnosis based on the CXR of a patient of cystic fibrosis shown below?**



a. Round pneumonia with perihilar shadows
b. Hilar lymphadenopathy with coin shadows
c. Bi-basilar fibrosis
d. Egg shell calcification

**22. Identify the pathology:** *(Recent NEET Pattern 2016-17)*

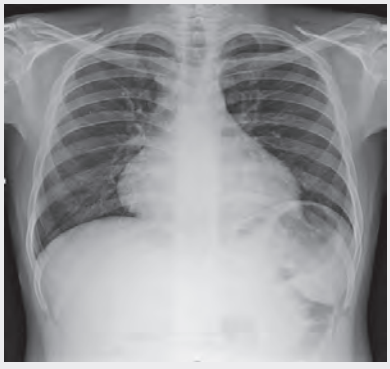

a. Pericardial effusion
b. Boot shaped heart
c. Egg on side appearance
d. Normal-sized heart

17. (a) 18. (b) 19. (d) 20. (d) 21. (a) 22. (a)

JAYPEE BROTHERS

**23. A 30-year-old hypertension patient presents with daily headaches. The CXR given below shows which of the following?** *(Recent NEET Pattern 2016-17)*

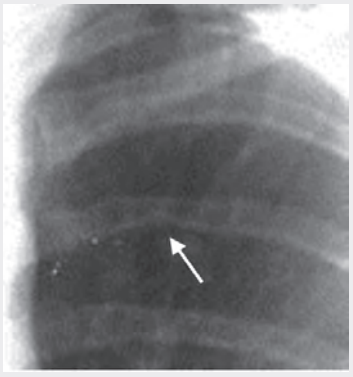

a. Preductal coarctation
b. Postductal coarctation
c. Aortic dissection
d. Takayasu arteritis

**24. Identify the chamber enlargement:**

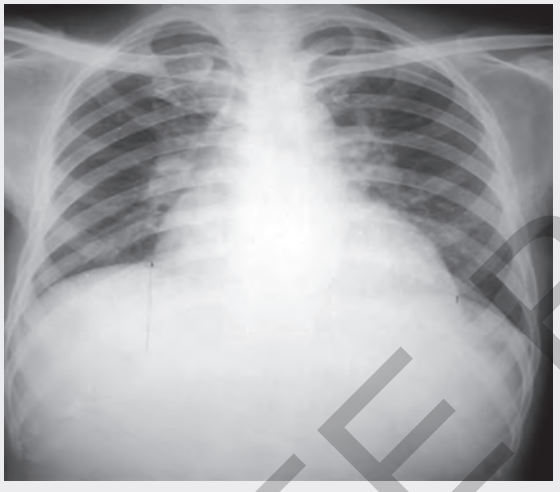

a. Left atrium
b. Left ventricle
c. Right atrium
d. Right ventricle

**25. Identify the chamber enlargement:**

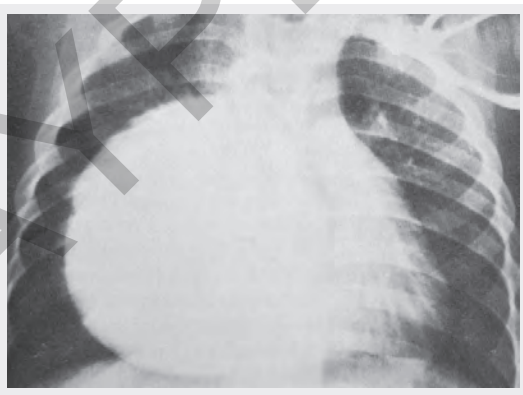

a. Right atrium
b. Left atrium
c. Left ventricle
d. Right ventricle

**26. Identify the chamber enlargement:**

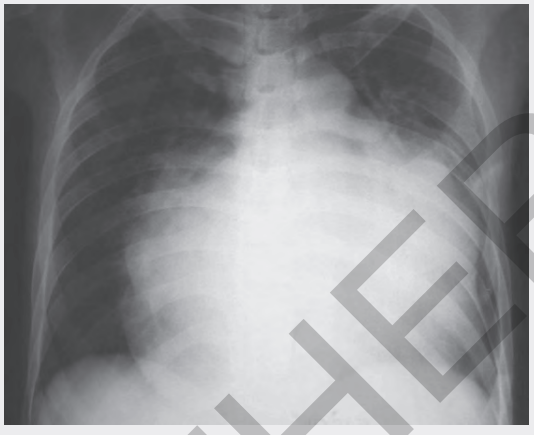

a. Right atrium
b. Left atrium
c. Left ventricle
d. Right ventricle

**27. Identify the chamber enlargement:**



a. Right atrium
b. Left atrium
c. Left ventricle
d. Right ventricle

**28. Identify the congenital heart disease presenting with cyanosis in CXR:** *(Recent NEET Pattern 2016-17)*

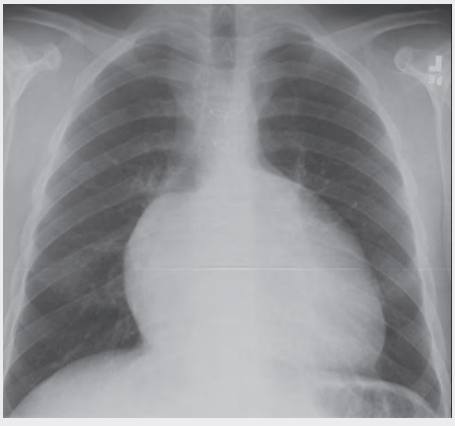

a. Tetralogy of Fallot
b. Pentalogy of Fallot
c. Ebstein anomaly
d. Snowman heart

23. (b) 24. (b) 25. (a) 26. (b) 27. (d) 28. (c)

JAYPEE BROTHERS

**29. An adult undergoes multiple FFP transfusions for excessive bleeding after cardiac surgery and develops respiratory distress. CXR done is shown below. What does it indicate?** *(Recent NEET Pattern 2016-17)*

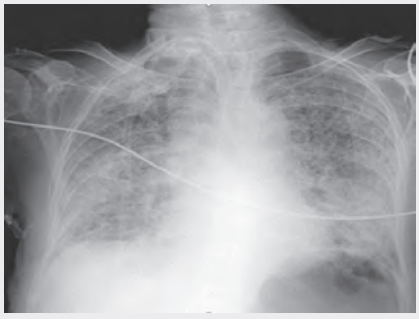

a. Volume overloading of heart
b. Mendelson's syndrome
c. Pneumomediastinum
d. TRALI

**30. A 35-year-old hypertension patient has the following CXR in annual medical check up. What does it show?**



a. Left ventricular hypertrophy
b. Pulmonary artery hypertension
c. Coarctation of aorta
d. Cor pulmonale

**31. A breast cancer patient presents with difficulty in breathing. CXR shows:** *(Recent NEET Pattern 2016-17)*



a. Canon ball metastasis
b. Pneumothorax
c. Pulmonary artery hypertension
d. Interstitial lung disease

**32. Which of the following is shown in the image below?**

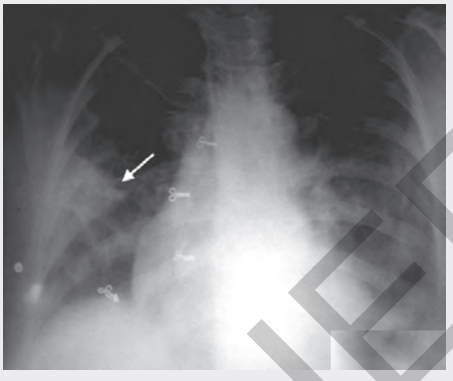

a. Westermark sign
b. Palla sign
c. Hampton hump
d. Round pneumonia

**33. A 35-year-old lady presents with fever, skin rash and dyspnea on exertion for last 2 months. CXR shows:**

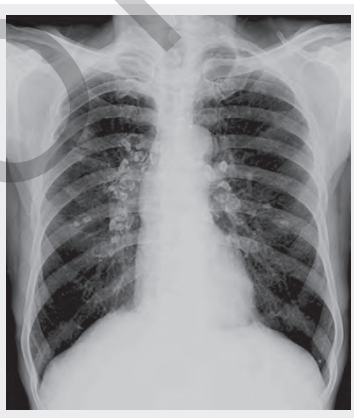

a. Shrinking lung syndrome
b. Sarcoidosis
c. Rheumatoid lung
d. Desquamative interstitial pneumonitis

**34. An AIDS patient presents with respiratory distress. CXR shows:** *(Recent NEET Pattern 2016-17)*



a. Pneumocystis pneumonia
b. Miliary TB
c. Streptococcal pneumonia
d. Lymphocytic interstitial Pneumonitis

29. (d) 30. (c) 31. (a) 32. (c) 33. (b) 34. (b)

JAYPEE BROTHERS

**35. A short stature female presents with history of wearing socks in summer season. Physical examination shows icy cold toes with cyanosis. CXR done shows:** *(Recent NEET Pattern 2016-17)*

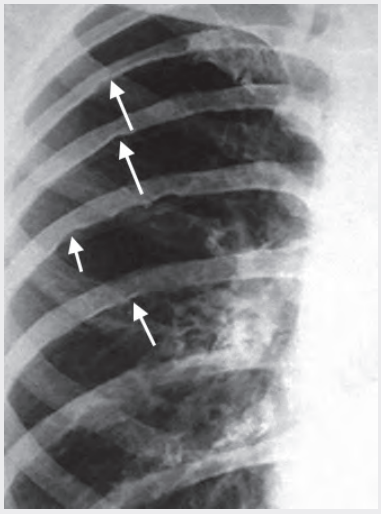

a. Hyperparathyroidism
b. Neurofibromatosis
c. Coarctation of aorta
d. Multiple myeloma

**36. CXR was done for a 15-year-old boy with low cardiac output. Which is incorrect about the patient?**

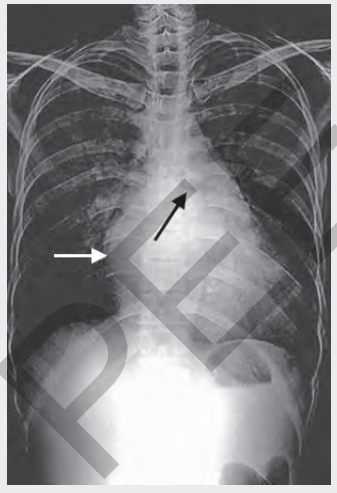

a. Reverse split S1
b. Straightening of left heart border
c. Carey Coombs murmur
d. Sea gull murmur

**37. What is the radiological sign demonstrated in the image provided?** *(Recent NEET Pattern 2016-17)*

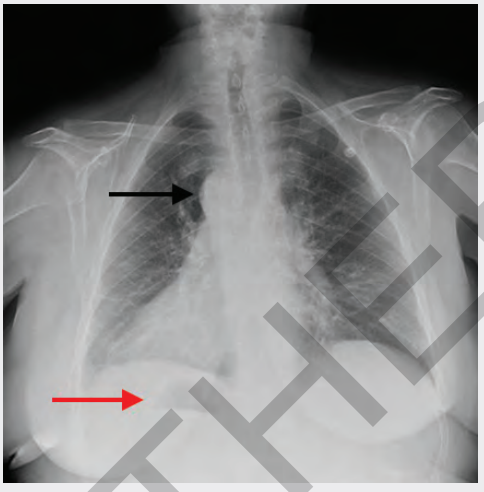

a. Bat wing sign
b. Gas under diaphragm
c. Situs inversus
d. Money bag appearance

**38. A 1-day-old neonate, home delivery is brought with respiratory distress. The given CXR shows:**

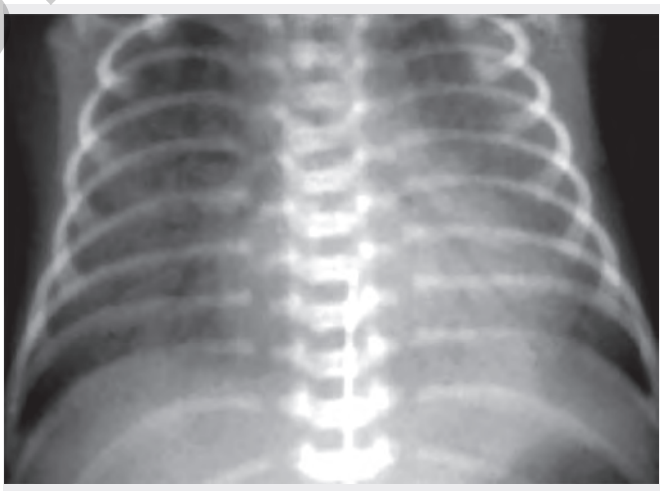

a. Hyaline membrane disease
b. Meconium aspiration syndrome
c. Transient Tachypnea of newborn
d. Congenital diaphragmatic hernia

35. (c) 36. (d) 37. (c) 38. (a)

JAYPEE BROTHERS

**39. Provide the diagnosis based on the presentation given below:** *(Recent NEET Pattern 2016-17)*

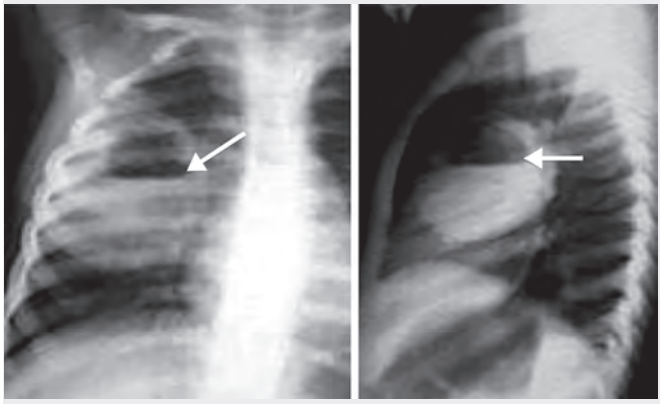

a. Lung abscess
b. Lobar emphysema
c. Segmental collapse
d. Bronchiectasis

**40. A 6-month-old child is on Vancomycin for pneumonia for 2 days. He develops worsening of respiratory distress and $SpO_2$ falls to 80%. The CXR performed is shown below. What is the diagnosis?**

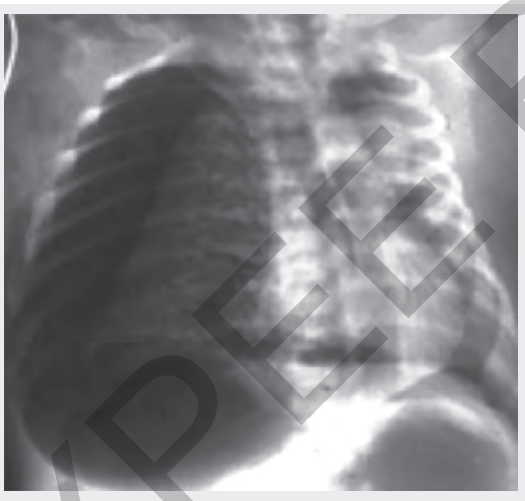

a. Lung abscess
b. Empyema
c. Pneumothorax
d. Segmental collapse

## CT Chest

**41. The X mark in the following CT chest shows:**

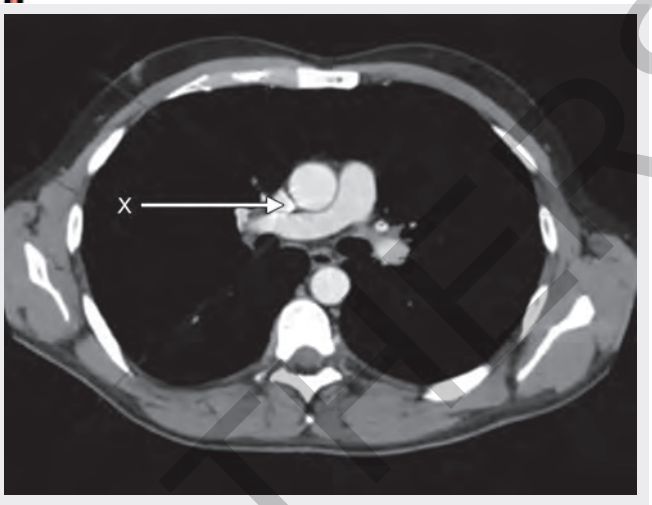


a. Ascending aorta
b. Descending aorta
c. Superior vena cava
d. Inferior vena cava

**42. What does the following CT chest show?** *(Recent NEET Pattern 2016-17)*

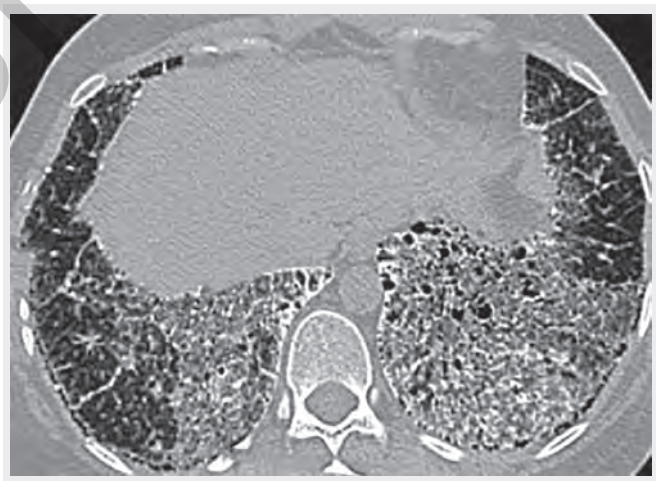

a. Ground glass appearance
b. Honey comb pattern
c. Signet ring pattern
d. Crazy pavement pattern

JAYPEE BROTHERS

Answers

39. (a) 40. (c) 41. (c) 42. (d)

**43. The following CT chest shows:**

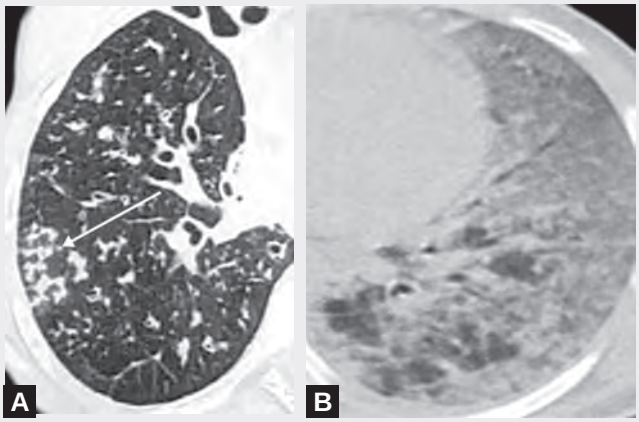


a. A= Tree in Bud appearance, B= Ground glass pattern
b. A= Crazy pavement pattern, B= Tree in bud appearance
c. A= Mosaic perfusion pattern, B= Crazy pavement pattern
d. A= Broncho vascular nodular pattern, B= Ground Glass pattern

**44. What does the following CT chest show?**

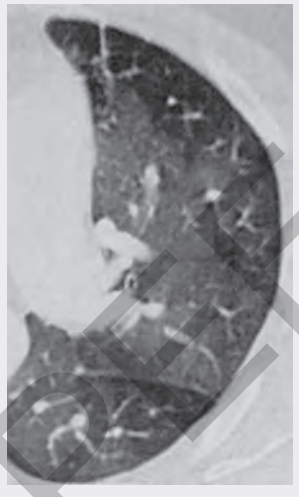

a. Honey comb pattern
b. Signet ring pattern
c. Crazy pavement pattern
d. Mosaic pattern

**45. The lung parenchyma on CT chest shown below is best described as:** *(Recent NEET Pattern 2016-17)*

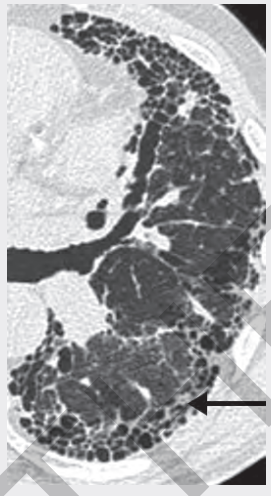

a. Honey comb pattern
b. Signet ring pattern
c. Crazy pavement pattern
d. Mosaic pattern

**46. The following lung window in CT chest is taken in which phase of respiration?**

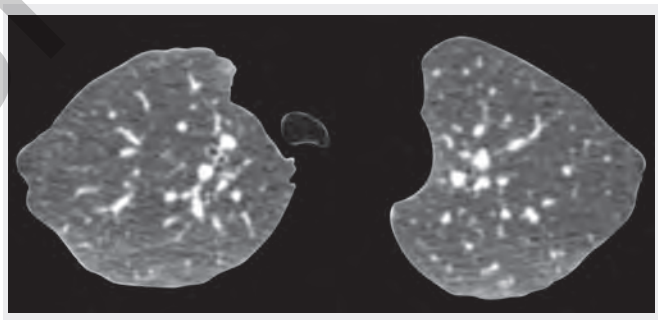

a. End inspiratory phase
b. End expiratory phase
c. Mid inspiratory
d. Cannot be determined

43. (a) 44. (d) 45. (a) 46. (b)

JAYPEE BROTHERS

**47. An 18-year-old boy is brought to the hospital with difficulty in breathing after a bar fight. What does the given CT chest show?**
*(Recent NEET Pattern 2016-17)*

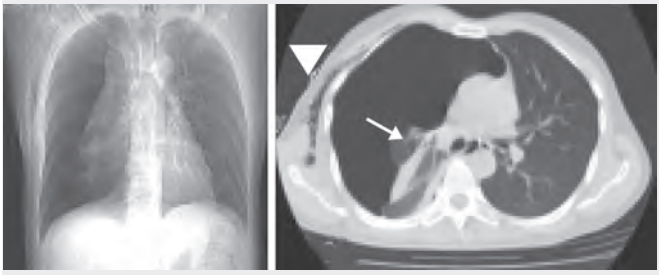

a. Pneumothorax
b. Consolidation
c. Pulmonary contusion
d. Haemothorax

**48. The arrow in the given CT chest points to:**

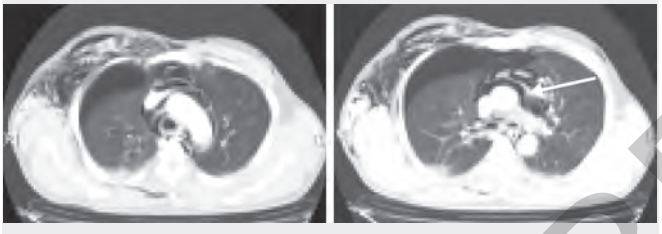

a. Pericardial effusion
b. Pneumo-mediastinum
c. Diaphragmatic rupture
d. Diaphragmatic eventration

**49. A cement slab fell on the chest of a 20-year-old construction worker. The arrow in the given CT chest points to:**
*(Recent NEET Pattern 2016-17)*



a. Lung contusion
b. ARDS
c. Diaphragmatic rupture
d. Pneumothorax

**50. A cement slab fell on the chest of a 20-year-old construction worker. His condition deteriorated over the next 24 hours after admission. A repeat CT chest was performed. What does it show?**

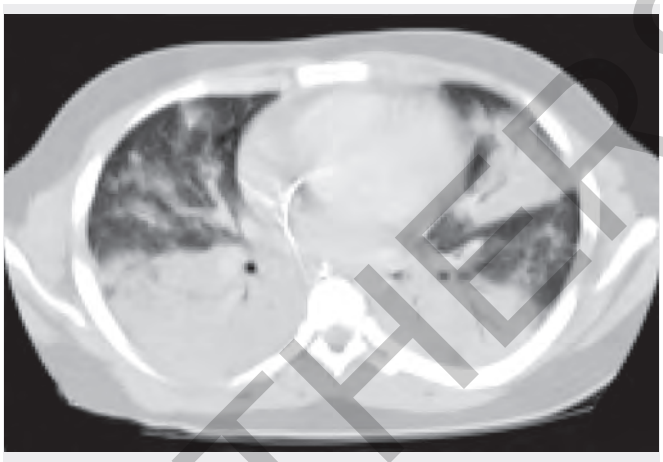

a. Bronchiolitis obliterans organising pneumonia
b. Hemothorax
c. ARDS
d. Cardiac tamponade

**51. A 25-year-old corporate executive was stabbed in the abdomen in a discotheque. In the emergency CXR and CT chest was performed. The radiologist then put an NG tube in the patient, injected contrast and repeated the scan. What is the diagnosis?**

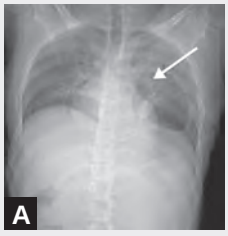





a. Diaphragmatic injury
b. Hemothorax
c. Pneumothorax
d. Cardiac Tamponade

47. (a) 48. (b) 49. (a) 50. (c) 51. (a)

JAYPEE BROTHERS

for detailed information on PGMEE books, visit our website **www.jaypeebrothers.com,** for detailed information on PGMEE books, visit our website **www.jaypeebro**

# Final Edge
## Image-based Questions

The third edition of Final Edge is a simulator for your clinical mind and exclusively designed to give you the final edge over intense competition. The book is a compilation of all the possible clinical scenarios which have been asked in various examinations and may be repeated in the future. This book provides a comprehensive and easy-to-grasp insight into the world of image-based questions.

The new pattern of examination has loads of image-based MCQs, creating an unpredictable atmosphere and doubts in even the best of brains.

This compilation is dedicated to all those young inquisitive minds, who have endured all the long study hours, feeling of despair and finally, relief when the results are out.

***Salient Features***

- The book consists of an adequate number of questions such that all critical areas are covered and no time is wasted over unnecessary questions.
- Written by a leading national level faculty with a vast experience of over 12 years of teaching Internal Medicine to PGMEE students.
- This book will be the first visual dictionary for all the medical conditions that are relevant for cracking PG exams.
- Quick revision of all the 20 subjects by decreasing the heavy load of reading the text and trying to remember the content.
- Experience the learning in the form of art and illustrations with an added edge of theory to it.

***Students' Reviews***

The one book to rule them all. An image book that is comprehensive and lucid to the bone. Covers all 19 subjects plus one bonus on ECG strips and tricks with full colored detailed images covering each and every high yield topics with extensive in detail explanation for each and every question. With the major bulk of today's exam questions coming from images, and authored by a teacher with unparalleled clinical acumen, it is a MUST READ book for every PGMEE exam aspirants because it is one stop success in there.

*—Aditya Bhatt, Intern, Baroda Medical College*

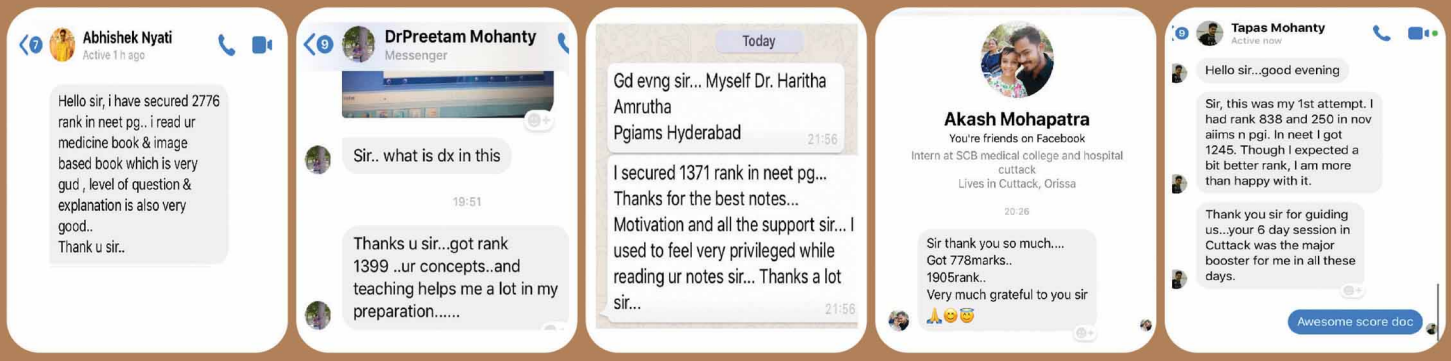


**Deepak Marwah** is an alumnus of Maulana Azad Medical College, New Delhi and loves to teach doctors in their quest for higher studies and has several published titles to his credit. Many students who have attended his extensive sessions have gone on to excel in various examinations. The author has taught students preparing for various examinations ranging from MCCQE1 (Canada), USMLE and PGMEE. His fluent delivery and simplified approach of a complicated subject like Internal Medicine has been appreciated by the students and testimonials can be seen on his Facebook page.

*Printed in India*

**Available at all medical bookstores or buy online at www.ejaypee.com**

**JAYPEE BROTHERS**
**Medical Publishers (P) Ltd.**
**EMCA House, 23/23-B, Ansari Road, Daryaganj, New Delhi - 110 002, INDIA**
**www.jaypeebrothers.com**

Join us on facebook.com/JaypeeMedicalPublishers
Follow us on instagram.com/JaypeeMedicalPublishers

ISBN 978-93-5270-431-6