rs.com, for detailed information on PGMEE books, visit our website www.jaypeebrothers.com, for detailed information on PGMEE books



Mastering NEET Series

Volume 1

Non-clinical Subjects

(Illustrated and concise guide to 'NEET' pattern question bank)

Anatomy, Physiology, Biochemistry, Pathology, Microbiology
Parasitology, Pharmacology, Forensic Medicine
Preventive and Social Medicine

Kamal KV

2nd Edition

JAYPEE

Contents

1. Anatomy **1**

Key Points 1
MCQs with Short Explanations 6
Answers with References 71
Practice Questions 80
Image-Based Questions 85
MCQ Points 88

2. Physiology **93**

Key Points 93
MCQs with Short Explanations 96
Answers with References 171
Practice Questions 180
Image-Based Questions 183
MCQ Points 185

3. Biochemistry **189**

Key Points 189
MCQs with Short Explanations 192
Answers with References 259
Practice Questions 267
Image-Based Questions 269
MCQ Points 271

4. Pathology **273**

Key Points 273
MCQs with Short Explanations 277
Answers with References 363
Practice Questions 370
Image-Based Questions 374
MCQ Points 377

5. Microbiology **381**

Key Points 381
MCQs with Short Explanations 385
Answers with References 442
Practice Questions 447
Image-Based Questions 450
MCQ Points 452

6. Parasitology **459**

Key Points 459
MCQs with Short Explanations 460
Answers with References 479
Practice Questions 480
Image-Based Questions 481
MCQ Points 484

7. Pharmacology **485**
Key Points 485
MCQs with Short Explanations 489
Answers with References 549
Practice Questions 556
Image-Based Questions 559
MCQ Points 562

8. Forensic Medicine **568**
Key Points 568
MCQs with Short Explanations 572
Answers with References 594
Practice Questions 598
Image-Based Questions 600
MCQ Points 602

9. Preventive and Social Medicine **604**
Key Points 604
MCQs with Short Explanations 612
Answers with References 685
Practice Questions 693
Image-Based Questions 698
MCQ Points 701

CHAPTER

1

ANATOMY

KEY POINTS

Sutures and Conditions Associated with Their Closure

- Dolichcocephaly/Scaphocephaly [Closure of sagittal suture (anteroposetrior widening)]
- Brachycephaly [Closure of coronal suture (transverse suture)]
- Oxycephaly/Acrocephaly/Turricephaly [All sutures are closed]

Structures Derived from Neural Crest

- Pia mater
- Dental papillae
- Adrenal medulla
- Schwann
- Melanoblasts
- Dorsal root ganglia
- Autonomic ganglia
- Cells belonging to APUD series
- Bones and connective tissues of craniofacial structures
- Cells of truncoconal; cushions of heart

Structures Derived from Pharyngeal Pouches

- 1st: Middle ear, Eustachian tube.
- 2nd: Tonsil
- 3rd: Upper-Inferior parathyroid; Lower-Thymus
- 4th: Upper-Superior parathyroid; Lower-Ultimobranchial body

Structures Derived from Pharyngeal Clefts

- 1st: External auditory canal
- 2nd, 3rd, 4th: Cervical sinus

Fetal Structures and Adult Remnants

- The extra hepatic portion of umbilical vein: The round ligament of the liver (ligamentum teres hepatic), which lies in the free edge of the falciform ligament
- The intrahepatic portion (ductus venosus): Ligamentum venosum
- Closure of ductus arteriosus: Ligamentum arteriosum
- Closure of distal part of Umbilical arteries: Medial umbilical ligament

Must Know Facts

- Just prior to ovulation, the primary oocyte enters and completes 1st meiotic division.
- During first 24 weeks, there is only fetal hemoglobin; after which adult type Hb appears, at term, 75-80 percent Hb is of fetal type, it is completely replaced by 4 months of age.
- Order of development of paranasal sinuses: Maxillary—Ethmoid—Frontal-Sphenoid.
- Occurrence of acute sinusitis and carcinoma in paranasal sinuses: Maxillary—Ethmoid—Frontal-Sphenoid.

Important Cells

- Gitter cells: Microglia
- Dieter cells: Outer hair cells of organ of Corti
- Hofbauer's cells: Ellipsoidal cells in chorionic villi of placenta
- Juxtaglomerular cells: Smooth muscle cells of afferent arteriole
- Ito cells: Stellate cells in liver
- Langerhans cells: Antigen presenting epithelial dendritic cells
- Glomus cells: Present in carotid bodies

Epithelium

- Simple squamous: Alveoli of lungs, mesothelium of pleura, peritoneum and pericardium, endothelium of heart and blood vessels
- Simple cuboidal: Lining of thyroid follicles, germinal epithelium of ovary
- Simple columnar: Lining of stomach, intestines, gall bladder
- Simple columnar ciliated: Fallopian tubes, uterus, osseous part of Eustachian tube

JAYPEE BROTHERS

- Keratinized stratified squamous: Epidermis of skin, external ear, external nose
- Non keratinized stratified: Esophagus, tongue, true vocal cords, cornea, tonsil
- Transitional: Calyces, ureter, urinary bladder, male urethra

Spaces Related to Upper Limb

i. Upper triangular space

- Medial boundary: Teres minor
- Lateral boundary: Long head of triceps
- Inferior boundary: Teres major
- Contents: Circumflex scapular artery

ii. Lower triangular space

- Medial boundary: Long head of triceps
- Lateral boundary: Medial border of humerus
- Superior boundary: Teres major
- Contents: Radial nerve and profunda brachii vessels

iii. Anatomical snuff box/radial fossa

- Anterior boundary: Abductor pollicis longus and extensor pollicis Brevis
- Posterior boundary: Extensor pollicis longus.
- Floor: Scaphoid, trapezium, radial artery
- Roof: Origin of cephalic vein, dorsal cutaneous branch of radial nerve
- Significance: Tenderness is suggestive of Scaphoid fracture

De Quervain's Stenosing Tenosynovitis

- Localized pain over radial styloid process
- Finkelstein's test is positive

Axial Arteries of Limbs

- Axial artery of upper limb: C7 intersegmental artery
- Axial artery of lower limb: L5 intersegmental artery

Infection of Hands and Their Spread to Spaces

- Thumb and index finger infection spreads to Thenar space
- Middle and ring fingers infection spread to Mid-palmar space
- Little finger infection spreads to borearm space of parona

Fascial Compartment of Thigh and Their Nerve-Artery

- Anterior: Femoral artery and Femoral nerve
- Medial: Profunda femoris artery and Obturator nerve
- Posterior: Branches of profunda femoris artery and Sciatic nerve

Fascial Compartment of Leg and Their Nerve-Artery

- Anterior: Anterior tibial artery and Deep peroneal nerve
- Lateral: Branches of peroneal artery and Superficial peroneal nerve
- Posterior: Posterior tibial artery and Tibial nerve

Contents of the Adductor Canal

- Terminal part of femoral artery
- Femoral vein
- Saphenous nerve
- Nerve to vastus medialis
- Terminal part of obturator nerve
- Deep lymph vessels

Must Know Facts

- Nutrient artery to the tibia is the largest nutrient artery in the body
- Housemaid's knee: Prepatellar bursitis
- Clergyman's knee: Infrapatellar bursitis

Bronchopulmonary Segments

- It is an anatomic, functional and surgical unit of the lung.
- As it is separated from rest of the lungs by a connective tissue septum, it can be separated surgically without affecting other segments
- It has a segmental bronchus, a segmental artery, lymph vessels and autonomic nerves.
- There are 10 segments on each side

Esophagus

- It is 10 inches/25 cm long
- Constrictions of esophagus: 15 cm (Cricopharynx); 25 cm (Aortic arch); 27 cm (Left bronchus); 40 cm (Diaphragmatic entry)
- Cricopharynx is the narrowest region of gastrointestinal tract.
- Esophagus shown three indentation on radiographic study; from above downwards they are: Aortic arch; Left bronchus; Left atrium
- Blood supply of esophagus: Upper third-Inferior thyroid artery; Middle third-Branches from descending thoracic aorta; Lower third-Left gastric artery

Diaphragmatic Hiatus

- Esophageal hiatus transmits: Esophagus, anterior and posterior vagal trunks
- Aortic hiatus transmits: Aorta, thoracic duct, Azygos vein

JAYPEE BROTHERS

Arterial Supply of Heart

- Right Coronary artery (Main branches are Posterior Descending and Marginal artery) supplies:
  - Right atrium and ventricle
  - Posterior 1/3rd of interventricular septum
  - SA node and AV node
- Left Coronary artery (Main branches are Left Anterior Descending and Circumflex artery) supplies:
  - Anterior 2/3rd of interventricular septum
  - SA node (in 40% cases)
  - Anterior part of right and left ventricle
  - Lateral wall of left ventricle

Venous Drainage

- 10% drains into heart chambers through venae cordis minimis
- 90% drains through Coronary Sinus into right atrium via Great, Small and Middle cardiac veins (GSM)

Length of

- Duodenum: 1 foot
- Jejunum: 8 feet
- Ileum: 12 feet

Liver

- Liver is divided into right and left lobes by the attachment of the peritoneum of the falciform ligament.
- The right lobe is further divided into a quadrate lobe and caudate lobe, by gallbladder, fissure for the ligamentum teres, the inferior vena cava and the fissure for ligamentum vevosum.

Tributaries of Left Renal Vein

- Left gonadal vein
- Left suprarenal vein
- Left inferior phrenic vein

Coverings of Kidney from Inside our

- Fibrous capsule
- Perirenal fat
- Renal fascia (fascia of Gerota)
- Pararenal fat (fascia of Zuckerkandl is the posterior layer of ranal fascia)

The Renal Hilum Transmits Following Structures from Front to Backwards

- Renal vein
- Two branches of the renal artery
- Ureter
- Third branch of the renal artery

Ureter

- 10 inches/25 cm long
- Has three constrictions in its course: Where the renal pelvis joins the ureter; Where it crosses the pelvic brim; Where it enters the bladder wall

Renal Transplantation

- Iliac fossa is the preferred site for transplanted kidney

Prostate

- Prostatic urethra is the widest and the most dilatable part of urethra.
- Lobes of prostate: Anterior lobe; Median/middle lobe (enlarged in BPH); Posterior lobe (most common site of malignancy); Right and left lateral lobes

Superficial Fascia is Divided into

- Camper's fascia: Superficial fatty layer
- Scarpa's fascia: Deep membranous layer

Constituents of Spermatic Cord

- Ductus deferens
- Testicular and cremasteric arteries and artery of the ducts deferens
- Pampiniform plexus of veins
- Lymph vessels from testis
- Plexus of sympathetic nerves around the artery to the ductus deferens
- Remains of processus vaginalis

Coverings of the Spermatic Cord

- External spermatic fascia: Derived from external oblique aponeurosis
- Cremasteric fascia: Derived from internal oblique aponeurosis
- Internal spermatic fascia: Derived from fascia transversalis

Blood Supply of the Stomach

- Right gastric artery (Hepatic artery) supplies: Lower right part of the stomach
- Short gastric artery (Splenic artery) supplies: Fundus
- Left gastric artery (Celiac artery) supplies: Lower third of esophagus, upper right part of the stomach
- Left gastroepiploic artery (Splenic artery) supplies: Upper part of greater curvature

JAYPEE BROTHERS

- Right gastroepiploic artery (Gastroduodenal artery) supplies: Lower part of greater curvature

Layers of SCALP

- S: Skin
- C: Connective tissue
- A: Aponeurosis
- L: Loose areolar tissue
- P: Pericranium

Cranial Nerve and Functions

- Olfactory (Sensory): Perceives smell
- Optic (Sensory): Vision
- Oculomotor (Motor): Supplies levator palpebrae superioris, superior rectus, medial rectus, inferior rectus, inferior oblique, supplies sphincter pupillae and ciliary muscle with parasympathetic fibres
- Trochlear (Motor): Supplies superior oblique
- Trigeminal (Mixed): Supplies sensory fibres to the skin of the scalp, face, mouth, teeth, nasal cavity and paranasal sinuses; supplies motor fibres to the muscles of mastication, tensor veli palatini and tensor tympani
- Abducent (Motor): Supplies lateral rectus
- Facial (Mixed): Supplies motor fibres to the muscles of face, scalp with auricle, buccinator, platysma, stapedius, stylohyoid and posterior belly of digastric; gives sensory supply to anterior 2/3rd of tongue, floor of mouth and the palate; gives parasympathetic secretomotor fibres to the submandibular and sublingual salivary glands, lacrimal glands and the glands of the nose and palate.
- Vestibulocochlear (Sensory): Position and movement of head; hearing
- Glossopharyngeal (Mixed): Supplies stylopharyngeus muscle; supplies parasympathetic secretomotor fibres to the parotid gland, sensory and taste fibres to the posterior third of tongue and pharynx.
- Vagus (Mixed): Supplies constrictor muscles of pharynx and intrinsic muscles of larynx involuntary muscles of trachea and bronchi, heart, alimentary tract from pharynx to splenic flexure of colon, liver and pancreas; Afferent fibres from the abdominal structures, taste from epiglottis and velleculae
- Spinal accessory (Motor): Supplies sternocleidomastoid and trapezius
- Hypoglossal (Motor): Supplies muscles of tongue, except palatoglossus.

Cranial Foramen with the Structures Passing Through Them

- Carotid canal: Internal carotid artery
- Foramen rotundum: Maxillary nerve
- Foramen lacerum: Internal carotid artery, nerve of pterygoid canal
- Jugular foramen: Inferior petrosal sinus, 9th, 10th, 11th cranial nerves, internal jugular vein
- Stylomastoid foramen: Facial nerve
- Foramen magnum: Medulla, tonsils of cerebellum, meninges.
  - Through subarachnoid space-Spinal accessory nerve, vertebral artery, posterior spinal artery, anterior spinal artery.
  - Anterior part-Ligament of dens, membrana tectoria.
- Optic canal: Optic nerve
- Superior orbital fissure: Superior ophthalmic vein, lacrimal, frontal, Trochlear, oculomotor, nasociliary, abducent nerves
- Hypoglossal canal: Hypoglossal nerve
- Internal acoustic meatus: Vestibulocochlear and facial nerve
- Foramen spinosum: Middle meningeal artery, nervus spinosus, posterior trunk of middle meningal artery.
- Foramen ovale: Mandibular nerve, Accessory meningeal artery,Lesser petrosal nerve, vein connecting cavernous sinus with the pterygoid plexus of veins.

Branches of External Carotid Artery

- Anterior: Superior thyroid, Lingual, Facial
- Posterior: Occipital, Posterior auricular
- Medial: Ascending pharyngeal
- Terminal: Maxillary, Superficial temporal.

Sensory Innervation of Tongue [General Sensation (GS); Taste Sensation (TS)]

- Anterior 2/3rd (including circumvallate papillae for taste sensation): Lingual nerve (GS); Chorda tympani branch of facial nerve (TS)
- Posterior 1/3rd (except circumvallate papillae for taste sensation): Glossopharyngeal nerve for GS and TS

Carotid Sheath Contains

- Carotid arteries (within the sheath common carotid divides into external and internal carotids)
- Internal jugular vein
- Vagus nerve

Ocular Muscles (Nerve Supply and Function)

- Superior rectus: Oculomotor nerve; Moves eyeball upward and medially
- Inferior rectus: Oculomotor nerve; Moves eyeball downwards and medially

JAYPEE BROTHERS

- Medial rectus: Oculomotor nerve; moves eyeball medially
- Lateral rectus: Abducent; Moves eyeball laterally
- Superior oblique: Trochlear; Moves eyeball downwards and laterally
- Inferior oblique: Oculomotor nerve; Moves eyeball upwards and laterally
- Orbicularis oculi: Facial nerve; Closes eyeball and dilates lacrimal sac
- Levator palpebrae superioris: Oculomotor nerve; Raises upper lid and sympathetic supply
- Sphincter Pupillae: Parasympathetic supply; Constricts pupil by oculomotor nerve
- Dilator pupillae: Sympathetic supply; Dilates pupil
- Ciliary mucle: Parasympathetic supply by oculomotor nerve; controls shape of eye, helps in accommodation

Must Know Facts

- Only cranial nerve to arise from the dorsal aspect of the brain stem is Trochlear nerve
- Facial vein communicates with the cavernous sinus through the superior and inferior ophthalmic veins
- Stenson's duct—Parotid gland
- Wharton's duct—Submandibular gland

Lesion of Visual Pathway

- Optic nerve: Blindness in that eye
- Crossing fibres of optic chiasma: Bitemporal hemianopia
- Lateral parts of chiasma: Binasal hemianopia
- Optic tract/lateral geniculate body: Contralateral homonymous hemianopia
- Meyer's loop of optic radiation: Contralateral superior quadrantic anopia
- Vascular lesion of occipital lobe: Contralateral homonymous hemianopia with macula sparing

Blood-Brain Barrier is Absent at

- Pituitary
- Area postrema
- Organum vasculosum of lamina terminalis
- Subfornical organ
- Ventral part of median eminence of hypothalamus
- Anterior pituitary
- Pineal gland

Sesamoid Bones (in the Tendons of)

- Quadriceps femoris (Patella-largest sesamoid bone)
- Peroneus longus
- Tibialis anterior
- Tibialis posterior
- Lateral head of gastrocnemius

Peculiarities of Sesamoid Bones

- Ossify at birth
- Devoid of periosteum
- Absence of haversian system

Spinal Nerves

- Cervical: 8
- Thoracic:12
- Lumbar: 5
- Sacral: 5
- Coccygeal:1
- Total: 31

Vertebral Levels and Bony Landmarks

- C7: Most prominent spinous process at the base of neck
- T3: Level of the spine of scapula
- T7: Level of lower angle of scapula
- T12: Floating rib
- L4: Level of iliac crests
- S2: Level of posterosuperior iliac supine

Structure and Their Levels in Body

- Xiphoid process: T9
- Celiac trunk: T12 L1
- Spleen: 10th rib
- Superior mesenteric artery: L1
- Stomach pylorus: L1
- Spinal cord ends (adults): L1, L2
- Spinal cord ends (children): L3
- Pancreas: L1, L2
- Inferior mesenteric artery: L3
- Umbilicus: L3, L4
- Highest point of iliac crest: L4
- Transtubercular plane: L5
- ASIS: Sacral promontory

JAYPEE BROTHERS

MCQs WITH SHORT EXPLANATIONS

EMBRYOLOGY

1. Establishment of fetal circulation is by:

a. 16th day
b. 14th day
c. 21st day
d. 28th day

Events following fertilization

- Fertilization: 0 hours
- 16 celled stage/ morula enters cavity: 4th day
- Blastocyst formation: 5th day
- Interstitial implantation: 7th day
- Placenta fully established; fetal circulation established & heart formed: 21st day
- Internal gonads formed: 8th weeks
- Swallowing starts: 10–12th weeks
- Fetal breathing movements starts: 11 weeks
- External genital formed; urine formation occurs: 12 weeks

Timetable of some events

Age	*Developmental events*
3rd week	Blood and vessels forming cells (angioblastic islands) appear. The cardiogenic area, heart tubes and pericardium have formed.
4th week	Heart and pericardium lie ventral to foregut. Subdivisions of heart tube are visible. Heart begins to beat (becomes functional). Heart septa begin to form. Aortic arches begin to establish in cranial to caudal sequence. Most of the first aortic arch disappears at the end of 4th week. Veins start forming.
5th week	The spiral septum is formed. Formation of aortic arches is complete. Lymphatic sacs form. The cardinal, umbilical and vitelline veins are formed. Conduction system of heart forms.
6th week	Coronary circulation is becoming established. Atrio-ventricular valves and papillary muscles are forming.
7th week	Heart septa are completely formed.

Contd...

2. Which of the following is derived from 5th pharyngeal pouch?

a. Superior parathyroid
b. Inferior parathyroid
c. Thymus
d. Thyroid (parafollicular cells)

Derivatives of pharyngeal pouches

- **Pharyngeal Pouch 1:** Develops into the auditory tube and middle ear cavity
- **Pharyngeal Pouch 2:** Forms numerous infoldings that become the crypts of the palatine tonsil; later, lymphocytes (from the thymus and bone marrow) infiltrate the underlying lamina propria to establish the definitive palatine tonsil.
- **Pharyngeal Pouch 3:** Divides into a superior (or dorsal) and inferior (or ventral) portion:
  - **Dorsal portion of pouch 3:** Forms the inferior parathyroid glands–the chief (or principal) and oxyphil cells are derived from the endodermal lining of the pouch
  - **Ventral portion of pouch 3:** Forms the thymus – the epithelial reticular cells (including those that comprise the thymic or Hassall's corpuscles) are derived from the endodermal lining of the pouch. T-cell progenitors from the bone marrow infiltrate the cortex to establish the definitive thymus.
- **Pharyngeal Pouch 4:** Also divides into a superior (or dorsal) and inferior (or ventral) portion:
  - **Dorsal portion of pouch 4:** Forms the superior parathyroid glands –the chief (or principal) and oxyphil cells are derived from the endodermal lining of the pouch
  - **Ventral portion of pouch 4:** Forms a diverticulum called the ultimobranchial body, which releases signaling factors to induce the migration and differentiation of nearby neural crest cells into parafollicular (C) cells of the thyroid gland.
- **Pharyngeal pouch 5/Ultimobranchial pouch:** It is generally believed to be incorporated in to the fourth pouch and the two together forming the caudal pharyngeal complex. The superior parathyroid gland arises from this complex. The complex probably also gives origin to the parafollicular cells of the thyroid gland

Ans. **1. c.** 21st day **2. d.** Thyroid (parafollicular cells) > a. i.e. Superior parathyroid

JAYPEE BROTHERS

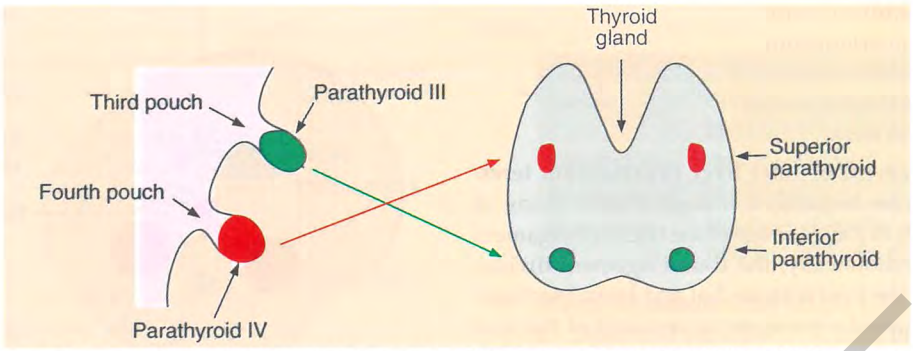

Derivation of superior and inferior parathyroid glands. Note that the relative position of parathyroid III and IV is reversed during development.

3. How many oogonia are present at birth?

a. 1-2 thousands b. 1-2 lakhs
c. 1-2 crores d. 1-2 millions

Number of germ cells/follicles

- Up to the 22nd week of pregnancy, the primordial germ cells multiply along with the resulting oogonia by mitosis.
- The maximum number of germ cells (7 million), found in an ovary, is reached already in the 20th week due to the concomitant massive degeneration of germ cells that begins in the 14th week.

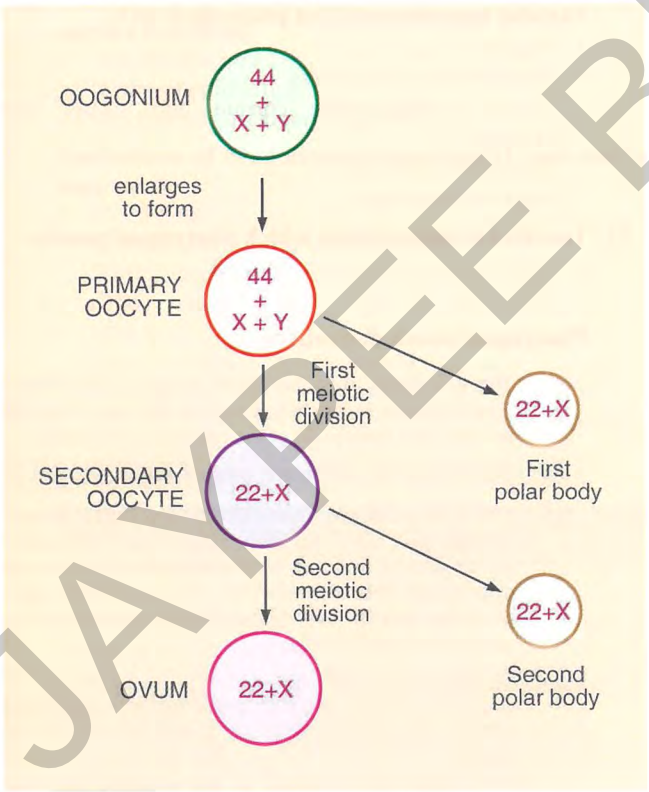

Stages in oogenesis.

- At the time of birth only about 2 million germ cells are still present in the ovary.
- The very first primary oocytes enter the prophase in the 12th week.
- The passage through the various stages, up to the arresting of further development, takes approximately 4 weeks and is accompanied by a restructuring of the epithelial covering (coelomic epithelium → follicular epithelium), so that the first primordial follicle with the primary oocyte, arrested in the dictyotene stage, appears roughly 4 weeks later in the 16th week.
- It is assumed that the generation of the primordial follicles is complete by the time of birth.

4. Which of the following does NOT divide:

a. Spermatogonia b. Primary spermatocyte
c. Secondary spermatocyte d. Spermatid

Spermatids differentiates (NO division) into sperms

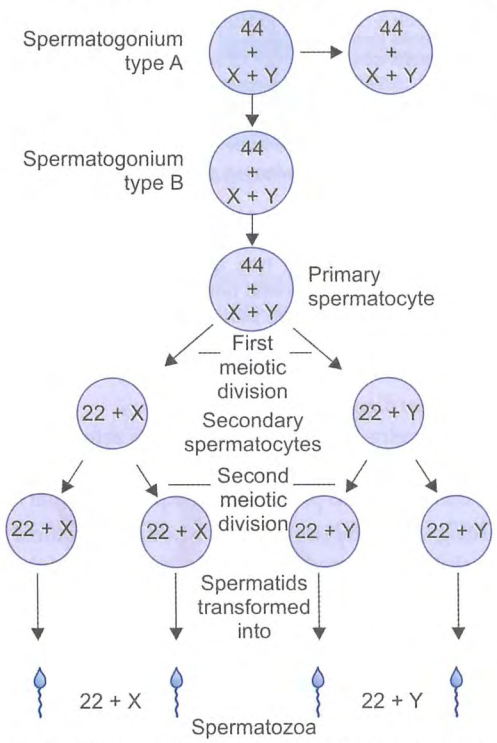

Stages in spermatogenesis. Note the number of chromosomes at each stage.

Ans. **3. d.** 1-2 millions **4. d.** Spermatid

JAYPEE BROTHERS

5. Remnant of umbilical vein:

a. Ligamentum arteriosum
b. Ligamentum venosum
c. Medial umbilical ligament
d. Ligamentum teres

The **round ligament of (the) liver (ligamentum teres/ ligamentum teres hepatis)** is a degenerative string of tissue that exists in the free edge of the falciform ligament of the liver. Anatomically, the round ligament divides the left part of the liver into medial and lateral sections. The round ligament represents the remnant of the fetal umbilical vein.

6. Notochord persists as:

a. Spinous process b. Vertebral foramen
c. Annulus fibrosus d. Nucleus pulposus

The **notochord** is a flexible rod-shaped body found in embryos of all chordates. It is composed of cells derived from the mesoderm and defines the primitive axis of the embryo. In some chordates, it persists throughout life as the main axial support of the body, while in most vertebrates it becomes the nucleus pulposus of the intervertebral disk. The notochord is found ventral to the neural tube.

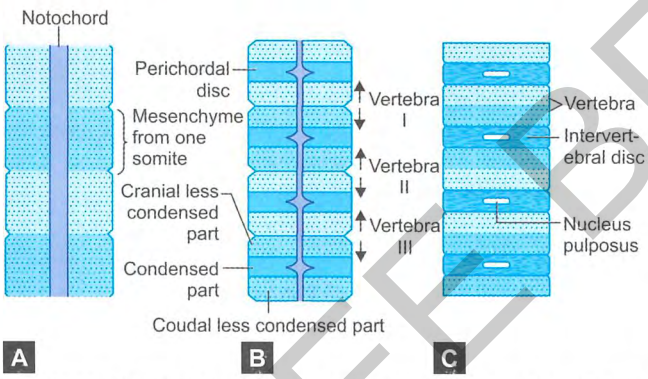

(A) Mesenchyme derived from somites is seen in the form of segments. (B) Each segment has a central condensed part, and cranial and caudal less condensed parts. (C) A vertebra is formed by fusion of adjoining uncondensed parts of two somites. Hence it is an intersegmental structure. Each intervertebral disc is derived from the condensed part of one somite. Hence, it is segmental in position.

7. True regarding umbilical cord:

a. Two veins b. Two arteries
c. Covered by amnion and chorion
d. Umbilical cord pulsation rate equals maternal heart beat

During prenatal development, the umbilical cord is physiologically and genetically part of the fetus and (in humans), normally contains two arteries (the umbilical arteries) and one vein (the umbilical vein), buried within Wharton's jelly. The umbilical vein supplies the fetus with oxygenated, nutrient-rich blood from the placenta. Conversely, the fetal heart pumps deoxygenated, nutrient-depleted blood through the umbilical arteries back to the placenta.

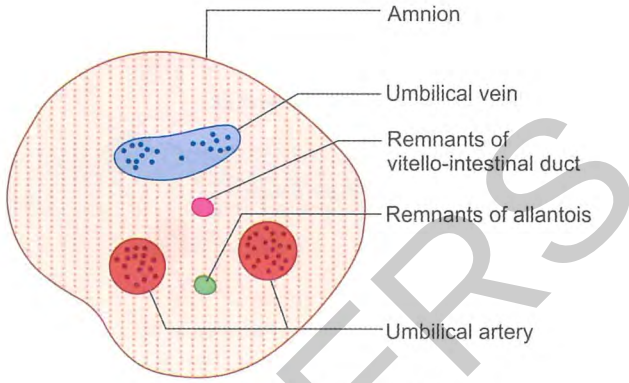

Section through umbilical cord.

8. NOT a derivative of mesonephric duct:

a. Ureter b. Vas deferens
c. Prostatic utricle
d. Trigone of urinary bladder

The prostatic utricle is important primarily because it is the male homologue of the female uterus and vagina, usually described as derived from the Müllerian ducts (paramesonephric duct).

9. Stapes is derived from which pharyngeal arch:

a. 1st b. 2nd
c. 3rd d. 4th

Skeletal derivatives of 2nd pharyngeal arch

- Stapes
- Temporal styloid process
- Hyoid (lesser/smaller cornua and upper part of body)
- Stylohyoid ligament
- Reichert's cartilage.

10. Tonsils are derived from which pharyngeal pouch:

a. 1st b. 2nd
c. 3rd d. 4th

Pharyngeal pouch derivatives

1st	The endoderm lines the future auditory tube (Pharyngotympanic Eustachian tube), middle ear, mastoid antrum, and inner layer of the tympanic membrane.
2nd	Contributes the middle ear, palatine tonsils
3rd	The third pouch possesses Dorsal and Ventral wings. Derivatives of the dorsal wings include the inferior parathyroid glands, while the ventral wings fuse to form the cytoreticular cells of the thymus. The main nerve supply to the derivatives of this pouch is Cranial Nerve IX, glossopharyngeal nerve.
4th	Derivatives include: Superior parathyroid glands and ultimobranchial body which forms the parafollicular C-cells of the thyroid gland. Musculature and cartilage of larynx (along with the sixth pharyngeal pouch).
5th	Rudimentary structure, becomes part of the fourth pouch contributing to thyroid C-cells

Ans. **5. d.** Ligamentum teres **6. d.** Nucleus pulposus **7. b.** Two arteries **8. c.** Prostatic utricle **9. b.** 2nd **10. b.** 2nd

JAYPEE BROTHERS

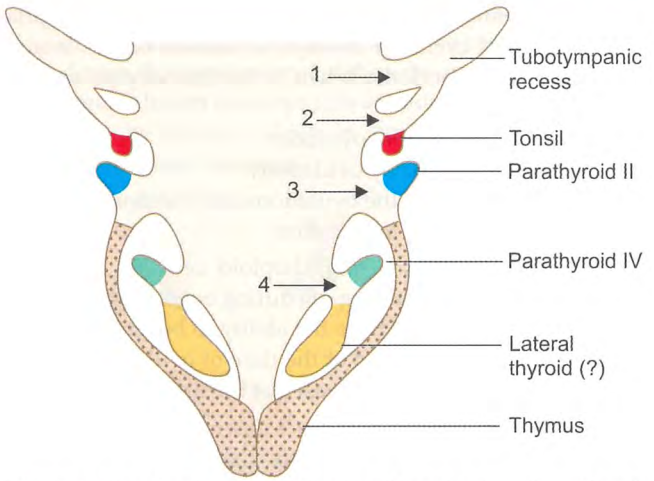

Scheme to show the fate of the pharyngeal pouches (numbered 1 to 4).

11. Muscles of mastication are derived from mesoderm of which pharyngeal arch:

a. 1st b. 2nd
c. 3rd d. 4th

Muscles of mastication, anterior belly of digastrics, mylohyoid, tensor tympani and tensor veli palatini are derived from first pharyngeal arch.

12. The following ocular structure is NOT derived from surface ectoderm:

a. Crystalline lens b. Sclera
c. Corneal epithelium
d. Epithelium of lacrimal glands

Derivatives of head mesenchyme (neural crest and/or mesoderm)

- Blood vessels
- Corneal stroma and endothelium
- Stroma of choroid, ciliary body, and iris
- Ciliary muscle
- Sclera
- Optic nerve sheath (meninges)
- Extraocular muscles and fasciae
- Remainder of the eyelids (orbicularis oculi muscle, tarsus, orbital septum, etc.)
- Vitreous (part).

Summary of derivation of various part of the eyeball.

Part	*Derived from*
Lens	Surface ectoderm
Retina	Neuroectoderm (optic cup)
Vitreous	Mesoderm
Choroid	Mesoderm (infiltrated by neural crest cells?)
Ciliary body	Mesoderm
Ciliary muscles	Mesenchymal cells covering the developing ciliary body (neural crest?).
Iris	Mesoderm
Muscles of Iris	Neuroectoderm (from optic cup)
Sclera	Mesoderm (infiltrated by neural crest cells?)

Contd...

Contd...

Part	*Derived from*
Cornea	Surface epithelium by ectoderm, substantia propria and inner epithelium by neural crest
Conjunctiva	Surface ectoderm
Blood vessels	Mesoderm
Optic nerve	Neuroectoderm. Its coverings (pia, arachnoid and dura) are derived from mesoderm

13. All are of mesodermal origin EXCEPT:

a. Sphincter pupillae b. Ciliary muscle
c. Iris d. Ovarian tissue

Within the stroma of the iris, the sphincter pupillae and dilator pupillae muscles develop from optic cup neuroectoderm. In contrast, the ciliary muscle, which is responsible for changing the shape of the lens, is derived from overlying mesenchyme (mesoderm).

14. In hydatidiform mole, blood cell does not develop because of defect in:

a. Primary ectoderm b. Mesoderm
c. Endoderm d. Trophoblast

Blood vessels do not develop in hydatidiform mole due to lack of mesoderm. Blood vessels are mesodermal in origin.

15. True regarding content of umbilical vessels:

a. 2 arteries, 2 veins b. 2 arteries, 1 vein
c. 1 artery, 2 veins d. 1 artery, 1 vein

The umbilical cord contains Wharton's jelly, a gelatinous substance made largely from muco-polysaccharides which protects the blood vessels inside. It contains one vein, which carries oxygenated, nutrient-rich blood to the fetus, and two arteries that carry deoxygenated, nutrient-depleted blood away.

16. Double aortic arch is due to:

a. Persistence of right 4th aortic arch
b. Persistence of left 6th aortic arch
c. Persistence of right 6th aortic arch
d. Persistence of left 4th aortic arch

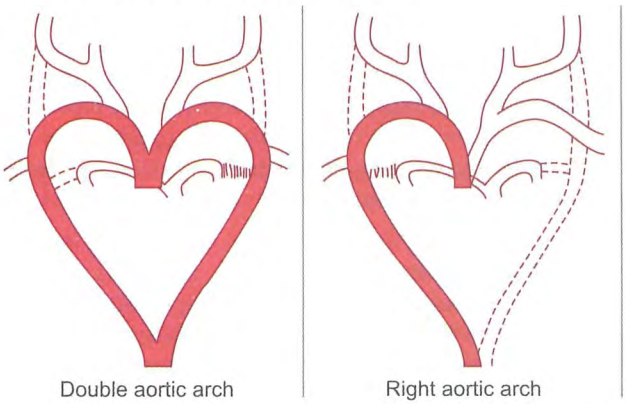

Double aortic arch Right aortic arch

Contd...

Ans. **11. a.** 1st **12. b.** Sclera **13. a.** Sphincter pupillae **14. b.** Mesoderm
15. b. 2 arteries, 1 vein **16. a.** Persistence of right...

JAYPEE BROTHERS

Contd...

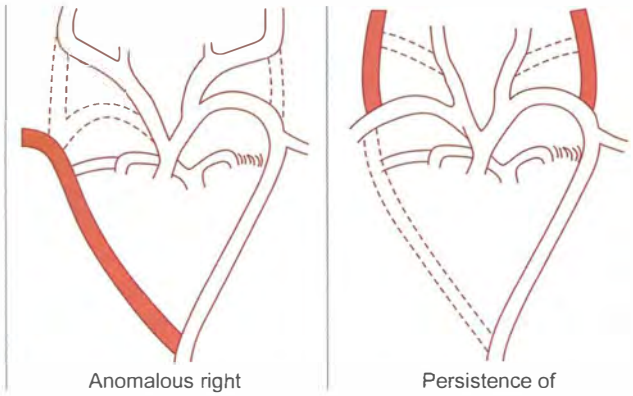

Anomalous right subclavian artery | Persistence of ducts caroticus

Anomalies associated with the development of aortic arches. The abnormal vessels are shown in red.

The *fourth right arch* forms the right subclavian as far as the origin of its internal mammary branch; while the fourth left arch constitutes the arch of the aorta between the origin of the left carotid artery and the termination of the ductus arteriosus. A double aortic arch; occurs with the development of an abnormal right aortic arch in addition to the left aortic arch, forming a vascular ring around the trachea and esophagus, which usually causes difficult breathing and swallowing.

17. Ectopia cordis is related to:

a. Lungs b. Liver
c. Heart d. Lens

Ectopia cordis (Greek: *'away/out of place'* + *Latin: 'heart'*) is a congenital malformation in which the heart is abnormally located either partially or totally outside of the thorax.

18. Meckel's diverticulum arises from:

a. Foregut b. Ileum
c. Cecum d. Colon

Meckel's diverticulum is located in the distal ileum, usually within 60–100 cm (2 feet) of the ileocecal valve. This *blind segment* or small pouch is about 3–6 cm long and may have a greater lumen diameter than that of the ileum. It runs anti-mesenterically and has its own blood supply. It is a remnant of the connection from the yolk sac to the small intestine present during embryonic development. It is a *true diverticulum*, consisting of all 3 layers of the bowel wall which are mucosa, submucosa and muscularis propria.

19. Ovary is derived from:

a. Müllerian duct
b. Wolffian duct
c. Genital ridge
d. Genital tubercle

The gonadal ridge (or genital ridge) is the precursor to the gonads.

20. In a young female of reproductive age with regular menstrual cycles of 28 days, ovulation occurs around 14th day of periods. When is the first day polar body extruded:

a. 24 hours prior to ovulation
b. Accompanied by ovulation
c. 48 hours after the ovulation
d. At the time of fertilization

A **polar body** is a small haploid cell that is formed concomitantly as an egg cell during oogenesis, but which generally does not have the ability to be fertilized. First polar body is released at the time of ovulation whereas second polar body is released at the time of fertilization.

21. Primary structural defect is known as:

a. Mutation b. Deformation
c. Anomaly d. Malformation

A **malformation** is associated with a disorder of tissue development. Malformations often occur in the first trimester.

22. Closure of neural tube starts from:

a. Lumbar b. Cephalic
c. Cervical d. Podalic

For a short time, the neural tube is open both cranially and caudally. These openings, called neuropores, close during the fourth week in the human. The closure of the neural tube begins in the cervical area (in the middle of the embryo) and extends from there in both the cranial and caudal directions. Improper closure of the neuropores can result in neural tube defects such as anencephaly or spina bifida.

23. Trigone-urinary bladder develops from:

a. Ectoderm b. Endoderm
c. Mesoderm d. None of the above

Embryologically, the trigone of the bladder is derived from the caudal end of mesonephric ducts, which is of mesodermal origin (the rest of the bladder is endodermal). In the female the mesonephric ducts regresses, causing the trigone to be less prominent, but still present.

24. Auerbach plexus and Meissner plexus are derived from:

a. Epithelial lining of gut b. Mesoderm
c. Endoderm d. Neural crest

The majority of the enteric nervous system is derived from vagal neural crest cells (NCC), which migrate to the developing gut, proliferate, form plexuses and differentiate into neurons and glia.

25. Ureter develops from:

a. Mesonephric duct
b. Paramesonephric duct
c. Urogenital sinus
d. Mesonephric tubules

Ans. **17. c.** Heart **18. b.** Ileum **19. c.** Genital ridge **20. b.** Accompanied...
21. d. Malformation **22. c.** Cervical **23. c.** Mesoderm **24. d.** Neural crest
25. a. Mesonephric duct

JAYPEE BROTHERS

The **ureteric bud,** also known as the **metanephrogenic diverticulum,** is a protrusion from the mesonephric duct during the development of the urinary and reproductive organs. It later develops into a conduit for urine drainage from the kidneys, which, in contrast, originate from the metanephric blastema.

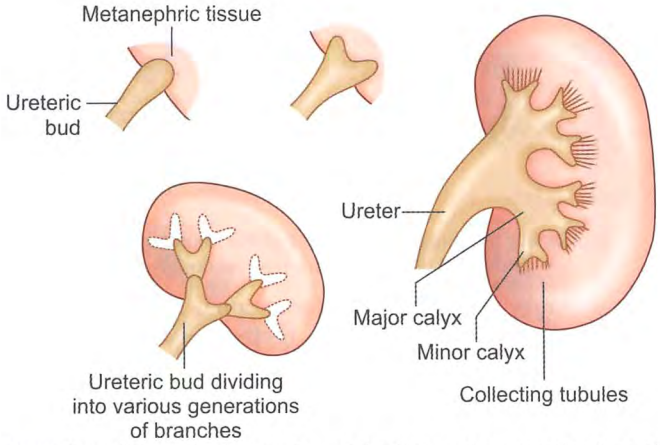

Formation of the collecting system of the kidney, from ramifications of the ureteric bud.

26. Gartner duct is a remnant of:

a. Epoophoron b. Cloacal duct
c. Wolffian duct d. Müllerian duct

The derivatives of the mesonephric duct/Wolffian duct can be remembered using the mnemonic, **'Gardener's SEED'** for **G**artner's duct, **S**eminal vesicles, **E**pididymis, **E**jaculatory duct and **D**uctus deferens.

Summary of Male and Female Homologues derived from Undifferentiated Genital System.

Structure	*Male Derivative*	*Female Derivative*
Gonad	Testis	Ovary
Sex cords	Sertoli cells (seminiferous tubules)	Granulose cells
Primordial germ cells	Spermatozoa	Ova
Paramesonephric duct	Appendix of testis Utricle of prostate	Uterine tube, uterus Upper vagina
Mesonephric duct	Appendix of epididymis, Epididymis, Ductus deferens, Ejaculatory duct Seminal vesicle	Appendix of ovary Gartner's duct
Mesonephric tubules	Vasa efferentia Paradidymis	Epoophoron Paroophoron
Genital tubercle	Penis	Clitoris
Genital swellings	Scrotum	Labia majora
Urethral folds	Floor of penile urethra	Labia minora

27. NOT a derivative of midgut:

a. Jejunum b. Appendix
c. Ascending colon d. Descending colon

The **hindgut** (or **epigaster**) is the posterior (caudal) part of the alimentary canal. In mammals, it includes the distal third of the transverse colon and the splenic flexure, the descending colon, sigmoid colon and rectum.

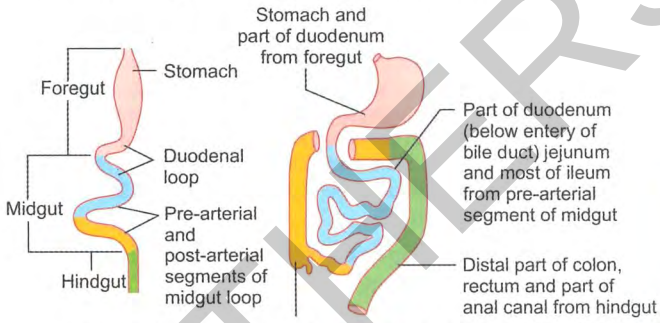

Derivation of various parts of the gut.

28. Clitoris develops from:

a. Genital ridge b. Genital tubercle
c. Wolffian duct d. Müllerian duct

A **genital tubercle** or **phallic tubercle** is a body of tissue present in the development of the reproductive system. It forms in the ventral, caudal region of mammalian embryos of both sexes, and eventually develops into a phallus. In the human fetus, the genital tubercle develops around week 4 of gestation, and by week 9 becomes recognizably either a clitoris or penis.

29. Parathyroid gland develops from:

a. Branchial arch b. Branchial pouch
c. Both d. None

Inferior parathyroid develops from 3rd pharyngeal pouch whereas superior parathyroid gland develops from 4th pharyngeal pouch.

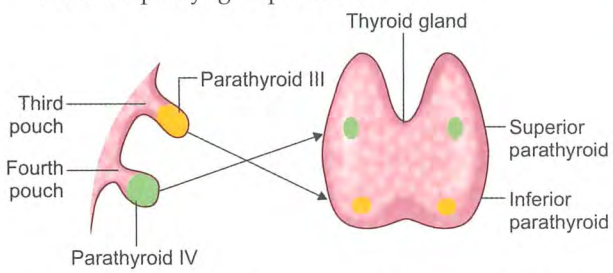

Derivation of superior and inferior parathyroid glands. Note that the relative position of parathyroid III and IV is reversed during development.

30. Appendix of testes is a remnant of:

a. Germ cell b. Urogenital fold
c. Mesonephric duct d. Paramesonephric duct

The **appendix testis** (or **hydatid of Morgagni**) is a vestigial remnant of the Müllerian duct/ paramesonephric duct, present on the upper pole of the testis and attached to the tunica vaginalis. It is present about 90% of the time.

Ans. **26. c.** Wolffian duct **27. d.** Descending colon **28. b.** Genital tubercle **29. b.** Branchial pouch **30. d.** Paramesonephric duct

JAYPEE BROTHERS

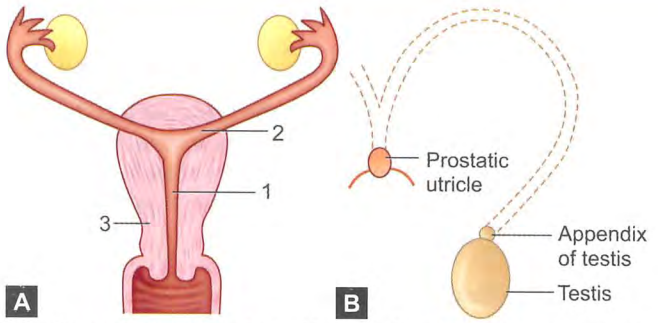

Fate of paramesonephric ducts. (A) In the female they form the uterine tubes, the uterus, and part of the vagina. 1 is epithelium of uterus, 2 is fundus of uterus and 3 is myometrium. (B) In the male most of the duct disappears. Remnants are seen as the appendix of the testis and the prostatic utricle.

31. Lower 1/4th of vagina develops from:

a. Mesonephric duct
b. Paramesonephric duct
c. Genital tubercle
d. Urogenital sinus

Upper 3/4th of vagina develops from Müllerian duct/ paramesonephric duct whereas lower 1/4th develops from urogenital sinus.

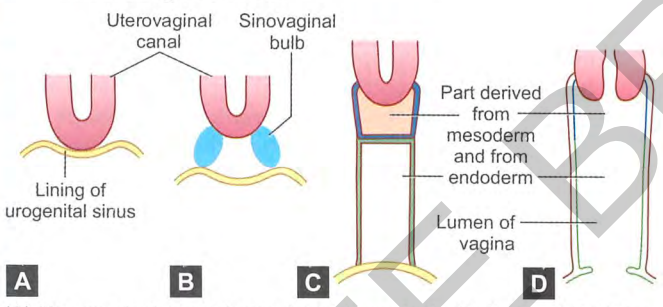

(A) Uterovaginal canal (mesoderm) in contact with lining of UGS (endoderm). (B) Sinovaginal bulbs are formed by proliferation of endodermal lining. (C) Solid vaginal plate derived partly from mesoderm of uterovaginal canal and partly from endoderm of sinovaginal bulbs. (D) Vagina formed by canalisation of vaginal plate.

32. Lens is derived from:

a. Endoderm
b. Surface ectoderm
c. Mesoderm
d. None of the above

Ocular structures derived from surface ectoderm are lens, cornea, lacrimal gland, tarsal glands and the conjunctiva of the eye.

33. Sympathetic ganglia arise from:

a. Endoderm
b. Neural crest
c. Mesoderm
d. All of the above

Neural crest cells are a transient, multipotent, migratory cell population unique to vertebrates that gives rise to a diverse cell lineage including melanocytes, craniofacial cartilage and bone, smooth muscle, peripheral and enteric neurons and glia.

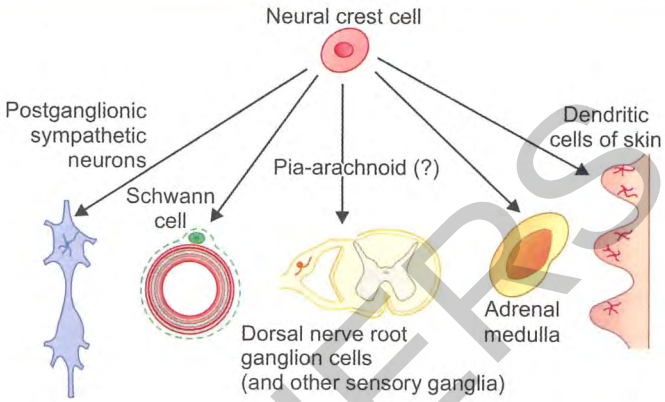

Traditionally recognised derivatives of the neural crest. Some additional derivatives are now recognised.

34. In embryonic life, blood formation is first observed in:

a. Liver
b. Bone marrow
c. Yolk sac
d. Spleen

In the developing embryos, blood formation occurs in aggregates of blood cells in the yolk sac, called blood islands. As development progresses, blood formation occurs in the spleen and liver. When bone marrow develops (third month), it eventually assumes the task of forming most of the blood cells for the entire organism.

35. CNS cells of mesodermal origin:

a. Microglia
b. Sympathetic ganglia
c. Schwann cells
d. Neurons

Mesoderm derivatives include the muscle (smooth, cardiac and skeletal), the muscles of the tongue (occipital somites), the pharyngeal arches muscles (muscles of mastication, muscles of facial expressions), connective tissue, dermis and subcutaneous layer of the skin, bone and cartilage, dura mater, endothelium of blood vessels, red blood cells, white blood cells, microglia and Kupffer cells, the kidneys and the adrenal cortex.

Various types of cells are derived from neuroepithelium.

Derivation of nerve cells (neurons) and neuroglial cells

From neural tube	*From neural crest*	*From mesenchymal cells*
Neurons Fibrous astrocytes Protoplasmic astrocytes Oligodendroglia (?) Ependymal cells	Schwann cells Dorsal n. root ganglion cells Cells of other sensory ganglia Neurons in sympathetic ganglia	Microglia Oligodendroglia (?)

36. Umbilical cord contains:

a. 2 veins, 2 arteries
b. 1 vein, 2 arteries
c. 2 veins, 1 artery
d. 1 vein, 1 artery

Initially, there are 2 arteries and 2 veins in umbilical cord, but then right umbilical vein disappears and left umbilical vein is left.

Ans. **31. d.** Urogenital sinus **32. b.** Surface ectoderm **33. b.** Neural crest **34. c.** Yolk sac **35. a.** Microglia **36. b.** 1 vein, 2 arteries

JAYPEE BROTHERS

r detailed information on PGMEE books, visit our website www.jaypeebrothers.com, for detailed information on PGMEE books, visit

Mastering NEET Series

Salient Features

- Entire text has been presented in full colour. This will help in understanding the images more clearly.
- The text has been compiled in 2 volumes:
  - Volume I: Non-clinical subjects
  - Volume 2: Clinical subjects
- The content has been arranged into:
  - Key notes
  - MCQs with concise explanations (attached images/ tables)
  - Practice MCQs
  - Image-based MCQs
  - MCQ points
- Key notes had been compiled based on high-yield topics, from which questions are usually asked.
- MCQ has been categorized into different sections. The sections are same as those in 'Self Assessment & Review of FMGE' so that students can read both the titles together, section wise, so as to have an in-depth knowledge of NBE pattern.
- Explanations are short concise and tries to highlight the fact that why a particular option is the answer to that MCQ.
- For the ease of studying, explanations are placed after the MCQs and answers are written in foot-notes.
- Illustrative approach has been adopted. Related images have been attached with the explanations, which will help students in understanding the text.
- Wherever possible, tables have been inserted to give detailed information about the topic
- Practice MCQs are given in each chapter for self assessment
- Image-based MCQs are provided to help the students in solving picture-based questions asked in examinations
- One-liner type of questions has been compiled as MCQ points for quick recap
- All efforts were done to keep the presentation simple and reader-friendly

JAYPEE BROTHERS

Available at all medical bookstores
or buy online at www.jaypeebrothers.com



JAYPEE BROTHERS
Medical Publishers (P) Ltd.
www.jaypeebrothers.com

Join us on facebook.com/JaypeeMedicalPublishers

ISBN 978-93-5270-436-1

9 789352 704361