& gynecology books, visit our website www.jaypeebrothers.com, for detailed information on obstetrics & gynecology boo

Practical Guide in Reproductive Surgery

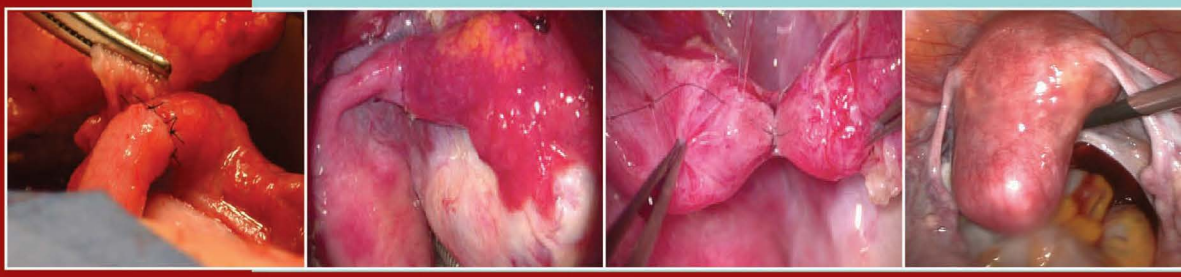

Editors

Gita Ganguly Mukherjee

Gautam Khastgir

Bhaskar Pal

23RD ISAR2018 KOLKATA

19th – 22nd April

ISAR BENGAL

Contents

Chapter 1.	Diagnostic Laparoscopy in Infertility *Gita Ganguly Mukherjee, Mausumi De Banerjee, Siddhartha Chatterjee*	1
Chapter 2.	Role of Diagnostic Hysteroscopy in Infertility *Biswajyoti Guha, Alok Basu, Arati Ghosh*	10
Chapter 3.	Hysteroscopy Treatment and Management: As Day Care *Abhinibesh Chatterjee, Polly Chatterjee*	15
Chapter 4.	Role of Laparoscopic Ovarian Drilling Today *KK Roy, Manisha Bansal*	39
Chapter 5.	Fibroids, Infertility and Assisted Reproductive Technology *Prakash Trivedi, Soumil Trivedi*	45
Chapter 6.	Myomectomy in Asymptomatic Fibroid and its Outcome in Infertility Management *Sebanti Goswami, Bhaskar Pal*	55
Chapter 7.	Endometriosis: Does Surgery Improve the Chance of Pregnancy? *Pramathes Das Mahapatra, Pradip Kumar Mitra, Amiya Kanti Majumdar*	59
Chapter 8.	Role of Surgery in Deep Infiltrating Endometriosis *Arun Madhab Baruah, Mohini*	69
Chapter 9.	Recurrent Endometriosis *Sunita Tandulwadkar*	75
Chapter 10.	Role of MRgFUS in the Management of Fibroids and Adenomyosis *Ramya Jayaram, Mirudhubashini Govindarajan*	82
Chapter 11.	Laparoscopic Adhesiolysis Infertility *Aruna Tantia, Kavita Mandal*	94
Chapter 12.	Reversal of Female Sterilization *Anima Biswas, Biswapati Mukherjee, Subhash Halder, Mayukh Ray*	104
Chapter 13.	Surgery for Ectopic and Heterotopic Pregnancy *Malvika Sabharwal, Shivani Sabharwal, Nupur Chhabra*	116
Chapter 14.	Surgery before Assisted Reproductive Technology *Subrata Gangooly*	126

Chapter 15.	**Robotics in Infertility** *Lavanya Kiran, Sowparnika SN*	**134**
Chapter 16.	**Hysteroscopy in Recurrent Implantation Failure** *Nutan Jain, Vandana Jain, Parima Jain*	**147**
Chapter 17.	**Hysteroscopic Metroplasty for T-shaped Uterus** *Shashi Bala Arya, Ruchica Goel, JK Goel*	**161**
Chapter 18.	**Case Reports—Complication of Oocyte Retrieval: Bleeding from Ovarian Surface and Ureteric Injury after Pickup** *Kedar Ganla, Rana Choudhary*	**171**
Chapter 19.	**Surgical Sperm Retrieval Procedures in Azoospermia** *Vasan SS, Shashidhar B*	**183**
Chapter 20.	**Ovarian Tissue Freezing: Introducing New Paradigms in Infertility Preservation** *Biswanath Ghosh Dastidar*	**203**
Chapter 21.	**Fertility Preservation in Women Suffering from Gynecological Cancer** *Jaydip Bhaumik*	**216**
Chapter 22.	**Anesthesia for Laparoscopic Gynecology Surgery** *Namrata Biswas*	**225**
Chapter 23.	**Bariatric Surgery for Infertility Patient** *Aruna Tantia*	**236**
Chapter 24.	**Role of Surgery in Male Infertility** *Sunil Jindal, Anshu Jindal*	**246**
Chapter 25.	**Pregnancies Following Reconstructive Surgery for Congenital Cervicovaginal Atresia** *BN Chakravarty, M Chakravarty, KD Bakshi, NN Roychowdhury*	**259**
Index		*273*

CHAPTER

3

Hysteroscopy Treatment and Management: As Day Care

Abhinibesh Chatterjee, Polly Chatterjee

PREOPERATIVE DETAILS

Appropriate surgical management always begins with accurate history taking, physical examination, and careful workup of the suspected problem. In preparation for hysteroscopic procedures, the following considerations may be useful.

Antibiotic Prophylaxis

For hysteroscopy, prophylactic antibiotics are not indicated unless the patient has clinically significant valvular disease or a history of tubal occlusion due to pelvic inflammatory disease.

Cervical Stenosis

In patients with known cervical stenosis or tortuous cervical canals, preoperative vaginal or oral misoprostol, or intraoperative vasopressin 1% administered paracervically may be used to assist in cervical dilation. Additionally, when intravaginal misoprostol is used for preoperative cervical ripening in the premenopausal women (without known cervical stenosis), it has been described to increase the ease of dilation, reduce the need for mechanical cervical dilation, and lower the rate of cervical laceration.However, not all studies have shown the same improvement. The potential benefits still need further evaluation in the postmenopausal population and potential side effects (vaginal bleeding, cramping, fever, diarrhea, and nausea) must be considered for all women. The optimal dose and route of administration (vaginal or oral) remains an area of investigation.

Endometrial Preparation for Ablation

Before ablation procedures are performed, the administration of a gonadotropin-releasing hormone (GnRH) agonist in the luteal phase of the

JAYPEE BROTHERS

previous menstrual cycle in ovulating women improves visibility and provides a smooth, pale, hypovascular surface 3–4 weeks later (after the patient has her menses). These changes make the procedure easier to perform and improve its success rate.

For those who do not want a GnRH agonist, the simultaneous use of a GnRH antagonist with progesterone at any point in the menstrual cycle theoretically creates a similar surface after the patient has her menses, but it has fewer adverse effects and allows greater scheduling flexibility than does the other method.

One antagonist, ganirelix acetate (Antagon) (Organon, Inc, Oss, the Netherlands), is available packaged with gonadotropins for use in infertility therapy. However, cetrorelix, (Cetrotide; Serono, Inc, Rockland, Massachusetts) is available packaged alone. The author has successfully used a single 3 mg dose of cetrorelix administered subcutaneously every 4 days along with medroxyprogesterone acetate (Provera) 10 mg taken orally for 5 days. Unlike the agonist, the action of the antagonist is immediate, suppressing follicle-stimulating hormone (FSH) and luteinizing hormone (LH) without any of the flare effect commonly observed with the agonist. The ablation procedure is then typically performed after the patient completes her menses, which usually begins 2–3 days after she takes the last progesterone tablet.

Finally, suction curettage done before ablation creates a comparable surface. However, it appears to be most effective in the late luteal phase or during menstruation, when the endometrium is loosely attached. In this author's experience, the medical approaches are superior.

Fibroids

For large submucosal fibroids, the use of a GnRH agonist decreases uterine volume by approximately 30%. It may decrease blood loss and allow for an easier and more complete resection, though some data suggest that the change in tissue quality may make the procedure technically more difficult than before, negating other benefits. There is currently no consensus on their use prior to hysteroscopic myomectomy. Benefits of preoperative use should be weighed against their cost and side effect profile.

Large Uterus

During ultrasonography or sonohysterogram, measurements of the uterine dimensions are helpful. In particular, a uterus longer than 10 cm makes the case difficult because of the length of the hysteroscope (typically 35 cm) because it must traverse the length of the uterus, cervix, and vagina while maintaining a position outside the introitus with enough distance to attach the camera and manipulate the fluid inflow-outflow valves and the surgical instruments. Also, maintaining intrauterine pressures with large cavities is more difficult than with small cavities.

JAYPEE BROTHERS

INTRAOPERATIVE DETAILS

Anesthesia

The type of anesthesia used depends on the procedure, the patient's level of anxiety, and the anesthesiologist's expertise. Simple diagnostic procedures can be completed without anesthesia, with a paracervical block alone, or with mild sedation. For extensive procedures or for patients with a low pain tolerance, general or regional anesthesia is indicated. If electrosurgery is to be performed, sufficient anesthesia must be given to ensure that the patient does not move with uterine stimulation because of the risk of uterine perforation and intraperitoneal injury.

Positioning

The patient is placed in the dorsal lithotomy position then prepared and draped in a sterile manner. Unless a laparoscopy is also planned, the patient's thighs should be positioned at a 90° angle to the pelvis to create enough space for the surgeon to manipulate the hysteroscope. The patient's perineum should be just past the edge of the table, with the coccyx and sacrum well supported on the flat surface of the table. The patient's legs should be secured in the leg stirrups to avoid any abrupt movements, which can cause nerve or muscle injury to the patient or potential injury to the surgeon. The surgeon should be seated with the operative field and hysteroscope at the level of his or her abdomen. If it is positioned higher, the surgeon's shoulders become fatigued, and, if it is positioned lower, the instrument is hard to maneuver and is likely to become contaminated.

Hemostasis

Attempts to reduce blood loss and fluid deficits are reported (and ultimately tried by the author). Use of cold (i.e. 5°C) distention medium causes vasoconstriction and reduces blood loss and distention fluid deficits. However, the patient's core body temperature substantially decreases and may interfere with the anesthesia process. Vasopressin in dilute solution (i.e. 1%) can be injected paracervically to help constrict the cervical and lower uterine branches of the uterine artery and its collaterals, reducing blood loss, and fluid deficits.

Placing the Hysteroscope

Bladder Catheterization

At the discretion of the surgeon, the bladder may need to be emptied with a straight, red rubber catheter by using sterile technique.

JAYPEE BROTHERS

Examination under Anesthesia

Bimanual examination should always be performed before the endocervix and uterus are dilated and entered. This examination aids the surgeon in assessing angles and preventing perforation.

Cervical Dilation

Using the standard approach, the cervix is manually dilated with metal dilators to the same diameter as the outer diameter of the outer sheath of the hysteroscope setup. A single-tooth tenaculum is placed on the anterior lip of the cervix while dilating to help straighten the cervix and uterus. Take care to avoid creating a false cervical passage that could make it difficult to continue with the surgery. If the surgeon is unsure of the path of the cervical canal, lacrimal duct probes, or flexible uterine sounds should be used to determine the correct angle. Ultrasonographic guidance for dilation may be helpful in severe cases.

Visualization of the Uterine Cavity

After the cervix is dilated, the hysteroscope is inserted into the endocervical canal and advanced into the uterine cavity (with the distention medium flowing) under direct visualization to limit the risk of perforation. The tenaculum on the cervix is left in place to help in manipulating the uterus, and the vaginal speculum is removed to increase maneuverability of the hysteroscope. If the cervix was dilated too much and if fluid is leaking extensively, a purse-string suture can be placed around the cervix using 0-Vicryl to limit this leakage. The suture should be removed at the end of the procedure.

Alternatively, a vaginoscopic approach has also been defined. Distention media is introduced into the vagina at the same pressure used for dilation of the uterine cavity (around 30–40 mm) to distend the vaginal cavity. The hysteroscope is then used to visualize the cervix and facilitate its entry into the cervical canal. The use of a speculum and tenaculum is not needed with this approach.

Techniques

Procedures are individually described below with regard to the type and width of the hysteroscope, the type of medium, and the use of surgical instrumentation and energy sources, depending on the indications and desired outcomes.

Diagnostic Hysteroscopy

A small 5 or 7 mm hysteroscope can be used with isotonic sodium chloride distention medium. A 30° scope is preferable to clearly visualize the tubal ostia. The ability to introduce small surgical instruments through an operating

JAYPEE BROTHERS

channel is optimal. Office procedures can be performed with 2.5–3 mm flexible or rigid hysteroscopes that are attached to isotonic sodium chloride solution in a bag or 30 mL syringe. Some models have a small operating channel through which a thin-wired biopsy forceps can be placed. This channel is enough to sample suspected areas or to remove small polyps.

Diagnostic minihysteroscopy, using a 3.5 mm single-flow diagnostic sheath (ACMI Slim-line hysteroscope, Southborough, Massachusetts), has also proven to be an easy and reliable procedure with acceptable patient tolerance.

Endometrial Ablation

First-generation endometrial ablation using the rollerball or rollerbarrel method, resection method, and laser method are described below.

- *The rollerball or rollerbarrel method*:
  - The cervix must typically be dilated to 7–9 mm depending on the resectoscope used. An Iglesias grip mechanism on the resectoscope is preferred because it maintains the electrode within the shaft at rest. A 12° scope is suggested because it provides a panoramic view of the uterine cavity. A coagulation mode of 50–100 watts is used.
  - A rollerbarrel improves the uniformity of contact with the endometrium compared with the rollerball, but it may inadequately ablate the cornua and fundus. A 2 mm rollerball is more effective than a 4 mm ball because it has more current density for a given power level. The ball or barrel is extended and allowed to passively return toward the sheath at a rate of 1.0–1.5 mm/s. In clinical use, the proper amount of power is being used if the crater that is formed is 25% of the volume of the electrode and if the borders of the crater are carbonized.
  - On occasion, the rollerball or barrel may become coated with tissue, and it may have to be removed and cleaned with sterile gauze. If the endometrium is not thinned, resection may be preferred. The uterine cornua and tubal angles are ablated first because of their difficulty. Starting at the 9 O'clock position, the lateral and anterior walls are ablated next because blood, debris, and bubbles rise, making later ablation attempts more difficult. The posterior wall is then ablated by continuing in a clockwise fashion. Do not continue to ablate over areas that have already been treated because of the risk of uterine perforation.
- *The resection method*: As with the other procedures, the cervix is typically dilated to the size of the resectoscope. A blended current of 70–100 watts is preferred. A 5 or 7 mm loop electrode is used and extended. The electrode is allowed to return passively at 1.0–1.5 mm/s. A methodical approach should be used, with a plan to uniformly continue around the cavity. Do not resect the same place twice. The angles of the tubal ostia are difficult to ablate with the loop electrode, so a small rollerball is preferable. Also, the corpus and isthmus may be thin; therefore, a rollerball is preferable in this area as well. The correct wattage is being used if the loop easily penetrates

JAYPEE BROTHERS

the tissue without tearing it. Depending on the system used, the strips of resected tissue may require removal intermittently with polyp forceps. All tissue is sent to the pathologist for histologic evaluation.

- *The laser method*:
  - The neodymium-doped yttrium aluminium garnet laser (Nd: YAG laser) can also be used for ablation. Laser energy is delivered to the tissues via a fiber inserted through an operating hysteroscope. The laser energy provides a tissue penetration of 5–6 mm. Two techniques are commonly described. The dragging technique requires the laser fiber to be in constant contact with the endometrium, which ultimately results in vaporization of the tissue.
  - Alternatively, coagulation can be induced with the blanching technique in which the fiber does not come in direct contact with the endometrium. Both techniques require constant motion to minimize risk of perforation. Choice of distention media includes normal saline (NS) or Dextran 70.

Second-generation Endometrial Ablation and Hydrothermal Method

The HydroThermAblator System (Boston Scientific, Natick, Massachusetts) is the only second-generation ablation device that uses direct visualization with the hysteroscope. A single-use 3 mm hysteroscope coated with polycarbonate is inserted into the endometrial cavity. Saline is instilled at low intrauterine pressures of less than 45 mm Hg and then heated to 90°C. This low pressure is used to prevent flow of heated saline through the fallopian tubes. After the treatment is complete, cool saline is used to replace the heated saline prior to removal of the device from the cavity. Endomyometrial necrosis to a depth of 2–4 mm is achieved after 10 minutes of treatment. The endometrial cavity is uniformly ablated with this method, including both cornua.

Submucosal Fibroids

Several instruments may be used for hysteroscopic myomectomy. They include the resectoscope (by far the most common), scissors, the laser, and the morcellator. Some gynecologists inject vasopressin into the cervical stroma before the procedure to decrease blood loss and surgical time.

- *Resection:*
  - This is similar to resection of the endometrium, but the resectoscopic method results in resection of only the fibroid rather than the surface layer of endometrium. Take care when resecting a fibroid to limit the resection to only the fibroid without resecting the adjoining endometrial tissue, especially in women desiring to conceive. The fibroid can be resected to the level of the endometrium. After some is removed, any remaining intramural portion of the fibroid may begin to invert into the endometrial cavity. Surgeons should apply their skill and experience to estimate how many passes they will continue to resect while aiming to avoid uterine perforation. The loop can often be used to separate

JAYPEE BROTHERS

the fibroid from the pseudocapsule, often called cold-loop resection, facilitating its removal, and helping to identify normal myometrium and endometrium to avoid coagulation, especially in young women desiring to conceive.

- For resection of a submucosal fibroid, high cutting power is required. Using the cutting mode at 80–100 watts provides clean cuts through the fibroid and facilitates a rapid technique. Power settings lower than this do not allow for easy resection and only delay completion of the procedure, with resulting fluid deficits.
- Resectoscopes historically relied on monopolar currents to cut tissue and thus required the use of hypotonic electrolyte-free distention media. Strict fluid monitoring is an obvious need. Fortunately, bipolar resectoscopes are now in use. The Princess resectoscope (Richard Wolf Medical Instruments Corporation, Vernon Hills, Illinois and of Storz) is a 7 mm resectoscope—the smallest bipolar resectoscope currently available.
- Obstructed visualization due to floating tissue fragments during resection can prove difficult and may necessitate catching the loose tissue with the loop electrode or poly forceps, removing the hysteroscope to grab the tissue, followed by reintroduction of the scope. To address this problem, the Bipolar Chip E-Vac System (Richard Wolf Medical Instruments Corporation, Vernon Hills, Illinois) has been introduced to the market. The system uses a traditional resectoscope with an automatic chip aspirator and can be used with monopolar or bipolar current. A microprocessor controlled pump pulses at an adjustable level to aspirate chips out through an operative channel in the hysteroscope while preventing fluid losses and uterine collapse. Published reviews favorably evaluate this new system but do note that the aspiration system is prone to becoming clogged if tissue chips are too large. This system encourages the surgeon to remove smaller tissue fragments with each pass of the resectoscope.

◆ *Vaporization*:

- Vaporization of a fibroid can also be performed through the use of a variety of different shaped electrodes. The chosen electrode is dragged along the surface of the myoma to directly vaporize the tissue. Perforation from prolonged use at one point can occur. Using this method, tissue is destroyed and thus unavailable for pathologic examination.
- The Gynecare Versapoint Bipolar Electrosurgery System (Johnson & Johnson Gateway LLC, Piscataway, NJ) provides the opportunity to use both a vaporizing electrode and resecting loop electrode with NS distention media for a variety of operative needs. Vaporizing electrode options include a ball or spring electrode for rapid vaporization and desiccation and a twizzle electrode for more precision.

JAYPEE BROTHERS

- *Laser ablation*: Fibroids less than 2 cm in diameter can also be ablated with the use of the Nd: YAG laser. The laser fiber is dragged over the surface of the fibroid until it is flat. As with its use for endometrial ablation, continual movement is required and tissue is destroyed and not available for pathology evaluation.
- *Morcellation*:
  - Hysteroscopic morcellation may also be used for resection of submucosal fibroids, as well as, endometrial polyps. The Intrauterine morcellator (IUM) (prototype: Smith & Nephew Operative Hysteroscopy System, Andover, Massachusetts and Bagauti Shaver of Storz) provides a nonelectrosurgical removal option. The morcellator consists of an inner rotating or reciprocating tube electronically controlled by a foot pedal and a 4.5 mm outer tube. Only a single insertion through a 9 mm rigid hysteroscope is required, followed by saline inflation of the uterus. After the fibroid or polyp is visualized, the morcellator is placed against the lesion and rotation (optimal for polyp morcellation) or reciprocation (optimal for myomas) of the inner tube cuts the lesion as controlled suction is used for continuous tissue removal and outflow. Each tube has an opening at the end of it for visualization of cutting.
  - Advantages of morcellation include the use of physiologic saline for distention and irrigation and the availability of tissue fragments for histologic analysis after morcellation. Of note, the system is not designed to be used for submucosal fibroids with greater than 50% intramural penetration. Mean operating time has been demonstrated to be shorter when compared to resectoscopy in both a retrospective comparison and a randomized controlled pilot study among residents in training. The latter study demonstrated a significantly reduced operating time of more than 8 minutes in comparison to conventional resectoscopy when using the IUM for polyps as well as type 0 and small (<30 mm) type 1 submucosal myomas (17 minutes versus 30.9 minutes).
  - Interlace Medical, Inc (Framingham, Massachusetts) has also developed a hysteroscopic morcellation system not yet commercially available. The system is used with NS and is being tested using 2 lens options. The rigid rod lens hysteroscope has an overall outer diameter of approximately 6.2 mm and the flexible hysteroscope has an overall diameter of less than 5.5 mm. The morcellator is designed to both reciprocate and rotate simultaneously. The metal and coating used make this device sharp and decreases tissue clogging. There is a side window in the rod for visualization of cutting. The morcellator is designed to treat type 0 and type 1 submucosal fibroids and has been used successfully during user preference testing for fibroids as large as 5 cm (oral communication). In addition to successful testing under general anesthesia, procedures using this device are also reported to be acceptable to sedated patients with use of a paracervical block. The system has the potential to be performed in the office.

JAYPEE BROTHERS

Fibroids with an Intramural Component

In general, nonhysteroscopic myomectomy should be considered for fibroids with greater than 50% myometrial extension (type II, G2 fibroids), which are technically the most difficult resections to perform through the hysteroscope. In addition, resection of the intramural component is associated with the greatest risk of fluid intravasation and decreases the chance per procedure of achieving complete resection. However, different techniques for hysteroscopic resection have been proposed for the experienced surgeon. Resection of a completely intramural fibroid poses the risk of intravasation of media due to prolonged procedure time.

- *Resection*:
  - After initial excision of the intracavitary portion of the fibroid, the intramural component will typically expel into the cavity, but the volume of the remaining intramural fibroid will subsequently increase. Thus, excising only the intracavity portion can prove futile.
  - One surgical option is complete electrosurgical excision of the fibroid, including the intramural component. This technique is associated with increased risk of perforation, bleeding, thermal damage, and fluid absorption.
  - Another suggested resection technique involves using a resectoscope to cut the capsule of the myoma away from myometrium to prevent the fibroid from sinking into the muscular layer, followed by grasping of the myoma with graspers. Rotation can then be used to pull the myoma into the intrauterine cavity. This is accomplished under ultrasonographic guidance. Supporting data is limited, with only two cases reported using this technique.
- *Cold loop*: Alternatively, the cold loop myomectomy has been proposed. The surgeon first excises the intracavitary portion of the fibroid and then uses a loop, not connected to an electrical source, for blunt dissection. The loop is used to mechanically create a plane between the fibroid and myometrium. Once the fibroid is detached from the myometrium, it can then be removed in pieces.
- *Toto enucleation*: Alternatively, in toto enucleation has been proposed. An elliptic incision is made in the endometrial mucosa covering the fibroid until the cleavage zone of the myoma and myometrium is reached. Tissue bridges between the myoma and muscle fibers are resected with electrocautery, resulting in protrusion of the fibroid into the uterine cavity. Myomectomy can then be completed by slicing. This technique has been successful in a small series of women (41 of 44) with myomas less than 4 cm in diameter with a reported mean operating time of 27 minutes.
- *Uterine contractions*: Induction of uterine contractions by facilitating rapid changes in intrauterine pressure, uterine massage, or pharmacologic agents has also been proposed as a means to encourage migration of the residual intramural fibroid into the uterine cavity.

JAYPEE BROTHERS

Intrauterine Adhesions

The standard treatment of intrauterine adhesions is hysteroscopic resection. The operative hysteroscope is introduced into the uterine cavity and centrally located synechiae are lysed first. Progression is then made to the margins of the cavity. Thin, filmy adhesions can often be lysed with blunt dissection, but thicker adhesions require excision or transection. This can be accomplished with scissors, vaporization with bipolar electrocautery, or fiberoptic laser. Concurrent use of laparoscopy or ultrasonography may be useful with extensive adhesive disease to reduce the risk of perforation.

Intraoperative fluoroscopic guidance during synechiolysis has also been proposed. With this technique, a 16 gauge, 80 mm needle or an 18 gauge, 100 mm needle is used to introduce contrast transcervically along side the hysteroscope. As contrast is injected, pockets of endometrium are identified and the needle is used to create a passageway in the surrounding adhesions. Subsequent sharp resection with the needle or hysteroscopic scissors then follows. Advantages of this technique may include early detection of false passage and capability to concurrently assess tubal patency.

Mechanical disruption of mild intrauterine adhesions through the use of pressure lavage under ultrasonographic guidance has also been proposed.

Transection and Resection of the Uterine Septum

Three methods for performing this procedure are discussed. A 12° scope is preferred with this procedure. If extensive lysis is indicated, laparoscopy can be used as an aid to decrease the risk of perforation by visualizing the illuminated cavity intra-abdominally.

The first method involves the use of resectoscope, a straight, 5 mm loop electrode, and a blended current of 70–100 watts. The septum is transected until small areas of bleeding are observed; these indicate that myometrium is reached. Do not allow the intrauterine fluid pressure to become higher than the patient's mean arterial pressure because this may prevent these bleeders from being observed easily.

In the second method, a 5–7 mm operative hysteroscope and small scissors are used to transect the septum until the important, small bleeding areas are observed. The intrauterine pressure helps in expanding the septum as it is cut.

With the third method, an operative hysteroscope and vaporizing electrode (i.e. Versapoint system) is used with 0.9% sodium chloride solution. By vaporizing the septum distally toward the fundus, it is completely removed rather than just transected.

Resection of uterine septum can be performed with scissors, a laser, or the resectoscope. When the septum is narrower than 3 cm at the fundus, incising it from distal to cephalic may allow the fibroelastic band to retract; this usually results in minimal bleeding. A broad septum requires a different approach. The first step is a lateral, alternating technique of side-to-side resection up to 0.5 cm from the fundus. Then, the remainder is removed from cornua to

JAYPEE BROTHERS

cornua to avoid damage to this area and to decrease bleeding. Laparoscopy or transabdominal ultrasonography may be useful to evaluate the external uterus during resection. If ultrasonography is used, the bladder should be left full to best visualize the uterus.

Although the septum is usually contained within the uterine cavity, a cervical septum may be present. The cervical septum can be incised with the use of Metzenbaum scissors followed by hysteroscopic resection of the corporal portion. Historically, removal has not been recommended as it may result in bleeding and cervical incompetence. However, recent studies have demonstrated improved outcomes after resection. Decreased operating times (36 minutes versus 73 minutes), use of less distending media and favorable reproductive outcomes have been reported with resection when compared to retention of the cervical septum.

Transcervical Tubal Sterilization

With the Essure system, a 5 mm hysteroscope is used to introduce a delivery catheter that contains a 3.85 cm flexible coil called a microinsert into the proximal portion of the fallopian tube. The inserts are made of a stainless steel inner coil wound in polyethylene fibers and an outer coil of nickel titanium. After a microinsert is placed at the uterotubal junction, the delivery catheter is removed and the outer coil of the insert expands. Three to eight trailing coils of the insert should remain visible at the tubal ostia. The inner polyethylene fibers induce tissue in-growth into the insert, facilitating occlusion of the tubal lumen by 12 weeks. The procedure can be performed without any anesthesia with acceptable pain scores. Additionally, it can be performed safely and efficiently in the office setting with great overall patient satisfaction. Placement in the operating room may not offer any advantage.

Intrauterine Device Removal

By using a 5–7 mm hysteroscope and a 12° scope, the intrauterine device (IUD) is grasped with a toothed grasper. The IUD is pulled toward the hysteroscope sheath. Pulling the IUD through the operating channel of the hysteroscope is impossible. Instead, the grasper is held closed, and both hysteroscope and the IUD are pulled out together.

Proximal Tubal Cannulation

A 5–7 mm hysteroscope is used with a 30° scope. The occluded tubal ostia is cannulated approximately 1–2 cm with a flexible tubal catheter, and indigo carmine is injected through the cannula and observed for its spillage through the fimbriated end by the surgical assistant performing laparoscopy. If no patency is documented, the assistant straightens the fallopian tube as the hysteroscopic surgeon slides a guide wire with a soft and flexible tip through the initial catheter and into the isthmic area of the fallopian tube. The wire is then withdrawn and patency is evaluated again.

JAYPEE BROTHERS

Operative Office Hysteroscopy

Small, more sophisticated instruments and improved flow systems now allow an operative therapy to be performed at the same time as initial diagnosis. Procedures performed in the office setting include targeted endometrial biopsy, polypectomy, myomectomy, adhesiolysis, metroplasty, and tubal sterilization.

The 5 mm Office Continuous Flow Operative Bettocchi Hysteroscope (Karl Storz, Tuttlingen, Germany) has encountered success in the office setting. This system includes a 2.9 mm rod lens system with an outer diameter of 5 mm. The instrument has a sheath for irrigation and another for suction as well as a 5 F (1.6 mm) operative canal. An oval-shaped tip facilitates introduction of the scope through a similarly shaped internal cervical os. Rotation of the scope by 90 degrees during entry to align the main axis of the scope with the transverse axis of the internal cervical os is recommended. A 4 mm system with a 2 mm rod lens system is also available. A number of 5 F instruments and bipolar electrodes are available for use with either system.

A variety of procedures have been well tolerated, without any analgesia or anesthesia, when using this system with a vaginoscopic entry approach. Procedures include mechanical treatment of cervical and endometrial polyps, IUAs, and cervical anatomical impediments, as well as Versapoint treatment of endometrial polyps and submucosal and partially intramural myomas.

Small diameter miniresectoscopes are also available. Recently, a small, prospective, observational study using a prototype of the 5.3 mm monopolar resectoscope (Karl Storz, Tuttlingen, Germany) reported favorable results for the removal of endometrial polyps and small (<3 cm) type 0 or 1 submucosal fibroids.

POSTOPERATIVE DETAILS

General Posthysteroscopy Care

Patients typically report cramping after the procedure. A single dose of ketorolac tromethamine (Toradol) reduces postoperative discomfort. Opioid derivatives can be added, if needed, for severe pain. Peritoneal discomfort may occur if a substantial amount of the distention media entered the abdominal cavity by way of the fallopian tubes. This discomfort generally subsides within 24 hours.

Most patients can go home within 1–2 hours. They require nonsteroidal anti-inflammatory drugs (NSAIDs) for 24–48 hours. Patients may have some light-to-heavy spotting for a few days to a couple of weeks, depending on the procedure performed.

Intrauterine Adhesiolysis

Prevention of postoperative adhesion formation begins with minimizing endometrial and myometrial trauma during the initial hysteroscopic

JAYPEE BROTHERS

for detailed information on obstetrics & gynecology books, visit our website www.jaypeebrothers.com, for detailed inform

Practical Guide in Reproductive Surgery

Salient Features

- The past few decades have seen major developments in the field of minimally invasive surgery. Though in many situations, assisted reproduction has replaced traditional fertility enhancing surgeries, there are several areas where *reproductive surgery* complement assisted reproduction.
- This volume, *Practical Guide in Reproductive Surgery*, covers various aspects of fertility enhancing surgeries contributed by eminent authors from all over India incorporating the latest available evidences in the field.



Gita Ganguly Mukherjee DGO MD FICOG FICMCH FRCOG is a brilliant academician and eminent teacher. She is a Senior Consultant Gynecologist and Senior Consultant in Reproductive Medicine, former Professor and Head, Department of Gynecology and Obstetrics, RG Kar Medical College and Hospital, Kolkata, West Bengal, India. She edited many important books on current issues on Obstetrics and Gynecology such as Reproductive Health, Preterm labor, PCOS, Ethical and Medico-legal Issues, Genital Tuberculosis and IUI, etc. She is the former Vice President of FOGSI, Former President of BOGS and ISOPARB and the President of RN Ganguly Foundation, which along with social work also regularly organizes CMEs for doctors. She took great effort in establishing ISAR Bengal and at present she is the chair person of ISAR Bengal. Her contribution in the field of Obstetrics, Gynecology and Infertility, and numerous publications and monographs made her known nationally and internationally.



Gautam Khastgir MD (Cal) FRCS (Edin) FRCOG (Lond) FICOG is Founder and Medical Director of BIRTH, an appropriate acronym for Bengal Infertility and Reproductive Therapy Hospital, which is one of the busiest Infertility Institution in Eastern India. He is a Subspecialist in Reproductive Medicine and Surgery, whose training has been accredited by the Royal College of Obstetricians and Gynaecologists. He was awarded a prestigious Research Fellowship from the charitable trust Well Being in the UK. His research at the Imperial College in London under the supervision of Professor John Studd led to several original papers in peer review journals as well as many chapters in textbooks. He has lectured and published widely in the field of Infertility, HRT and Endoscopic Surgery. He has also written several books on Reproductive Health in regional Indian languages for educating general public.



Bhaskar Pal DGO MD DNBE FICOG FRCOG is currently Senior Consultant of Obstetrics and Gynaecology at Apollo Gleneagles Hospital, Kolkata. He is Vice President of FOGSI, 2017, Treasurer of Indian Association of Gynaecological Endoscopists, 2017–18, Chairperson of RCOG India East IRC and the Senior Vice President of The Bengal Obstetric and Gynaecological Society, Kolkata. He is greatly involved in academic activities and contributed many chapters in various books.

Available at all medical bookstores
or buy online at www.jaypeebrothers.com

JAYPEE BROTHERS
Medical Publishers (P) Ltd.
www.jaypeebrothers.com

Join us on facebook.com/JaypeeMedicalPublishers

Shelving Recommendation
OBSTETRICS & GYNECOLOGY

ISBN 978-93-5270-484-2