logy books, visit our website www.jaypeebrothers.com, for detailed information on cardiology books, visit our website www.jaypeebrothers.com, for detailed information on cardiology books

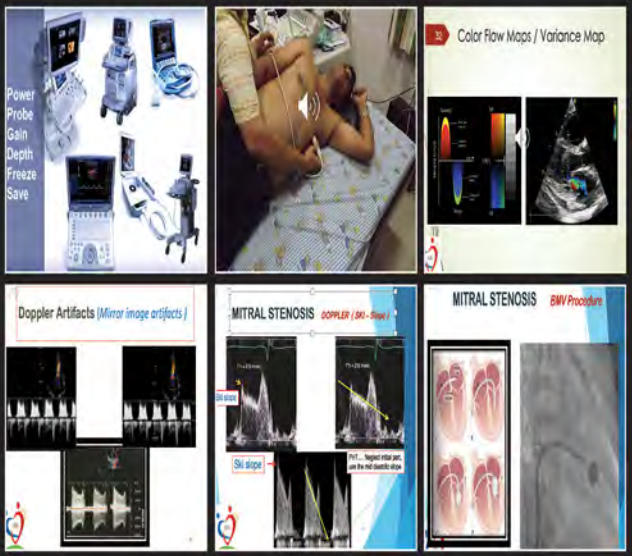

Celebrating 50 Passion, Quality and Innovation in Healthcare Publishing

Illustrative Video Manual of Echocardiography

A Step by Step Approach

PART I

SECOND EDITION

Rajesh Shah



Includes 2 Interactive DVD-ROMs
Containing 11 Videos
Duration 5 hours

Foreword
Satish C Govind

JAYPEE

CONTENTS

Echo Physics—The Basics 1



Slides 1 to 6

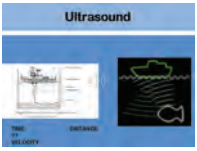

Slide 7



Slides 8 to 14

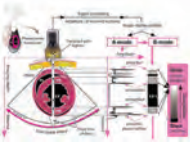
Slides 15 to 17



Slides 18 to 24



Slides 25 to 28



Slides 29 to 34

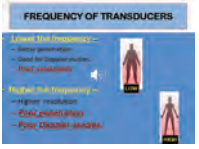

Slides 35 to 38



Slides 39 to 42

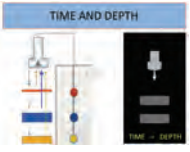

Slides 43 and 44

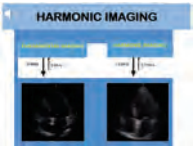

Slide 45



Slides 46 to 54



Slides 55 to 59

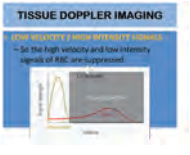

Slides 60 and 62



Slides 63 to 79

Image Optimization 4


Slides 1 to 3



Slides 4



Slides 5 to 7



Slide 9



Slides 10 to 15

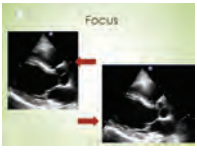

Slides 16 to 19

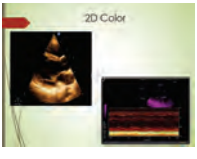

Slides 20 to 22



Slides 23 and 24



Slides 25 to 29



Slides 30 to 34



Slides 35 and 36

Introduction to Echocardiography 6



Slides 1 and 2

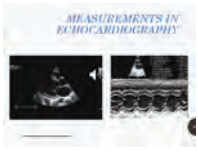

Slides 3 to 5



Slides 6 to 9



Slides 10 to 13



Slides 14 to 17



Slides 18 to 21

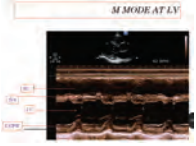

Slides 22 to 24

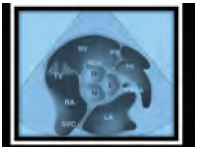

Slides 25 to 30



Slides 31 to 33



Slides 34 to 41



Slides 42 to 45



Slides 46 to 48

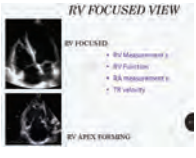

Slides 49 to 54

Basics of Color Flow Imaging and Doppler Echocardiography 9

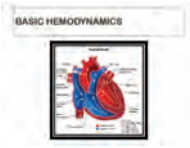

Slides 1 and 2

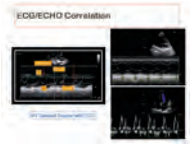

Slides 4 to 6



Slides 7 and 8

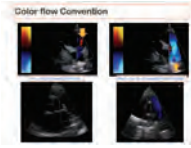

Slide 9



Slide 10

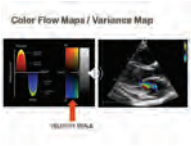

Slides 11 and 13



Slide 14



Slides 15 to 19



Slides 20 and 21

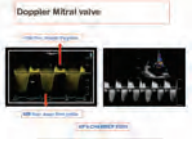

Slides 22 to 24



Slides 25 and 26

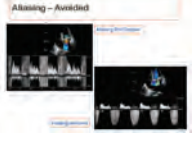

Slides 27 and 28



Slide 29



Slide 30



Slides 31 to 33



Slide 34



Slide 35



Slides 36 to 38



Slides 39 to 44



Slides 45 and 46

Mitral Valve and Mitral Stenosis 13

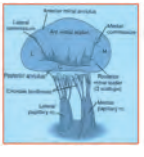

Slides 1 to 7



Slide 8



Slides 9 to 11



Slides 12 and 13



Slides 14 to 19

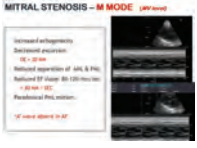

Slides 20 to 22



Slides 23 to 25



Slides 26 to 29



Slides 30 and 31



Slides 32 to 37

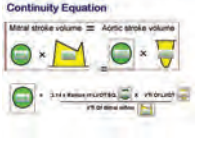

Slides 38 to 40

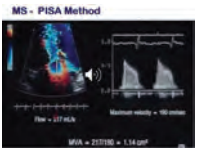

Slides 41 and 42

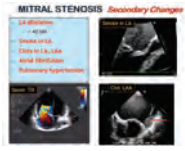

Slides 43 and 44

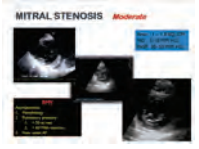

Slides 45 to 47



Slides 48 to 53

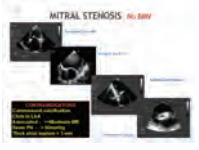

Slides 54 to 60



Slides 61 and 62

Mitral Regurgitation 16



Slides 1 to 4



Slides 5 and 6

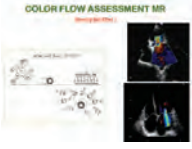

Slides 7 to 11

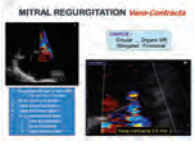

Slides 12 and 13

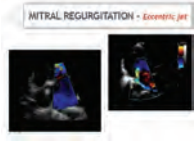

Slides 14 to 16

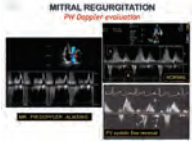

Slides 17 to 20



Slides 21 to 23



Slides 24 to 27



Slides 28 to 30



Slides 31 to 33

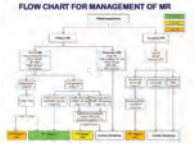

Slide 34



Slides 35 to 40



Slides 41 to 44



Slides 45 to 47



Slides 48 and 49



Slides 50 to 52

Aortic Valve and Aortic Stenosis 19



Slides 1 to 6



Slides 7 to 9



Slides 10 to 16



Slides 17 to 19



Slides 20 to 23

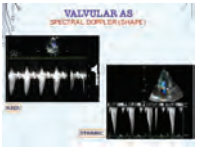

Slides 24 to 29



Slides 30 to 37



Slides 38 to 41



Slide 42

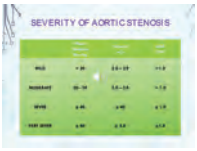

Slides 43 to 46



Slides 47 to 49



Slides 50 to 54



Slides 55 to 58



Slides 59 and 60

Aortic Regurgitation 22



Slides 1 and 2



Slides 3 to 8



Slides 9 to 12



Slides 13 to 18

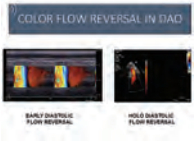

Slides 19 and 20



Slides 21 to 26



Slides 27 and 28



Slides 29 to 33

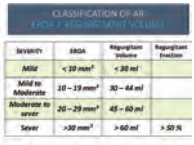

Slide 34


Slides 35 and 36

Pulmonary Valve 24

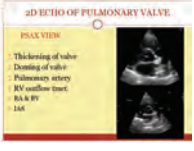

Slides 1 to 5



Slides 6 and 7

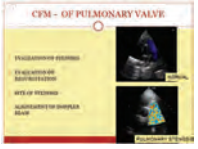

Slide 8

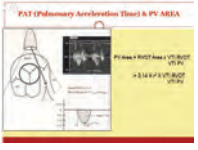

Slides 9 and 10

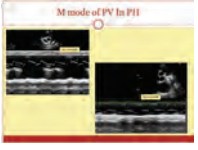

Slides 11 to 15

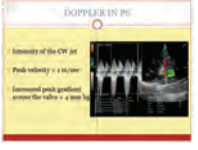

Slides 16 to 18

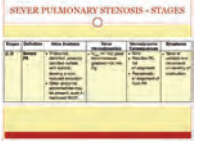

Slide 19



Slides 20 and 21



Slides 22 to 24

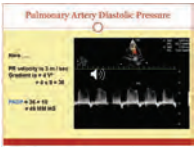

Slides 25 to 27



Slides 28 and 29

Tricuspid Valve 26



Slides 1 to 6



Slide 7



Slide 8



Slides 9 to 11



Slides 12 to 14



Slides 15 and 16



Slides 17 and 18

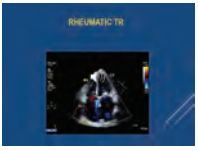

Slides 19 to 23

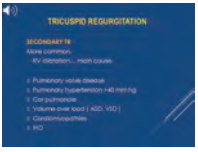

Slide 24

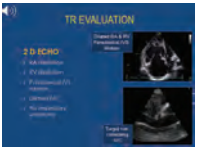

Slides 25 to 28

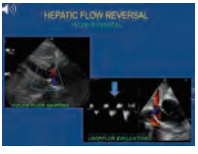

Slides 29 and 30



Slides 31 to 34

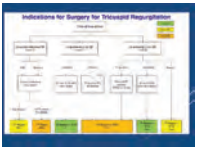

Slides 35 and 36

Pulmonary Hypertension 29

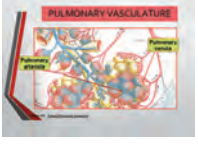

Slides 1 to 3



Slides 4 to 6


Slide 7



Slide 8



Slides 9 to 14

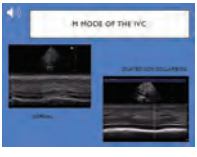

Slides 15 to 17

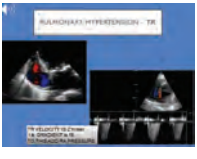

Slides 18 to 22



Slides 23 to 27

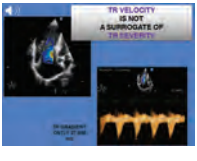

Slide 28



Slides 29 to 31

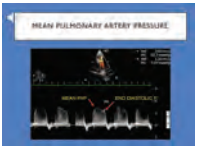

Slides 32 to 34

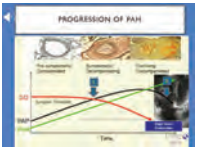

Slides 35 and 36

Illustrative Video Manual of Echocardiography

- Echo Physics—The Basics
- Image Optimization
- Introduction to Echocardiography
- Basics of Color Flow Imaging and Doppler Echocardiography
- Mitral Valve and Mitral Stenosis
- Mitral Regurgitation
- Aortic Valve and Aortic Stenosis
- Aortic Regurgitation
- Pulmonary Valve
- Tricuspid Valve
- Pulmonary Hypertension

Echo Physics—The Basics

Slides 1 to 6



These slides depict the indications and the advantage of the sonography along with the great advances in the field. People have started with large machines occupying the whole room to now only handheld devices that can be carried in the pocket.

Slide 7

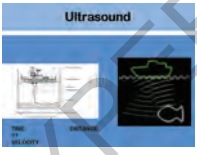

This slide illustrates how the idea of using ultrasound for evaluation of the heart came in the mind, from the use of sonar equipment in the ship. It was used to find the depth of the sea bed or locate the whales.

Slides 8 to 14



These slides discuss the basics of sound waves, there properties like wavelength and frequency, and the speed in various tissues.

Slides 15 to 17

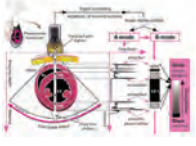

These slides discuss the display of ultrasound in its three forms namely—A-mode, B-mode and the M-mode.

JAYPEE BROTHERS

Slides 18 to 24

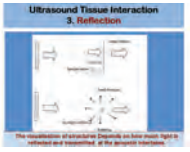

These slides discuss the different ultrasound—tissue interactions, namely—the refraction, reflection, attenuation, scatter, etc.

Slides 25 to 28



These slides, all tell us about the different target tissue characteristics and the meaning or the terminologies used such as isoechoic, anechoic, hypoechoic, etc.

Slides 29 to 34



All these slides discuss the construction and the types of transducers that are used in ultrasonography, namely—the linear, convex and microconvex, etc.

Slides 35 to 38



These slides discuss the selection of the probe for particular examination and the choice of the frequency, the advantages and disadvantages of high and low frequency transducers.

Slides 39 to 42



All these slides discuss the different physical properties of the probe, such as the near and far zone, the focal point, the significance of the index mark.

Slides 43 and 44



These slides discuss the relation of the depth of the structure to the time and the use of TGC, i.e. time gain compensation.

JAYPEE BROTHERS

Slide 45

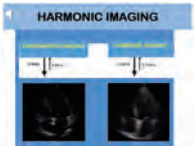

This slide discusses the details of harmonic imaging against the fundamental imaging.

Slides 46 to 54



These slides discuss in detail all about the types of resolutions, namely—axial, lateral, contrast and temporal. The importance and the methods of increasing the frame rate are also discussed.

Slides 55 to 59



These slides discuss the use of different adjustments in the machine such as zoom mode, the 2D color, dynamic range and screen display to have a good image.

Slides 60 and 62

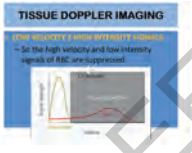

These slides discuss the different filters used in normal and tissue Doppler imaging.

Slides 63 to 79



All these slides discuss in details the causes of artefacts, and method of overcoming them, like, the side lobe artefacts, near field clutter, enhancement, reverberation, the mirror image artefacts and electromagnetic artefacts.

JAYPEE BROTHERS

Image Optimization

Slides 1 to 3



These slides discuss the importance of a crisp, good esthetic image of the ultrasound.

Slide 4



This slide discusses in detail all the methods of acquiring a good esthetic image, as recommended by the American Society of Echocardiography (ASE).

Slides 5 to 7



These slides discuss the importance of imaging from the true apex and avoiding foreshortening.

Slide 9



This slide again guides us the as to the use of different available modalities in obtaining a good image.

Slides 10 to 15



These slides discuss the proper use of sufficient amount of jelly for examination along with the proper adjustments of the gains, and time gain compensation (TGC) for image optimization.

Slides 16 to 19

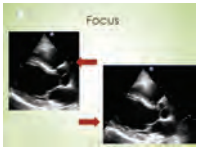

These slides discuss the proper use of focus, sector size, and sector movement along with proper depth for obtaining a good image.

JAYPEE BROTHERS

Slides 20 to 22

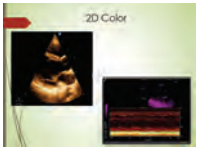

These slides discuss the use of zoom in mode as often as required along with the 2D color, called Chroma, and the screen display of the one-third to two-thirds type.

Slide 23 and 24



These slides enumerate all the Doppler settings that are a must to have the proper measurement of the velocities and gradients. These include filters, gains, scale, envelope sweep speed, etc.

Slides 25 to 29



These slides exemplify all the spectral Doppler settings that should be done, like the scale, envelope, and the sweep speed.

Slides 30 to 34



These slides discuss the adjustments that should be done for the evaluation of the color flow examination. Such as area of interest, gains, black white suppress, 2D gains, etc.

Slides 35 and 36



These slides enumerate all the Do's and Don'ts for acquitting a good image, such as minimizing translational motion, maximizing resolution, avoiding apical foreshortening, maximizing endocardial border and identifying the end diastole and systole.

JAYPEE BROTHERS

Introduction to Echocardiography

Slides 1 and 2



These slides give us an idea as to the inclusions in this presentation, like the position of patient, the different windows, M-mode, 2D echocardiography and the details of the structures seen in various windows.

Slides 3 to 5



These slides give us all the details of the modern measurement methodology.

Slides 6 to 9



These slides describe the positon of the patient, different echocardiographic windows and the different views in these windows.

Slides 10 to 13



These slides describe in details the position of the patient, the position of the probe, and the structures seen in the parasternal long axis view.

Slides 14 to 17



These slides describe the method, the wave forms with their physiological importance as seen in the M-mode examination at the mitral valve level.

Slides 18 to 21



These slides exemplify the M-mode examination at the aortic valve and left atrial level, with the normal values and some examples of abnormalities seen in this examination.

JAYPEE BROTHERS

Slides 22 to 24



These slides illustrate the method of examination of the LV by M-mode, with the normal values.

Slides 25 to 30

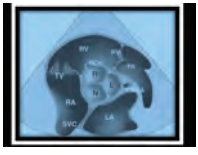

These slides describe the short axis view at the aorta and LA level, with all the structures, seen, along with the RA, PA, LA, to the coronaries.

Slides 31 to 33



These slides discuss and illustrate the parasternal short axis views at the mitral, papillary muscle and the apical level, and the different measurements taken in these vies along with the segments evaluated in these views.

Slides 34 to 41



These slides illustrate all the apical views along with the structures seen in these views the patient position, the method of imaging, along with certain abnormalities seen in these views, like the dilated coronary sinus.

Slides 42 to 45



These slides discuss the method of recording the subcostal views, the importance of these views, and most important the imaging of the inferior vena cava (IVC).

Slides 46 to 48



These slides show the method of obtaining the suprasternal view both the long and the short axis ones, along with the structures seen in these views.

JAYPEE BROTHERS

Slides 49 to 54

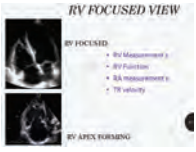

These last few slides demonstrate certain special views, that are taken in certain special conditions, for evaluation of specific structures, like the posterior tricuspid leaflet, the RA and the RV, the aortic flow.

JAYPEE BROTHERS

Basics of Color Flow Imaging and Doppler Echocardiography

Slides 1 and 2

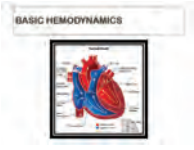

These slides deal with the hemodynamic of the blood flow across all the valves.

Slides 4 to 6

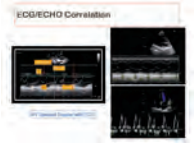

These slides show the correlation of the flow patterns across each valve in relation to the electrocardiogram which is very important for the precise timing of the various events.

Slides 7 and 8



These slides enumerate the physical properties of color flow imaging.

Slide 9

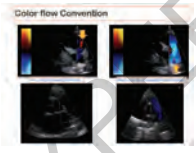

This slide shows the flow across the pulmonary valve and the color coding as per the convention, with live videos.

Slide 10



This slide demonstrates the color flow across the left ventricular inflow and outflow.

Slides 11 and 13

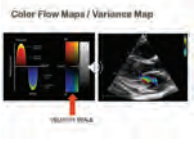

These slides discuss the types of color flows, namely—laminar and turbulent, are discussed in these two slides.

JAYPEE BROTHERS

Slide 14



The slide shows the artefacts seen during color flow imaging.

Slides 15 to 19



These slides deal with the basic physical properties of Doppler, the Doppler principle and Doppler shift and the importance of the angle of the Doppler beam to the blood flow.

Slides 20 and 21



These slides stress the importance of being parallel to the blood flow as possible and the degree of error incurred if one does not align parallel to the flow.

Slides 22 to 24

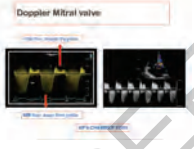

These slides show the polarity of the spectrum across each valve, in normal and disease conditions.

Slides 25 and 26



These slides discuss the properties of two different modalities of Doppler namely—pulsed wave and continuous wave Doppler are discussed in detail.

Slides 27 and 28



These slides discuss Aliasing in detail.

JAYPEE BROTHERS

Slide 29



This slide enumerates the various uses of pulsed and continuous Doppler are discussed in this slide. As in other modalities, the Doppler artifacts and the method to avoid them are shown.

Slide 30



As in the case of 2D echo and color flow imaging, certain artefact that are seen in Doppler echocardiography are shown.

Slides 31 to 33



These slides discuss the use of various Doppler modalities like the PW, CW and the color Doppler, and the normal velocities across all the valves.

Slide 34



This slide discusses the differences of the 2D verses the Doppler modalities.

Slide 35



This slide summarizes all the method of Doppler evaluation of the patient.

Slides 36 to 38



These slides discuss the Bernoulli's equation, the peak, mean gradients and VTI and their significance.

JAYPEE BROTHERS

Slides 39 to 44



These slides enumerated the views that are best for evaluation of the different valves, namely—mitral, aortic, tricuspid and the pulmonary. They also explain the view that are not useful for Doppler evaluation.

Slides 45 and 46



These slides summarize and give a take home message about the Doppler evaluation in any patient.

JAYPEE BROTHERS

for detailed information on cardiology books, visit our website www.jaypeebrothers.com, for detailed information on cardiology books, visit our website www.jaypeebrothers.com, for detail

CARDIOLOGY

Illustrative Video Manual of Echocardiography

A Step by Step Approach

Rajesh Shah



TWO INDISPENSABLE DVDs WITH STEP-BY-STEP INSTRUCTIONS FOR ELEVEN VIDEO SERIES ON ILLUSTRATIVE ECHOCARDIOGRAPHY

Salient Features

- A concise, yet practical style for learning echocardiography, and an ideal companion for the echocardiographers
- Includes all the new and updated guidelines in echocardiography such as chamber quantification, valvular heart disease assessment, etc., in accordance with the American Society of Echocardiography (ASE)
- Presents all the topics point-wise in an audio-visual manner, with suitable boxes, tables and diagrams to facilitate easy understanding
- Incorporates the fundamental techniques of echocardiography
- An easily accessible tool to recapitulate echo techniques prior to attending teaching courses, workshops or conferences on echocardiography
- Useful for practicing physicians and students of medicine, cardiology and radiology, who can learn 'on the go', at their convenience and leisure.

Contents of Part I

DVD 1 Contents

- Echo Physics: The Basics
- Image Optimization
- Introduction to Echocardiography
- Basics of Color Flow Imaging and Doppler Echocardiography
- Mitral Valve and Mitral Stenosis
- Mitral Regurgitation

DVD 2 Contents

- Aortic Valve and Aortic Stenosis
- Aortic Regurgitation
- Pulmonary Valve
- Tricuspid Valve
- Pulmonary Hypertension

Contents of Part II

DVD 1 Contents

- Left Ventricular Systolic Function
- Left Ventricular Diastolic Function
- Hypertrophic Cardiomyopathy
- Dilated Cardiomyopathy

DVD 2 Contents

- Restrictive Cardiomyopathy
- Pericardial Diseases
- Cardiac Masses



Rajesh Shah MD (Med) is a proud alumnus of Government Medical College and Hospital, Aurangabad. He had a brilliant academic career and got honored with a Gold Medal in his postgraduate MD examination. He worked at Nanavati Hospital, Mumbai, under leading cardiologists; Dr MJ Gandhi and Dr DB Pahalajani.

Consequently, he started his private practice, and has been blessed with a bright career spanning over 27 years. He is not only a renowned internist, but also an ebullient teacher. He has passion for teaching and is remembered by his students, for his art of presentation. He has also achieved the honor of being a part of the faculty of Echocardiography Conferences at Pune, Indore, Goa, and Nashik.

Available at all medical bookstores or buy online at www.jaypeebrothers.com

JAYPEE BROTHERS
Medical Publishers (P) Ltd.
www.jaypeebrothers.com

Join us on facebook.com/JaypeeMedicalPublishers

Shelving Recommendation
CARDIOLOGY

ISBN 978-93-5270-504-7