ers.com, for detailed information on neurology books, visit our website www.jaypeebrothers.com, for detailed information on neurology books



NEUROLOGICAL EXAMINATION

A Structured Approach

GRK Sarma

Foreword
P Satishchandra

JAYPEE

Contents

1. Assessment of Higher Mental Functions 1
GRK Sarma, Madhusudanan M

Overview of Mental Status Examination 1
Assessment of State Functions 3
Pictorial Pretest 3; Physiological Basis 3; Methodology and Observations 6; Interpretation 8; Caveats 8; Answers to the Pretest 8
Language Disorders 9
Definitions Important in Language Assessment 9; Physiologic Basis 10; Methodology 11; Observations 13; Interpretation 14
The Apraxias 19
Pictorial Pretest 19; Physiological Basis 20; Methodology 25; Interpretation 25; Answers to the Pretest 26
Calculations 28
Calculations and Related Parietal Lobe Functions (Finger Identification, Right-Left Orientation) 28
The Agnosias 31
Physiologic Basis 31; Methodology 33; Interpretation 35; Caveats 36
Memory 38
Pretest 38; Physiologic Basis 39; Methodology 40; Interpretation 43; Caveats 44; Answers to the Pretest 44
Construction and Dressing 45
Pictorial Pretest 45; Construction 45; Dressing 47; Answer to the Pretest 48
Tests for Higher Order Thinking (Reasoning, Abstraction, Judgment, and Executive Functions) 49
Physiologic Basis 49; Methodology 49; Judgment, Insight, and Social Appropriateness 50
Mini-mental Status Examination 51
Methodology 51; Interpretation 53; Caveats 53

2. Examination of a Patient in Coma 60
Raghunandan Nadig, GRK Sarma

Pictorial Pretest 60; Physiological Basis 62; Examination of the Comatose Patient 63; Level of Consciousness 64; Breathing 65; Circulation 66; Motor Response to Stimulus 72; Answers to the Pretest 75

3. Cranial Nerves 76
GRK Sarma, Seshu Babu G

The Olfactory Nerve (I N) 76
Physiologic Basis 76; Definitions 77; Methodology 77; History 77; Examination Technique 78; Interpretation 78; Caveats 79

JAYPEE BROTHERS

The Optic Nerve (II N) 80
Physiologic Basis 80; Methodology 82; Answers to the Pretest 93; Clinical Interpretation 99
Ocular Motor Nerves (III, IV and VI) 104
Pictorial Pretest 104; Ocular Motor Nerves 104; Physiologic Basis of Ocular Motor System 106; Certain Terms and Rules 108; Answers to the Pretest 116; Examination of Pupils and Lids 117; The Pupils 119; Eyelids 133; Answers to the Pretest 1 135; Answers to the Pretest 2 136; Answers to the Pretest 3 137
Examination of Gaze Disorders 138
Pretest 138
Saccades 139
Physiologic Basis 140; Methodology 143; Interpretation 144; Answers to the Pretest 147
The Pursuit System 148
Smooth Pursuit System 150
Vergence System 152
Physiologic Basis 152; Methodology 153; Interpretation 153
Nystagmus 154
Physiologic Basis 154; Methodology and Observations 158; Interpretation 161; Caveats 162
Trigeminal Nerve (V N) 163
Pictorial Pretest 163; Physiological Basis 163; Motor Nucleus 166; Sensory Portion 167; Trigeminal Nerve Divisions 167; Examination Method 171; Answers to the Pretest 174
The Facial Nerve (VII N) 176
Methodology 177; Interpretation 179; Caveats 180
Vestibulocochlear Nerve (VIII N) 181
Physiological Basics 181; Cochlear Nerve 183; Vestibular Nerve 185; Nystagmus in Vestibular Lesion 188; Some Practical Points 189
Glossopharyngeal Nerve (IX N) 191
Physiologic Basis 191; Methodology 192; Interpretation 193; Caveats 193
Vagus Nerve (X N) 194
Physiologic Basis 194; Methodology 197; Interpretation 197
Accessory Cranial Nerve (XI N) 200
Pictorial Pretest 200; Physiological Basis 200; Methodology 203; Interpretation 203; Caveats 204; Answers to the Pretest 204
Hypoglossal Nerve (XII N) 206
Pictorial Pretest 206; Answer to the Pretest 211

4. Motor System **212**
GRK Sarma

Muscle Tone 214; Assessment of Muscle Power—General Principles 223
Scapular Movements 228
Scapular Abduction and Forward Rotation 229; Scapular Elevation 231; Scapular Adduction 232; Scapular Depression and Adduction 233; Shoulder Flexion 235; Shoulder Abduction 239; Shoulder Internal Rotation 243

JAYPEE BROTHERS

Examination of Forearm and Hand 244
Elbow Flexion 244; Forearm Supination 247; Forearm Pronation 248; Wrist Flexion 249; Metacarpophalangeal Extension 252; Finger Flexion at Proximal and Distal Interphalangeal Joints 253; Testing of Distal Interphalangeal Flexion 254; Finger Metacarpophalangeal Extension 255; Finger Abduction 256; Finger Adduction 257; Thumb Movements 258; Thumb Extension 260; Thumb Abduction 261; Thumb Adduction 263; Thumb Opposition 264; Little Finger Opposition 265
Examination of Power of Lower Limb Muscles 266
Hip Flexion 266; Hip Extension 267; Hip Adduction 268; Hip Abduction 269; Hip External Rotation 270; Hip Internal Rotation 271; Knee Flexion 272; Knee Extension 273; Ankle Plantar Flexion 275; Foot Dorsiflexion and Inversion 276; Foot Inversion 277; Foot Eversion 278; Toe Metatarsophalangeal Flexion 279; Toes Plantar and Distal Interphalanges Flexion 280; Toe Dorsiflexion 281

5. Examination of the Sensory System 283
GRK Sarma

Proprioception 284
Physiologic Basis 284; Methodology 285; Other Tests 286; Interpretation 287
Vibration 287
Physiologic Basis 287; Methodology 288; Interpretation 289
Tactile Sensation 291
Methodology 291; Pain and Temperature 292; Segmental Localization of Sensory Loss 294

6. Reflexes 299
GRK Sarma

Deep Tendon Reflexes 299; Superficial Reflexes 307; Superficial Abdominal Reflex 307; Superficial Anal Reflex 308; Bulbocavernosus Reflex 308; Cremasteric Reflex 309; Plantar Reflex and the Babinski Sign 309; Pathologic or Primitive Reflexes 314; Pictorial Pretest 314; Primitive Reflexes 315; Grasp Reflex 315; Primitive Oral Reflexes 317; Palmomental Reflex 318; Answers to the Pretest 319

7. Examination of Coordination 320
GRK Sarma

Basic Principles 321; Testing of Station/Stance 323; Past Pointing 325; Position Holding 326; Finger-to-Nose Test 327; Heel-Knee-Toe Test 328; Dysdiadochokinesis 329; Rebound Test 330

8. Examination of Gait 332
GRK Sarma

Gait Assessment 332; Interpretation 335; Caveats 338

9. Examination of Movement Disorders 339
GRK Sarma

General Approach to Movement Disorders 339; Tremor 344;

JAYPEE BROTHERS

Archimedes Spiral Drawing (Spirography) 350; Dystonia 353; Chorea 359; Myoclonus 364; Tics 371

10. Clinical Evaluation of Seizures and Epilepsies **376**
Elisabeth Hartl, Soheyl Noachtar

Seizure Semiology 376
Pictorial Pretest 376; Physiological Basis 378; Answers to the Pretest 386

11. Examination of a Patient with Vertigo **388**
GRK Sarma, Thomas Mathew

Physiologic Basis 389; Ocular Alignment and Ocular Tilt Reaction 390; Subjective Visual Vertical (Bucket Test) 391; Head Heave Test 393; Examination of Eye Movements 393; Gaze-evoked Nystagmus 394; Head-Shaking Nystagmus 395; Hyperventilation-induced Nystagmus 396; Vibration-induced Nystagmus 397; Valsalva-induced Nystagmus 397; Positional Testing 398; The Vestibulo-ocular Reflex 402; Head Heave Test (Translational VOR) 404

12. Autonomic Nervous System **407**
GRK Sarma

Pictorial Pretest 407; Introduction 408; Heart Rate Response to Breathing 411; Bedside Orthostatic Test (Active Standing) 412; Valsalva Maneuver 414; Answers to the Pretest 415

13. Examination of a Patient with Neck Pain **417**
GRK Sarma

Pictorial Pretest 417; Examination of a Patient with Neck and Arm Pain 418; Answers to Pretest 425

14. Examination of a Patient with Low Back Pain **426**
GRK Sarma

Physiological Basis 426; Examination 431; Interpretation 433

15. Examination of Other Joints **436**
GRK Sarma

Shoulder Joint 436; Sacroiliac Joint 440; Knee Joint 443

16. Examination of Trigger Points **451**
GRK Sarma

Myofascial Pain 451

17. Neurological Examination of a Neonate **458**
Chandrakala BS

General Examination 460; Posture 460; Involuntary and Spontaneous Movements 461; Neurobehavioral Items 462; Fontanelles, Sutures and Head Circumference 463; Tone 464; Reflexes 470; Central versus Neuromuscular Hypotonia 473; Cranial Nerve Examination 473; Summary of Age Related Neurological Examination Findings in Neonates 475

18. Pediatric Neurological Examination **477**
Sushma K, Ranjini Srinivasan

General Principles of Pediatric Neurological Examination 477; General Physical Examination in Pediatric Neurology 478

Index *497*

JAYPEE BROTHERS

CHAPTER 13

Examination of a Patient with Neck Pain

GRK Sarma

JAYPEE BROTHERS

PICTORIAL PRETEST

A 65-year-old man presented with chronic neck pain in the following distribution (Fig. 13.1). The pain was mild to moderate and is brought on and increased after walking for 10 minutes, and relieved by rest. Mostly, he is forced to rest because of the pain. There was no associated chest pain or diaphoresis.

He is a known to have poorly controlled diabetes mellitus with end organ involvement including nephropathy and peripheral neuropathy. His cervical spine was non-tender, with nearly normal range of movements. There were no neurological deficits to suggest cervical radiculopathy or myelopathy. His MRI cervical spine showed mild disc bulges at multiple cervical levels without significant root or cord compression. His cardiac evaluation was normal including electrocardiography (ECG), echocardiography and treadmill test. In the latter, the patient developed the habitual neck pain without ECG changes.

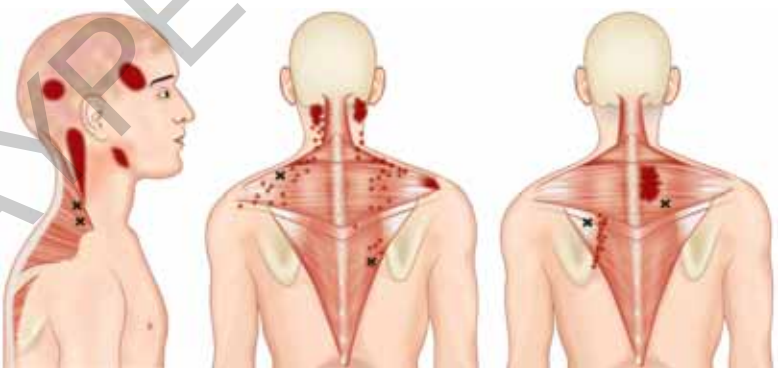

Fig. 13.1: Pain distribution in a 65-year-old man, precipitated by walking.

Questions

1. What is the source of the neck pain in this patient?
2. What is this distribution of pain known as?

3. Which bedside or laboratory test may confirm the diagnosis?

(Answers are discussed at the end of the chapter)

EXAMINATION OF A PATIENT WITH NECK AND ARM PAIN (FIGS. 13.2 TO 13.5)

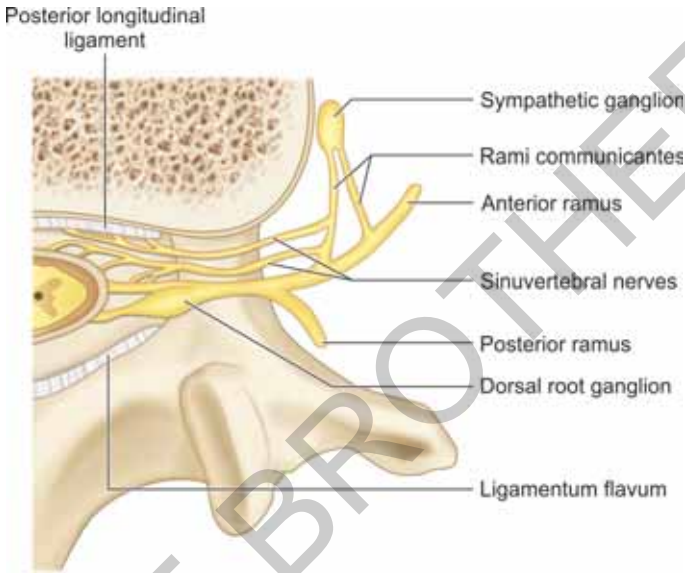

Fig. 13.2: Spinal nerve roots and their branches.

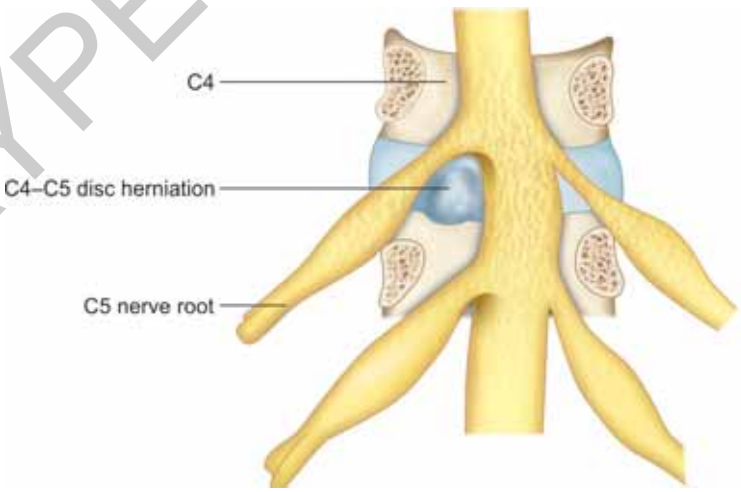

Fig. 13.3: Relation between the vertebral level and the root level in the cervical spine.

JAYPEE BROTHERS

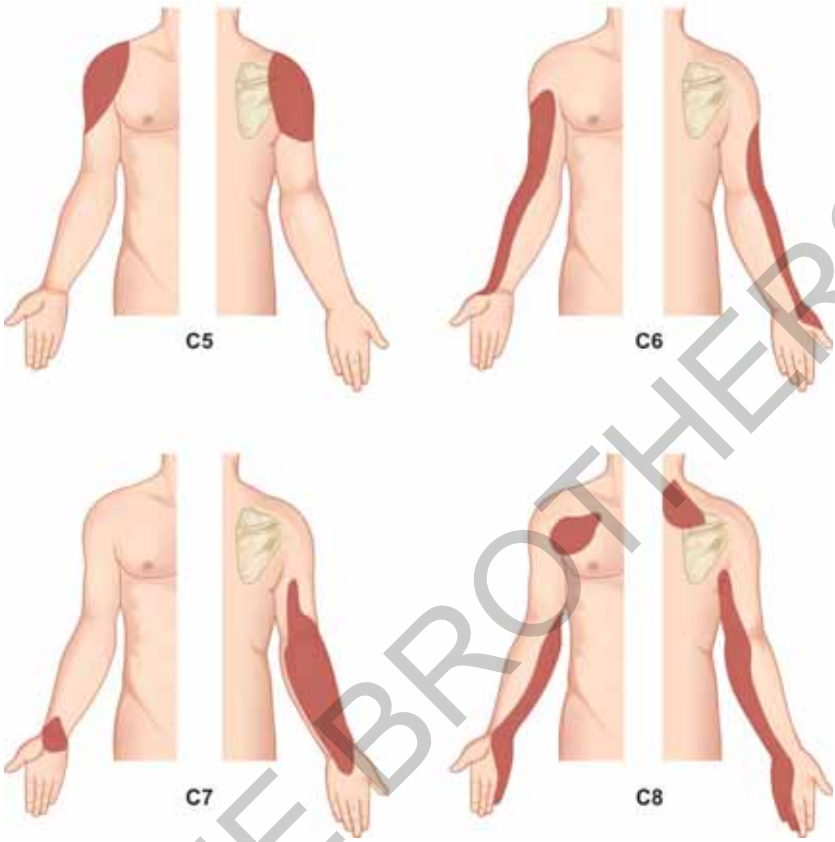

Fig. 13.4: Distribution of radiating pain in radiculopathy at various levels.

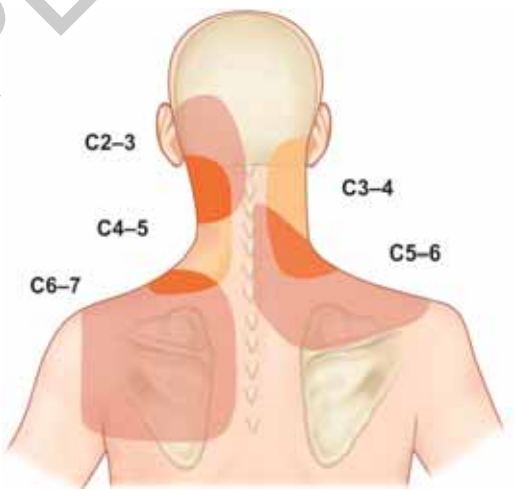

Fig. 13.5: Local pain distribution in disc disease at various levels.

JAYPEE BROTHERS

Physiologic Basis

Certain anatomical factors are important in understanding the pathogenesis of spinal disease as well as the variability in its clinical manifestations. Some of the more important anatomical factors are described below. For a comprehensive review of spinal anatomy, please see the references.

- The mid-sagittal diameter of the cervical spinal canal is an important parameter in understanding pathogenesis of cervical compressive myelopathy. Its normal values are as follows:
  - C1-3: 21 mm (16–30 mm)
  - C4-7: 18 mm (14–23 mm)
  - The cervical cord occupies 40% of the diameter of the spinal canal.
- With neck extension, the diameter decreases by 2–3 mm and can cause cord compression in the already diseased spine (e.g. spondylosis/ congenital canal stenosis).
- Neck hyperextension can also compromise the anterior spinal artery by the same mechanism and cause ischemic cord injury as well as vertebral artery dissection.
- Neck pain is a common symptom of various disease processes that involve the spine. To evaluate this symptom in a systematic way, understanding its pathogenesis is important.
- The pain sensitive structures of spine are:
  - Skin
  - Subcutaneous tissue
  - Adipose tissue
  - Ligaments (longitudinal spinal, interspinous, flaval)
  - Periosteum
  - Epidural fibrofatty tissue
  - Dura
  - Arterioles
  - Veins (epidural and paravertebral)
  - Paravertebral muscles
  - Nerve roots
  - Diseases involving any of the above structures can cause neck pain.

  Notably absent from the list is the inter-vertebral disc, which has no significant nociceptive fibers. When the herniated disc comes into contact with ventral root, painless weakness can result. When it contacts the sinuvertebral nerves in the posterior ligaments and the dura of the nerve root sleeve, pain is produced. This explains why a prolapsed disc can: (a) be painless, (b) cause non-radiating pain, (c) cause radicular pain, and (d) cause radicular weakness with or without pain.

Classifications

Neck pain may be classified as **radiating**, **non-radiating and referred pain**. Each of these pain types has a different source and a different nerve supply.

JAYPEE BROTHERS

Non-radiating Neck Pain

- It is presumed to be due to musculoligamentous injury and degenerative changes.
- It is mediated by the **posterior primary ramus** and the recurrent meningeal nerves (**sinuvertebral nerves**) (Figure 13.2).
  - The **posterior rami** provide sensory fibers to fascia, ligaments, periosteum and facet joints.
  - The **sinuvertebral nerves** innervate the degenerated intervertebral discs, anterior and posterior longitudinal ligaments, dura mater and blood vessels.
- The usual areas where non-radiating pain is reported by patients with disc lesions at various levels are depicted in the Figure 13.4.
- Salient differences between the non-radiating pain and radiating pain are listed in the (Table 13.1).
- Another important cause of neck pain (the so called "**coat hanger**" pain) is orthostatic hypotension. The mechanism is ischemia of the cervical structures in erect posture. It is often mistaken for "spondylotic pain" with unsuccessful management strategies. It is brought on by prolonged standing or exercise in patients with autonomic insufficiency.

Radiating Neck Pain

- It is mediated by the spinal nerves
- It originates from mechanical compression or inflammation
- Inflammation is partly immunologic (due to exposure of the herniated nucleus pulposus to immune system) and partly neurogenic
- The distribution of radiating pain with root compression at different levels is shown in the Figure 13.4.

Table 13.1: Differences between radicular and musculoskeletal pains.

Parameter	*Radicular pain*	*Musculoskeletal pain*
Quality of pain	Sharp, lancinating	Deep aching pain
Location	Along dermatomal distribution	Paraspinal region
Spread	Along dermatomal pattern	Shoulder, scapula, upper arm only
Duration	Lasts days to weeks	Lasts 1–3 months
Diurnal variation	Worse on waking up	Worse as the day passes
Effect of Valsalva	Worsens or reproduces	Remains localized
Neurological deficits	Often present	Absent

Referred Pain

- It is poorly defined and often cramping type of pain
- Its precipitating and relieving factors provide a clue to the organ that is generating the pain.
- It is usually referred to midback or low back, and rarely to cervical level.
- Some possible causes include: Myocardial ischemia, aortic dissection, etc.

JAYPEE BROTHERS

Methodology

The clinician must aim to find physical tests that reproduce each of the patient's symptoms.

Inspection

The following signs may be looked for:

- Head tilt
- Neck deformity
- Restricted neck movements
- Visible spasm of the paraspinal muscles
- Long droopy neck

Note the distribution pattern of pain as described by the patient as it has a localizing value (Table 13.1).

Palpation

- Tenderness
- Range of neck movements
- Trigger points.

Neuromechanical Tests

Spurling test (formainal compression test)(Fig. 13.6):

- Tilt the head to the side of the arm pain
- Compress the head downwards
- Pain and paresthesia radiating down the ipsilateral arm suggest its root compression.
- The sensitivity of this test is reported as 40–60% while specificity is 90–100% for cervical radiculopathy.
- Caveats:
  - This test does not indicate the etiology, though prolapsed disc is the most common one
  - In some patients, pain and paresthesia may radiate down the contralateral limb due to stretching of the compressed root on that side.

Arm abduction test (Relief sign): It was also described by Spurling.

- Reduced nerve root tension is the possible cause for symptom relief with shoulder abduction
- Method: Active abduction of symptomatic arm, placing patient's hand on head.
- Positive test is relief or reduction of ipsilateral cervical radicular symptoms.
- Sensitivity of 40–50%, specificity of 80–100% for cervical radiculopathy have been reported.

JAYPEE BROTHERS

Traction test (opposite of the Spurling test):

- Patient is usually placed in supine position
- Hold the patient's head in both hands, with one hand under the chin and the other below the occiput
- Gently lift the head away from the fixed trunk
- Relief of pain and paresthesia suggests root compression
- Sensitivity of 40% and specificity of 80% have been reported.

Valsalva test: Increase in pain on Valsalva maneuver suggests that the intrathecal pressure is being transmitted to the compressed/inflamed nerve root.

Lhermitte's test:

- Patient is seated comfortably
- Flex the neck of the patient as much as possible
- Pain and paraesthesia radiating down the back or to the arms is abnormal
- Positive Lhermitte's test suggests posterior column disease as in B_{12} deficiency and multiple sclerosis. It is also seen in compressive lesions of the cord
- The sensitivity and specificity of this sign have not been systematically evaluated.

Trigger points:

(See the chapter on Trigger Points)

Facet joint:

Cervical facet syndrome includes following symptoms and signs:

- Axial neck pain (rarely radiating past the shoulders), most common unilaterally
- Pain with and/or limitation of extension and rotation
- Tenderness upon palpation
- Palpate along the paravertebral regions and directly over the transverse processes because the facet joints are not truly palpable.

Adson's test:

- Has been described as a sign of cervical rib or scalenus anticus syndrome
- Its utility has been discussed in Adson's review of 169 surgically treated cases
- However, there are no other studies on the sensitivity or specificity of this test.

Method:

- The patient's head is rotated to face the tested shoulder
- The patient then extends the head
- The examiner laterally rotates and extends the patient's shoulder
- The examiner locates the radial pulse, and the patient is instructed to take a deep breath and hold it.

JAYPEE BROTHERS

- A disappearance of the pulse is indicative of a positive test
- About 80–90% of patients with positive Adson's test had good relief after surgical treatment in the above series.

Neurological Examination

i. Muscle power in myotomal pattern
ii. Sensory examination in dermatomal pattern
iii. Sensory level and sacral sparing or involvement
iv. Deep tendon reflexes
v. Abdominal reflexes, plantar reflexes, cremasteric reflexes (see respective chapters)
vi. Autonomic signs
vii. Signs that indicate additional supraspinal or extraspinal lesion: Even in a patient with neck pain and a clear radicular pain, it is useful to check the following signs. Sometimes, there could be an unrelated brain lesion (multi-infarct state in an elderly man with neck pain due to spondylosis) or a related brain lesion (demyelinating plaques in brain in addition to cord lesion).
    - Jaw jerk
    - Palmomental reflex
    - Snout reflex
    - Pout reflex
    - Extrapyramidal signs
    - Scalp tenderness
    - Temporal artery tenderness
    - Temporomandibular joint tenderness.



Fig. 13.6: Spurling test.

JAYPEE BROTHERS

Caveats

In many instances, the pain may not be clearly localized to the source of its origin, inspite of various clinical symptoms and signs. In such cases which are not improving with therapy, a neuroimaging is warranted.

ANSWERS TO PRETEST

The pain distribution is called "coat hanger" headache. It is described in orthostatic hypotension and is believed to be due to ischemia of the cervical and cranial structures in erect position and walking. In this patient, local causes were excluded by clinical examination and normal MRI. Referred pain from myocardial ischemia is a concern, but a treadmill test was negative for inducible ischemia, inspite of pain reproduction.

Bedside measurement of BP and pulse rate are the initial steps in the diagnosis. Formal autonomic function tests with head up tilt may be very informative. His autonomic function studies revealed significant postural drop of blood pressure and a failure of compensatory tachycardia. He improved significantly with elastic compression stockings and fludrocortisone.

BIBLIOGRAPHY

1. Adson AW. Cervical ribs: symptoms, differential diagnosis, and indications for section of the insertion of the scalenus anticus muscle. J Internat Coll Surg. 1951; 16:546-59.
2. Devereaux MW. Anatomy and examination of the spine. Neurol Cli. 2007;25:331351.
3. Fast A, Parikh S, Marin EL. The shoulder abduction relief sign in cervical radiculopathy. Arch Phys Med Rehabil. 1989;70:402-3.
4. Malanga GA, Landes P, Nadler SF. Provocative tests in cervical spine examination: Historical basis and scientific analyses. Pain Physician. 2003;6:199-205.
5. Sandmark H, Nisell R. Validity of five common manual neck pain provoking tests. Scand J Rehab Med. 1995;27:131-6.
6. Viikari-Juntura E, Porras M, Laasonen EM. Validity of clinical tests in the diagnosis of root compression in cervical disease. Spine. 1989;14:253-7.
7. Viikari-Juntura E. Interexaminer reliability of observations in physical examinations of the neck. Phys Ther. 1987;67:1526-32.

JAYPEE BROTHERS

for detailed information on neurology books, visit our website **www.jaypeebrothers.com**, for detailed information on neurology books, visit our w

Neurological Examination

A Structured Approach

The main objective of this book is to make neurological examination as **objective** and **standardized** as possible and to minimize the variability in its **execution** and **interpretation**. This is achieved by following a structured format throughout the book that divides each clinical test into **four components**:

- **Physiological basis**
- **Methodology**
- **Interpretation**
- **Caveats**

This fixed format facilitates **quick access** to the topic of interest and inculcates **logical thinking** in day-to-day practice.

The other salient features are:

- **Pictorial pretests** and answers to drive home a teaching point
- **Bulleted format** and **direct language** make it an easy reading for a busy reader
- Some **exclusive topics** are covered here:
  - **Seizure semiology**
  - **Autonomic** function tests
  - Evaluation of **vertigo**
  - Assessment of **gait**
  - Neurological examination of **neonates, infants and children**
  - Examination of cervical spine and lumbosacral **spine**
  - Assessment of **trigger points** and **myofascial pain**
  - An exhaustive discussion of individual **muscle power assessment.**
- Useful for clinicians and trainees in Neurology, Neurosurgery, General Medicine and Pediatrics. Some chapters are also of interest to Orthopedicians and Psychiatrists
- Critical comments, suggestions and controversies can be mailed at sarma.grk@gmail.com and will be discussed in the Google+ page dedicated to this book.

GRK Sarma MD DM is Professor, Department of Neurology, St. John's Medical College Hospital, Bengaluru, Karnataka, India. He did his undergraduate and postgraduate medical education (General Medicine) from the Jawaharlal Institute of Postgraduate Medical Education and Research **(JIPMER)**, Puducherry, India. He received DM Neurology training from the National Institute of Mental Health and Neurosciences **(NIMHANS)**, Bengaluru. He has completed the Epileptology and Neurophysiology course and Observership at the Cleveland Clinic Epilepsy Center, Cleveland, Ohio, USA.

He has been a faculty in the Department of Neurology, St. John's Medical College Hospital, Bengaluru, for the past 18 years. He has experience in teaching students of DM Neurology, DNB Neurology and EEG/EMG technician courses. He served as examiner in DM Neurology, DNB Neurology, MD Psychiatry and PhD in basic sciences. He has about 50 publications in national and international journals and book chapters.

Available at all medical bookstores
or buy online at www.jaypeebrothers.com



JAYPEE BROTHERS
Medical Publishers (P) Ltd.
www.jaypeebrothers.com

Join us on facebook.com/JaypeeMedicalPublishers

Shelving Recommendation
NEUROLOGY

