CONTENTS

1. **Evaluation, Workup and Postoperative Care in Hair Transplant** 1
   Rajesh Kumar, Pradeep Sethi, Abhinav Kumar, Sarita Sanke

2. **Direct Hair Transplantation** 11
   Pradeep Sethi, Arika Bansal

3. **Anesthesia, Pain Management and Hemostasis in Hair Transplant** 19
   Abhinav Kumar, Arika Bansal, Raghunatha Reddy

4. **Designing the Anterior Hairline** 27
   Pradeep Sethi, Arika Bansal, Abhinav Kumar, Sarita Sanke

5. **Temple, Hump and Mid-scalp Reconstruction** 65
   Pradeep Sethi, Arika Bansal, Abhinav Kumar

6. **Designing the Crown** 83
   Arika Bansal, Pradeep Sethi, Abhinav Kumar

7. **Body Hair Transplant** 101
   Arika Bansal, Abhinav Kumar, Pradeep Sethi

8. **Art and Science of Scoring of Grafts** 119
   Abhinav Kumar, Arika Bansal

9. **Graft Handling** 135
   Abhinav Kumar, Pradeep Sethi, Sarita Sanke

10. **Complications: A Rare Thing in Trained Hands** 147
    Sarita Sanke, Arika Bansal, Abhinav Kumar

11. **Corrective Hair Transplant** 165
    Pradeep Sethi, Arika Bansal, Abhinav Kumar

12. **Megasession or Gigasession** 185
    Arika Bansal, Pradeep Sethi, Abhinav Kumar

13. Female Hair Transplantation **211**
Arika Bansal, Sarita Sanke, Pradeep Sethi

14. Eyebrow and Eyelash Transplantation **225**
Sarita Sanke, Manas Chatterjee, Pradeep Sethi

15. Hair Transplantation in Cicatricial Alopecia **235**
Sarita Sanke, Pradeep Sethi, Priyadarshini Das, Abhinav Kumar

16. Setting Up a Hair Transplant Center **241**
Pradeep Sethi, Abhinav Kumar, Sarita Sanke

17. Photography in Hair Transplant **255**
Pradeep Sethi, Abhinav Kumar, Priyadarshini Das

Case Studies *271*

Index *313*

CHAPTER 4

Designing the Anterior Hairline

Pradeep Sethi, Arika Bansal, Abhinav Kumar, Sarita Sanke



No two faces on earth are similar!

Every face contains two eyes, one nose, two ears, one forehead, two cheek bones, chin, two eyebrows, one mouth and one hairline! Every face is a permutation and combination of each of these components. It is customized to one individual. The anterior hairline is the gateway into the face. It is the most important aspect of the aesthetic part of the hair restoration surgery. It needs to be done aiming to reproduce a near natural hairline.

JAYPEE BROTHERS

INTRODUCTION

Frontal hairline is one of the most important aesthetic feature of scalp hair and plays an important role in assessing the age of the patient. Recession of anterior hairline is almost always a part of androgenetic alopecia, and sometimes in cicatricial alopecia like frontal fibrosing alopecia, traction alopecia (especially in females these two can also be one of the causes).

Restoring the anterior hairline in a patient is challenging for any hair transplant surgeon. The three major goals of a surgeon would be to give a natural appearance to the hairline, maintain the symmetry grossly and thirdly the aesthetic appearance should be such that, it should make the patient look younger (Figs. 4.1A to E).

Five types of anterior hairline shapes have been mentioned by Sirinturk et al.[1] These include the round, M type, rectangular, bell-shaped and triangular (Figs. 4.2 to 4.6). Males usually have M type hairline, while females have round or rectangular hairline.

A. *Round:* This hairline is suited for a wider head with mature stable temporal hair. It shows convexity throughout the design.
B. *M type:* Severe frontotemporal recession is present.
C. *Rectangular:* Horizontal frontal line with minimal frontotemporal recess. This hairline design will consume more grafts but it is a more natural form of hairline and helps in restoring the original youthful look of the early twenties.
D. *Bell-shaped:* Large frontal height than normal. It is meant for a narrow head and it conserves grafts and has temporal recession.
E. *Triangular:* Hairline moves down from frontal to temporal area nearly straight.

ANATOMICAL LANDMARKS OF ANTERIOR HAIRLINE

Hairline designing is not pure mathematics where you just know the various anatomical points on the face and scalp and draw a line joining them to create a hairline. The unique selling point of a beautiful hairline is the inability of the

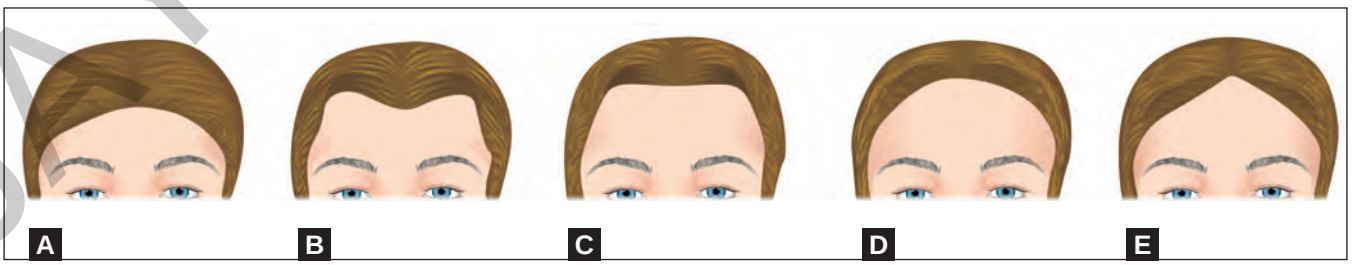

Figures 4.1A to E

Different designs of the anterior hairline.

JAYPEE BROTHERS



Figures 4.2A to C

Pictures depict a round hairline for a person with wider head.



Figures 4.3A to C

Triangular hairline.



Figures 4.4A and B

A rectangular hairline—we make this hairline in people where we see a rectangular face with flat forehead.

JAYPEE BROTHERS



Figures 4.5A to C

Another variant of rectangular hairline with three small peaks.



Figures 4.6A to C

A bell-shaped hairline in a male with its post-transplant results after 5 months.

onlooker to detect that you have got a transplant! It is only possible when the hairline does not hit the person's eyes as something unnatural or weird. A young hair transplant surgeon should use all his observation of natural hairlines to give the best possible hairline to his patient.

However, a basic understanding of landmarks is important (Figs. 4.7 and 4.8).[2]

Mid-frontal point (MFP): It should be marked on the vertical line from glabella to trichion. The forehead height (from trichion to glabella) is usually 6–6.5 cm. But for surgical lowering of hairline, the MFP should be marked usually at a height of 7–10 cm. However, this varies from person to person with different types of face contour.

JAYPEE BROTHERS



Figure 4.7

Image depicts a hairline which arches down from the MFP (mid frontal point) to MTP (mid temporal point) instead of arching upward. Always cross check the side views of the hairline to avoid such mistakes.



Figures 4.8A and B

Anatomical landmarks of the anterior hairline. A, C, B, T, S are the exact point where FA, FRA, TPA, IA and SA are located (Point A to C: FA; Point B: FRA; Point T: TPA; and Point S: SA).
(FA: frontal area; FRA: frontotemporal recess area; TPA: temporal peak area; IA: infratemple area; SA: sideburn area)

JAYPEE BROTHERS

Frontotemporal angle (FTA): It is always located on a line drawn vertically from the lateral epicanthal folds. A line drawn from the MFP to the FTA should always slope slightly upward when viewed from the side. If the line arches down, it will look like an artificial hairline from side view. If patient wants the hairline to be more aggressive, the line from MFP to FTA can go flat but it can never arch down.

Frontal area (FA): Also known as widow's peak or central peak. It is an inverted triangular area, with its peak at the center pointing downward. This peak also known as mid-frontal point (MFP) forms reference point for determining the symmetry of the hairline, and the height of the hairline.

Frontotemporal recess area (FTR): The two other points of the triangle above form the FTR area. It lies on a line drawn vertically from the lateral epicanthal fold (Fig. 4.9).

Temporal peak area (TPA): It is the temporal area hairline pointing anteriorly toward the angle of eye.

Infratemple area (ITA): The area just below the TPA is the infratemple area and is concave in shape.

Mid-pupillary point is the point where the hairline starts to recede back, just behind the MFP (Fig. 4.10).

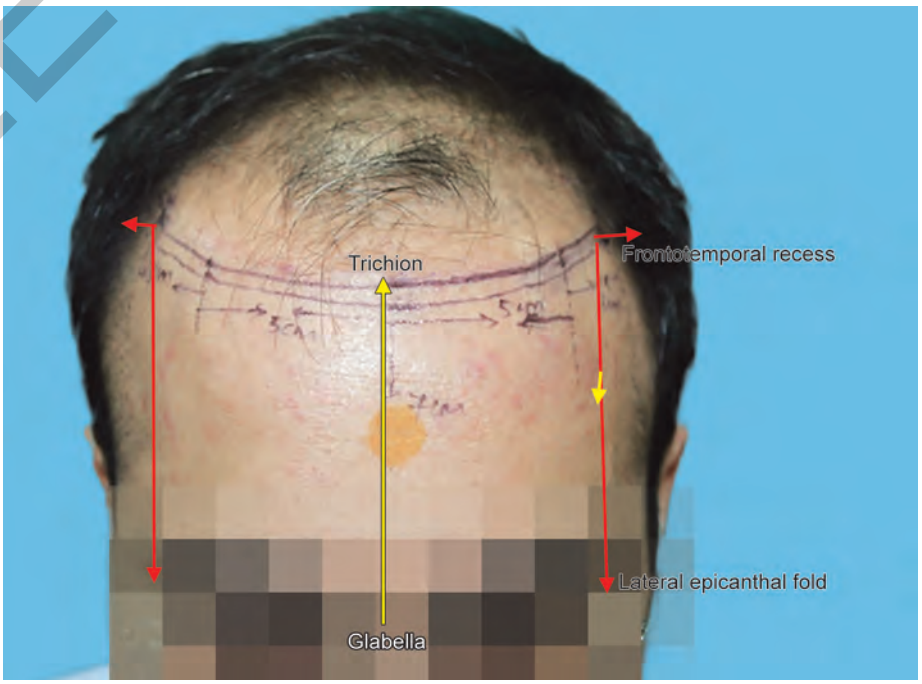

Figure 4.9

The yellow line depicts the forehead height from trichion at top to glabella at root of nose. The frontotemporal recess always lies on the red line extending vertically upward from lateral epicanthal folds.

JAYPEE BROTHERS



Figure 4.10
Mid-pupillary point.

Drawing the Hairline

After knowing the anatomical points, the hairline design starts with marking the mid-frontal point. Mid-frontal point can be kept anywhere between 7 cm and 10 cm from the glabella.[3] Doctors often fall into the trap of patients who are young and wish to keep the hairline very low at 7 cm or even at 6.5 cm, in spite of having a bigger head and family history of Norwood grade 7 baldness. Keeping a low hairline will make the patient repent in later years of his life when there is progressive loss of the hair behind and lateral to the reconstructed hairline, making the anterior transplanted hairline look unnatural. However, keeping the hairline too high will also not give satisfaction to the patient, so it is important to find the right distance of mid-frontal point from the glabella, which will ensure a consistent look of the patient throughout his rest of life. One way of deciding the mid-frontal point is the intersection between horizontal and vertical planes (Fig. 4.11).[3] Another way of deciding this point is to use a flexible scale and measure the distance from glabella and then mark the MFP followed by using a laser-assist hairline design device to mark the hairline (Fig. 4.12).[4]

After determining the mid-frontal point, the location of frontotemporal angle needs to be determined. It can be determined by drawing a line from lateral epicanthus of the eye back toward the point where it meets the temporal hair.[3]

JAYPEE BROTHERS

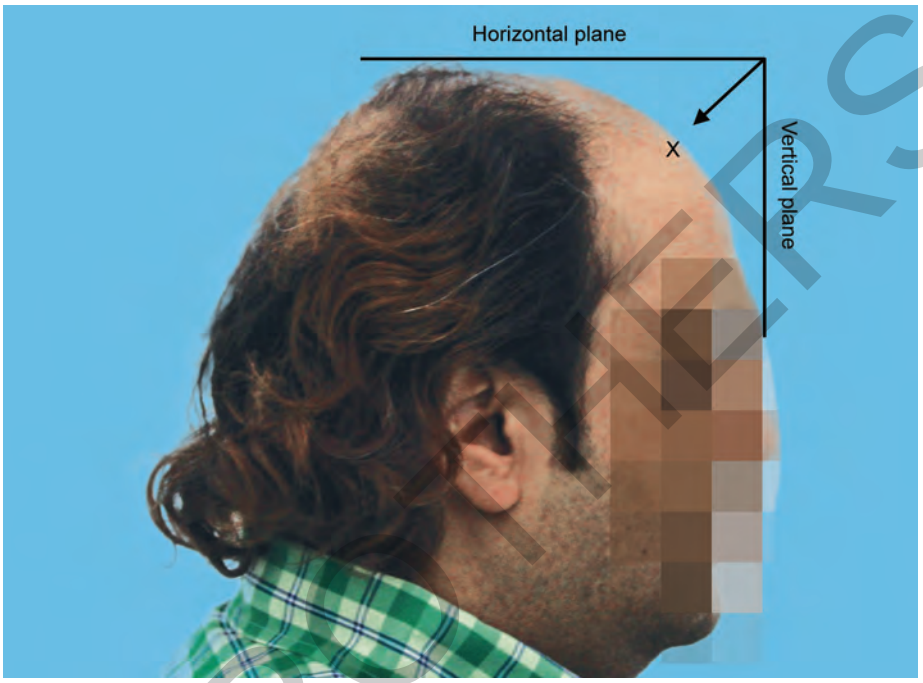

Figure 4.11

The point where the horizontal and vertical planes intersect is marked as mid-frontal point (MFP).

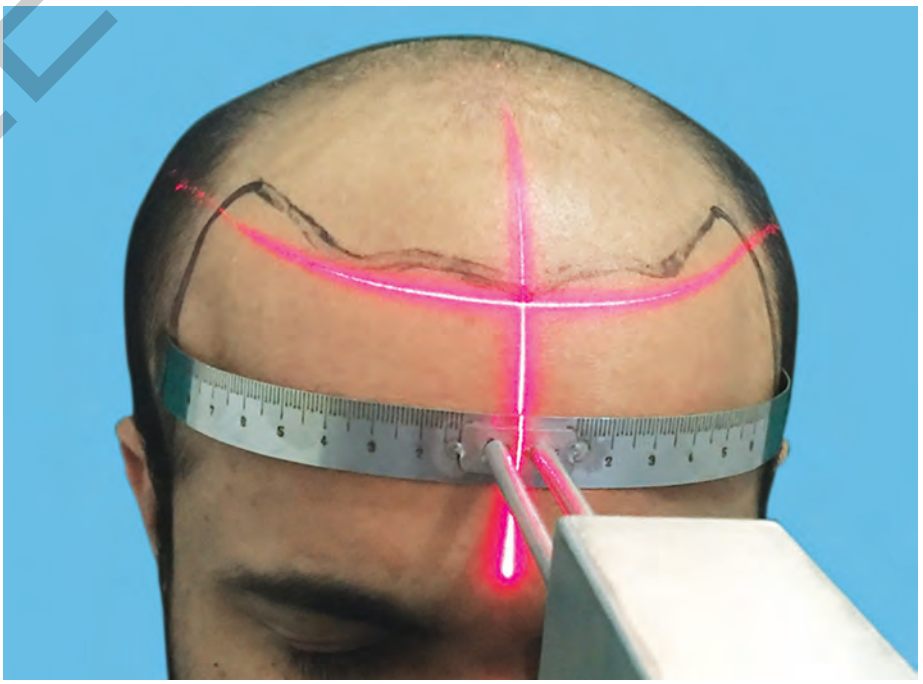

Figure 4.12

Laser-assist hairline design device which is being used to make a hairline, to ensure the symmetry of the hairline. Tracing your hairline along the laser beam is not necessary for a good hairline!

JAYPEE BROTHERS

In case of severe degree of baldness where there is no temporal hair, visualizing lateral or parietal hump is important.[3] The lateral hump is a semicircular area of hair which bridges the lateral fringe and the mid-scalp region. It is present in Norwood Grade 6 baldness and is absent in Norwood grade 7 baldness. Visualizing this hump in Norwood grade 7 gives the lateral epicanthal line a target to intersect.[3] They usually meet near the top of the hump and lateral hump usually becomes the inferior border of frontotemporal angle (Fig. 4.13).[3]

Another visualization technique is drawing a line parallel to the side burn, and the point where it meets the lateral epicanthal line, is the location of frontotemporal angle (Fig. 4.14).[3]

After drawing the hairline, the patient should be shown the mirror in which he can visualise his to be the reconstructed hairline. One should remember that the image, which a patient sees in the mirror, is 2D image of the hairline and may ask for some corrections which do not fit into surgeons' imaginations.[5] Disconnect between the surgeons' imagination and patient's imagination has to be explained to the patient. The surgeon should also look at the hairline from a distance and from the back by making the patient look upward. One should remember that recession of the left and right temple is never identical, so slight asymmetry in hairline drawing is acceptable and provides naturalness in the look.

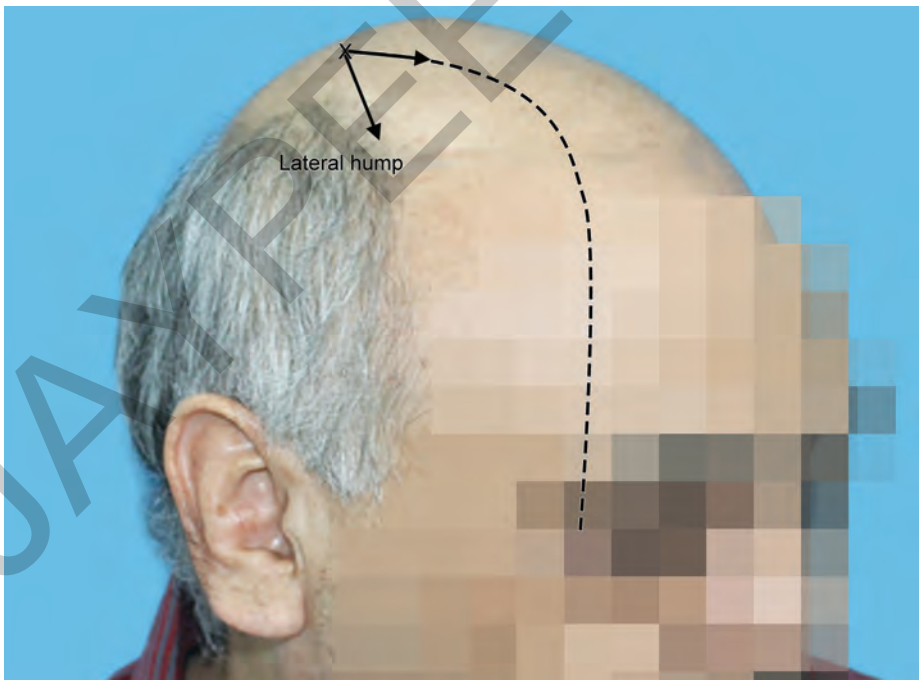

Figure 4.13

Intersection of the lateral epicanthal line with the upper border of the "lateral hump" gives the frontotemporal angle.

JAYPEE BROTHERS



Figure 4.14

A line is drawn parallel to the side burn, and the point where it meets the lateral epicanthal line, is the location of frontotemporal angle.

HAIRLINE DESIGNING

After drawing the hairline, which is acceptable to both the surgeon and the patient, one can proceed with the surgery. The surgeon must evaluate and re-evaluate the symmetry, shape and position of hairline from all possible angles, i.e. from the front, with the head bent downward and from behind.[5] However, few patients may not agree to surgeon's designed hairline and will insist for a lower hairline, it can be done by creating a widow's peak which creates an illusion of a lower hairline.[3] A widow's peak is recommended in a conservative bell-shaped hairline. Some patients ask to fill the frontotemporal angle. Instead of filling the angle, the whole frontotemporal angle can be brought forward.[3] A hairline which looks symmetrical to the surgeon may look asymmetrical to the patient in the mirror because he is seeing himself in the mirror which distorts the 3D image of the surgeon to 2D image of the mirror due to asymmetry of the skull.[5] The surgeon should try to reach a middle path regarding the hairline design, before going ahead with the procedure.

Anterior hairline should always be constructed keeping in mind two zones: (1) transition zone (TZ) and (2) the defined zone (DZ) (Figs. 4.15 and 4.16).

JAYPEE BROTHERS



Figure 4.15

The image depicts the angle of the needle while slit making.



Figure 4.16

Red arrow: Defined zone area with more densely packed grafts. *Green arrow:* Transition zone area with 1–2 hair follicle grafts. *Black arrow:* Irregular anterior border showing microirregularities.

JAYPEE BROTHERS

Transition zone (TZ): Most anterior area of frontal line (anterior 0.5–1 cm area of the scalp), where density of hair is less and consist of irregularities. Density of hair should be sparse here. It should be initially irregular and ill-defined and then become more defined as it progresses to the defined zone (DZ). Single follicle hair graft should be planted in the initial 0.5 cm, to give the hairline a softer look. This should be followed by 2 follicles hair graft posteriorly. These hair should be placed in a zigzag pattern, to give it a natural look and not in a straight line.

Microirregularities: Tiny irregularities are usually made in the transition zone comprising of small triangular clusters of single graft hair follicles. These irregularities are known as microirregularities and can be made out only on close observation.

Macroirregularities: The anterior hairline is not a straight line but a curvaceous one. These curves can be made out from a distance and are known as macro-irregularities.

Defined zone (DZ): Defined zone area just behind the TZ, where density of hair increases. The hair in this area should look more dense, fuller and defined. Two-follicle and 3-follicle hair grafts should be planted in this area. The angle of the hair should be 30–40° to the scalp. The direction of frontal hair should usually point forward. As you move posteriorly, the angle should be increased to 40–50°.

Frontotemporal hairline: A mild recession in the FTA should be maintained in males to give a natural look. However, females are an exception where the recession should not be present. The hair are grafted similarly as in TZ and DZ. The angle should be 10–20°, and the direction of hair should be pointing inferiorly towards ear.

RECIPIENT SITE CREATION IN HAIRLINE

Creating hairline zone is an art, which should be mastered if one wants to be a successful hair transplant surgeon. The doctor should improve his hairline design after seeing every result of his previous transplants. He has to compete with himself to find flaws in his previous hairline to keep improving in giving excellent results. The art and science of slit creation after drawing the hairline has equally important role in giving fabulous hairlines in patients. There are some basic guidelines, which should be followed.

- All recipient sites should be aimed forward in a parallel or slightly converging pattern.[5]

JAYPEE BROTHERS