ebsite www.jaypeebrothers.com, for detailed information on dermatology books, visit our website www.jaypeebrothers.com

Celebrating 50 YEARS
Passion, Quality and Innovation in Healthcare Publishing

The Sensitive Skin

Treatment Modalities and Cosmeceuticals

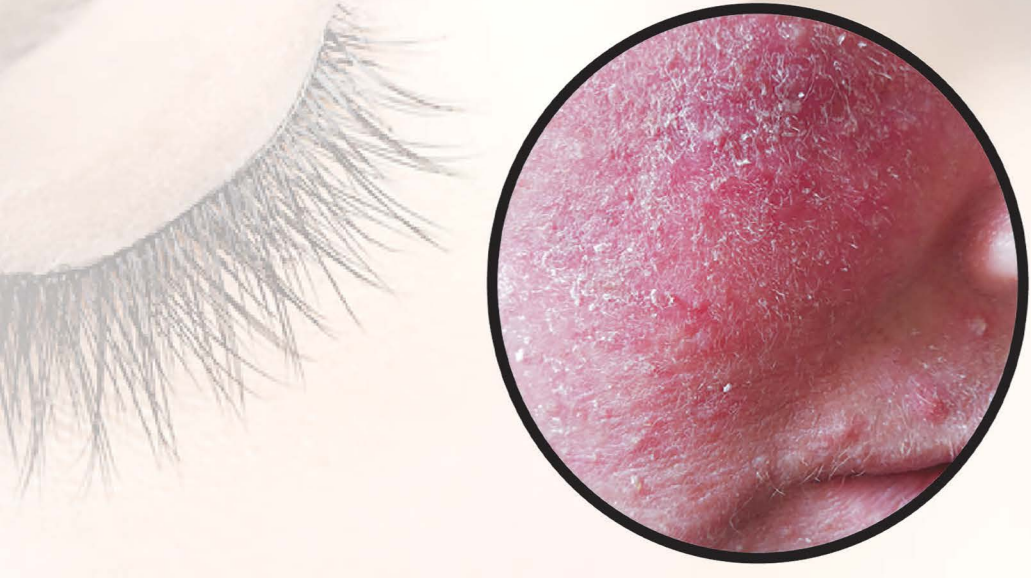

Editors
Rashmi Sarkar
Surabhi Sinha

JAYPEE

CONTENTS

1. **What is Sensitive Skin?** 1
   Surabhi Sinha, Rashmi Sarkar

2. **Sensitive Skin Care: General Measures—Do's and Don'ts** 14
   Neha Meena, Surabhi Sinha, Rashmi Sarkar

3. **Skin Care of Acne Vulgaris in Sensitive Skin** 19
   Divya Arora, Shilpa Garg

4. **Skin Care in Sensitive Skin of Rosacea** 31
   Karen Koch, Ncoza C Dlova

5. **Topical Steroid Damaged/Dependent Face** 39
   Yasmeen J Bhat, Safia Bashir

6. **Skin Care in Dermatitis and Psoriasis in Patients with Sensitive Skin** 49
   Ambika Damodaran, Trilokraj Tejasvi

7. **Cosmetic Intolerance Syndrome** 57
   Surabhi Sinha

8. **Dermatological Products for Sensitive Skin: Practice Tips** 61
   Surabhi Sinha, Sidharth Tandon

9. **Care of Sensitive Skin in Newborns** 69
   Indrashis Podder, Rashmi Sarkar

10. **Skin Care of Aged Skin** 78
    Indrashis Podder, Rashmi Sarkar

11. **Cosmetics for Sensitive Skin: Practical Tips** 82
    Minal Patwardhan, Akreti S Sobti

12. **Dermatological Procedures in Sensitive Skin** 89
    Azin Ayatollahi, Alireza Firooz

13. Skin Care Products for Sensitive Skin: Soaps, Cleansers, and Shampoos **97**
Soumya Jagadeesan, Minu L Mathew

14. Moisturizers in Sensitive Skin **104**
Surabhi Sinha

Index ***113***

4

CHAPTER

Skin Care in Sensitive Skin of Rosacea

Karen Koch, Ncoza Dlova

INTRODUCTION

Rosacea is a common chronic inflammatory disorder affecting the face and eyes. It presents with a wide range of symptoms including erythema, telangiectasia, pustules, rhinophyma, and ocular irritation.

PATHOGENESIS

The exact pathogenesis is not clear and different subtypes of rosacea may have specific factors:

- Neurovascular dysregulation: Vasodilation leading to easy flushing and persistent erythema is easily triggered in rosacea. Abnormal receptors and vasoactive peptides are some of the proposed mechanisms[1]
- Ultraviolet (UV) light and heat: The role of UV light in rosacea is controversial. UV exposure may aggravate erythrotelangiectatic rosacea but not necessarily other subtypes[2]
- Immune dysregulation: Abnormal activation of antimicrobial peptide cathelicidin via toll-like receptors leads to an inflammatory cascade. Enzymes such as matrix metalloproteinases are found in increased concentrations in rosacea. They are thought to lead to chronic inflammation, hardening, and thickening of the skin[2,3]
- Microorganisms: Hypersensivity to *Demodex folliculorum* mite is a known trigger for rosacea.[2] Other possible microbial organisms associated with rosacea include *Bacillus olenorium* (a bacteria

JAYPEE BROTHERS

found within the *Demodex* mite), *Helicobacter pyloria*, and *Staphylococcus epidermidis*[4]

- Genetic predisposition: Family members have an increased risk of rosacea but the exact genetic basis has not been established.[5]

EPIDEMIOLOGY

The exact prevalence of rosacea is unknown but it is estimated to affect from 1–22% in fair-skinned individuals.[6,7] Adults over 30 are more commonly affected. Overall, women are more likely to be affected than men.[7]

CLINICAL PRESENTATION

The clinical presentation of rosacea is varied. Onset is usually over the age of 3.[7] Frequent or easy flushing or blushing may be one of the first symptoms of rosacea. Skin is usually sensitive and tends to be easily irritated by skin products. Flushing is aggravated by spicy food, alcohol, exercise, or UV exposure.

This is followed by persistent facial redness and fine telangiectasia, typically sparing the periocular and perioral region.

Rosacea may progress to papules and pustules without comedones affecting the nose, forehead, cheeks, and chin which is characteristic of rosacea. Pustules are dome-shaped rather than pointed.

The skin may also become flaky or thickened (due to underlying edema). The nose (rhinophyma), forehead (metophyma), and chin (gnathophyma) may become thickened and enlarge due to sebaceous hyperplasia.

Ocular rosacea accompanies 40% of facial rosacea but may occur in isolation. It is characterized by blepharitis. The eyes will feel gritty with papules, sores, styes (hordeolum) and telangiectasia along the eyelid margin.

Severe edema over the whole face may occur due to lymphatic obstruction (Morbihan disease).

"Skin sensitivity" is a frequent finding in rosacea and is characterized by irritation by hot water, acidic compounds (retinoic acid, lactic acid), soaps, and chemicals. It is important that the cosmetic and skincare product formulation considerations for rosacea

JAYPEE BROTHERS

patients include cosmetic products with minimal ingredients, lack of common sensitizers, least number of irritants, and absence of skin stimulants.[8]

Proper instructions and guidance on use of proper general skin care products (such as gentle cleansers, moisturizers, sun protection, and avoidance of triggers) is prudent for all rosacea patients, to ensure optimal treatment effects.

According to Schaller et al., the following skincare advice is recommended and crucial for rosacea patients, e.g., use of sunscreen (SPF 30+), frequent use of suitable nonirritating moisturizers and use of gentle over-the-counter cleansers.[9]

CLASSIFICATION/GRADING

The National Rosacea Society Expert Committee has divided up rosacea into the following subtypes:[10]

- Type I: Erythematotelangiectatic rosacea (ETR)—facial erythema, flushing, dryness, and increased overall skin sensitivity
- Type II: Papulopustular rosacea—papules and pustules occurring over the nose, cheeks, and forehead; may also have coexisting ETR
- Type III: Phymatous rosacea—thickened skin due to sebaceous hypertrophy leading to enlargement and distortion of the nose, forehead, chin, and ears
- Type IV: Ocular rosacea—increased eye sensitivity with inflammation of the eyelid margins. This results in redness, burning, tearing, and frequent hordeolum (stye) formation. Ocular rosacea is not always associated with cutaneous rosacea.

DIAGNOSIS

The diagnosis is usually made on history and clinical appearance.

HISTOPATHOLOGY

On biopsy, dilation of superficial vessels, perivascular and perifollicular lymphocytic, and neutrophilic infiltrates may be seen. Pustules will show neutrophilic collections in hair follicles. *Demodex* mites may be seen in dilated hair follicles.[11]

JAYPEE BROTHERS

TREATMENT

General Measures for Sensitive Skin of Rosacea[9]

- Gentle skin care—avoid any harsh soaps, rubbing the skin, or enzymatic exfoliators
- Products—avoid oil-based cosmetics or facial products. Use of water-based products is advised
- Sun protection—advise use sunscreen with UVA and UVB protection (SPF ≥30). Avoid direct sun in peak hours
- Avoid irritating products—toners, astringents, alcohol-based skin products, or fragrances on the skin
- Camouflage—use face creams or powders that contain a green pigment base. This counteracts the overall redness of the skin. This is effective for both men and women
- Avoid triggers—avoid known triggers such as overheating, hot showers, steam rooms, spicy food, and alcohol should be avoided. Patients may benefit from keeping a diary to accurately identify triggers
- Review medications—nicotinic acid and vasodilators may exacerbate facial flushing.

Medications

The use of topical and oral medications to treat rosacea depends on the subtype and severity of disease. Patients often have more than one subtype of rosacea requiring combinations of treatments. Oral agents should be used in conjunction with appropriate topical treatments.

The ROSacea COnsensus (ROSCO) guidelines suggest a symptom-based algorithm.[9]

Topical Treatments

- Topical brimonidine: This is an α2-adrenergic receptor antagonist used for facial redness in ETR type rosacea. It is applied once daily with onset within 30 minutes with effects lasting up to 12 hours.[4] There is a small risk of transient rebound erythema estimated to affect up to 20% of users.[12] The treatment is generally well-tolerated with few patients reporting burning, stinging, and a contact dermatitis

JAYPEE BROTHERS

- Topical oxymetazoline: This is an α1 and partial α2-adrenergic receptor antagonist approved in 2017 by the FDA for facial erythema in rosacea. The onset of effect is within 3 hours and the reduction in redness lasts up to 12 hours. Potential side effects include skin irritation, pain, and pruritus
- Topical azelaic acid: Azelaic acid has anti-inflammatory and antioxidative qualities. It is useful in the treatment of platelet-rich plasma (PRP) rosacea. The exact mechanism of action is not known but it is thought to reduce cathelicidin production. Twice daily use of azelaic acid has been shown to be at least as effective as topical metronidazole in treating rosacea.[13] Other studies suggest no significant difference between twice and once daily application.[14] Treatment may take a few weeks to show effect[6]
- Topical metronidazole: This antibiotic and antiprotozoal medication also has anti-inflammatory and antioxidant properties.[15] It is used to treat both PRP and ETR. Different formulations (cream, gel, and foam) have shown similar efficacy.[16] Onset of effect is usually seen within 2–4 weeks. Side effects that have been reported include burning, stinging, and dryness[16]
- Ivermectin 1% cream: Ivermectin is an antiparasite agent with anti-inflammatory properties. One of the mechanisms of action is its anti-*Demodex* effect on the skin. It is safe and well-tolerated. It has been shown to be effective at reducing pustular rosacea.[17] Compared to metronidazole, topical ivermectin has been shown to be more effective in treating inflammatory lesions[18]
- Other agents used in the treatment of rosacea for which there is less evidence include permethrin, clindamycin, azithromycin, benzoyl peroxide, tacrolimus, and pimecrolimus.[4]

Oral Medications

- Tetracyclines: Tetracycline, doxycycline, and minocycline are used in therapeutic and subantimicrobial doses to treat both telangiectatic and papulopustular rosacea. Tetracyclines have anti-inflammatory effects on the skin. Doxycycline in particular has been shown to be equally effective at a dose of 100 mg/day and 40 mg (slow release) per day.[19] Minocycline is less often used to the risk of adverse effects. The starting dose for doxycycline is 50–100 mg daily and for tetracycline 250–500 mg twice daily.

JAYPEE BROTHERS

Treatment needs to be continued for at least 4–12 weeks to maximize effectiveness. Tetracyclines should not be used in children under the age of 9 years

- Macrolides: Clarithromycin at a dosage of 250 mg twice daily for one month followed by 250 mg daily for a month showed similar efficacy to doxycycline and may be a useful alternative for patients who cannot tolerate tetracyclines[20]
- Isotretinoin: Isotretinoin is a vitamin A derivative retinoid with anti-inflammatory properties. It effectively reduces the size of enlarged sebaceous glands and decreases sebum production. It is particularly useful for resistant papulopustular type rosacea and inflammatory phase rhinophyma. It can be associated with significant side effects. Most notably it is highly teratogenic. Fertile female patients are advised to use two forms of contraceptive throughout its use and one month after stopping treatment. Baselines screening for pregnancy, liver function, and triglycerides should be done. The recommended dosage to treat rosacea is 0.3 mg/kg/day for at least 3 months.[21]

Light and Laser Therapy

Treatment with light-based is particularly used to target erythema and telangiectasia. During treatment, energy is absorbed by hemoglobin within vessels leading to coagulation. Commonly used forms of laser include: Intense-pulsed-light (500–1,200 nm), potassium titanyl phosphate (KTP, 532 nm) and pulsed dye laser (585–595 nm).[22,23] Treatment may be effective but do not cure the condition. Retreatment is generally required.[24]

Cosmeceuticals

There is an increased interest in natural ingredients to reduce irritation and inflammation of rosacea. Some of these ingredients include licorice, chamomile, turmeric, niacinamide, teas, colloidal oatmeal, quassia amara extract and eperua falcata bark extract.[4,25]

CONCLUSION

Rosacea is a common multifactorial skin condition that primarily affects women over the age of 30 years. Localised persistent facial flushing, papulopustules and general skin sensitivity often leads to

JAYPEE BROTHERS

social embarrassment. Overall skin sensitivity means that commonly used skin care products can aggravate the condition. Education, avoidance of triggers, cosmetic camouflage and apporpriate medical treatments can greatly enhance the quality of life of patients with rosacea.

REFERENCES

1. Aubdool AA, Brain SD. Neurovascular aspects of skin neurogenic inflammation. J Investig Dermatol Symp Proc. 2011;15(1):33-9.
2. Crawford GH, Pelle MT, James WD. Rosacea: I. Etiology, pathogenesis, and subtype classification. J Am Acad Dermatol. 2004;51(3):327-41.
3. Yamasaki K, Gallo RL. The molecular pathology of rosacea. J Dermatol Sci. 2009;55(2):77-81.
4. Weinkle AP, Doktor V, Emer J. Update on the Management of Rosacea. Plast Surg Nurs. 2015;35(4):184-202.
5. Abram K, Silm H, Maaroos HI, Oona M. Risk factors associated with rosacea. J Eur Acad Dermatol Venereol. 2010;24(5):565-71.
6. Elewski BE, Draelos Z, Dreno B, et al. Rosacea - global diversity and optimized outcome: proposed international consensus from the Rosacea International Expert Group. J Eur Acad Dermatol Venereol. 2011;25(2):188-200.
7. Tan J, Berg M. Rosacea: current state of epidemiology. J Am Acad Dermatol. 2013;69(6 Suppl 1):S27-35.
8. Draelos ZD. Sensitive skin: perceptions, evaluation, and treatment. Am J Contact Dermat. 1997;8(2):67-78.
9. Schaller M, Almeida LM, Bewley A, et al. Rosacea treatment update: recommendations from the global ROSacea COnsensus (ROSCO) panel. Br J Dermatol. 2017;176(2):465-71.
10. Wilkin J, Dahl M, Detmar M, et al. Standard classification of rosacea: Report of the National Rosacea Society Expert Committee on the Classification and Staging of Rosacea. J Am Acad Dermatol. 2002;46(4):584-7.
11. Marks R, Harcourt-Webster JN. Histopathology of rosacea. Arch Dermatol. 1969;100(6):683-91.
12. Docherty JR, Steinhoff M, Lorton D, et al. Multidisciplinary Consideration of Potential Pathophysiologic Mechanisms of Paradoxical Erythema with Topical Brimonidine Therapy. Adv Ther. 2016;33(11):1885-95.
13. Elewski BE, Fleischer AB Jr, Pariser DM. A comparison of 15% azelaic acid gel and 0.75% metronidazole gel in the topical treatment of papulopustular rosacea: results of a randomized trial. Arch Dermatol. 2003;139(11):1444-50.
14. Thiboutot DM, Fleischer AB Jr, Del Rosso JQ, et al. Azelaic acid 15% gel once daily versus twice daily in papulopustular rosacea. J Drugs Dermatol. 2008;7(6):541-6.
15. Miyachi Y. Potential antioxidant mechanism of action for metronidazole: implications for rosacea management. Adv Ther. 2001;18(6):237-43.

JAYPEE BROTHERS

16. Wolf JE Jr, Del Rosso JQ. The CLEAR trial: results of a large community-based study of metronidazole gel in rosacea. Cutis. 2007;79(1):73-80.
17. Stein L, Kircik L, Fowler J, et al. Efficacy and safety of ivermectin 1% cream in treatment of papulopustular rosacea: results of two randomized, double-blind, vehicle-controlled pivotal studies. J Drugs Dermatol. 2014;13(3):316-23.
18. Taieb A, Ortonne JP, Ruzicka T, et al. Superiority of ivermectin 1% cream over metronidazole 0.75% cream in treating inflammatory lesions of rosacea: a randomized, investigator-blinded trial. Br J Dermatol. 2015;172(4):1103-10.
19. Webster GF. An open-label, community-based, 12-week assessment of the effectiveness and safety of monotherapy with doxycycline 40 mg (30-mg immediate-release and 10-mg delayed-release beads). Cutis. 2010;86(5 Suppl):7-15.
20. Torresani C, Pavesi A, Manara GC. Clarithromycin versus doxycycline in the treatment of rosacea. Int J Dermatol. 1997;36(12):942-6.
21. Sbidian E, Vicaut E, Chidiack H, et al. A Randomized-Controlled Trial of Oral Low-Dose Isotretinoin for Difficult-To-Treat Papulopustular Rosacea. J Invest Dermatol. 2016;136(6):1124-9.
22. Papageorgiou P, Clayton W, Norwood S, et al. Treatment of rosacea with intense pulsed light: significant improvement and long-lasting results. Br J Dermatol. 2008;159(3):628-32.
23. Alam M, Dover JS, Arndt KA. Treatment of facial telangiectasia with variable-pulse high-fluence pulsed-dye laser: comparison of efficacy with fluences immediately above and below the purpura threshold. Dermatol Surg. 2003;29(7):681-4.
24. Clark SM, Lanigan SW, Marks R. Laser treatment of erythema and telangiectasia associated with rosacea. Lasers Med Sci. 2002;17(1):26-33.
25. Emer J, Waldorf H, Berson D. Botanicals and anti-inflammatories: natural ingredients for rosacea. Semin Cutan Med Surg. 2011;30(3):148-55.

JAYPEE BROTHERS

for detailed information on dermatology books, visit our website **www.jaypeebrothers.com,** for detailed information on derma

The Sensitive Skin

Treatment Modalities and Cosmeceuticals

Salient Features

- A comprehensive resource that provides up-to-date content on management of every aspect of skin problems associated with sensitive skin
- This book helps in evaluation, diagnosis and treatment of commonly encountered dermatological condition in those with sensitive skin
- Detailed discussions on management of acne, rosacea, eczemas and common skin diseases in individuals with sensitive skin
- Dedicated chapters on cosmeceuticals, moisturizers, skin care products and dermatological procedures for sensitive skin
- Special emphasis on care of sensitive skin in different situations and different populations such as newborns and elderly patients
- Written by experts with enormous clinical experience from across the globe
- Invaluable resource for dermatologists, physicians and postgraduate students.

Rashmi Sarkar MD MNAMS is a Professor of Dermatology at Maulana Azad Medical College and Associated LNJP Hospital, New Delhi, India. She has done her MD (Dermatology) from PGIMER, Chandigarh, India. She is the Editor-in-Chief, Pigment International and World Clinics in Dermatology; was the Founder Editor of Asian Pigment Bulletin (APB); was Associate Editor of Journal of Cutaneous and Aesthetic Surgery (2011–14); Associate Editor, Journal of Cosmetic Dermatology; Section Editor, Indian Journal of Dermatology, Venereology, and Leprology; Editorial Board Member of Indian Journal of Pediatric Dermatology, Indian Journal of Dermatology, and internationally, International Journal of Dermatology (2014–17), International Journal of Women's Dermatology, Dermatologic Therapy, and Journal of Clinical and Aesthetic Dermatology; besides being a reviewer for 20 Journals. She has 145 publications in peer reviewed international and national journals and 60 chapters in textbooks of dermatology and pediatrics. She has edited 5 textbooks in dermatology. She is the President of Indian Association of Dermatologists, Venereologists, and Leprologists (IADVL), Delhi State Branch (2018). She was the National Honorary Secretary of IADVL (2014–15); Chief Founder and President of Pigmentary Disorders Society; and Founding President of Joint Women's Dermatologic Society-Indian Women's Dermatologic Society. She is also a recipient of several prestigious awards and honors including Maria Duran Fellowship from International Society of Dermatology (ISD), Member Making a Difference Award from American Academy of Dermatology (AAD), Career and Community Development Award from Women's Dermatologic Society, and other International Travel Awards from ISD, World Congress of Dermatology, and AAD. Dr Sarkar has been an invited speaker in many international and national conferences, including the prestigious Annual AAD Meetings since 2006.

She is Vice President of ISD; President-Elect ASPCR (2017–20); International Representative, Board of Directors in Women's Dermatologic Society (WDS) (2011–14; 2017–18); former Board of Directors in Skin of Color Society (SOCS); Co-Chair of International Mentorship Committee of ISD; and Member of International Affairs Committee of AAD.

Surabhi Sinha MD DNB MNAMS is a specialist in Dermatology at Dr. Ram Manohar Lohia Hospital and PGIMER, New Delhi. She has done her MBBS and MD from Maulana Azad Medical College, New Delhi, India. She is the proud recipient of Dr V N Sehgal gold medal and Dr A S Thambiah gold medal in MD and DNB respectively. She is Assistant Editor at Pigment International, the official journal of the Pigmentary Disorders Society of India. She is also a reviewer for 5 journals. She is currently Joint Secretary IADVL Delhi State Branch 2018. She is also the Treasurer for Pigmentary Disorders Society. She has been the proud recipient of the International Travel Grant from Women's Dermatologic Society. She has authored over 25 publications in national and international journals and has also contributed chapters to Dermatology textbooks.

Available at all medical bookstores
or buy online at www.jaypeebrothers.com



JAYPEE BROTHERS
Medical Publishers (P) Ltd.
www.jaypeebrothers.com

Join us on facebook.com/JaypeeMedicalPublishers

Shelving Recommendation
DERMATOLOGY

