thers.com, for detailed information on ophthalmology books, visit our website www.jaypeebrothers.com, for detailed information on ophthalmology book

Celebrating 50 Years
Passion, Quality and Innovation in Healthcare Publishing

Basic Measurements in Ophthalmology



J Antony

JAYPEE

Contents

1. General Configuration and Gross Measurements of Eye **1**
- Eyeball 1
- Summary of general measurements of eyeball 4

2. Measurements of Conjunctiva **6**
- Structure 6
- Portions of conjunctiva 7
- Conjunctival sac 8
- Attachments of bulbar conjunctiva 9
- Fornix-based conjunctival flap 9
- Goblet cells 10
- Conjunctival impression cytology 11
- Summary of measurements and dimensions of conjunctiva 12

3. Measurements of Sclera **14**
- Scleral dimensions 14
- Structure of sclera 15
- Insertion of extraocular muscles 16
- Scleral apertures 16
- Weak areas of sclera 20
- Scleral rigidity 20
- Ocular rigidity and applanation tonometry 24
- Functions of sclera 24
- Summary of measurements of sclera 24

4. Measurements of Cornea **26**
- Structure of cornea 26
- Endothelium 30
- Thickness of layers of cornea 32
- Corneal innervation 32
- Surface area of cornea 32
- Corneal diameter 32
- Microcornea 33
- Megalocornea 33
- Shape and curvature of cornea 35
- Normal variations of corneal curvature 35
- Measurement of corneal curvature and shape (Topography) 37
- Computerized corneal topography (Videokeratography) 39
- Refractive power 41
- Refractive index 41
- Corneal thickness 41
- Summary of measurements of cornea 44

5. Measurements of Limbus **46**
- Limit (extend) of limbus 46
- Structure of limbus (layer by layer changes) 47
- Functions and importance of limbus 47
- Vulnerability limbus to diseases (medial limbus) 48
- Diseases particularly affecting limbus and adjacent regions 48
- Dimensions of limbus 49
- Landmarks of limbus 49
- Zones of limbus 50
- Surgical anatomy and dimensions of limbus 51
- Cyclodestructive procedures 55
- Cataract surgery and limbus 56
- Postlimbal—scleral incision 58

6. Measurements of Anterior Chamber **62**
- Boundaries of anterior chamber 62
- Dimensions of AC and its normal variations 63
- Summary of measurements of anterior chamber 63
- Angle of anterior chamber 63
- Trabecular meshwork 64
- Aqueous humor 67
- Intraocular pressure 69
- Glaucoma 70
- Tonometry 71
- Tonography 75

7. Measurements of Posterior Chamber **81**
- Parts of posterior chamber 81
- Boundaries of posterior chamber (summary) 83
- Functions of posterior chamber 83
- Dimensions of posterior chamber 84

8. Measurements of Uveal Tract **85**
- Iris 85
- Pupil 89
- Ciliary body 91
- Choroid 96

9. Measurements of Lens **99**
- Dimensions of lens 99
- Structure and surgical anatomy of lens 102
- Summary of dimensions of lens 107

10. Measurements of Zonules (of Zinn) **109**
- Dimensions and extent of zonules 109
- Parts of zonules 110
- Zonular bundles 110
- Functions of zonules 111
- Summary of dimensions and extent of zonules 111

11. Measurements of Vitreous Humor **112**
- Structure of vitreous 112
- Primary, secondary and tertiary vitreous 113
- Vitreous topography 114
- Vitrectomy measurements 118

12. Measurements of Retina **126**
- General structure (architecture) of retina 127
- Summary of measurement of retinal layers 131
- Gross measurements and general features of retina 132
- Clinical and functional differentiations and measurements of optic disk, macula and peripheral retina 135
- Methods of evaluation of different portions of retina particularly the retinal nerve fiber layer 146
- Summary of measurements of retina 151

13. Measurements of Optic Nerve **152**
- Differences of optic nerve from other cranial nerves 152
- Structure and dimensions of various portions of optic nerve 153
- Variations in the arrangement of fibers in the distal and proximal portions of optic nerve 156
- In the proximal portion (chiasmal) of optic nerve 157
- Functions of optic nerve 158
- Summary of measurements of optic nerve 159

14. Measurements of Optic Chiasma **160**
- Dimensions of optic chiasma 161
- Position of optic chiasma in the cranial cavity 161
- Relations of optic chiasma 162
- Measurements of sella 165
- Variations in the relationship of optic chiasma to sella turcica and pituitary gland 165
- Arrangement of fibers in optic chiasma 167
- Common lesions affecting optic chiasma 168
- Visual field defects in chiasmal lesions 168
- Clues for clinical suspicion of chiasmal lesions 171

15. Measurements of Eyebrows **172**
- Dimensions of eyebrows 172
- Layers or structure of eyebrows 173
- Functions of eyebrows 174
- Clinical situations involving eyebrows 174

16. Measurements of Eyelids **178**
- Gross measurements of upper lid 178
- Structure of upper lid 178
- Palpebral fissure 186
- Relative levels of medial and lateral canthi 187

- Measurements of ptosis 189
- Measurements of lower lid 191
- Functions of eyelids 195
- Measurement of upper lid (gross) 195
- Measurements of individual eyelid structures 195

17. Measurements of Lacrimal Apparatus **197**
- Main lacrimal gland and its measurements 198
- Accessory lacrimal glands 199
- Lacrimal passages and their measurements 200
- Nasolacrimal duct 203
- Lacrimal sac surgery measurements 206

18. Measurements of Orbit **209**
- Dimension of orbits 209
- Bones and walls of orbit 211
- Orbit-eyeball relationship—normal and abnormal 213
- Walls of orbit 215
- Lateral wall of orbit 217
- Floor of orbit 219
- Medial wall of orbit 222
- Orbital apex 223
- Communications of orbit 225
- Optic canal 225
- Superior orbital fissure 227
- Inferior orbital fissure 228
- General configuration and surface marking of recti muscle insertions 232
- Dimensions of extraocular muscles 235
- Angle or meridian of insertion of extraocular muscles 236
- Visual axis, optic axis, center of rotation of eyeball, orbital planes and orbital axis 236
- Center of rotation of eyeball 238
- General principles and measurements in surgical correction of squints 239

Suggested Readings *243*

Index *245*

CHAPTER 4

Measurements of Cornea

Cornea constitutes the anterior 1/6th of outer ocular wall. It is the only transparent window through which light enters the eye. Cornea is a visually vital structure as it transmits about 99% of incident light and contributes about 65% (+40 Diopters) of refractive power (Total + 6OD) to the eye. The average diameter cornea is about 11–12 mm, thickness is 0.5–1 mm, radius of curvature is 6.5–8 mm and surface area is 1.3 cm^2 (Fig. 1).

STRUCTURE OF CORNEA (FIG. 2)

Cornea has a precise architectural structural arrangement of following layers culminating in its unique function of transparency and light transmission.

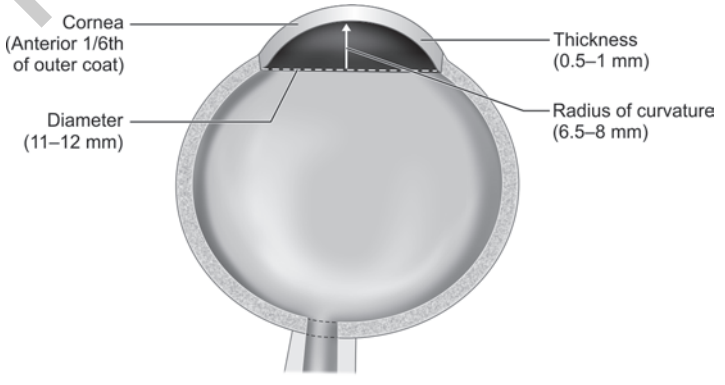

Fig. 1: Dimensions of cornea.

JAYPEE BROTHERS

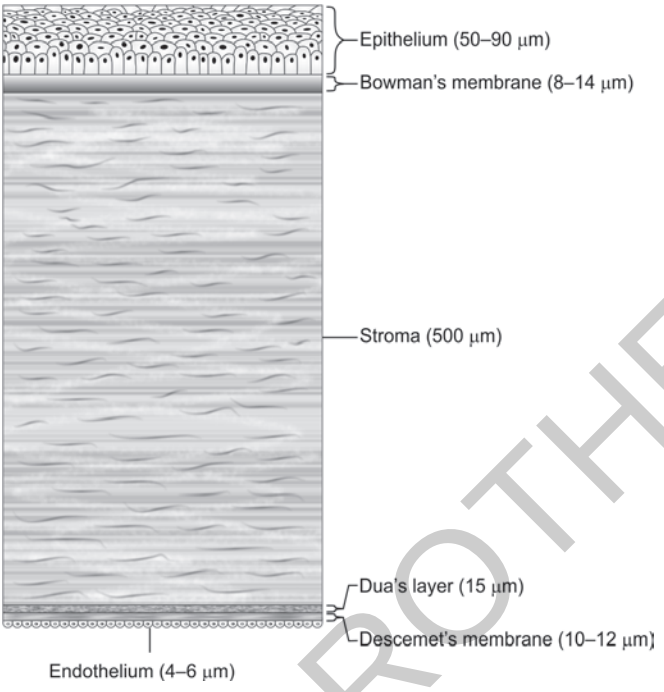

Fig. 2: Structure (layers) of cornea.

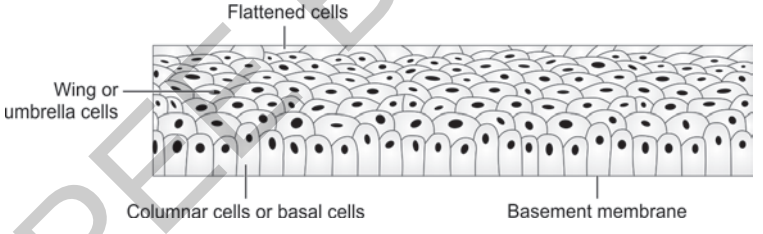

Fig. 3: Corneal epithelium.

Epithelium (Fig. 3)

Epithelium, the anterior layer of cornea is a *50–90 μm thick stratified, non-keratinized non-secretory squamous epithelium. It makes about 5% (0.05 mm) of total thickness of cornea.* It is made of 3 types of cells—flattened cells, wing or umbrella cells and columnar or basal cells arranged in *five to seven layers.* The lower most single layer of basal cells have mitosis and adheres to a basement membrane. The primary **function** of epithelium is:

- It forms a very *strong refractive surface*
- The extraordinary *dense sensory nerve* plexus induces rapid response to touch and injuries
- It form a *barrier to invasion of eye by pathogens*
- Prevent the uptake of excess of *fluid* by stroma.

JAYPEE BROTHERS

Basement Membrane or Basal Lamina

Basement membrane or basal lamina of epithelium is 40 to 60 nm thick, contains type IV collagen, laminin proteoglycan and fibrin. Epithelium attaches to this basement membrane and Bowman' layer by hemidesmosomes and type VII collagen fibrils called anchoring fibrils. The anchoring fibrils penetrate as deeply as 2 μm into stroma ending in structures called anchoring plaques. This adhesion is complete and is destroyed in photorefractive keratectomy and must be reassembled during the healing process. *Following corneal injury (abrasion), though, epithelialization and hemidesmosome formation can occur as early as 18 hours, anchoring fibrils form only after many days and full structural integrity is achieved only after many months. This may be the reason for recurrent erosions following injury of cornea by sharp objects.*

Bowman's Membrane

Bowman's membrane is an acellular narrow *homogenous 8–14 μm thick membrane* underlying the epithelium. It consists of a felted meshwork of fine collagen fibrils of uniform size lying in a ground substance. *The diameter of fibrils is about 24–27 nm and it less than that of corneal stroma.* The compact arrangement of collagen fibers confers great strength to this zone. Thus, it is relatively resistant to trauma (mechanical) and infection. Once destroyed it is not reformed but is replaced by scar tissue. It is perforated in many places by unmyelinated nerves proceeding to epithelium. It is considered as condensation and barrier of superficial stroma.

Function of Bowman's membrane are:

- It may be functioning as a smooth, rigid base for maintaining epithelial uniformity for refraction.
- It prevents the close contact between stromal and epithelial cells which might induce stromal activation.

Stroma (Substantia Propria) (Fig. 4)

Stroma is 500 μm thick. The stromal portion of cornea mainly contributes to the structure and optical properties of cornea and *makes up to 90% of its thickness.* Stroma is made of regularly arranged *bundles of fibers of 200–300 numbers centrally and 500 peripherally.* These vary in width between 9 and 260 nm and 1.5 and 2 nm in height. Lamellae are arranged in layers parallel with each other and with corneal surfaces. They stretch from limbus to limbus. *At limbus they*

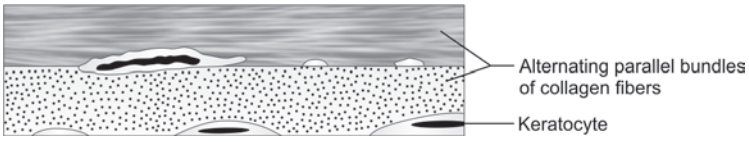

Fig. 4: Parallel arrangement of bundles of fibers in alternating lamellae in corneal stroma.

JAYPEE BROTHERS

run circumferentially forming an annulus of 1.5–2 mm wide around the cornea. It is this annulus that maintains the curvature of cornea.

Union between neighboring bands slightly hinders separation of cornea into lamellae, anteriorly than posteriorly. *So, lamellar separation is readily achieved* by blunt dissection and is the basis for lamellar corneal grafting.

In deeper stroma, the lamellae form strap like ribbons which run approximately at right angles to those in consecutive layers. *Functions of stroma* are:

- Maintains transparency and allows passage of light into eye
- It forms part of the rigid framework of eyeball and helps in maintaining intraocular pressure
- It contributes to alignment of optic pathway.

Dua's Layer

Dua's layer was hypothesized in 2013 by Dr Harminder Singh Dua and his colleagues at University of Nottingham as the fourth layer of cornea located between corneal stroma and Descemet's membrane. *It is about 15 micrometers (0.00059 inch) thick.* Though very thin it is strong enough to withstand a bursting pressure of 70 mm–900 mm Hg and is impervious to air.

Dua's layer is made of 5–8 thin compact lamellae of type I, IV and VI collagen fibers which traverse in longitudinal and oblique direction. Keratocytes are lacking in this layer.

This layer was first observed during deep lamellar keratoplasty (DALK) procedures and related research on donated eyes. The cleavage of this layer from stroma could be accomplished for about 8.5–9 mm diameter area from center of cornea and there after it is firmly adherent to stromal bed to periphery but not up to Schwalbe line.

More studies about this layer in future will help in understanding more about the diseases of cornea like keratoconus, descemetocele, pre-Descemet's dystrophies, etc. and will improve the outcome of lamellar keratoplasties.

Descemet's Membrane (Fig. 5)

Descemet's membrane (DM), the basal lamina of endothelium is *about 10–12 μm thick in adult and binds to stroma posteriorly and is the plane of separation usually used in lamellar keratoplasty.* Though appear homogenous, it has a laminated structure, *anterior 1/3rd having a vertically banded pattern and posterior 2/3rd appearing amorphous and granular.* Termination of Descemet's membrane at the corneal periphery (internal landmark of corneal limbus) appears Gonioscopically as a glistening line called Schwalbe's line to which the apex of trabecular meshwork is attached. It is prominent in 15–20% of individuals and hypertrophied in congenital anomalies; then it may appear as a visible shelf on gonioscopy—posterior embryotoxon.

JAYPEE BROTHERS



Fig. 5: Dua's layer, Descemet's membrane and endothelium.



Fig. 6: Specular microscope.

ENDOTHELIUM

Endothelium is a *monolayer of about 500000 hexagonal cuboid cells attached to the posterior surface of Descemet's membrane.*

The corneal endothelium can be studied on the slit lamp by specular reflection under high magnification and also by specular microscopy (Fig. 6). Normal endothelial cells are approximately *20 μm in diameter and 4–6 μm thick.* These cells contain numerous mitochondria, prominent cytoplasmic reticulum and Golgi apparatus. The endothelial cells are metabolically active in *transport, synthesis and secretory activities.* Endothelial cells are interconnected by tight junctions and gap junctions (macula occludens). This makes the endothelium a "leaky barrier" by permitting paracellular diffusion of aqueous humor into cornea but preventing bulk fluid flow between aqueous humor and stroma. *Endothelium plays a major role in maintaining corneal transparency by regulating corneal hydration.*

Specular microscopic studies show that average endothelial cells population is around 2500–5000 cells/mm^2 in adult (Fig. 7).

At birth the endothelial cell density is about 6000/mm^2 and falls by about 26% in first year. A further 26% is lost over the next 11 years but rate of loss possibly stabilizes around middle age. At birth cells are 10 mm in height, but become extremely flat (3–5 mm) with age.

Normally, there is a 0.6% decrease in cell density per year in typical patients with no history of corneal disease or surgery.

Minimum level of endothelial cell density required for maintenance of normal corneal function and transparency is about 400–700 cells per mm^2.

JAYPEE BROTHERS



Fig. 7: Specular micrograph of endothelium.

The *degree of uniformity of cell* size is determined by measuring the areas the apical membranes of a population of cells and calculating the *coefficient of variation (CV) of cell size (standard deviation (SD) of mean cell area/mean cell area).* The normal endothelium has a CV of about 0.25. An increase in this value indicates a variation of cell size, known as polymegathism. This may be *indicative of a stressed or unstable endothelium in which cell volume is not adequately regulated.*

Endothelial cell density and size variations in various clinical conditions.

- **Contact lens wear:** Polymegathism of corneal endothelial cells have been reported following long-term use of rigid PMMA *contact lenses* and daily wear extended wear CLs. Contact lens induced hypoxia may be the cause.
- **Glaucoma:** In glaucoma patients with elevated IOP, there is a *significant decrease* in *endothelial* cell density.
- **Diabetes mellitus:** In type 2 diabetes patients (more than 10 years duration) *CV is increased and the percentage of hexagonal cells decreases to 50%.* These changes are related to changes in cell metabolism.
- **Keratoconus:** Keratoconus patients have normal cell density but *percentage of hexagonal cells drops from normal to 50% showing stress.*
- **Keratoplasty:** Penetrating keratoplasty (PK)patients showed endothelial cell loss rate of *7.8% per year from 3–5 years after PK,* on long-term follow-up of clear grafts.
- **Cataract surgery:** Endothelial cell loss following *phacoemulsification* with 10 L implantation using peribulbar block was *about 8.5% after 12 months.* Using intracameral 1% preservative free lidocaine for anesthesia, the mean

JAYPEE BROTHERS

decrease in cell density was 5.5% after 1 month. CV increased 12.5% and hexagonality decreased 4.7%.

- **LASIK:** Following LASIK for correction of 2.25 to 14.5D of myopia, there was *no significant effect* on endothelial cell density or the percentage of hexagonal cells 3 years after surgery. A residual corneal thickness of 200 μm of stroma above corneal endothelium after refractive should be left unablated to protect the corneal endothelial structure and barrier function.

THICKNESS OF LAYERS OF CORNEA

1.	Epithelium	:	50–90 μm
2.	Bowman's membrane	:	8–14 μm
3.	Stroma	:	500 μm
4.	Dua's layer	:	15 μm
5.	Descemet's membrane	:	10–12 μm
6.	Endothelium	:	4–6 μm

CORNEAL INNERVATION

Cornea is one of the *most densely innervated of all tissues* of body. Corneal epithelium is almost highly innervated of all epithelia with approximately 300–400 *more nerve endings per unit area than epidermis.* Sensitivity of cornea is 100 times *more than conjunctiva*. The nerves supplying the cornea are mostly sensory nerve fibers from *long ciliary* nerves arising from ophthalmic division of trigeminal nerve. The long ciliary nerve enters the cornea from perichoroidal space a short distance posterior to limbus. Here they form an annular plexus. About 1mm outside limbus they lose their perineurium and myelin sheaths (which contribute to corneal transparency). Branches then pass forwards in a radial fashion to enter stroma.

After crossing Bowman's membrane and epithelial basement membrane (maintaining Schwann cell sheath) the bundles again turn 90° and run parallel to the base of epithelium. These bundles are called leashes.

At this point of crossing the epithelial basement membrane, Schwann sheath is lost. Beaded nerves of leashes pass between epithelial cells terminating in outer squamous cells to form an intraepithelial plexus. There is no specialized nerve endings and axons are naked and devoid of Schwann sheath.

SURFACE AREA OF CORNEA

The area of anterior surface of cornea is about 1.3 cm^2 (one-sixth of surface area of globe).

CORNEAL DIAMETER (FIGS. 8 AND 9)

Anterior surface of cornea appear slightly oval horizontally because of the greater overlap of sclera and conjunctiva above and below than laterally. *Thus, the*

JAYPEE BROTHERS

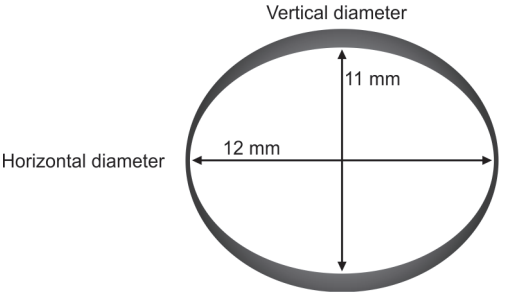

Fig. 8: Diameter of anterior surface of cornea.

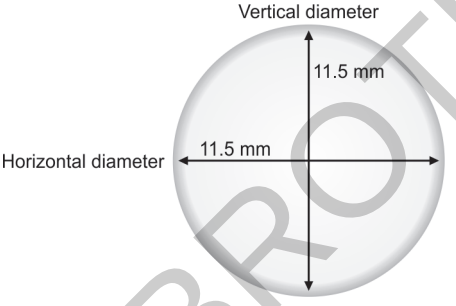

Fig. 9: Diameter of posterior surface of cornea.

diameter of anterior surface of normal adult cornea is about 11 mm vertically and 12.6 mm horizontally.

Posterior surface of cornea is circular. So, the vertical and horizontal diameter of posterior surface are 11.5 mm. Cornea is 1 mm wider in males than females.

Measurement of corneal diameter with a caliper is important in the diagnosis and management of conditions like buphthalmos, microcornea and megalocornea, etc. Cornea reaches its adult size by 2 years of age.

MICROCORNEA (FIG. 10)

In microcornea *adult horizontal diameter is less than 11mm.* It can occur as a true (isolated) condition (rest of globe normal) or associated with other ocular anomalies as in Ehlers-Danlos syndrome, intrauterine rubella, toxoplasmosis and trisomy 13, etc.

MEGALOCORNEA

Megalocornea is primarily an *enlarged diameter of cornea more than 13 mm in horizontal diameter in absence of increased intraocular pressure.* This is a rare condition caused by bilaterally symmetric corneal enlargement.

JAYPEE BROTHERS

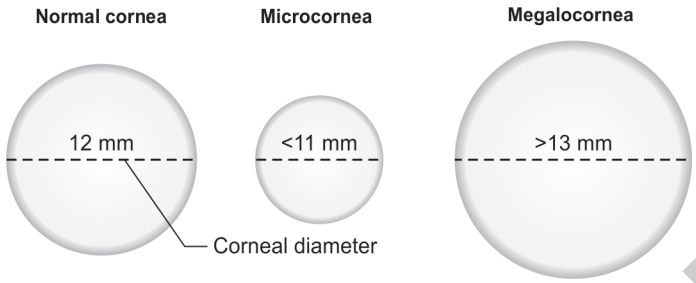

Fig. 10: Corneal diameter variation of microcornea and megalocornea from normal.

Normal horizontal diameter of cornea of newborn is about 10 mm. If the diameter is 12 mm or more in a neonate or 13 mm or more in adult megalocornea is present. Megalocornea can occur as:

- **Simple megalocornea**, not associated with any other ocular anomalies
- **In megalocornea of megalophthalmos** (X-linked) there are iris and angle anomalies and also early subluxation and cataract formation of lens.

Keratoglobus and Corneal Diameter

In keratoglobus there is generalized thinning of stroma resulting in a spherical protuberance but corneal diameter is normal.

Corneal Diameter and Intraocular Pressure

At birth the normal horizontal corneal diameter is between 9.5 to 10.5 mm. It enlarges about 0.5 mm in first year of life. Distension of the globe in response to increased IOP (Buphthalmos) leads to enlargement of cornea especially near the corneoscleral junction. *Thus corneal diameter larger than 12 mm in first year is suspicious. When the corneal diameter becomes 13 mm or more it strongly suggests abnormalities, like childhood glaucoma or buphthalmos.* (Figs. 11 and 12). Corneal diameter may be a more reliable guide than axial length in assessment of congenital glaucoma. A surgical interference in buphthalmos earlier than 13.5 mm corneal diameter can give good visual results (Table 1).



Fig. 11: Enlarged corneal diameter in buphthalmic right eye.

JAYPEE BROTHERS

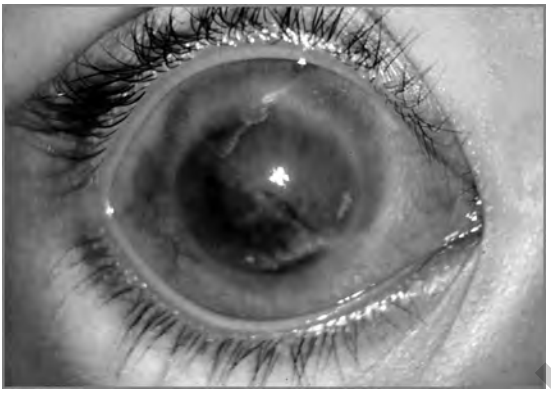

Fig. 12: Congenital glaucoma (buphthalmos) with enlarged corneal diameter and limbal stretching. (*For color version, see Plate 1*)

TABLE 1: Horizontal corneal diameter (in mm) in normal and buphthalmic eyes.

Age	*Normal*	*Possible glaucoma*
Birth to 6 months	9.5–11.5	>12 mm
1–2 years	10–12	> 12.5 mm
Older child	≤12	>13 mm

SHAPE AND CURVATURE OF CORNEA

A study of curvature and shape of cornea using keratometer, keratoscope or corneal topographer is an essential step in diagnosis and management of corneal ectasias and conditions of corneal irregularities. They are also important in contact lens fitting, pre and postoperative assessment of cataract surgery, keratoplasty and refractive surgeries.

Average radius of curvature of anterior surface of cornea ranges from 7.2 mm to 8.4 mm (mean 7.8 mm) and radius of curvature of posterior surface is 6.5 mm in adult male (Fig. 13).

NORMAL VARIATIONS OF CORNEAL CURVATURE

Cornea is flatter (radius of curvature more) in infants. Cornea slightly flattens on convergence.

Anterior Corneal Astigmatism

Though normal cornea appears spherical, having same radius of curvature from limbus to limbus on slit lamp examination, *in reality it is a spherical and has different curvatures in different parts and meridians.*

Cornea is normally more curved in vertical meridian than horizontal meridian for about 0.25 D. This is direct astigmatism or astigmatism with rule (Fig. 14A).

JAYPEE BROTHERS

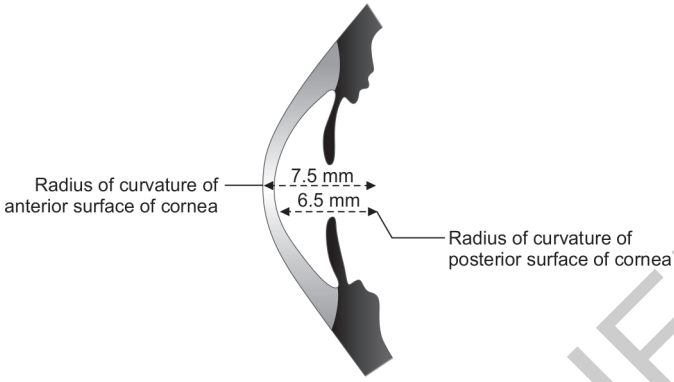

Fig. 13: Radius of curvature.

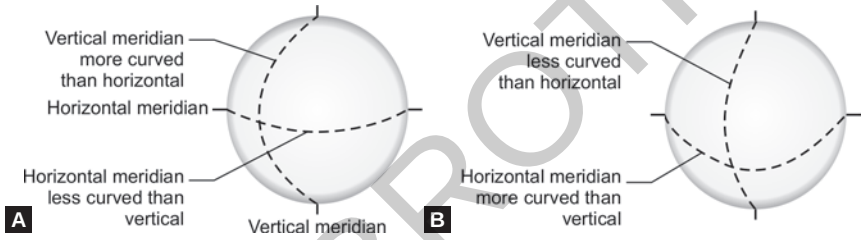

Figs. 14A and B: (A) Astigmatism with-the-rule; (B) Astigmatism against-the-rule.

As age advances or surgical or other types of scarring in upper or lower part of cornea, direct astigmatism tends to disappear or even reverses itself into an *inverse astigmatism or astigmatism against rule, with vertical curve less than horizontal (Fig. 14B).*

Posterior Corneal Astigmatism

Posterior surface of cornea also has an irregularity in its curvature ranging from 0.25 to 0.75 D with the rule (WTR) or against the rule (ATR). Posterior corneal astigmatism can be measured separately from anterior corneal astigmatism using Barrett's (more accurate) or Bayer's calculators and the measurements are useful in calculating the power and the meridian of toric intraocular lens (IOL) in cataract surgery.

Corneal Topographic Zones

Normally, the central third of cornea (2–4 mm area) is more curved than periphery—the corneal cap. This area is decentered upwards and outwards relative to visual axis but correctly centered for papillary aperture (which is less 0.4 mm temporally).

Cornea flattens peripherally, greater flattening nasal than temporal, above than below (Fig. 15).

JAYPEE BROTHERS

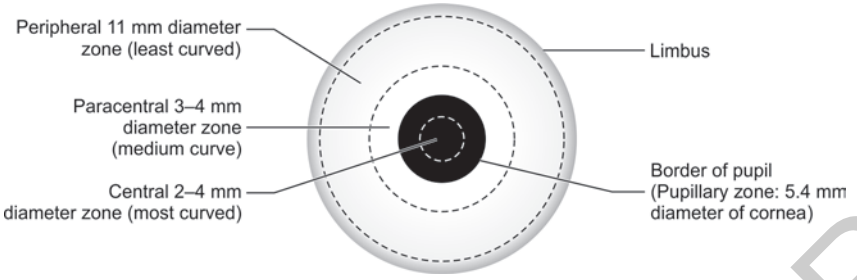

Fig. 15: Corneal topographic zones.

Clinically cornea is a spherical and has three zones with different curvatures.

- **Central zone:** Central zone is 1–2 mm which is almost spherical and steepest.
- **Paracentral zone:** A progressively flattening adjacent 3–4 mm portion with an outer diameter of 7–8 mm.

  Central and paracentral zone mainly provide the refractive power of cornea and the optical zone of cornea overlying the pupil is the central 5 mm diameter area.
- **Peripheral zone:** Adjacent to paracentral zone of 11 mm diameter has maximum flattening and asphericity. Rest of the portion near the limbus cornea steepens further before joining the sclera.

Conventional keratometry measure the shape of central 3 mm of cornea and the videokeratoscopy measure the mid peripheral and central zones (central 7–8 mm area) of cornea.

MEASUREMENT OF CORNEAL CURVATURE AND SHAPE (TOPOGRAPHY)

An accurate measurement of corneal shape is important in preoperative assessment of refractive surgery, diagnosis of corneal irregularities (ectasias, dystrophies, etc.) unexplained visual loss, etc. Topography can be obtained mainly by three methods.

Keratometry

Keratometry measures the corneal curvature and the corneal element of astigmatism. It *studies the curvature of central part of anterior surface of cornea at four points.* Keratometry is based on the physical principle; anterior surface of cornea acts as a convex mirror so that size of image reflected by it, varies with curvature. *The steeper the cornea (more curved) smaller the image and flatter (less curved) larger the image.* Four keratometric images (mires) are reflected from points of about 1.5 mm either side of corneal apex by a device which double the image by a double refracting prism, is used.

The average radius of curvature of cornea measured by a keratometer ranges from 7.2 to 8.4 mm. The shorter the radius of curvature, steeper the cornea and the more refracting power it has.

JAYPEE BROTHERS

for detailed information on ophthalmology books, visit our website www.jaypeebrothers.com, for detailed information on ophthalmology books, visit our

Basic Measurements in Ophthalmology

Salient Features

- Several academically and clinically useful measurements are described in 18 chapters systematically
- Can be used as a reference book
- Most of the measurements are described fitting to the different clinical situations
- Simple diagrams which can be easily remembered and reproduced.



J Antony MS DO is Professor and Head, Department of Ophthalmology, Sree Gokulam Medical College and Research Foundation, Thiruvananthapuram, Kerala, India. He did his graduation and postgraduation (MS) from Government Medical College, Thiruvananthapuram. He has entered the Government Medical College service and worked in several medical colleges in various capacities and retired from service as Professor from Regional Institute of Ophthalmology, Thiruvananthapuram.

He took a lot of effort in propagating the message of eye donation among public and performed a number of corneal transplantation surgeries. For his unique contribution for prevention of blindness in rural areas, he was honored by Lions Club International with the 'Knight of the Blind' award. He has published about 10 papers in Kerala Journal of Ophthalmology and conducted several coronal mass ejections (CMEs). He was the co-author of the medical book *Sarvaroga Vijnanakosham*.

Available at all medical bookstores or buy online at www.jaypeebrothers.com

JAYPEE BROTHERS
Medical Publishers (P) Ltd.
www.jaypeebrothers.com

Join us on facebook.com/JaypeeMedicalPublishers

Shelving Recommendation
OPHTHALMOLOGY

ISBN 978-93-5270-548-1