halmology books, visit our website **www.jaypeebrothers.com,** for detailed information on ophthalmology books

Celebrating 50 YEARS
Passion, Quality and Innovation in Healthcare Publishing

CLINICAL NEURO-OPHTHALMOLOGY



Editor
Ambar Chakravarty

JAYPEE

CONTENTS

1. Assessment of Visual Acuity 1
Arnab Biswas

2. Optical Cohererence Tomography In Neurological Practice 4
Pushpita Sahu

3. Ophthalmoscopy in Clinical Practice 8
Ambar Chakravarty

4. Visual Field Examination for the Neurologist 19
Ambar Chakravarty, Pushpita Sahu

5. Examination of Pupil 30
Ambar Chakravarty, Debasish Roy

6. Unexplained Visual Loss 41
Ambar Chakravarty

7. Transient Visual Loss 48
Jayanta Roy

8. Optic Neuritis 58
Debasish Roy, Ambar Chakravarty

9. Neuromyelitis Optica Spectrum Disorders 68
Debasish Roy, Ambar Chakravarty

10. Non-inflammatory Optic Neuropathies 77
Debasish Roy, Sandip Chatterjee, Ambar Chakravarty

11. Chiasmal Disorders 93
Sandip Chatterjee

12. Retrochiasmal Visual Impairments 105
KK Sinha

13. Visual Illusions and Hallucinations 117
Ambar Chakravarty

14. Nuclear and Infranuclear Ophthalmoplegias 127
Ambar Chakravarty

15. Phoria. Squint and Diplopia 153
Pushpita Sahu, Ambar Chakravarty

16. Gaze and Supranuclear Oculomotor Disorders 163
Angshuman Mukherjee, Ambar Chakravarty

17. Ocular Oscillations 187
Angshuman Mukherjee, Ambar Chakravarty

18. **Ptosis and Blepharospasm** 199
Ravindranath M Chowdhury, Sanjib Sinha

19. **Proptosis** 208
Ajitesh Das, Sudip Chatterjee

20. **Psychogenic Neuro-ophthalmological Disorders** 218
Ambar Chakravarty

21. **Idiopathic Intracranial Hypertension** 225
Barun K Sen, Arabinda Mukherjee

22. **The Eye and Headache** 246
Koushik Pan, Ambar Chakravarty

23. **Problem Oriented Neuro-Ophthalmology: Pearls and Pitfalls** 254
Koushik Pan, Ambar Chakravarty

Appendix 1: Dynamic Visual Acuity: A Simple Test for Vestibular Function 267
Arnab Biswas

Appendix 2: Strabismus Terminology 268
Pushpita Sahu, Ambar Chakravarty

Appendix 3: A Note on Ocular Motor Disorders in Multiple Sclerosis 270
Pushpita Sahu, Ambar Chakravarty

Index 275

4 CHAPTER Visual Field Examination For the Neurologist

Ambar Chakravarty, Pushpita Sahu

INTRODUCTION

Visual field is that portion of the space which is visible to an individual. Although this is perceived binocularly, the field of vision is plotted for each eye separately. Neurologists often make a major clinical distinction between "confrontation" and "formal" visual field testing. Confrontation testing usually involves fingers wiggling or various colored pins moving, and is invariably done well by a neurologist. The fundamental principle is comparing the field of the patient with that of the examinee's assuming that the examiner possesses a normal acuity and a normal visual field. Formal visual field testing involves large pieces of other people's expensive equipment and is usually done (eventually) by someone else. Although the underlying principles and anatomic correlations are essentially the same for all forms of visual field testing, the increased volume and sensitivity of the clinical information provided by formal "perimetry" makes the understanding and utilization of these techniques essential for all neuro-ophthalmic and most neurologic practitioners.

In 1947, Lloyd classified the visual fields obtained in his outpatient clinic under three broad headings:

1. Those interpretable on their own merits
2. Those that mean something to the person who took them
3. Those unintelligible to anyone.

He further stated that most of the difficulties in perimetry may be listed as follows:

- Inefficient explanation of what is required, either by the physician to the perimetrist, by the perimetrist to the patient, or both
- Uncomfortable, hungry, or frankly bored patient
- Large nose or dropping lid as causes of contraction
- Failure to watch the patient's eye to ensure proper fixation
- Moving test-object too fast or too slow
- Going on too long for the patient or the perimetrist
- Failure to give a separate explanation of what is required for the central field, particularly a demonstration of the blind spot and an assurance that this is normal where the patient shows signs of anxiety
- Failure on the part of the perimetrist to remember what he is looking for.

Despite subsequent passage of more than 50 years, and the advent first of Goldmann perimetry and then of automated perimetry, surprisingly little appears to have changed.

Critical to any attempt to produce a meaningful examination of the visual fields is the fundamental question: "Why are we doing this?" A clear goal must be defined before instituting the visual field testing. "We" is emphasized as a reminder that perimetry is always a collaborative team activity, which usually includes a patient, a nurse/technician, and an interpreting physician.

The two main indications for visual field testing in neurology are:

1. *Diagnostic:* What is the anatomical location and pathology of the lesion present?
2. *Prognostic:* Is there quantitative or qualitative change in a visual field defect that has previously been detected?

Currently, the two principal methods for formal neuro-ophthalmic visual field testing are Goldmann perimetry and automated (computerized) perimetry (e.g., Humphrey, Octopus systems). A simpler but now much less

JAYPEE BROTHERS

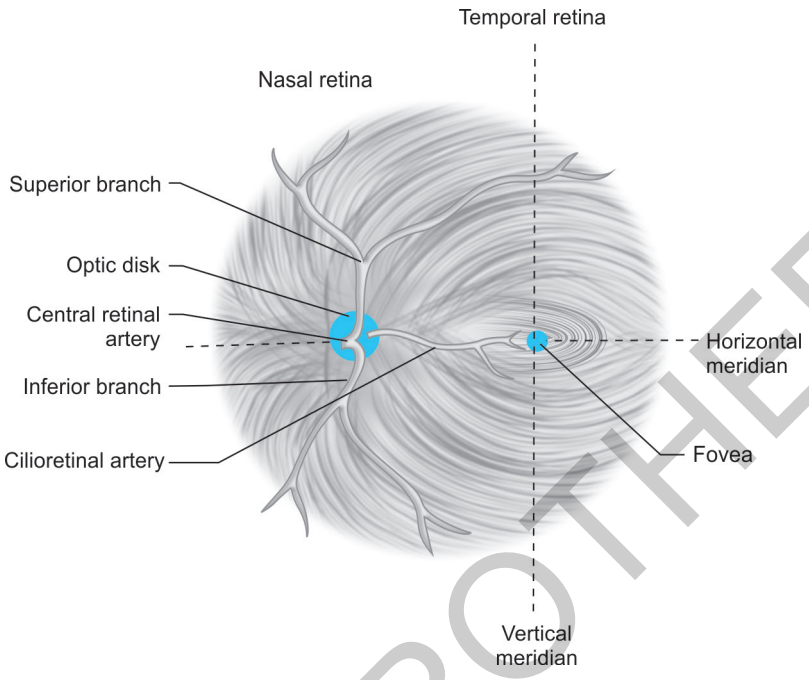

FIG. 1: Retinal nerve fiber layer and arteries. Note the arcuate distribution of temporal and nasal fibers as they coverage to the disc and the imagery horizontal and vertical meridians.

commonly used technique is the manual tangent screen (Bjerrum's). Goldmann perimetry is usually performed as a kinetic (moving target) test, while automated perimetry uses static testing. Each system has inherent advantages and disadvantages (Table 1).

However, no matter what technique is used, four sad but honest truths are likely to remain:

1. Any perimetry is a boring test for most patients
2. Intra- and intertest variation is an almost inevitable concomitant of perimetry
3. Automated perimetry is still a subjective test—just because the perimeter uses a computer, it does not alter the intelligence or capacity of the patient undergoing the test, the technician supervising the test or the physician ordering and interpreting it
4. There are still patients in whom visual field examination, by any testing method, may not be successful.

Frisén commented *"Perimetry is a demanding test for both the patient and the examiner. Both have the right to work under optimal conditions, with a minimum of distractions, and both work best if they know precisely what is expected from them. Perimetry is never performed in a vacuum, but represents one quantitative aspect of visual function testing, based on sound indications reached by careful history and detailed physician's examination. For maximum yield within a minimum time, the examination must be geared to the exact needs of the individual. However, repeated measurements with sufficiently finely graduated stimuli will nearly always give different results."*

TOPICAL DIAGNOSIS

Three golden rules to improve the interpretation of diagnostic field testing are:

1. Reject artefact
2. Respect the horizontal meridian (monocular field = retina or optic nerve)
3. Worship the vertical meridian (chiasmal/retrochiasmal)

Artefact

Artefact masquerading as meaningful neuro-ophthalmic visual field loss, comes from a number of sources including:

- Intra- or intertest fluctuation in responses

JAYPEE BROTHERS

Table 1: Perimetry systems

Goldmann Perimetry	Automated Perimetry
Advantages	
• Shorter examination time	• Increased sensitivity (especially central field)
• Easier for "difficult" or "neurological" patients ○ Fixation monitoring ○ Hands-on patient/examiner interaction ○ Rapid re-examination of artefacts	• Random presentation; avoidance of examiner bias
• Full-field examination	• Statistical data analysis possible (individual field and longitudinal comparisons)
• Rapid screening (e.g., normal; hemianopia)	• Easily operated
Disadvantages	
• Lower sensitivity (especially central field)	• Duration of testing ○ Often limits examination to central 24–30 degrees
• Interexaminer variability (e.g., target presentation, response detection)	• Poor with "difficult patients" ○ Reduced compliance ○ Increased fatigue
• Subjective examiner bias ("artistry")	• Hidden "neurological" peripheral field defects
• Difficulties with statistical analysis or longitudinal comparisons	• Poor intratest artefact detection
• Requires experienced operator	
Lesions of Choice	
• Retrochiasmal "neurological" fields	• Optic neuropathies
• Hysteria/malingering	• Chiasmal lesions
	• Assessment of change in (1) and (2)
	• Change in known retrochiasmal lesions (e.g., tumor therapy)

- Small pupil size causing peripheral field constriction
- Amblyopia, cataract or media opacity causing generalized or central field depression
- Omitting refractive correction for central 30 degree testing, causing central pseudoscotomata or depression
- Non-rimless refractive correction or lens holder poorly located, causing ring or hemi-ring scotomata
- Aphakia: Corrective lens causing ring scotomata or no correction causing erratic central responses
- Ptosis or heavy brow causing altitudinal field loss
- Inattentive, uncooperative, unreliable, or unsuitable patient producing strange or meaningless fields, especially with automated perimetry
- Hysteria or malingering causing particularly wide fluctuations in response

Horizontal Meridian

Optic Nerve or Retina

The horizontal meridian of the visual field reflects the horizontal raphe of the distribution of the optic nerve fiber layer across the retina. Visual field defects that respect the horizontal meridian are classically one of the hallmarks that help to distinguish anterior optic nerve (optic nerve head) lesions (e.g., glaucoma, anterior ischemic optic neuropathy) from retinal lesions (geographic scotoma) or macular lesions (central scotoma).

JAYPEE BROTHERS

In cases of idiopathic or demyelinating optic neuritis, the classic (diagnostic) description of the visual field loss as a "central or cecocentral scotoma with intact peripheral field" has therefore been somewhat awkward to explain theoretically. However, this description was enshrined prior to the development of automated perimetry. More recently, an interesting and repeated observation in optic neuritis and other optic neuropathies has been that static, automated perimetry may sometimes define a patchy "Swiss-cheese type" of central vision field defect, while kinetic Goldmann perimetry is relatively normal despite reduced visual acuity (statokinetic dissociation). Now automated perimetry results from the recent optic neuritis treatment trial have shown that actually a wide variety of visual field defects can occur in optic neuritis, with altitudinal defects being the most common on visual inspection of the field testing results, and statistical analysis of the visual field defects suggesting evidence for some involvement of all components of the central 30 degrees of the visual field (Table 2).

An additional note of caution regarding a central scotoma as "diagnostic" of demyelinating optic neuritis in a recent report showing that some

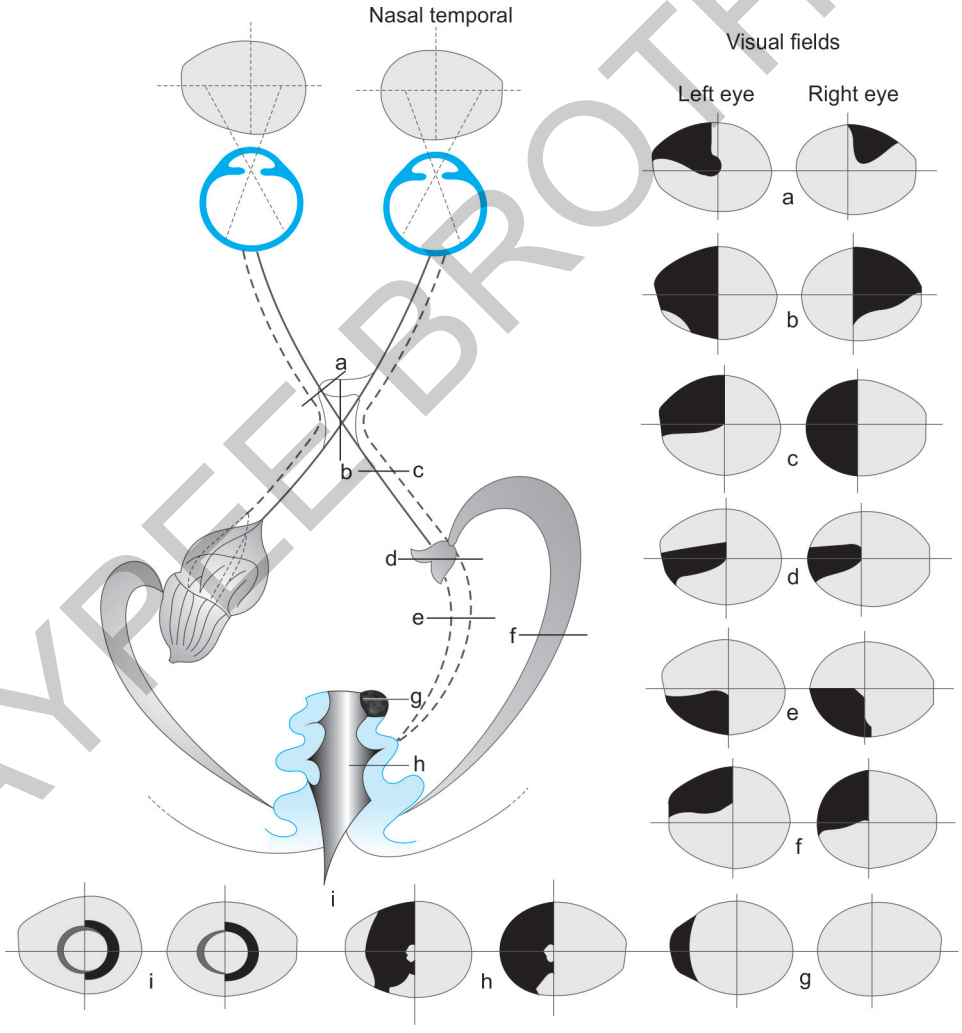

FIG. 2: Localization of lesions in the optic pathway (Chiasmal and retrochiasmal) causing various field defects. Visual fields from both eyes are usually abnormal but there is greater congruity with more posteriorly located lesions.

JAYPEE BROTHERS

Table 2: Characteristics of pupils encountered in neuro-ophthalmology

Condition	General characteristics	Response to light	Room condition
Essential anisocoria	Round, regular	Both brisk	No change
Horner's syndrome	Small, round, unilateral	Both brisk	Darkness
Tonic pupil syndrome	Usually lager in bright light; sector pupil palsy, vermiform movement unilateral or less often bilateral	Absent to light, tonic to near; tonic redilation	Light
Argyll Robertson pupils	Small, irregular, bilateral	Poor to light, better to near	No change
Midbrain pupils	Mid dilated; May be oval; bilateral	Poor to light, better to near	No change
Oculomotor palsy	Mid-dilated, unilateral (rarely bilateral)	Fixed	Light
Pharmacologically dilated pupils	Very large round, unilateral	Fixed	Light

Source: Dorsolateral medullary infarct (Wallenberg's syndrome).

cases of anterior ischemic optic neuropathy may also present with a central scotoma rather than an altitudinal hemianopia.

Uncommon but important differential diagnoses that can masquerade as "optic nerve type" visual field defects which respect the horizontal meridian include retinal lesions such as retinal detachment, autosomal dominant retinitis pigmentosa, chorioretinal degeneration or branch retinal artery occlusions. In addition, neurologists need to be aware of retinal disorders such as the cone dystrophies, which cause progressive visual loss with central scotomas, impaired color vision and optic atrophy, and are therefore often misdiagnosed as an optic neuropathy, with subsequent extensive (and expensive) but unnecessary laboratory and radiological investigations.

One other retinal disorder of importance to neurologists is the peripheral visual field constriction associated with the use of the anticonvulsant vigabatrin, a GABA transaminase inhibitor. Although initially considered a rare complication, it has now been recognized that this visual field loss is extremely common, and that once it has developed it is usually irreversible, despite cessation of the drug. The visual field loss is almost never detected by confrontation visual field testing, and it is therefore essential that all patients receiving vigabatrin, or probably any of the GABAergic anticonvulsants, should have regular visual field testing performed using computerized or Goldman perimetry.

Vertical Meridian

The vertical meridian is the great visual field watershed that separates retinal and optic nerve lesions from chiasmal and retrochiasmal damage. It is essential to recognize even the most subtle visual field deficit that respects the vertical meridian.

Optic Chiasma

The classic description of the complete bitemporal field defect caused by a lesion of the optic chiasm needs little elaboration. However, in early chiasmal compression, asymmetric visual field involvement is the rule rather than the exception, with a wide variety of field defects possible, and examination of the central 15 degrees of visual field for bitemporal foreshortening or field loss respecting the vertical meridian is critical. The tilted optic disk syndrome is an important congenital anomaly that can masquerade as a bitemporal chiasmal field defect with "pseudorespect" for the vertical meridian, and its recognition is important to prevent unnecessary neurological investigations.

Unilateral temporal visual field defects that respect the vertical meridian are, until incontrovertibly proven otherwise, an invaluable warning of a chiasmal lesion. If overlooked, they can represent a major neuro-ophthalmic disaster.

Binasal Field Loss

This, in contrast, usually arises as a subset of field defects involving the horizontal meridian.

JAYPEE BROTHERS



FIG. 3: Bitemporal visual field loss.

Common causes are:

- Glaucoma
- Optic nerve head drusen
- Chronic disk edema (e.g., papilledema)
- Optic nerve hypoplasia

Also include:

- Retinoschisis or detachment
- Chorioretinal degeneration

Historically cited but dubious:

- Dolichoectasia of the carotid or anterior cerebral arteries, with compression of the lateral sides of the optic chiasm or both optic nerves
- Chiasmal trauma
- Neurosyphilis

Finally:

- Hysteria/malingering—the absence of an area of "pre-fixation blindness" helps to distinguish this from organic binasal loss.

Retrochiasmal Lesions

The hallmark of the visual field defects caused by retrochiasmal lesions is that they are homonymous, and as a general principle the pattern of the defect in each eye becomes increasingly congruous as the lesion approaches the occipital lobe. Visual acuity is unaffected by the hemianopia, but frequently patients are not aware that the field defect is in both eyes and they report that the vision is reduced in the eye on the side of the hemianopia.

Complete Homonymous Hemianopia

This in an individual patient essentially does not have anatomically localizing value, since it may arise from a lesion at any point in the retrochiasmal pathway. However, associated clinical deficits may suggest a localization (e.g., optic tract lesion with hemiparesis and hypothalamic dysfunction; optic radiation lesion with hemiparesis, hemisensory loss and aphasia). In 100 patients with homonymous hemianopia, Smith reported that 40% had occipital lobe lesions, 33% parietal lobe, and 24% temporal lobe lesions, but optic tract and lateral geniculate lesions were rare. Approximately 42% of cases had a vascular origin and 38% were caused by tumor. However, in patients presenting with an isolated homonymous hemianopia, 89% were of vascular origin, with 86% due to occipital lobe infarction caused by posterior cerebral artery occlusion. In contrast, all of the cases under 30 years of age had nonvascular causes.

Optic Tract Lesions

These usually cause grossly incongruous homonymous hemianopia, often associated with unilateral or bilateral impairment of central visual acuity and sometimes a classical ipsilateral temporal optic disk pallor and contralateral wedge or butterfly band pallor.

JAYPEE BROTHERS

Lateral Geniculate Nucleus Lesions

These usually have a distinctive, rule-breaking congruous wedge-shaped homonymous defect that straddles the horizontal meridian in a pattern that reflects either lateral or anterior choroidal artery occlusion.

Occipital Lobe Lesions

These usually produce either a complete homonymous hemianopia, with or without macular sparing, or exquisitely congruous homonymous scotomata that can be anatomically localized within the architecture of the calcarine cortex. Midline tilting (deviation from the absolute meridian) of the field defect in patients with complete homonymous hemianopia is very common when careful perimetry is performed, but is rarely more than 15 degrees.

The classic map of the visual cortex created by Gordon Holmes is well known and depicts an orderly topographic representation of the contralateral hemifield of vision in the human striate cortex, with the central 15 degrees of visual field being allocated to approximately 25% of the surface area of the striate cortex. With the advent of high-resolution magnetic resonance scanning, this long-held clinical–anatomical correlation has undergone revision, with considerable expansion of the area of the striate cortex that subserves central vision and a concomitant reduction of the area devoted to peripheral vision. These changes help to explain why visual defects confined to the monocular temporal crescent are rare, since the anterior striate cortex subserving this monocular region of visual field constitutes less than 10% of the total striate cortex surface area. Similarly, the commonly used central 24–30 degree paradigms for computerized visual field testing actually assess 80–83% of the striate cortex, mitigating against failure to detect cortical occipital lesions with these programs.

The phenomenon of macular sparing with homonymous hemianopia is also more readily understood with this expanded central field representation, and is ascribed to the conjoint vascular supply of the occipital pole by the posterior and middle cerebral arteries that occurs in a minority of patients. Because the representation of the central vision field is so magnified in the posterior half of the striate cortex, perfusion by the middle cerebral artery with preservation of any portion of this region after posterior cerebral artery occlusion will variably spare cortex devoted exclusively to macular vision. Thus, the presence of a macular sparing homonymous hemianopia does suggest an occipital lobe origin for the deficit.

Several important clinical syndromes that involve lobe lesions warrant mention:

- Ipsilateral eye pain with contralateral homonymous hemianopia is an important indicator of occipital lobe infarction due to posterior cerebral artery occlusion (usually

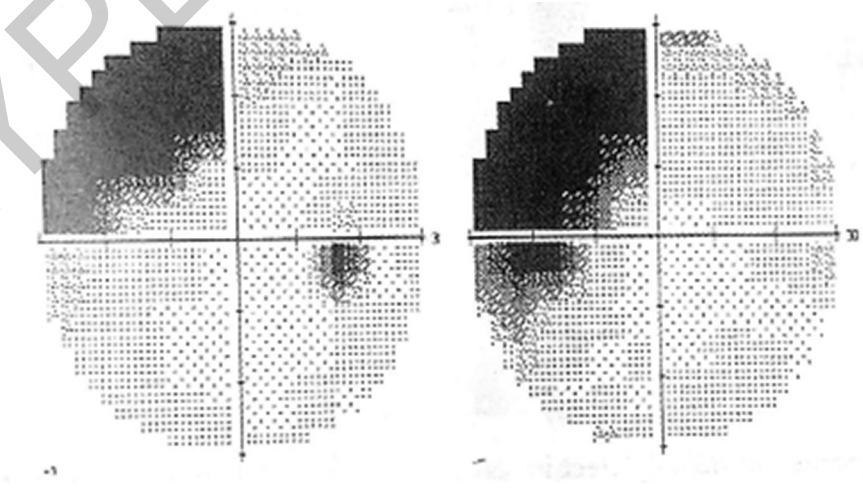

FIG. 4: Left superior homonymous quadranopia.

JAYPEE BROTHERS

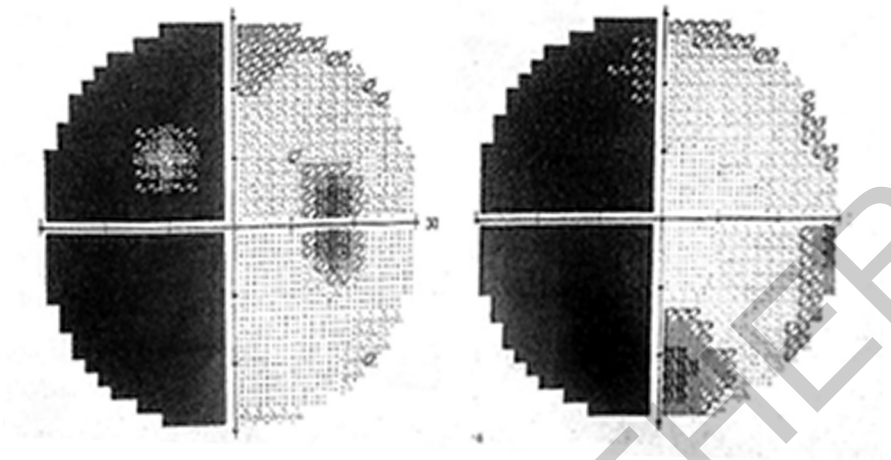

FIG. 5: Left homonymous hemianopia.



FIG. 6: Right homonymous hemianopia.

embolic). While cardiac investigation may be warranted, carotid studies are not directly indicated

- Alexia without agraphia and a right homonymous hemianopia indicates infarction of the left occipital lobe with extension to the splenium of the corpus callosum. All patients with a right homonymous hemianopia should have reading tested as part of their neurological examination
- Monocular peripheral field loss (temporal crescent) occurs with posterior optic radiation or anterior occipital lobe lesions that damage the projection of the unpaired peripheral nasal retinal fibers. Conversely, in a homonymous hemianopia, the monocular temporal crescent may be spared with posterior occipital lobe lesions that do not involve the anterior visual cortex. However, as discussed above, occipital lobe lesions causing visual field defects confined entirely to the monocular temporal crescent are rare. Monocular peripheral temporal visual field defects far more commonly arise from retinal lesions

JAYPEE BROTHERS



FIG. 7: .Superior altitudinal defect in glaucoma. Similar defect may be seen rarely in AION.

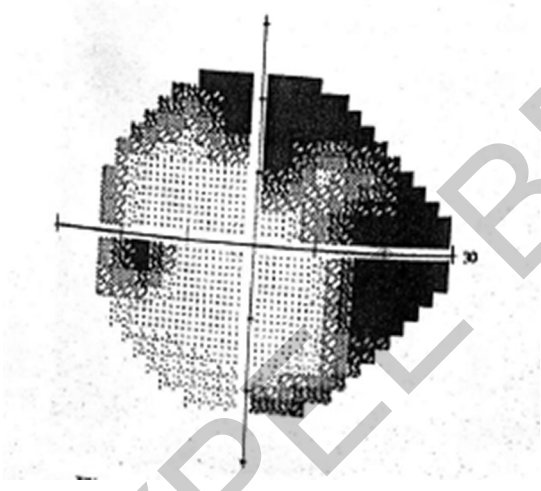

FIG. 8: Nasal step in glaucoma.

not occipital lesions, and the peripheral nasal retina should be carefully examined before a diagnosis of occipital pathology is made.

- Isolated homonymous congruous quadrantic visual field deficits with sharp horizontal borders have a high degree of specificity for lesions of the occipital lobe, rather than parietal or temporal lobes. When the field defect respects the horizontal meridian, it suggests specific involvement of the extrastriate (V2/V3) cortex as well as the upper or lower calcarine striate (V1) cortex. These lesions are often small, arise from vertebrobasilar disease and may escape detection by CT scan if presenting acutely. In contrast, the visual field defects caused by lesions of the optic radiations in either the parietal or temporal lobe are often incongruous and tend to have sloping borders that fail to respect precisely the horizontal meridian. Similarly, patients with optic tract lesions, such as those that occur occasionally following posterior GPi pallidotomy for Parkinson's disease, have incomplete homonymous quadrantic defects that do not respect the horizontal meridian and are often accompanied by homonymous paracentral scotomas.
- Rarely, occipital lobe lesions may cause bilateral homonymous paracentral scotomata that are mistaken for bilateral optic nerve lesions with cecocentral scotomas. With occipital lobe lesions, the pupil reflexes are normal.

Visual Field Defects in Glaucoma

Neurologits should acquaint themselves with at least the common forms of visual field defects produced by raised intraocular pressure. The common and important defects are only highlighted here.

Before discussing the field loss in glaucoma one must familiarize self with a few basic points. The retinal nerve fiber layer is constructed in such a way that no axon crosses the horizontal midline, and defects tend to localize to one side of the horizontal or the other. Fibers from macula run to the temporal side of the disk in the papillomacular bundle. The rest of the peripheral temporal retinal fibers arch above and below the macula to reach the upper and lower pole of the disk. The nasal fibers pass to the disk radically. It is the loss of the axon that results in visual field defect. The size and shape depend on the fibers affected. Loss of the arcuate temporal fibers will result in arcuate field defect and loss of radial nasal fibers will result in wedge defect. However due to the optics of the eye, the field defect will be reversed, i.e., the upper arcuate temporal fiber loss will produce a lower nasal arcuate defect and vice versa.

Damage to the optic nerve and hence the field defect in glaucoma may occur in one of two ways or a combination of both. Progressive nerve

JAYPEE BROTHERS

damage may occur diffusely with concentric enlargement of cup, progressive increase in cup: disc ratio and thinning of neuroretinal rim. The whole field may be diffusely affected showing an increase of threshold and lowering of sensitivity. This type of diffuse loss in early glaucoma is usually associated with high intraocular pressure. Damage may also occur focally with enlargement of the cup superiorly or inferiorly, or affection of part of neuroretinal rim producing nerve fiber bundle defect and corresponding field loss. This is mostly of vascular origin and seen in so-called "low tension glaucoma". With progress, both the features overlap.

Early glaucomatous damage therefore can show a diffuse lowering of sensitivity, or isolated paracentral scotoma in the same isopter as the blind spot, or a temporal wedge, even an early nasal step. With progress, there is enlargement of blind spot, Seidel scotoma, superior or inferior arcuate, double arcuate meeting in nasal step with or without peripheral breakthrough. With further progress an entire hemifield may be involved resulting in altitudinal defect. Finally, the patient may be left with a small central island and a small temporal crescentic field left.

Malingering and Factitious Visual Field Defects

Nonorganic (functional) visual loss is often accompanied by well-recognized indicators on manual (Goldmann/tangent screen) perimetry testing of the visual fields, including tubular or spiraling visual fields and crossed isopters. However, automated computerized visual field analyzers are becoming increasingly the instrument of choice for routine visual field screening and their output ostensibly has impressive controls for subject reliability and statistical analysis of deviation from the normal. Several reports are therefore important in demonstrating that malingerers without previous experience of visual field testing can easily produce automated visual fields that appear to reliably reflect organic patterns of visual field loss, including enlarged blind spots, quadrantic, hemianopic, altitudinal, and pseudo, chiasmal field defects. Neurologists suspecting factitious impairment must be guided by the summation of their whole examination, and not influenced by statistical output of a computerized field tester.

SUGGESTED READINGS

1. Anderson DR, Patella VM. Automated Static Perimetry. Mosby, St Louis, 2nd Edition, 1999.
2. Arndt CF, Derambure P, Defoort-Dhellemmes S, et al. Outer retinal dysfunction in patients treated with vigabatrin. Neurology. 1999;52:1201-5.
3. Biousse V, Newman NJ, Carroll C, et al. Visual fields in patients with posterior GPi pallidotomy. Neurology. 1998;50:258-65.
4. Fang JP, Donahue SP, Lin RH. Global visual field involvement in acute unilateral optic neuritis. Am J Ophthalmol. 1999;128:554-65.
5. Frisén L. Kinetic perimetry: Techniques and Strategies. Topics in Neuro-ophthalmology. Thompson HS. et al (eds). William & Wilkins Baltimore 1979, pp20-29.
6. Grochowicki M, Vighetto A, Berquet S, et al. Pituitary adenomas: Automatic static perimetry and Goldmann perimetry. A comparative study of 345 visual field charts. Br J Ophthalmol. 1991;75:219-21.
7. Horton JC, Hoyt WF. Quadrantic visual field defects. A hallmark of lesions in extrastriate (V2/V3) cortex. Brain. 1991;114:1703-18.
8. Horton JC, Hoyt WF. The representation of the visual field in human striate cortex. A revision of the classic Holmes map. Arch Ophthalmol. 1991;109:816-24.
9. Jacobson DM. The localizing value of a quadrantanopia. Arch Neurol. 1997;54:401-4.
10. Johnson MA, Krauss GL, Miller NR, et al. Visual function loss from vigabatrin. Effect of stopping the drug. Neurology. 2000;55:40-5.
11. Keltner JL, Johnson CA. Automated and manual perimetry–A six-year overview. Special emphasis on neuro-ophthalmic problems. Ophthalmology. 1984;91(1):68-85.
12. Lloyd JPF. Making perimetry pay. Tr Ophth Soc UK. 1948;67:409-22.
13. Luco C, Hoppe A, Schweitzer M, et al. Visual field defects in vascular lesions of the lateral geniculate body. J Neurol Neurosurgery and Psychiatry. 1992;55:12-5.
14. McFadzean R, Brosnahan D, Hadley D et al. Representation of the visual field in the occipital striate cortex. Br J Ophthalmol. 1994;78:185-90.
15. McFadzean RM, Hadley DM. Homonymous quadrantanopia respecting the horizontal meridian. A feature of striate and extrastriate cortical disease. Neurology. 1997;49:1741-6.
16. Rizzo JF, Lessell S. Optic neuritis and ischemic optic neuropathy. Overlapping clinical profiles. Arch Ophthalmol. 1991;109:1668-72.
17. Smith JL. Homonymous hemianopsia: A review of one hundred cases. Am J Ophthalmol 1962;54:616-22.

JAYPEE BROTHERS

18. Stewart JFG. Automated perimetry and malingerers. Can Humphrey be outwitted? Ophthalmology. 1995;102:27-32.
19. The clinical profile of optic neuritis. Experience of the Optic Neuritis Treatment Trial. Optic Neuritis Study Group. Arch Ophthalmol. 1991;109:1673-6.
20. Thompson JC, Kosmorsky GS, Ellis BD. Fields of dreamers and dreamed-up fields. Functional and fake perimetry. Ophthalmology. 1996;103:117-25.
21. Trobe JD, Lorber ML, Schelzinger NS. Isolated homonymous hemianopsia. Arch Ophthalmol. 1973;89:377-81.

JAYPEE BROTHERS

for detailed information on ophthalmology books, visit our website **www.jaypeebrothers.com,** for detailed informat

CLINICAL NEURO-OPHTHALMOLOGY

Salient Features

- Only comprehensive text on neuro-ophthalmology published from India
- Expected to be very useful to practicing neurologists, neurosurgeons, and ophthalmologists as well as to those in training
- Very well illustrated and written in a lucid language incorporating up-to-date information
- Clinical examination methods like measurement of visual acuity, ophthalmoscopy, and visual field examination are included
- Topics of current interest like use of optical coherence therapy in neurological practice, neuromyelitis optica spectrum disorders, modern management of idiopathic intracranial hypertension, and thyroid ophthalmopathy included
- Complex topics like nuclear, infranuclear, and supranuclear ocular motor and gaze disorders including nystagmus discussed in detail
- A separate chapter on problem oriented neuro-ophthalmology—pearls and pitfalls, would surely evoke lot of interest.

Ambar Chakravarty is presently working as an Honorary Professor in Neurology and is also an Emeritus Consultant at the Vivekananda Institute of Medical Science, Kolkata, India. Recipient of several awards and prizes including the Dr B C Roy National Award Fellowship of the Medical Council of India and awards from the Migraine Trust of London. Dr Chakravarty is a Fellow of The Royal Colleges of Physicians of London and Edinburg, Royal College of Physicians and Surgeons of Canada, and the Indian Academy of Neurology. In addition to extensive training in clinical neurology in India and the UK, he worked as a Research Fellow at Sunneybrook Hospital, Toronto, Canada (1984) and obtained the Sanofi Travelling Fellowship in Pediatric Neurology to work at Newcastle General Hospital, Newcastle upon Tyne, UK (1989). Dr Chakravarty had published extensively in national and international peer reviewed journals, had been an Editor-in-Chief of Frontiers in Neurology (2012–16), written five monographs in Neurology, and had delivered around 20 orations so far. His research interests lie in headaches, epilepsy, ataxias, neuro-ophthalmology, vestibular disorders, and neuroscience and art. He is an avid art lover, a collector, and an art critic.

Available at all medical bookstores
or buy online at www.jaypeebrothers.com



JAYPEE BROTHERS
Medical Publishers (P) Ltd.
www.jaypeebrothers.com
Join us on facebook.com/JaypeeMedicalPublishers

Shelving Recommendations
OPHTHALMOLOGY, NEUROLOGY

