t our website **www.jaypeebrothers.com,** for detailed information on radiology books, visit our website **www.jaypeebrothers.com**

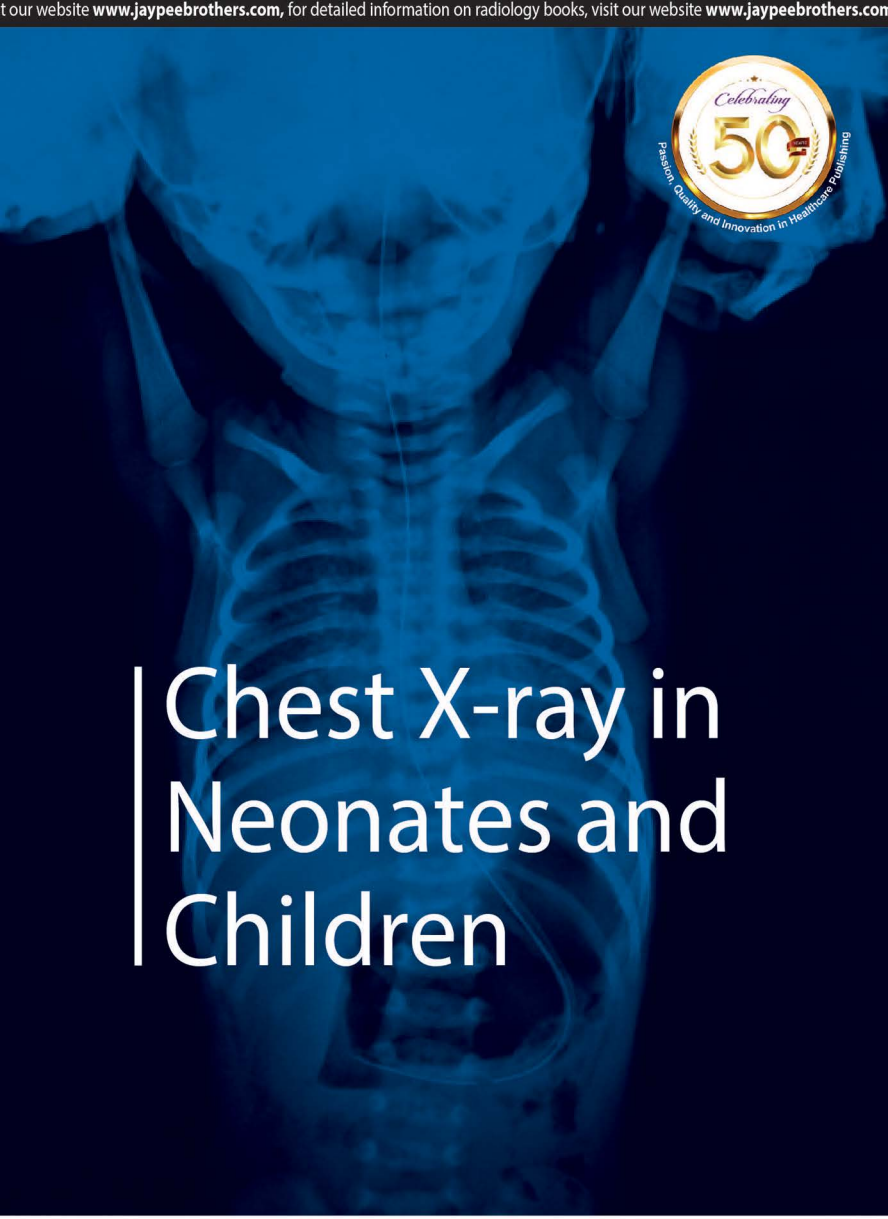

Chest X-ray in Neonates and Children

Swapan K Ray

JAYPEE

CONTENTS

1. Basics of Pediatric Chest X-ray **1**

2. Step by Step Interpretation **10**

Soft Tissue Shadows 10

Bones 12

Tracheal Anomaly 17

Cardiac Silhouette and Different Cardiological Conditions 18

Superior Mediastinal Lymphadenopathy 26

Thymic Enlargement 27

Pneumonia and Other Pulmonary Conditions 28

3. Miliary Shadows **40**

4. Pulmonary Space Occupying Lesion **43**

5. Chest X-ray in Neonates **45**

Index **61**

CHAPTER 4

Pulmonary Space Occupying Lesion

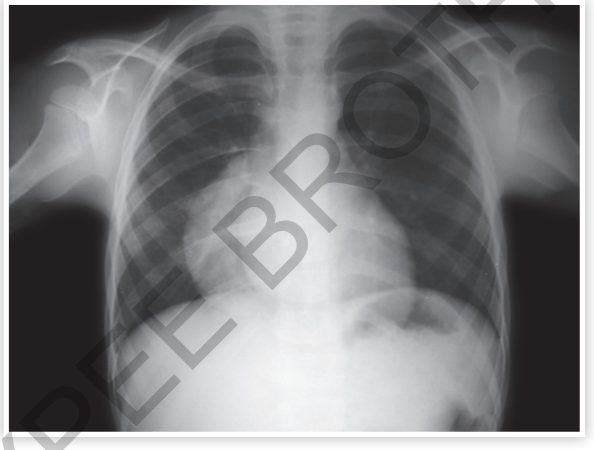

Fig. 1: X-ray chest PA view shows dense radiopaque shadow parallel and overlying right cardiac border.

X-ray chest PA view shows dense radiopaque shadow parallel and overlying right cardiac border, but the right border can be well visualized (Fig. 1).

Impression: Space occupying lesions (SOL) like neuroenteric cyst, lymphoma, sequestrated lung etc.

JAYPEE BROTHERS

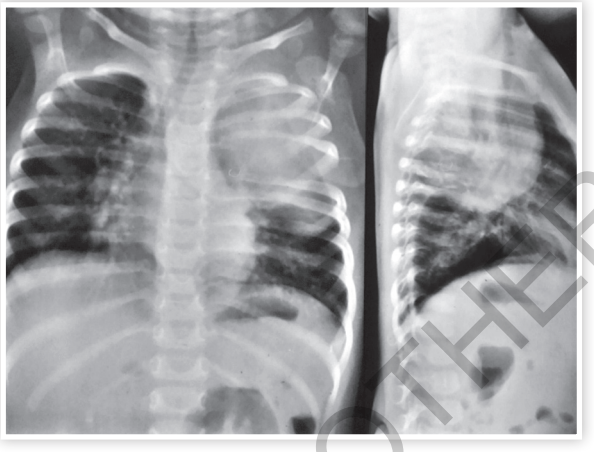

Fig. 2: X-ray chest PA view shows dense rounded radiopaque shadows in left upper zone.

X-ray chest PA view shows dense rounded radiopaque shadows left upper zone, the margin is well delineated (Fig. 2).

Impression: SOL left upper lobe (posterior mediastinal neurogenic tumor viz. neuroblastoma).

This child presented later with both lower limb weakness and upper motor neuron type of paralysis.

One must keep in his mind that all radiopaque shadows are not always pneumonias.

JAYPEE BROTHERS

for detailed information on radiology books, visit our website **www.jaypeebrothers.com,** for detailed information on radiology bo

Chest X-ray in Neonates and Children

Key Features

- A guide to interpret chest X-rays in a simpler and structured form, thus minimizing missing any findings
- Focus on common clinical scenarios and relevant findings
- Helps students for quick mopping of radiological aspects, in the last minute
- A practical book for pediatricians, postgraduate students and busy practitioners
- This book is a tribute to medical fraternity.

Swapan K Ray MBBS DCH DNB MNAMS is a Professor of Pediatrics in IQ City Medical College, Durgapur, West Bengal, India. He had a keen interest in Pediatric Radiology. He is considered as pioneer in Pediatric Radiology in India for his services at the Institute of Child Health, Kolkata for 23 years. He has worked under the guidance of Late Professor Sisir K Bose, who is considered as the doyen of Pediatric Radiology in India. He had presented different topics on Pediatric Radiology in different conferences, seminars and classes. He was a faculty in Pediatric Radiology in international, national and regional conferences. He has written a chapter on Pediatric Radiology in a book on infectious diseases in children. He was conferred with Purbanchal IAP Pioneer Award in the East Zone PEDICON in 2011. He has several publications in different indexed international, national and regional journals. He is the current President of Howrah Academy of Pediatrics. He was the Editorial Board member of West Bengal Academy of Pediatrics (WBAP) for 3 years and the organizing secretary of WBAP state conference in 2012.

Professor Swapan K Ray, as a teacher, wants to contribute for student welfare.

Available at all medical bookstores
or buy online at www.jaypeebrothers.com



JAYPEE BROTHERS
Medical Publishers (P) Ltd.
www.jaypeebrothers.com
Join us on facebook.com/JaypeeMedicalPublishers

Shelving Recommendation
RADIOLOGY

ISBN 978-93-5270-594-8

