rothers.com, for detailed information on pathology books, visit our website www.jaypeebrothers.com, for detailed information on pathology books

Celebrating 50 YEARS
Passion, Quality and Innovation in Healthcare Publishing

Renal Biopsy

Interpretation

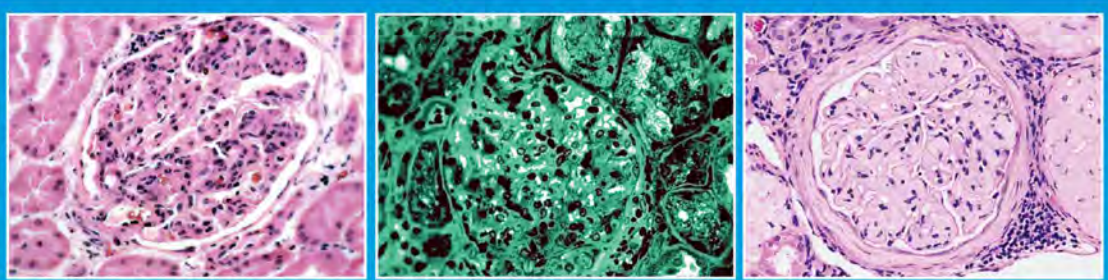

Anila Korula

JAYPEE

Contents

1. **Introduction** **1**
2. **Indications for Biopsy Proven Categories of Renal Diseases** **3**
3. **Histopathologic Evaluation** **5**
   - ❑ Normal Structure of Glomerulus 5
   - ❑ Ultrastructure of Glomerular Capillary Lobule 6
   - ❑ Reporting of the Renal Biopsy 8
4. **Glomerular Diseases** **10**
   - ❑ Primary Glomerulonephritis 10

   Non-proliferative Glomerulonephritis 10
   - ❑ Minimal Change Disease 10
   - ❑ Variants of Minimal Change Disease 12
   - ❑ Focal Segmental Glomerulosclerosis 16
   - ❑ Membranous Nephropathy 25

   Proliferative Glomerulonephritis 32
   - ❑ Diffuse Predominantly Endocapillary Proliferative Glomerulonephritis 32
   - ❑ IgA Nephropathy 36
   - ❑ Non-IgA Mesangial Proliferative Glomerulonephritis 42
   - ❑ Crescentic Glomerulonephritis 44
   - ❑ Membranoproliferative Glomerulonephritis 46
   - ❑ C3 Glomerulopathy 54
   - ❑ C1Q Glomerulopathy 59
   - ❑ Focal (Segmental) Proliferative Glomerulonephritis 60
5. **Systemic Glomerular Diseases** **61**

   Collagen Vascular Diseases 61
   - ❑ Systemic Lupus Erythematosus 61
   - ❑ ISN/RPS Classification of Lupus Nephritis (LN) (2003) 62
   - ❑ Mixed Connective tissue Disease 77
   - ❑ Systemic Sclerosis 78
   - ❑ Sjogren's Syndrome 80
   - ❑ Rheumatoid Arthritis 81
6. **Diabetic Nephropathy** **83**
   - ❑ Glomerular Classification of Diabetic nephropathy 85
7. **Systemic and Renal Limited Vasculitides** **89**

   Major Categories of Non-infectious Vasculitis 90
   - ❑ ANCA-associated Small Vessel Vasculitis 90
   - ❑ Large Vessel Vasculitis 96

- ❑ Medium-sized Vessel Vasculitis 96
- ❑ Henoch-Schonlein Purpura Nephritis 98

8. Anti-glomerular Basement Membrane Disease 100

9. Paraproteinemias/Dysproteinemias-associated Renal Disease 103

- ❑ Amyloidosis 103
- ❑ Monoclonal Immunoglobulin Deposition Disease 108
- ❑ Light Chain Cast Nephropathy 111
- ❑ Proliferative Glomerulonephritis with Monoclonal Immunoglobulin Deposits 112

10. Glomerulonephritis with Organized Immune Deposits 114

- ❑ Fibrillary Glomerulopathy 114
- ❑ Immunotactoid Glomerulopathy 117
- ❑ Cryoglobulinemic Glomerulonephritis 120

11. HIV-associated Nephropathy 124

12. Heredofamilial Glomerulopathies 128

Collagen Nephropathies 128

Type IV Collagen Nephropathies 128

- ❑ Alport's Syndrome 129
- ❑ Thin Basement Membrane Disease/Benign Familial Hematuria 132

Type III Collagen Nephropathy 134

- ❑ Collagenofibrotic Glomerulopathy 134
- ❑ Nail-Patella Syndrome (Hereditary Osteo-onychodysplasia) 136

Fibronectin Glomerulopathy 139

Lipid Storage Diseases 142

- ❑ Fabry's Disease 142
- ❑ Familial Lecithin Cholesterol Acyltransferase Deficiency 145
- ❑ Lipoprotein Glomerulopathy 146

Congenital Nephrotic Syndrome and Podocytopathies 148

- ❑ Finnish Type Congenital Nephrotic Syndrome 148
- ❑ Diffuse Mesangial Sclerosis 149
- ❑ Minimal Change Nephrotic Syndrome 150
- ❑ Focal Segmental Glomerulosclerosis 150
- ❑ Collapsing Glomerulopathy 151
- ❑ Podocytopathies 151

13. Tubulointerstitial Diseases 154

- ❑ Normal Structure 154
- ❑ Acute Tubular Injury/Necrosis 156
- ❑ Nephrotoxic Acute Tubular Necrosis 157
- ❑ Tubulointerstitial Nephritis 157
- ❑ Acute Tubulointerstitial Nephritis 158
- ❑ Chronic Tubulointerstitial Nephritis 159
- ❑ Granulomatous Interstitial Nephritis 160

- ❑ IgG4-related Tubulointerstitial Nephropathy 161
- ❑ Metabolic Disorders (Crystallopathies) 163
- ❑ Cystinosis 165
- ❑ Mitochondriopathies 166
- ❑ Hyperuricemia and Urate Nephropathy 166
- ❑ Hypercalcemic Nephropathy 167

14. Vascular Renal Diseases **171**

- ❑ Normal Structure of Renal Vasculature 171
- ❑ Juxtaglomerular Apparatus 172
- ❑ Malignant Hypertensive Nephrosclerosis 174
- ❑ Thrombotic Microangiopathy 176
- ❑ Antiphospholipid Antibody Syndrome 182
- ❑ Pre-eclamptic Toxemia and Eclampsia 183

15. Renal Transplant Diseases **186**

- ❑ Revised Banff 2017 Classification 186
- ❑ Acute/Active Antibody-mediated Rejection 187
- ❑ Chronic Active Antibody-mediated Rejection 194
- ❑ Acute/Active T cell-mediated Rejection 197
- ❑ Chronic active T cell-mediated Rejection (GRADE II) 200
- ❑ Calcineurin Inhibitor Toxicity 202
- ❑ Infections in Renal Allograft 204
- ❑ Polyomavirus Nephropathy 204
- ❑ Cytomegalovirus Nephropathy 208
- ❑ Adenovirus Nephropathy 209
- ❑ Recurrent Glomerulonephritis 210
- ❑ De novo Glomerular Diseases 212
- ❑ Post-transplant Lymphoproliferative Disorder 213

Index *219*

CHAPTER 4

Glomerular Diseases

ABSTRACT

This chapter categorizes this entity into non-proliferative and proliferative glomerulonephritis, and includes the incidence in CMCH, Vellore, relevant pathogenesis, light microscopic, immunofluorescence and electron microscopic features of each subtype, with the differential diagnosis, course and prognosis. The non-proliferative forms comprise minimal change disease, focal and segmental glomerulosclerosis (FSGS) and membranous nephropathy. Minimal change disease with its variants and inherited forms are dealt with concisely in perspective as "podocytopathies". The classification of FSGS and differentiation from secondary FSGS is delineated with pertinent details. The important stages of membranous nephropathy by light and electron microscopy are clearly highlighted along with the detection of glomerular expression of PLA2R as the major target antigen by immunohistochemistry.

The proliferative glomerulonephritis (GN) classified as focal or diffuse is further elucidated comprising details of the endocapillary, mesangial IgA (with the Oxford classification and MEST score) crescentic, membranoproliferative, (MPGN), C3GN and C1q glomerulopathy. The rarer forms of MPGN with electron microscopic features as reported in our center are clearly depicted.

PRIMARY GLOMERULONEPHRITIS

Primary glomerulonephritis comprises two major categories:

1. Non-proliferative
2. Proliferative.

Non-proliferative Glomerulonephritis

Non-proliferative glomerulonephritis comprises three major entities, that are associated with podocyte injury but do not exhibit significant proliferation of intrinsic glomerular cells, as follows:

1. Minimal change disease
2. Focal and segmental sclerosis
3. Membranous nephropathy.

MINIMAL CHANGE DISEASE

Minimal change disease accounts for 90% of primary nephrotic syndrome in children presenting with highly selective proteinuria of >3.5 g/day. The peak incidence is 2 to 3 years of age and median age is 2.5 years. Our biopsy series in the pediatric age showed a prevalence of 47.2%,[1] and

JAYPEE BROTHERS

this is the most common category in children.[2,3] This entity has a normal morphology by light microscopy and has ultrastructural features of a "podocytopathy" defined by effacement of foot processes and normal podocyte numbers. There are idiopathic, reactive and genetic forms of minimal change nephropathy (MCN). It is postulated that an associated T cell dysfunction, with release of cytokines initiates podocyte transformation. The latter process is mediated by signal transduction through the slit diaphragm, increased lysosomal proteinases, loss of cell polarity and loss of anionic podocyte proteins, resulting in proteinuria. As there are alterations in podocyte structure and no podocyte loss, these changes are potentially reversible with corticosteroids.[4]

Light Microscopic Features

- Normocellular glomeruli of standard normal size with patent capillary lumina in the majority (Fig. 4.1)
- Focal mild increase in mesangial cellularity with 3 mesangial cells in mesangial zone, in a minority
- No significant expansion of mesangial matrix
- Capillary walls of normal thickness
- Tubulointerstitial and vascular compartments are normal.

Immunofluorescent Features

- Negative for immunoglobulins and complement
- Mesangial IgM 1+ in occasional biopsies.

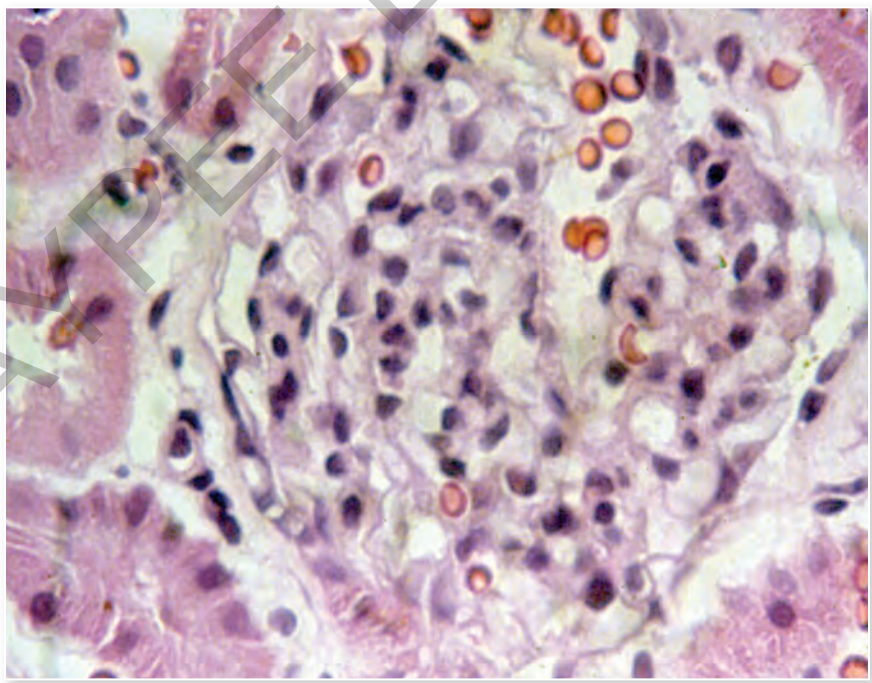

Figure 4.1: Minimal change disease (H&E x 400)

JAYPEE BROTHERS

Electron Microscopic Features

Diffuse effacement of foot processes of podocytes with retraction, widening and shortening of foot processes and normal numbers of podocytes (Figs 4.2A and B).

Prognosis

Remission of proteinuria is usually seen in 8 weeks of treatment with steroids in 90–95% of cases. Frequent relapses with steroid dependence occur in the remaining cases.

Glomerular hypertrophy with glomerular tuft area up to 1.75 times and greater than that of glomeruli from age matched normal controls or minimal change disease is associated with the risk of developing focal and segmental sclerosis, which can be detected on repeat biopsies.[5] Serial deeper sections of the entire paraffin block are required for the detection of an incipient focus of early tuft sclerosis and differentiation from minimal change disease in our experience.

VARIANTS OF MINIMAL CHANGE DISEASE

Diffuse Mesangial Hypercellularity

Diffuse mesangial hypercellularity accounts for 3% of pediatric nephrotic syndrome.

Light Microscopic Features (Fig. 4.3)

- Diffuse mesangial cellularity, with >4 mesangial cells per mesangial region, involving 80% of glomeruli, by International Study of Kidney Disease in Childhood (ISKDC) criteria[6,7]
- No evidence of mesangial matrix expansion or occlusion of capillary lumina.

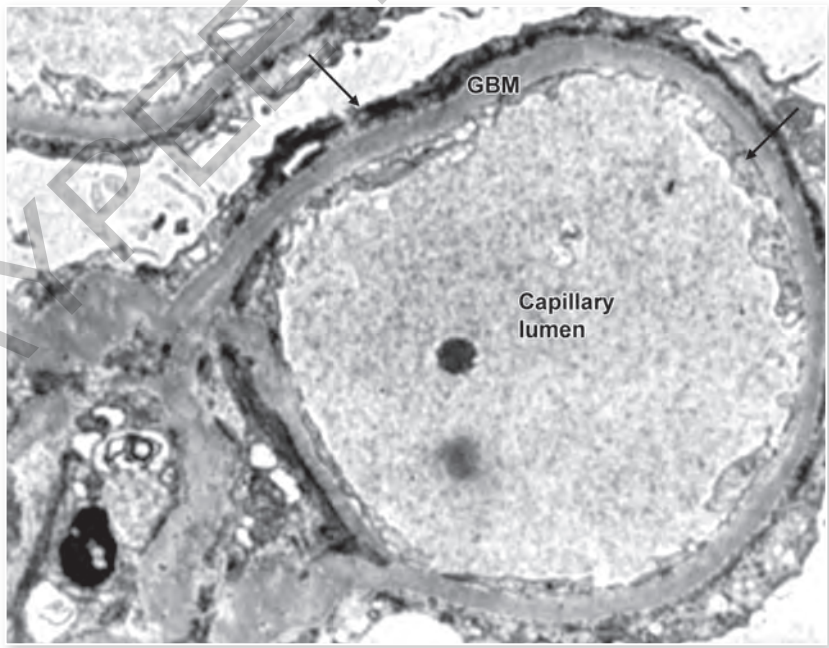

Figure 4.2A: Foot process effacement in minimal change disease (arrows)

JAYPEE BROTHERS

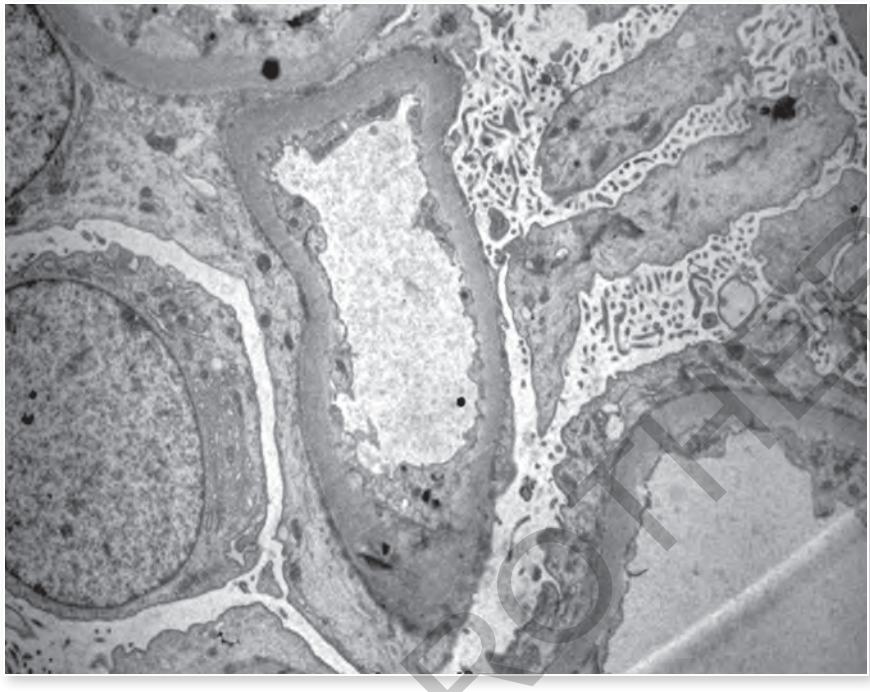

Figure 4.2B: Foot process effacement with microvillous hypertrophy in MCD (EM x 4200)

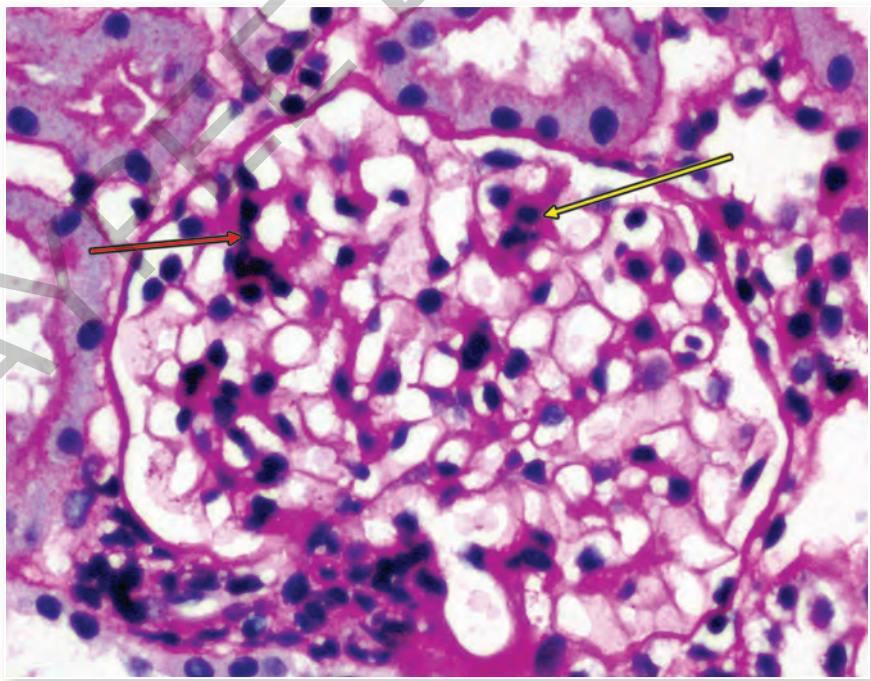

Figure 4.3: Mild (yellow arrow) to moderate (red arrow) mesangial hypercellularity (PAS x 400)

JAYPEE BROTHERS

Grades of Mesangial Hypercellularity: South West Pediatric Nephrology Study[8]

Mesangial hypercellularity is graded according to the number of mesangial cells/mesangial area as follows:

- Mild mesangial hypercellularity: 3 mesangial cell nuclei, per mesangial area
- Moderate mesangial hypercellularity: 4 mesangial cell nuclei, per mesangial area
- Severe mesangial hypercellularity: ≥5 mesangial cell nuclei, per mesangial area.

Prognosis

Diffuse mesangial hypercellularity and grades of mesangial hypercellularity, from mild to severe, are associated with poor response to 8 weeks course of intensive corticosteroid therapy.[9] There are reportedly no significant differences in long term outcome of diffuse mesangial hypercellularity, after 52 weeks of steroid therapy, from minimal change disease. Late steroid non-responsiveness is not related to the initial severity of mesangial hypercellularity and does well with alternative forms of immunosuppression.[9]

IgM Variant (IgM Nephropathy)

Light Microscopic Features

It can be similar to minimal change disease:

- Variable increase in mesangial cellularity is seen
- Progression to diffuse mesangial cell and matrix proliferation and focal and segmental sclerosis.[10-15]

Immunofluorescent Features

Diffuse mesangial deposition of IgM 2+ or 3+ with C3 deposits (in 30–100% cases).

Electron Microscopic Features

Extensive foot process effacement with small mesangial electron dense deposits in paramesangial areas in 50% cases.

Differential Diagnosis

Diffuse mesangial proliferative glomerulonephritis that is associated with diffuse mesangial matrix and cell proliferation and is often immunofluorescence negative.

Prognosis

Steroid dependence or resistance has been noted in 25–50% cases and progression to focal and segmental sclerosis on repeat serial biopsies. As the prognosis differs from minimal change disease this is considered as a different and distinct entity by some nephropathologists.

Inherited forms of MCNS that are steroid resistant have been reported with genetic mutations and include:

JAYPEE BROTHERS

- Non-syndromic type associated with the *podocin (NPHS2) gene*
- Syndromic type with *dysferlin (DYSF) gene* of limb-girdle muscular dystrophy, 2B mutation.[4,16]

Reactive forms of MCN are associated with malignancy (Hodgkin's lymphoma), immune dysregulation and are induced by medication (non-steroidal anti-inflammatory drugs penicillamine, interferon).

Minimal change disease in adults occurs in 10–15% cases[17] with 11.6% in our case series from CMC, Vellore.[18] A higher incidence of 21.8% has been recently reported, inclusive of children and adults from South India.[19] This is usually secondary or reactive associated with drugs, neoplasms, infections, allergies and other concurrent glomerular and extraglomerular diseases.

REFERENCES

1. Balakrisnan N, John GT, Korula A, Visalakshi J, Talauikar GS, Thomas PP, et al. Spectrum of biopsy proven renal disease and changing trends at a Tropical Tertiary Care Centre, 1990-2001. Indian J Nephrol. 2003;13; 29-35.
2. Habib R, Kleinknecht C. The primary nephrotic syndrome of childhood: Classification and clinicopathologic study of 406 cases. Pathol Ann.1971;6:417-74.
3. Churg J, Habib R, White RHR. Pathology of the nephrotic syndrome in children: a report of the International Study of Kidney Disease in Children. Lancet. 1970;1:1299-302.
4. Lane JC, Kaskel FJ. Pediatric nephrotic syndrome. From the simple to the complex. Seminars In Nephrology. 2009;29:389-98.
5. Fogo A, Hawkins EP, Berry PL, et al. Glomerular hypertrophy in minimal change disease predicts subsequent progression to focal glomerular sclerosis. Kidney Int. 1990;38:115-23.
6. Primary nephrotic syndrome in children: clinical significance of histopathologic variants of minimal change and of diffuse mesangial hypercellularity. A Report of the International Study of Kidney Disease in Children. Kidney Int. 1981;20(6):765-71.
7. Report of the International Study of Kidney Disease in Children. The primary nephrotic syndrome in children. Identification of patients with minimal change nephrotic syndrome from initial response to prednisone. J Pediatr. 1981;98:561-4.
8. Childhood nephrotic syndrome associated with diffuse mesangial hypercellularity. A report of the Southwest Pediatric Nephrology Study Group. Kidney Int. 1983;24(1):87-94.
9. Bernstein J, Edelmann CM. Minimal change nephrotic syndrome. Histopathology and steroid- responsiveness. Archives of Disease in Childhood. 1982;57:816-7.
10. Cohen AH, Border WA, Glassock RJ. Nephrotic syndrome with glomerular mesangial IgM deposits. Lab Invest. 1978;38:610-9.
11. Swartz SJ, Eldin KW, Hicks MJ, Feig DI. Minimal change disease with IgM+ immunofluorescence: a subtype of nephrotic syndrome. Pediatr Nephrol. 2009;24(6):1187-92. doi: 10.1007/s00467-009-1130-0. Epub 2009.
12. Zeis PM, Kavazarakis E, Nakopoulou L, Moustaki M, Messaritaki A, Zeis MP, et al. Glomerulopathy with mesangial IgM deposits: long-term follow-up of 64 children. Pediatr Int. 2001;43:287-92.
13. Al Eisa, et al. Childhood IgM nephropathy: comparison with minimal change disease. Nephron. 1996;72:37-43.
14. Hirszel P, et al. Mesangial proliferative glomerulonephritis with IgM deposits. Nephron.1984;32(2):100-8.
15. Little MA, Dorman A, et al. Glomerulonephritis with IgM deposits: Clinical characteristics and outcome. Renal Failure. 2000;22(4):445-57.
16. Caridi G, et al. Familial forms of nephrotic syndrome. Pediatr Nephrol. 2010;25:241-52L.
17. Rathi M, Bhaghat RL, Mukhopadhyay P, Kohli HS, Jha V, Gupta KL. Changing histologic spectrum of adult nephrotic syndrome over five decades in north India: A single center experience. Indian J Nephrol. 2014;24(2):86-91.
18. Narasimhan B, Chacko B, John GT, Korula A, Kirubakaran MG, Jacob CK. Characterization of kidney lesions in Indian adults: towards a renal biopsy registry. J Nephrol. 2006;19: 205-10.
19. Das U, Prayaga A, Dakshinamurthy KV. Pattern of renal disease in a single centre of South India:19 years experience. Indian J Nephrol. 2011;21:250-7.

JAYPEE BROTHERS

FOCAL SEGMENTAL GLOMERULOSCLEROSIS

Focal segmental glomerulosclerosis (FSGS) is a leading cause of nephrotic syndrome in adults and the most common biopsy proven category in the age groups >15 years in our experience, comprising 16.8–17% in a series of cases. By definition, this lesion is "focal", involving <50% of glomeruli in a biopsy and "segmental", affecting part of the circumference of a glomerular tuft. Diffuse effacement of podocyte architecture is a defining ultrastructural feature, with reduction in numbers of podocytes. Loss of podocytes through detachment or apoptosis, leads to denudation of the GBM, adhesions to Bowman's capsule with segmental sclerosis. Phenotypic changes in podocyte structure with epithelial mesenchymal transition and foot process effacement with loss of function of slit diaphragms and glomerular filtration barrier lead to proteinuria. These changes become progressive and irreversible in FSGS.[1-3] Circulating permeability factors including elevated serum levels of soluble urokinase receptor have been postulated to induce foot process effacement through the activation of podocyte B3 integrin, but the exact source and stimulants of this receptor is unknown.[4]

There are primary and secondary forms of FSGS with 5 morphologic variants in order of frequency in the Columbia classification,[2] as follows:

1. FSGS, not otherwise specified [FSGS (NOS)]
2. Perihilar variant
3. Cellular variant
4. Tip variant
5. Collapsing variant.

FSGS, Not Otherwise Specified

It is the classic or usual type, involves at least one glomerulus and requires the exclusion of other morphologic categories:[5-8]

Light Microscopic Features (Fig. 4.4)

- Discrete segmental increase and condensation of extracellular matrix
- Obliteration of glomerular capillary lumina
- Early involvement of peripheral segments of juxtamedullary glomeruli
- Associated hyalinosis, known as "plasmatic insudation" comprising: amorphous, eosinophilic, PAS positive nonargyrophilic and trichrome red material
- Diffuse mesangial hypercellularity (in pediatric cases)
- Capsular adhesions or synechiae to Bowman's capsule
- Cellular cap formed by podocytes over the segment
- Detachment of podocytes with intervening weakly positive PAS positive matrix.

Immunofluorescent Features (Fig. 4.5)

Focal and segmental trapping of IgM and C3 in sclerotic tufts.

Electron Microscopic Features (Figs 4.6A and B)

- Retraction of glomerular basement membrane in sclerotic segments
- Obliteration of lumen by matrix material

JAYPEE BROTHERS

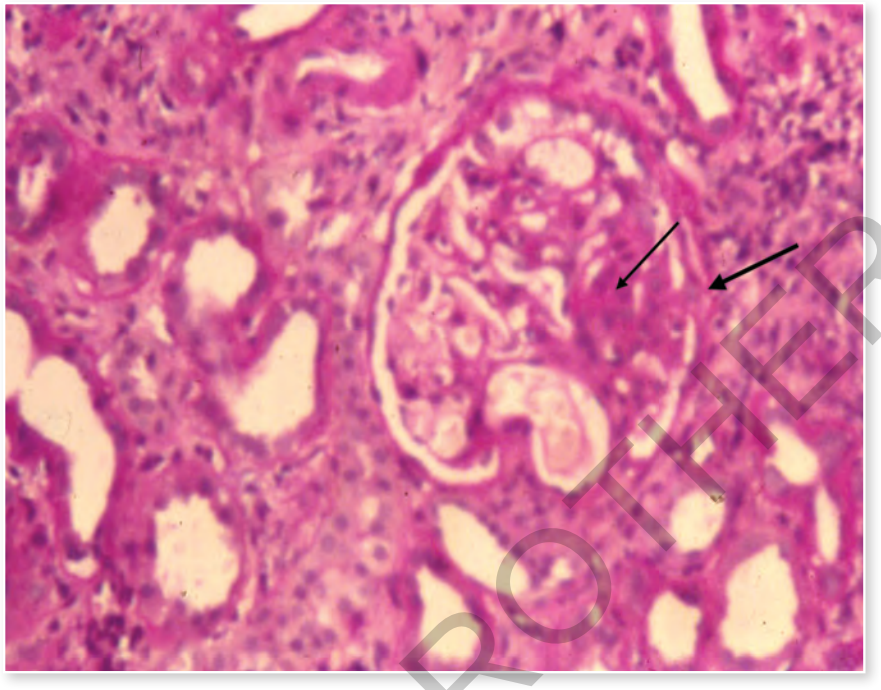

Figure 4.4: Focal segmental sclerosis-NOS (PAS x 400) with condensation of matrix (thin arrow) and capsular synechiae (thick arrow) (PAS x 400)

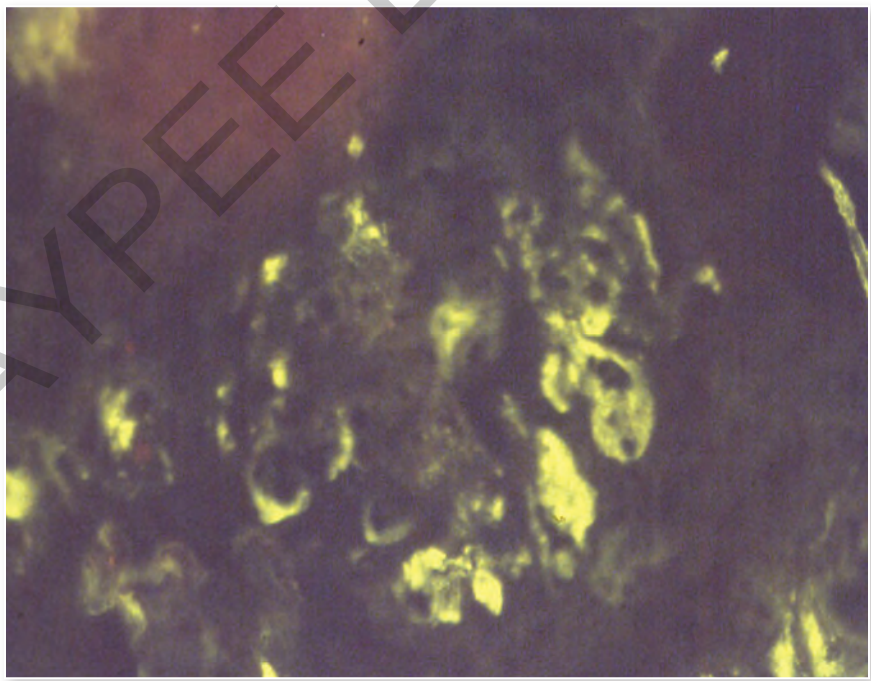

Figure 4.5: Focal segmental trapping of IgM in sclerotic tufts (IF x 400)

JAYPEE BROTHERS

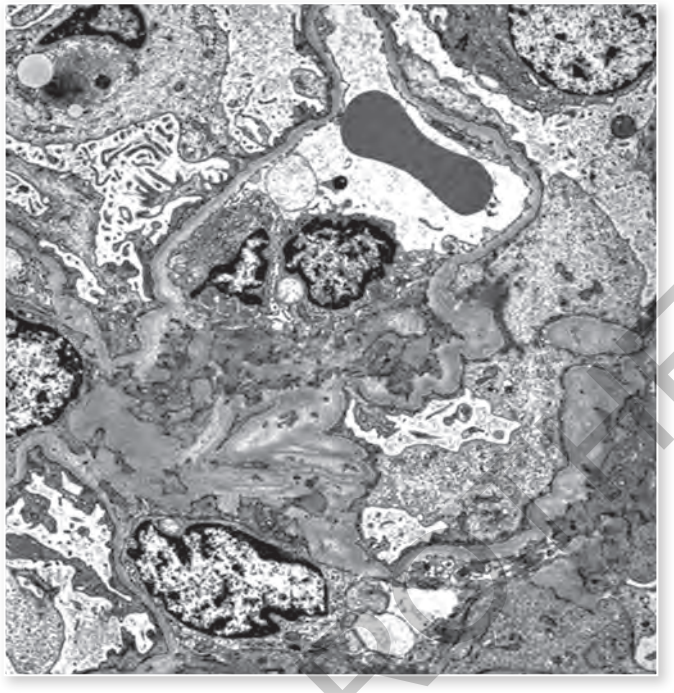

Figure 4.6A: FSGS (NOS) with diffuse effacement of foot processes of podocytes and microvillous processes (EM)

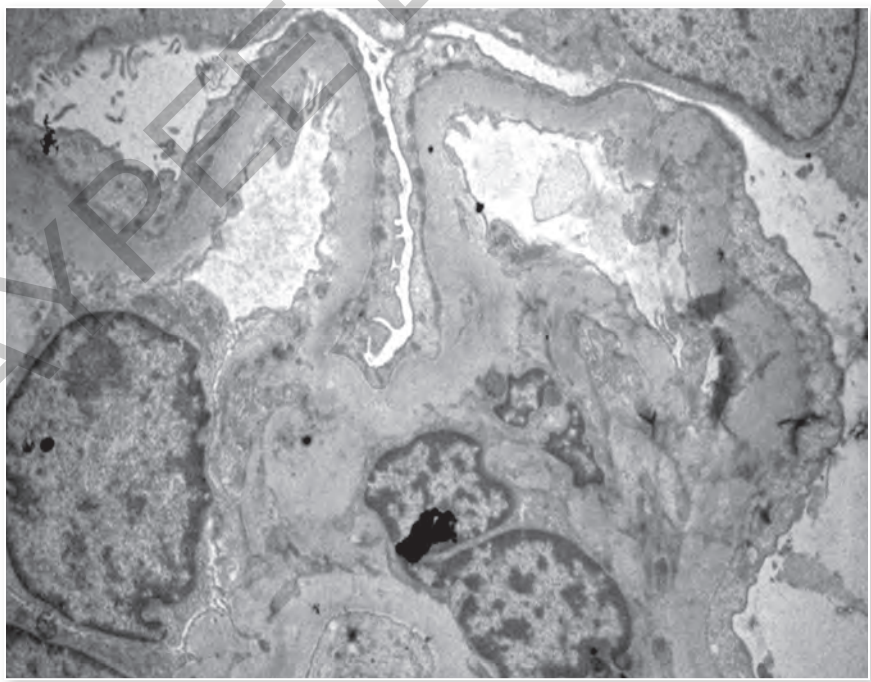

Figure 4.6B: FSGS (NOS) with diffuse effacement of foot processes (EM x 6000)

JAYPEE BROTHERS

- Electron dense hyaline material in lumen between endothelial cell and GBM
- Diffuse effacement of foot processes of podocytes (>50% of glomerular capillary surface area)
- Loss of primary cytoplasmic processes and slit diaphragms noted
- Detachment and hypertrophy of podocytes with microvillous processes, on luminal aspect
- Lamellated neomembrane between denuded GBM and detached podocyte.

Perihilar Variant

It is more common with secondary forms of FSGS, mediated by an adaptive response to increased capillary pressures with reduced number of functioning nephrons.[1]

Microscopic Features

- Sclerosis at and adjacent to vascular pole as the predominant lesion (Fig. 4.7)
- Involving >50% of segmentally sclerotic glomeruli
- Glomerulomegaly with capsular synechiae and arteriolar hyalinosis
- Podocyte hypertrophy and hyperplasia less frequent
- Other glomeruli can display segmental and/or global sclerosis of classical (NOS) type.

Cellular Variant[5,9-11]

Microscopic Features

- Segmental endocapillary hypercellularity of at least 25% of the tuft (Fig. 4.8)
- Peripheral or hilar segment involved with condensation of matrix

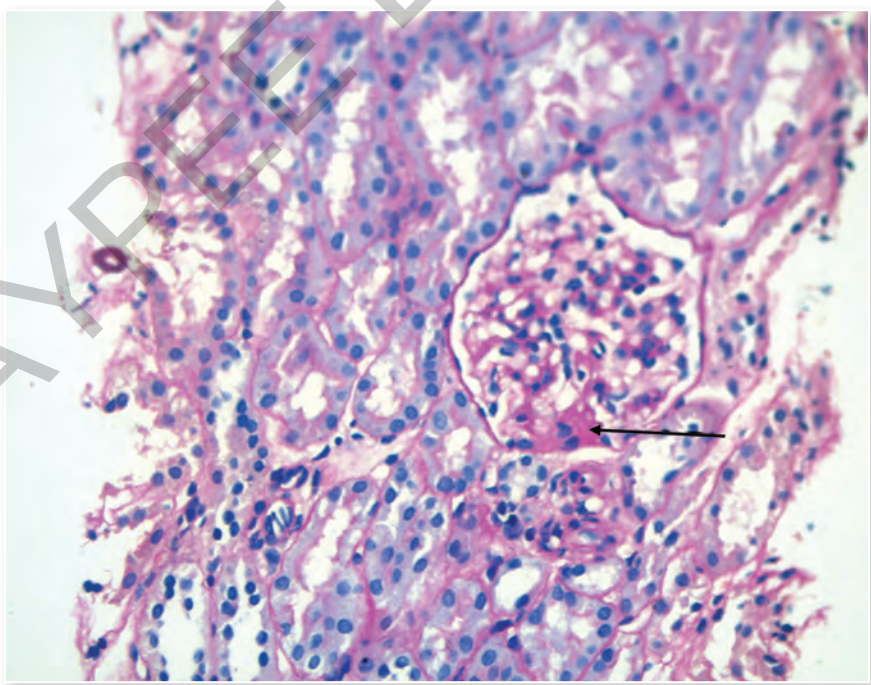

Figure 4.7: Focal segmental sclerosis—perihilar variant (PAS x 200, arrow)

JAYPEE BROTHERS

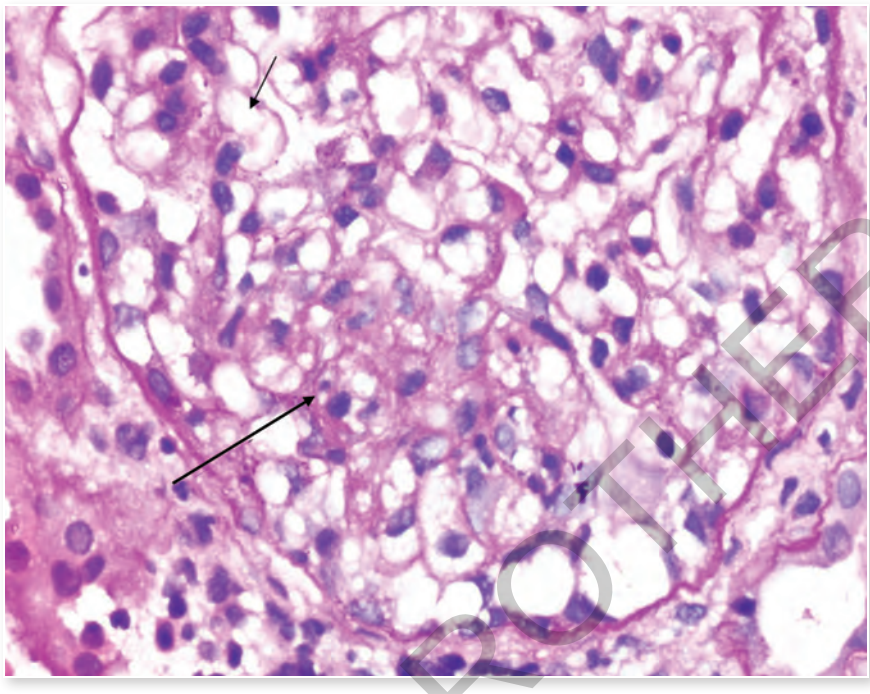

Figure 4.8: Focal segmental glomerulosclerosis—cellular variant (PAS x 400, arrow)

- Endocapillary cells include leukocytes (monocytes, **foamy macrophages, lymphocytes or neutrophils)**
- **Karyorrhexis** without rupture of glomerular basement membrane
- Often associated with lesions of classical, focal segmental (NOS) and global glomerulosclerosis
- Can be differentiated from focal segmental proliferative glomerulonephritis
- By immunofluorescence, glomeruli are negative for immune complex deposits.

Tip Variant[5,12,13]

Microscopic Features

- Focal condensation of matrix in tip domain, adjacent to origin of proximal tubule (Figs 4.9 and 4.10)
- Involves 25% of at least one glomerulus opposite the vascular pole
- Confluence of enlarged podocytes with parietal cells or tubular epithelial cells
- Intracapillary foam cells and capsular synechiae of the tuft at tubular pole
- Collapsing variant and perihilar sclerosis have to be excluded
- Peripheral segments of sclerosis or endocapillary hypercellularity in other glomeruli can be present.

Collapsing Variant (Collapsing Glomerulopathy)

The podocyte expresses a dysregulated phenotype with increased rate of proliferation and loss of mature podocyte markers including synaptopodin, WT-1, podocalyxin, GLEPP-1 (glomerular

JAYPEE BROTHERS

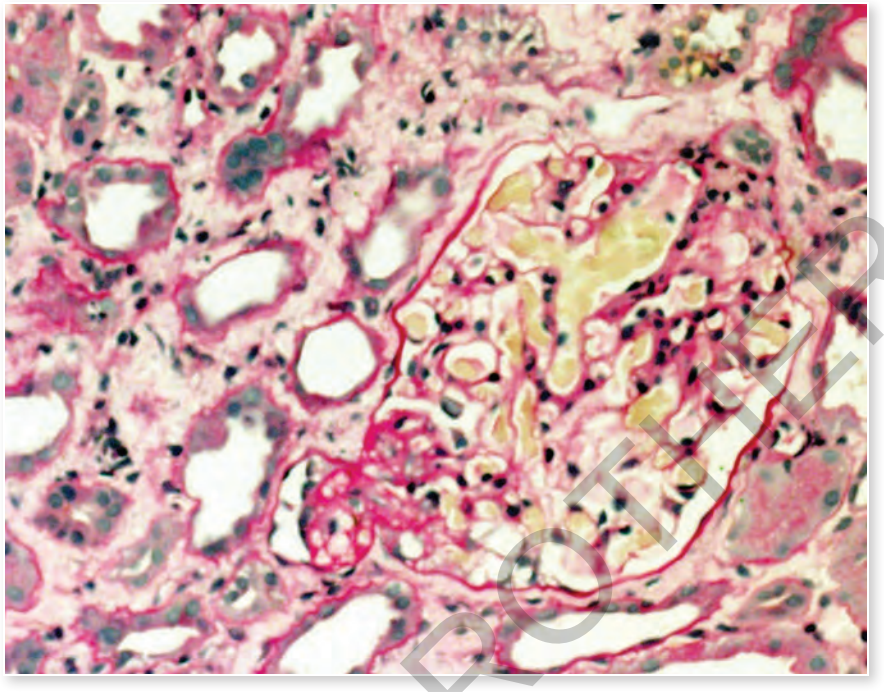

Figure 4.9: FSGS—tip variant (H&E x 200)

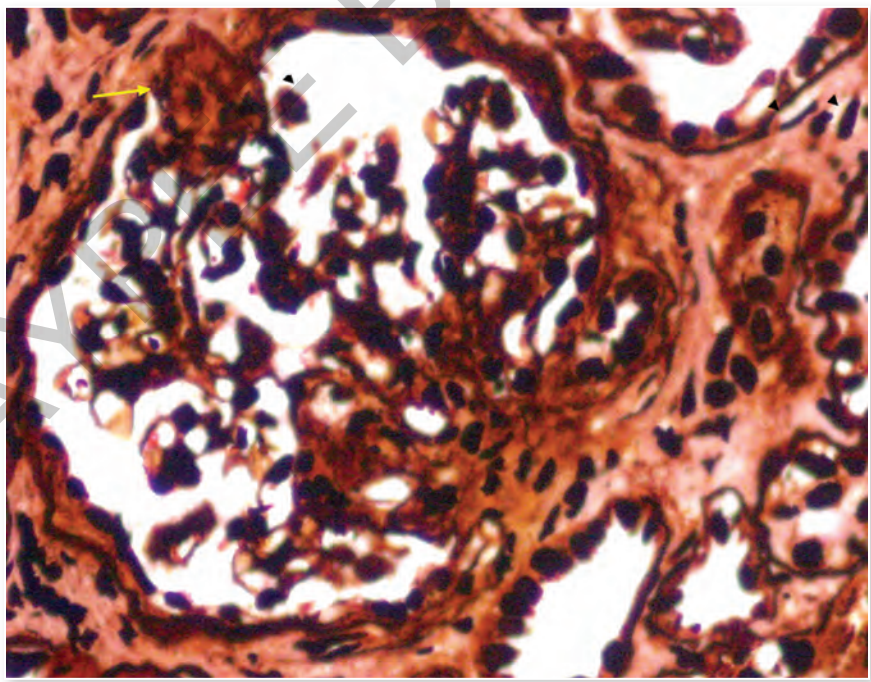

Figure 4.10: FSGS—tip variant (JMS x 400, arrow)

JAYPEE BROTHERS

epithelial protein), C3b receptor and CALLA (CD10), and re-expression of proliferative markers and cytokeratins. As the podocytes re-enter the cell cycle, there is associated reduced expression of cell cycle inhibitors.[14-17]

Microscopic Features

- Implosive wrinkling and collapse of glomerular basement membrane (on the PAS and Jones methenamine stains) of at least one glomerulus (Fig. 4.11)
- Segmental or global obliteration of capillary lumina
- No appreciable increase in intracapillary or mesangial matrix
- Marked podocyte hypertrophy and hyperplasia, forming "pseudocrescents"
- Comprised of discohesive rounded cells (not spindled) devoid of pericellular matrix
- Detached from intact Bowman's capsule
- Enlarged podocytes have vesicular nuclei and prominent nucleoli
- Occasional binucleate forms and mitoses are found
- Pseudocrescents contain prominent intracytoplasmic protein resorption droplets.

Immunohistochemistry: Negative for WT-1, positive for Ki67, PAX2 and cytokeratins (CK8, 18, CK19 and CAM 5.2).

Collapsing glomerulopathy can be idiopathic, reactive, secondary to HIV nephropathy or other viral infections, including parvovirus B19, CMV, bacterial and parasitic infections, autoimmune diseases (SLE, mixed connective tissue disease), thrombotic microangiopathy, hematologic malignancy, drugs (interferon, biphosphonates, valproic acid, calcineurin inhibitors) or associated with genetic mutations with dysregulation of mitochondrial activity.

Electron Microscopy

- Folded, corrugated, collapsed GBM with occlusion of capillary lumen
- Focal detachment of podocytes with interposed matrix
- Extensive foot process effacement
- Loss of primary processes
- Cuboidal podocytes with pale cytoplasm and protein reabsorption droplets
- Loss of fenestration of endothelial cells.

Prognosis

The collapsing variant has a rapid rate of progression to end stage renal disease when compared to the tip variant, which is an early lesion and the cellular variant that has an intermediate prognosis. The outcome of the perihilar and NOS variants depends on the degree of interstitial fibrosis rather than the percentage of glomerular involvement by segmental/global scars, which does not have an independent predictive value.

Differential Diagnosis[1,18,19]

Secondary Focal Segmental Glomerulosclerosis

It is caused by numerous factors such as:

JAYPEE BROTHERS

r detailed information on pathology books, visit our website **www.jaypeebrothers.com,** for detailed information on pathology books, visit our websi

Renal Biopsy Interpretation

Salient Features

- Renal biopsy interpretation requires skill and diagnostic expertise
- The author's vast experience describes in detail the current perspectives, recent classifications and elucidation of renal biopsies
- Well illustrated with excellent photomicrographs
- Excellent referral book for postgraduate, pathology, nephrology students, and consultants who wish to specialize in renal pathology.

Anila Korula MBBS MD (Pathology) is Professor, Department of Pathology, Pushpagiri Institute of Medical Sciences, Thiruvalla, Kerala, India. She graduated from the Madras Medical College in 1978 and for her postgraduation joined the Christian Medical College (CMC), Vellore, Tamil Nadu, India in 1981. On completion of her MD (Pathology) training, she continued to work at the Norman Institute of Pathology in CMC for 35 years. She served as Professor and Head, Department of Pathology, CMC, Vellore from 2006 to 2010. During her tenure, she had opportunities for further experience in Australia and New Zealand for 3 years.

She has been involved in reporting renal biopsies and teaching Nephropathology to medical students and Pathology and Nephrology DM postgraduates for the past 26 years. She has been an undergraduate and postgraduate examiner in pathology in The Tamil Nadu Dr MGR Medical University, Chennai, Tamil Nadu. She has participated in several national workshops and conferences in renal pathology. She has also published numerous articles in reputed national and international journals. Several renal pathologists in the country have been trained and mentored by her.

Available at all medical bookstores
or buy online at www.jaypeebrothers.com



JAYPEE BROTHERS
Medical Publishers (P) Ltd.
www.jaypeebrothers.com

Join us on facebook.com/JaypeeMedicalPublishers

Shelving Recommendation
PATHOLOGY

