ypeebrothers.com, for detailed information on radiology books, visit our website www.jaypeebrothers.com, for detailed information on radiology books

Celebrating 50 YEARS
Passion, Quality and Innovation in Healthcare Publishing

Musculoskeletal Ultrasound Teaching Files

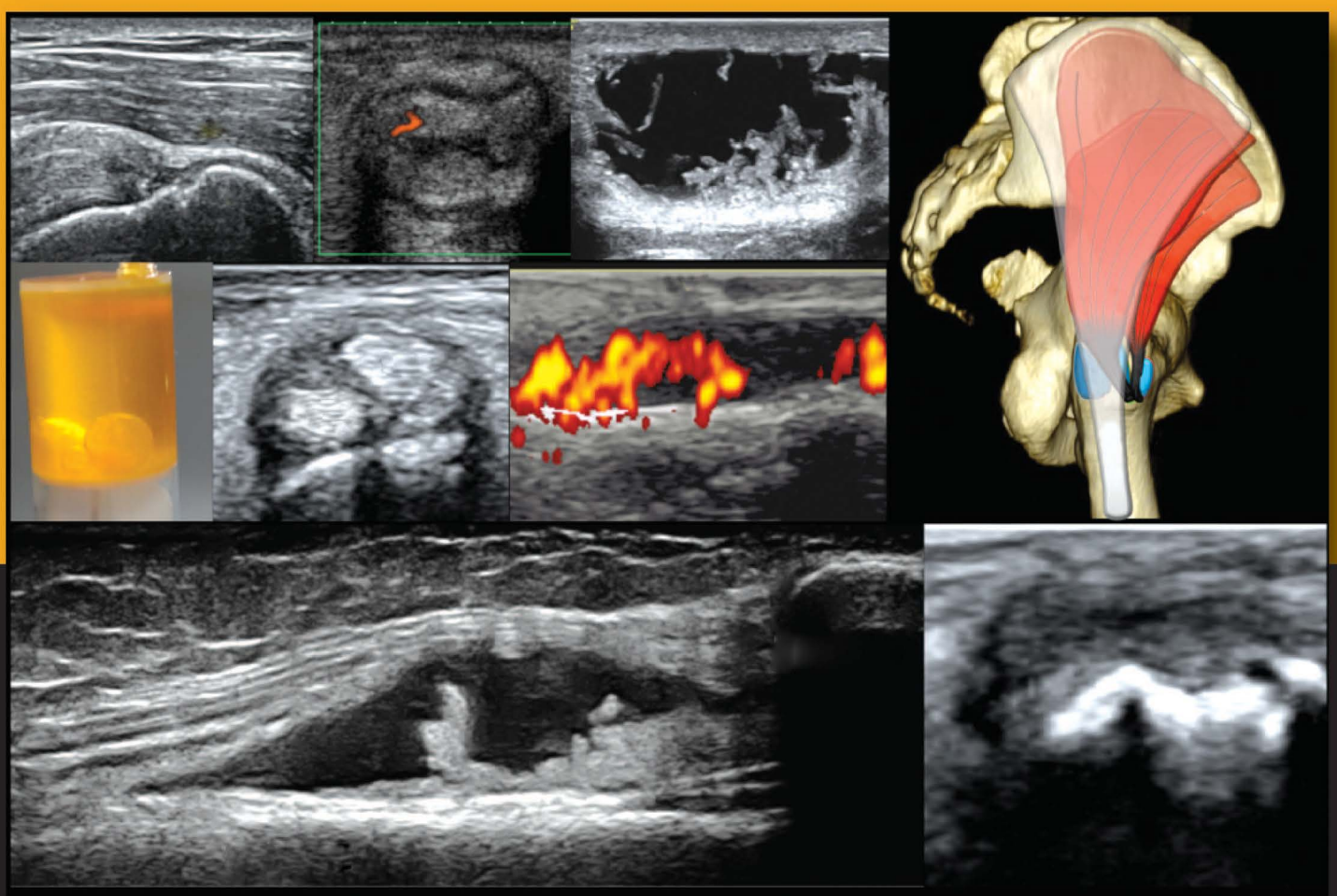

Bipin R Shah
Ankit B Shah

Foreword
Nidhi Bhatnagar

JAYPEE

CONTENTS

CASES

1. Subacromial Impingement of the Rotator Cuff 1
2. Partial-thickness Articular Surface Tear of the Rotator Cuff 4
3. Full-thickness Tear of the Rotator Cuff 7
4. Postoperative Retear of the Supraspinatus Tendon 10
5. Calcific Tendinosis of the Rotator Cuff 12
6. Subacromial-subdeltoid Bursal Inflammation 15
7. Tear of the Subscapularis Tendon 18
8. Tear of the Long Head of Biceps 20
9. Tenosynovitis of the Biceps Tendon Sheath 24
10. Adhesive Capsulitis of Shoulder 25
11. Paralabral Cyst with Suprascapular Nerve Entrapment 29
12. Acromioclavicular Joint Dislocation 32
13. Traumatic Fat Necrosis 34
14. Radial and Ulnar Nerve Injury 36
15. Stretch Injury of the Radial Nerve 39
16. Intramuscular Cysticercosis of the Triceps Muscle Belly 41
17. Ulnar Nerve Neuritis 43
18. Olecranon Bursitis 44
19. Bicipitoradial Bursitis 46
20. Tennis Elbow 48
21. Calcific Tendinosis Involving the Common Flexor Origin 51
22. Subcutaneous Rheumatoid Nodule 53
23. Chronic Partial-thickness Tear of the Triceps Muscle 55
24. Osseous Avulsion Injury of Triceps Tendon 57
25. Distal Biceps Tendon Tear 59
26. Partial-thickness Tear of the Ulnar Collateral Ligament of the Elbow 60
27. Myositis Ossificans 61
28. Volar Wrist Ganglion 63
29. Carpal Tunnel Syndrome 65
30. Fibrolipomatous Hamartoma of the Median Nerve 68

31. Peripheral Nerve Sheath Tumor of the Median Nerve 71
32. Tenosynovitis of the Flexor Tendon Sheath at the Wrist Joint 73
33. De Quervain's Tenosynovitis 74
34. Attritional Tear of Extensor Tendon at the Wrist due to Chronic Impingement 77
35. Inflammatory Tenosynovitis of Extensor Compartment IV Tendon Sheath at the Wrist Joint 78
36. Epidermal Inclusion Cyst 81
37. Trigger Finger 83
38. Trigger Thumb 85
39. Crystal Deposition Disease 86
40. Ganglion Arising from the A2 Pulley 88
41. Nodular Thickening of the A2 Pulley in a Known Case of Rheumatoid Arthritis 89
42. Inflammatory Synovitis Involving the Metacarpophalangeal Joint 90
43. Tenosynovitis with Tendinosis of the Flexor Tendons of the Finger due to a Retained Foreign Body 94
44. Traumatic Full-thickness Tear of Flexor Digitorum Profundus Tendon 96
45. Traumatic Full-thickness Tear of Extensor Pollicis Longus Tendon 97
46. Giant-cell Tumor of Flexor-tendon Sheath of a Finger 98
47. Giant-cell Tumor of Extensor Tendon of Finger 99
48. Subungual Glomus Tumor 101
49. Glomus Tumor 103
50. Avulsion Injury of Ulnar Collateral Ligament Injury of Thumb 104
51. Acute Partial-thickness Tear of the Adductor Muscles 106
52. Greater Trochanteric Bursitis 108
53. Partial-thickness Tear of Gluteus Medius Tendon 110
54. High-grade Partial Thickness Hamstring Tear with Hematoma 113
55. Partial-thickness Tear of the Rectus Femoris with Hematoma 116
56. Acute Synovitis of the Right Hip 118
57. Prepatellar Bursitis 119
58. Superficial Infrapatellar Bursitis 122
59. Sessile Exostosis 124
60. Jumper's Knee 126
61. Full-thickness Tear of the Patellar Tendon 128
62. Full-thickness Tear of the Quadriceps Tendon 130
63. Effusion in the Suprapatellar Recess 132
64. Effusion in the Suprapatellar Recess with Lipoma Arborescens 134
65. Baker's Cyst with Synovitis 135

66. Baker's Cyst **137**
67. Tennis Leg **138**
68. Herniation of the Tibialis Anterior Muscle **140**
69. Morel-Lavallée Lesion **142**
70. Tendinosis of the Achilles Tendon with an Interstitial Tear **144**
71. Chronic Partial-thickness Tear of the Achilles Tendon **147**
72. Full-thickness Tear of Achilles Tendon **149**
73. Insertional Calcific Tendinosis of Achilles Tendon **151**
74. Retrocalcaneal Bursitis **152**
75. Haglund's Syndrome **153**
76. Tear of the Anterior Talofibular Ligament **154**
77. Chronic Tophaceous Gout **156**
78. Interstitial Tear of the Tibialis Posterior Tendon with Tenosynovitis **159**
79. Interstitial Tear of Peroneus Brevis Tendon **162**
80. Foreign Body Granuloma **164**
81. Pyomyositis **165**
82. Plantar Fasciitis **166**

Index *169*

Case 4

Postoperative Retear of the Supraspinatus Tendon

CLINICAL HISTORY

A middle-aged man presented with persistent left shoulder pain during abduction of the arm. He was operated for a full-thickness tear of the rotator cuff 4 years ago.

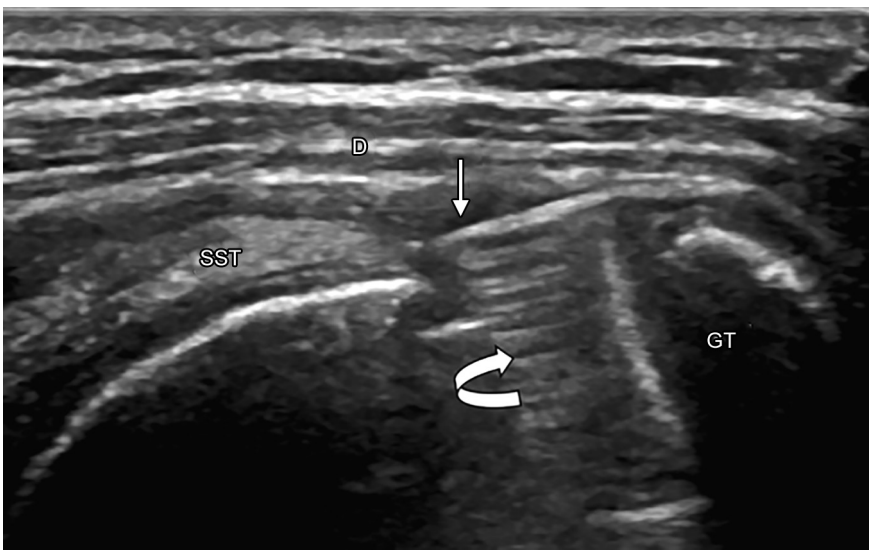

Fig. 1: Complete discontinuity of the supraspinatus tendon (SST) fibers suggests a recurrent tear (straight arrow). The anchor (curved arrow) is well embedded within the greater tuberosity (GT). (D: deltoid muscle)

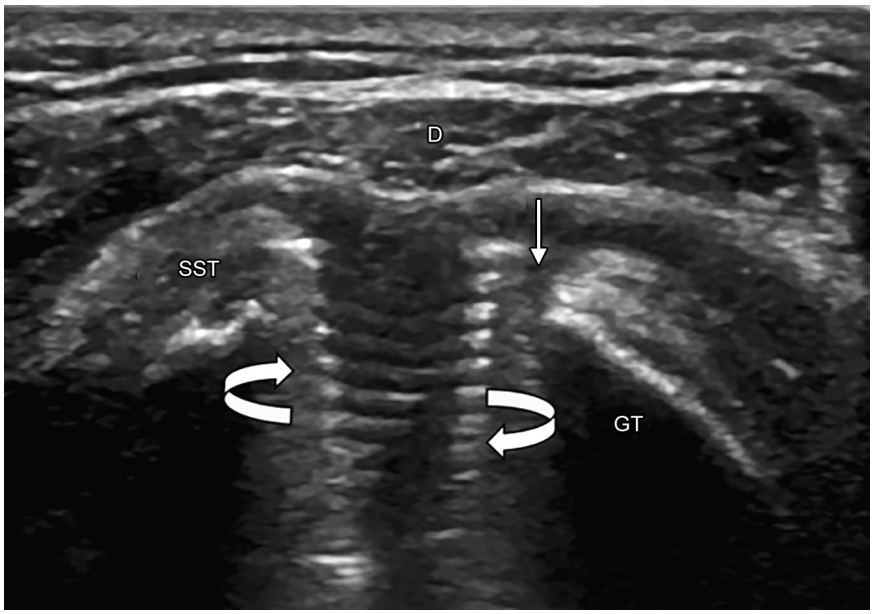

Fig. 2: Transverse images show the deltoid muscle (D) herniating within the defect caused by the recurrent tear (straight arrow) of the supraspinatus tendon (SST). The anchors are depicted by the curved arrows. (GT: greater tuberosity)

DIAGNOSIS

Full-thickness retear of the supraspinatus tendon.

DISCUSSION

- The incidence of cuff failure following a rotator-cuff repair ranges from 14% to 94%.[1]
- Absence of artifacts from the metallic implants and dynamic imaging make ultrasound (US) an ideal modality for evaluation of the postoperative cuff.
- Heterogeneous echotexture of the rotator cuff is a normal postoperative finding. This finding may persist for months to years after the surgery.
- Recurrent tears are diagnosed on US on the basis of partial- or full-thickness defects within the cuff at the site of tendon repair along the greater tuberosity (Figs. 1 and 2).

REFERENCE

1. Bishop J, Klepps S, Lo IK, et al. Cuff integrity after arthroscopic versus open rotator cuff repair: a prospective study. J Shoulder Elbow Surg. 2006;15:290-9.

for detailed information on radiology books, visit our website **www.jaypeebrothers.com,** for detailed information on radiology books, visit our website

Musculoskeletal Ultrasound Teaching Files

Salient Features

- Covers a spectrum of important musculoskeletal pathologies that are commonly encountered in day-to-day practice
- Includes the high-resolution images
- Emphasizes on the practical information that should be incorporated in the musculoskeletal ultrasound report so as to benefit the referring orthopedic surgeons or rheumatologists.



Bipin R Shah MD DMRD DMRE is Director, Eclat Polyclinic, Lifescan Imaging and Gray Scale Imaging, Mumbai, Maharashtra India. He is currently the President of Musculoskeletal Ultrasound Society (MUS). He has served as the Head, Department of Imaging, KB Bhabha Hospital and has a vast teaching experience of 33 years. He has been practicing cross-sectional imaging and musculoskeletal ultrasound in India for more than 25 years and has been regarded as a pioneer in musculoskeletal ultrasound. His current interests include musculoskeletal ultrasound and musculoskeletal MRI and CT. He has previously authored the book *Step by Step Sonography of the Shoulder Joint*, which was well received. He is an acclaimed national and international speaker and contributes to multiple CME programs.



Ankit B Shah DNB MD PG Dip MSK Ultrasound (UCAM-Spain) is the Consultant Radiologist, Eclat Polyclinic and Gray Scale Imaging, Mumbai, Maharashtra, India. After completing his postgraduation in Radiodiagnosis, he has worked at KB Bhabha Hospital, Lifescan Imaging and Gray Scale Imaging. He has done a short-term Fellowship in Neuroradiology, Henry Ford Hospital, Detroit, Michigan, USA. He holds a Postgraduate Diploma Fellowship in Musculoskeletal Ultrasound conducted by Universidad Católica de Murcia (UCAM), Spain. He has keen interest in musculoskeletal imaging and has been closely working with Dr Bipin R Shah. He has presented many posters and scientific papers on musculoskeletal imaging in radiologic and orthopedic national and international conferences. He is currently an integral part of the national faculty for musculoskeletal ultrasound teaching programs conducted by UCAM, Spain.

Available at all medical bookstores
or buy online at www.jaypeebrothers.com

JAYPEE BROTHERS
Medical Publishers (P) Ltd.
www.jaypeebrothers.com

Join us on facebook.com/JaypeeMedicalPublishers

Shelving Recommendation
RADIOLOGY

ISBN 978-93-5270-683-9
9 789352 706839