our website www.jaypeebrothers.com, for detailed information on dermatology books, visit our website www.jaypeebrothers.com

JAYPEE

Celebrating 50
Passion, Quality and Innovation in Healthcare Publishing

Case-based Reviews in Dermatology



Editor
Rashmi Sarkar

Co-Editors
Anupam Das
Isha Narang
Indrashis Podder

Content

1. **Oral Ulcers with Joint Pains** 1
   Sanjeev Handa, Sheetanshu Kumar

2. **Genital Ulcer** 28
   Somodyuti Chandra, Nilay Kanti Das

3. **Generalized Pruritus** 43
   Debabrata Bandyopadhyay

4. **Diffuse Hyperpigmentation** 57
   Komal Agarwal, Anupam Das, Rashmi Sarkar

5. **Fever with Rash in a Child** 72
   Nitin Nadkarni, Aayushi Mehta

6. **Nerve Thickening with or without Hypoesthetic Patch** 80
   Mala Bhalla, Kavita Poonia

7. **Papulonodular Lesions of Face** 96
   Anupam Das, Anand Toshniwal

8. **Vesiculopustular and Bullous Disorders in Children** 104
   Indrashis Podder, Rashmi Sarkar

9. **Vesiculobullous Disorder in Middle Age** 121
   Monica Chahar, Paschal D'Souza, Lalit K Gupta, Sudheer Kumar

10. **Erythroderma** 149
    Vijay P Zawar, Shrikant Kumavat

11. **Vaginal Discharge** 156
    Poonam Puri, Sushruta Kathuria

12. **Urethral Discharge** 172
    Taru Garg, Mahima Agrawal

13. **Granulomatous Disorders** 183
    Geeti Khullar, V Ramesh

JAYPEE BROTHERS

14. Diffuse Hair Loss **196**
Bela J Shah, Deval B Mistry

15. Scalp Pruritus **207**
Poonam Puri, Sushruta Kathuria

16. Facial Melanosis **219**
Rashmi Sarkar, Isha Narang, Bhavya Swarnkar

Index **233**

JAYPEE BROTHERS

CHAPTER 7

Papulonodular Lesions of Face

Anupam Das, Anand Toshniwal

INTRODUCTION

Papulonodular lesions of the face always pose an enigma to a dermatologists as various infectious, benign and malignant etiologies can manifest in this form. The final diagnosis is achieved by an accurate cutaneous and systemic examination and noting the age, mode of onset and morphology of the predominant lesions as well as by, dermoscopy. The final confirmative clincher is the histopathological examination.

CASE 1

A 23-year-old female presented with multiple asymptomatic skin colored papulonodules on face since 5 years of age (Fig. 1). Patient was otherwise healthy without any systemic complaints. Family history was insignificant. On cutaneous examination multiple dome shaped yellowish waxy appearing nodules predominantly affecting the T-area (pericentral) area of face were seen. Radiological examination was normal. Biopsy was done and the histopathological examination revealed keratinized stratified squamous epithelium overlying proliferating packets of basaloid cells with hyperchromatic nuclei, along with several keratin horn cysts and moderate stroma infiltrate of chronic inflammatory cells. Based on clinical and histopathological examination a diagnosis of trichoepithelioma was made.

Case Review in Nutshell

Papulonodular lesions on face pose a diagnostic dilemma as it could be an underlying long standing infectious disease or a genodermatosis. Based on the age of onset and clinical examination the following differentials were considered:

- Trichoepithelioma
- Trichilemmoma
- Steatocystoma.

Trichoepithelioma was considered the first differential considering the age of onset and waxy yellowish hue nodules involving pericentral areas of face with basaloid cells and keratin horn cysts supporting the same.

JAYPEE BROTHERS



Fig. 1: Multiple trichoepitheliomas affecting the face.

Trichilemmomas are solitary or multiple skin colored papules seen on face. Multiple are seen in Cowden syndrome, wherein they are associated with oral papillomatosis and acral keratosis. On histopathological examination, plate like growth of pale pink glassy cells with palisading at the periphery is observed.

Steatocystomas are yellowish papulonodules seen mainly at puberty with trunk and face predominantly involved. On histopathological examination it shows empty cyst lined by squamous epithelium and minimal granular cell layer. Sebaceous glands are found adjacent to cyst.

Thus, on the basis of clinical and histopathological findings, a diagnosis of trichoepithelioma was made. The benign nature of the disease was explained and surgical excision was advised for cosmetic concern.

CASE 2

A 36-year-old female patient came with complaints of asymptomatic nodules around eyes for 5 years (Fig. 2). She had a similar lesion 8 years back which she got excised. Lesions were gradually progressive in nature. Family history was nil significant with no other systemic complaints. Cutaneous examination revealed soft to firm nontender yellowish brown nodules involving the infraorbital area, not fixed to underlying tissues. There was no hepatosplenomegaly and lymphadenopathy. On investigations she was found to have a normal lipid profile, raised lactate dehydrogenase and immunoglobulin G1 (IgG1) spike on electrophoresis. Radiological examination revealed no abnormalities. Biopsy was done. Histopathological examination revealed unremarkable epidermis with dermis showing unencapsulated lesion comprising sheets of nodular collections of large foamy histiocytes admixed with lymphoplasmacytic infiltrate with extensive areas of hyaline necrobiosis. Touton and foreign body giant cells were also seen. Based on the clinical and histopathological correlation, diagnosis of necrobiotic xanthogranuloma was made.

JAYPEE BROTHERS



Fig. 2: Necrobiotic xanthogranuloma.

Case Review in Nutshell

Papulonodular lesions around the eye are usually misdiagnosed and treated as xanthelasma and may not receive proper investigations and follow-up. In the above case the following differentials were considered:

- Necrobiotic xanthogranuloma
- Necrobiosis lipoidica
- Diffuse xanthoma.

Necrobiotic xanthogranuloma was considered as a differential based on the clinical appearance of nodules, slow progression and IgG spike on electrophoresis which can be seen in necrobiotic xanthogranuloma associated with monoclonal gammopathy. The histopathological examination also showed necrobiosis with Touton giant cells and lymphoplasmacytic infiltrate with foamy cells.

Necrobiosis lipoidica in its atypical presentation involves the periorbital area. On histopathological examination it shows predominant involvement of septa and cholesterol clefts. Atypical giant cells, foam cells and dense infiltrate is absent.

Diffuse xanthoma usually presents as yellowish plaques and nodules. On histopathological examination it would reveal large sheets of foamy cells present throughout dermis and absence of Touton giant cells.

On the basis of clinical and histopathological correlation a diagnosis of necrobiotic xanthogranuloma was made and a complete surgical excision was done with regular follow-up every 6 months. No recurrence has been reported yet.

INTERACTIVE TOPIC REVIEW

Q.1 How to classify the causes of papulonodular lesions of face?

Ans: **Infections**

Molluscum contagiosum, tinea faciei, demodicosis, lupus vulgaris, Hansen's diseases, leishmaniasis, verruca vulgaris.

JAYPEE BROTHERS

Inflammatory Disorders

Acne vulgaris, Acne rosacea, lupus miliaris disseminatus faciei, sarcoidosis, facial Afro-Caribbean childhood eruption, perioral dermatitis, follicular mucinosis, Peli incarniti.

Differentials for normal surfaced eythematous papules is described in Flowchart 1.

Tumors

- Benign epidermal tumors and cysts: Milia, dermatosis papulosa nigra, keratoacanthoma, seborrheic keratosis
- Premalignant: Actinic keratosis, cutaneous horn
- Malignant: Basal cell carcinoma, squamous cell carcinoma, lymphoma, metastasis.

Tumors of Skin Appendages

- Eccrine gland: Syringoma, eccrine hidrocystoma
- Apocrine gland: Syringocystadenoma papilliferum
- Sebaceous gland: Sebaceous hyperplasia, sebaceoma, sebaceous adenoma
- Hair follicle mesenchyme: Trichodiscoma
- Hair follicle: Dilated pore of winer, trichoadenoma
- External root sheath: Trichilemmoma
- Hamartomas: Trichofolliculoma, trichoepithelioma
- Soft tissue tumors: Fibrous papule of nose, atypical fibroxanthoma
- Others: Granuloma faciale, angiofibroma, colloid milia, keratosis pilaris, lichen planus, lichen nitidus, dermatofibroma, hemangioma, palisaded encapsulated neuroma, pilomatrixoma, xanthoma.

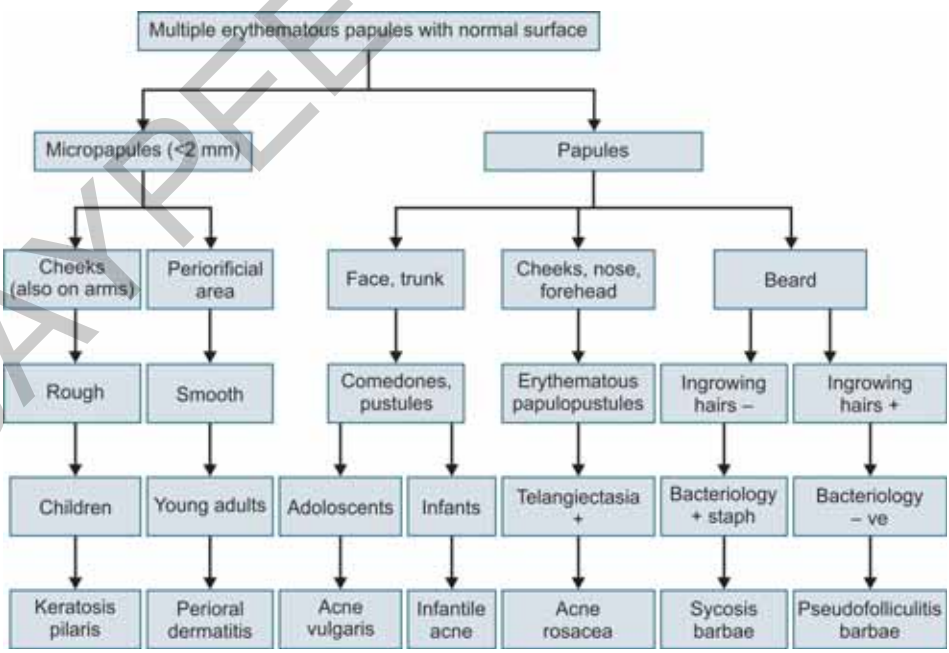

Flowchart 1: Differentials for normal surfaced erythematous papules.

JAYPEE BROTHERS

Q.2 What are the differentials for colored papules on face?

Ans:
- White papules: Molluscum contagiosum, cutaneous calculus, milia, closed comedones
- Brown papules: Compound nevus, seborrheic keratosis, pigmented basal cell carcinoma, nodular melanoma, plane warts
- Black papules: Dermatosis papulosa nigra, seborrheic keratosis, melanoma, trichostasis spinulosa
- Purple: Kaposi's sarcoma
- Blue: Blue nevus, apocrine hidrocystoma
- Skin/yellowish papules: Xanthoma, necrobiotic xanthogranuloma, fibrous papule of nose, keratosis pilaris, histoid Hansen's, post-kala-azar dermal leishmaniasis, angiofibromas, syringomas, etc.

Q.3 What is the significance of the surface of papulonodular lesions on face?

Ans:
- Pigmented and hairy: Congenital melanocytic nevus
- Crusted surface: Actinic keratosis, Bowen's disease, basal cell carcinoma, leishmaniasis, lupus vulgaris
- Smooth dome shaped: Intradermal nevus, compound nevus, colloid milia, apocrine hidrocystoma
- Flat topped papules: Plane warts, syringomas, trichilemmomas.

Q.4 What are syndromes associated with papulonodular lesions of face?

Ans:
- Brooke-Spiegler syndrome: Multiple cylindromas with trichoepitheliomas
- Birt–Hogg-Dubé syndrome: Fibrofolliculomas, trichodiscomas, acrochordons
- Cowden syndrome: Trichilemommas, oral papillomas, palmar keratosis, epidermal nevi, macrocephaly
- Rombo syndrome: Multiple milia, atrophoderma vermiculatum, telangiectasias, basal cell carcinoma
- Basaloid follicular hamartoma syndrome: Multiple milia, comedone like or dermatosis papulosa nigra like follicular lesions, hypotrichosis, palmar pits
- Muir–Torre syndrome: Gastrointestinal malignancy, Sebaceous adenoma, keratoacanthoma
- Grzybowski syndrome: Keratoacanthoma like papules, ectropion, hoarseness of voice, perioral papules
- Bourneville's syndrome: Adenoma sebaceum, Shagreen patch, fibrous plaque, Koenen tumors
- Bazex–Dupré-Christol syndrome: Multiple basal cell carcinomas, follicular atrophoderma, milia, hypotrichosis, hypohidrosis
- Apert syndrome: Acne vulgaris, syndactyly, craniosynostosis, crowded teeth, cleft palate.

Differentials for skin-colored nodules on face is described in Flowchart 2. Differentials for skin-colored papules on face is described in Flowchart 3.

Q.5 What are dermoscopic findings of common papulonodular lesions of face?

Ans:
- Blue nevus: Homogenous blue or bluish white
- Intradermal nevus: Globular homogeneous pattern

JAYPEE BROTHERS

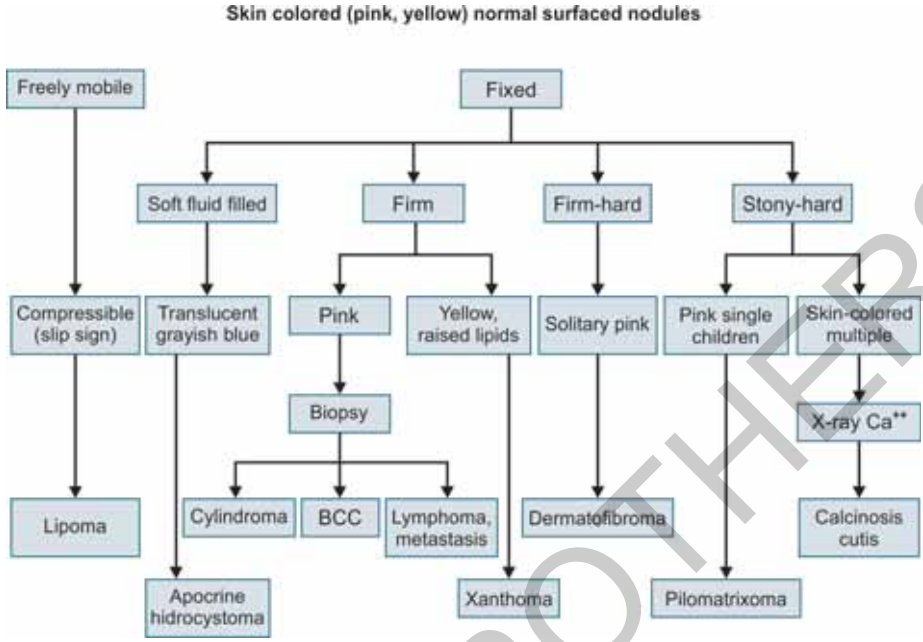

Flowchart 2: Differentials for skin-colored nodules on face.

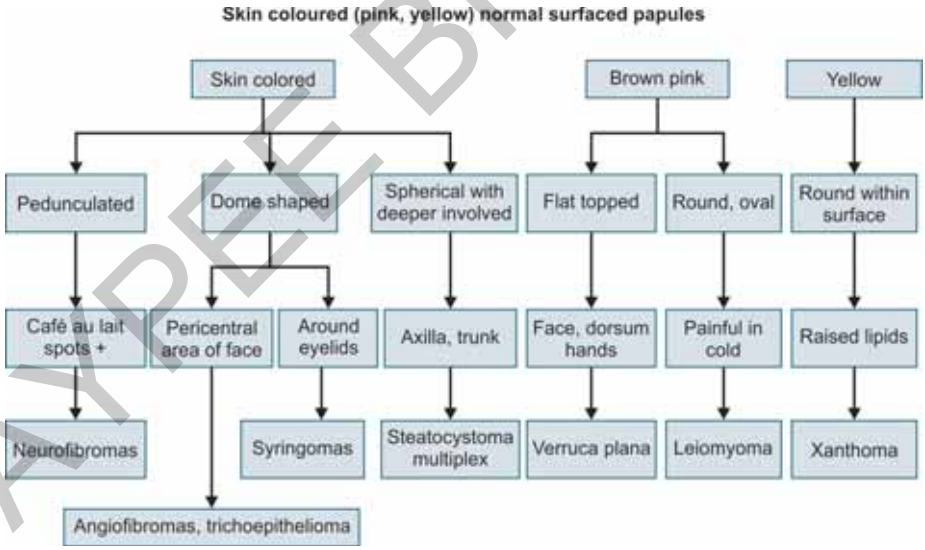

Flowchart 3: Differentials for skin-colored papules on face.

- Seborrheic keratosis: Sharply demarcated borders, milia-like cysts, comedo-like openings, ridges, fissures and hairpin vessels surrounded by a halo
- Sebaceous hyperplasia: Yellow to yellow white lobular structures; crown vessels or linear winding serpentine vessels at the periphery of the lesion that radiate toward the center

JAYPEE BROTHERS

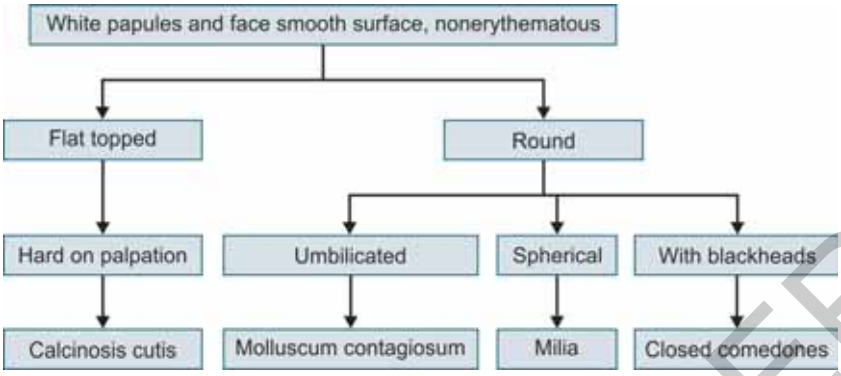

Flowchart 4: Differentials for white-colored papules on face.

- Granuloma faciale: White gray background with whitish streaks and elongated telangiectasia
- Sarcoidosis: Yellowish orange structure less globular area with linear vessels
- Lupus vulgaris: Fine yellowish gold background with telangiectasias and few milia-like cysts
- Actinic keratosis: Erythema with a pink to red pseudonetwork surrounding the hair follicles; fine, linear wavy vessels surrounding the follicular openings; and follicles with yellowish keratotic plugs
- Basal cell carcinoma: Leaf-like structures; multiple nonaggregated blue gray dots or blue globular structures, spoke wheel like structures, serpentine branched vessels, absence of pigmented network.

Differentials for white-colored papules on face as described in Flowchart 4.

Q.6 How do you approach a case of papulonodular lesions of face?

Ans: **History**

Age of Onset

- Infancy: Hemangioma
- Children: Lichen nitidus, pilomatrixoma
- Adults: Basal cell carcinoma.

Duration

- Acute: Tinea facei
- Chronic: Lupus vulgaris.

Evolution

- Sudden: Eruptive syringomas, acne vulgaris
- Gradual: Acne agminata, pseudolymphoma.

Mucosal Lesions

- Lichen planus, papular xanthoma, Cowden syndrome, Darier's disease.

Triggering Factors

- Sunlight: Polymorphic light eruption, acne rosacea.

JAYPEE BROTHERS

Photosensitivity

- Photoallergic contact dermatitis, polymorphic light eruption.

Systemic Complaints

- Joint pains: Acne fulminans, lymphoma
- Lymphadenopathy, pulmonary symptoms: Sarcoidosis.

Cutaneous Examination

Morphology of lesions, color, size, surface, shape, symmetry, distribution of lesions, diascopy, dermoscopy. Biopsy and relevant systemic investigations.

CONCLUSION

Papulonodules on the face require a holistic approach as it could be a manifestation of a spectrum of diseases ranging from infectious etiology to malignancy. A detailed clinical examination to look out for any associated systemic involvement and the use of dermoscope would be useful to obviate the need for biopsy in certain scenarios although histopathology would be the gold standard for confirmation.

KEY POINTS

- Always look for the colour, surface, shape, size and number of lesions along with examination of lymph nodes
- Dermoscopy is an invaluable tool and recognition of vascular, keratin pattern would help to differentiate benign from malignant lesions
- Acute erythematous lesions tend to be benign or infectious etiology and the chronic lesions tend to be towards granulomatous or malignant etiology
- Systemic fungal infections should be borne in mind while dealing with sudden evolution of lesions with associated immunosuppresion.

SUGGESTED READING

1. Ardigo M, Zieff J, Scope A, et al. Dermoscopic and reflectance confocal microscope findings of trichoepithelioma. Dermatology. 2007;215:354-8.
2. Char DH, LeBoit PE, Ljung BM, et al. Radiation therapy for ocular necrobiotic xanthogranuloma. Arch Ophthalmol. 1987;105:174-5.
3. Giacomel J, Zalaudek I. Dermoscopy of superficial basal cell carcinoma. Dermatol Surg 2005;31:1710-3.
4. Harada H, Hashimoto K, Ko MS. The gene for multiple familial trichoepithelioma maps to chromosome 9p21. J Invest Dermatol. 1996;107:41-3.
5. Mehregan DA, Winkelmann RK. Necrobiotic xanthogranuloma. Arch Dermatol. 1992;128:94-100.
6. Mohammadi AA, Jafari SMS. Trichoepithelioma: A rare but crucial dermatological issue. World J Plast Surg. 2014;3:142-5.
7. Rajesh G, Thappa DM, Jaisankar TJ, et al. Spectrum of seborrheic keratoses in south Indians: A clinical and dermoscopic study. Ind Dermatol Venereol Leprol. 2011;77:483-8.
8. Wood AJ, Wagner MV, Abbott JJ, et al. Necrobiotic xanthogranuloma: A review of 17 cases with emphasis on clinical and pathologic correlation. Arch Dermatol. 2009;145:279-84.
9. Zalaudek I, Kreusch J, Giacomel J, et al. How to diagnose nonpigmented skin tumors: A review of vascular structures seen with dermoscopy Part I. Melanocytic skin tumors. J Am Acad Dermatol. 2010;63:361-74.

JAYPEE BROTHERS

for detailed information on dermatology books, visit our website **www.jaypeebrothers.com,** for detailed information on derma

Case-based Reviews in Dermatology

Key Features

- The book is a novel attempt focusing on the methodology of approaching case scenarios in dermatology
- Evidence-based approach to the treatment of various uncommon dermatological conditions
- Each chapter starts with an interesting case, followed by a review of the disease entity in the form of relevant question and answer format
- It is an important source of learning the basics of clinical dermatology, co-relates the clinical findings and the laboratory investigations for disease diagnosis and management
- Presented in a reader-friendly manner, written by experts having extensive research and clinical experience
- The book is a valuable resource for dermatologists, physicians and postgraduate students.

Rashmi Sarkar MD MNAMS
Professor of Dermatology, STD and Leprosy
Maulana Azad Medical College and
Lok Nayak Jai Prakash Narayan Hospital
New Delhi, India

Anupam Das MD
Assistant Professor
Department of Dermatology
KPC Medical College and Hospital
Kolkata, West Bengal, India

Isha Narang MD (MAMC) MRCP (SCE)
Specialist Registrar (Dermatology)
University Hospitals of Derby and Burton
United Kingdom

Indrashis Podder MD DNB
RMO cum Clinical Tutor
Department of Dermatology
College of Medicine and Sagore Dutta Hospital
Kolkata, West Bengal, India

Available at all medical bookstores
or buy online at www.jaypeebrothers.com



JAYPEE BROTHERS
Medical Publishers (P) Ltd.
www.jaypeebrothers.com

Join us on facebook.com/JaypeeMedicalPublishers

Shelving Recommendation
DERMATOLOGY

