ophthalmology books, visit our website **www.jaypeebrothers.com,** for detailed information on ophthalmology book

OPHTHALMOLOGY

VOLUME 14



Recent Advances in OPHTHALMOLOGY

Editors
HV Nema
Nitin Nema



Contents

1. Management of Post-LASIK Ectasia **1**
Partha Biswas, Sneha Batra

- Epidemiology *1*
- Presenting Features *2*
- Investigations Helpful in the Diagnosis of PLE *2*
- Risk Factors for PLE *5*
- Pathogenesis *9*
- Histopathology *11*
- Management *12*
- Prevention *16*

2. Recent Advances in Lamellar Keratoplasty **23**
Casey J Randleman, Soosan Jacob

- Recent Advances in Endothelial Keratoplasty *23*
- Recent Advances in Anterior Lamellar Keratoplasty *32*

3. Keratopigmentation: An Innovative Surgical Option for Therapeutic and Cosmetic Purposes **39**
Olena Al-Shymali, Alejandra E Rodriguez, Maria A Amesty, Jorge L Aliö

- Instruments, Pigments, and Technologies Involved in Keratopigmentation *40*
- Keratopigmentation Surgical Techniques *42*
- Indications *45*
- Ophthalmological Assessment *46*
- Contraindications to Keratopigmentation *47*
- Outcomes *48*
- Complications *49*

4. Ocular Blood Flow in Glaucoma **53**
Murali Ariga, Pratheeba Nivean, Malarchelvi Palani, Maithri Arun Kumar

- Assessment of Ocular Blood Flow *53*
- Scanning Laser Ophthalmoscopic Angiography *54*
- Color Doppler Imaging *55*
- Laser Doppler Velocimetry *57*
- Laser Doppler Flowmetry *58*
- Retinal Vessel Analyzer *58*

- Retinal Oximetry *58*
- Doppler Optical Coherence Tomography *59*
- Optical Coherence Tomography Angiography *59*
- Factors that Affect Ocular Blood Flow *62*

5. Selective Laser Trabeculoplasty **67**
Purvi R Bhagat, Shivani Dixit, Nikunj Tank
- History and Concept *67*
- Mechanism of Action *67*

6. Shunts in the Management of Intractable Glaucoma **74**
Rengaraj Venkatesh, Annamalai Odayappan, MG Pavan Kumar
- Types of Glaucoma Drainage Devices *74*
- Current Drainage Devices *77*
- Preoperative Evaluation *80*
- Choosing Glaucoma Drainage Devices *81*
- Surgical Procedure *81*
- Placement of the Tube *85*
- Site of Implantation *85*
- Use of Antifibrotics *85*
- Complications *85*

7. Recent Advances in Intraocular Lens Power Calculation **90**
Prashob Mohan, Arup Chakrabarti
- Biometry *90*
- IOL Power Calculation Formulae *100*

8. Custom Cataract Surgery **112**
Rajiv Choudhary
- Refractive Targeting *112*
- Biometry *112*
- Customization of Surgical Modality *113*
- Role of Microincisional Cataract Surgery in Customization *115*
- Intraocular Lens Selection *115*
- How to Minimize Postoperative Astigmatism and Correct Preexisting Astigmatism? *117*

9. Astigmatism Management in Cataract Surgery **123**
Gitansha Shreyas Sachdev, D Ramamurthy
- Preoperative Assessment *123*
- Posterior Corneal Astigmatism *124*
- Preoperative Corneal Marking *124*
- Surgical Methods for Treating Corneal Astigmatism *126*

10. Pseudoexfoliation Cataract: Management **135**
Prakrati Gupta, Sirisha Senthil
- Preoperative Evaluation *135*
- Pseudoexfoliation and Cataract Surgery *138*
- Postoperative Complications *143*

11. Femtosecond Laser-Assisted Cataract Surgery in Posterior Polar Cataracts **147**
Mahipal S Sachdev, Gitansha Shreyas Sachdev, Rashmi Deshmukh, Hemlata Gupta
- Posterior Polar Cataract *147*
- Femtosecond Laser-Assisted Cataract Surgery *149*

12. Posterior Capsular Rupture Recognition and Management **156**
Mohan Rajan, M Ravishankar, Sriram
- Improperly Managed Posterior Capsular Rupture *156*
- Early Signs of Posterior Capsular Rupture *156*
- Prevention of Posterior Capsular Rupture *158*

13. Phacoemulsification in Subluxated Lenses **171**
Suhas Haldipurkar, Zain Khatib
- Capsular Support Devices for Subluxated Lenses *171*
- Preoperative Workup *176*
- Surgical Procedure *177*

14. Scleral-Fixated Intraocular Lenses: A Review **184**
Meena Chakrabarti, Arup Chakrabarti
- Sutured Scleral Fixation *184*
- Sutureless Intrascleral Haptic Fixated Posterior Chamber Intraocular Lens *197*
- Postoperative Complications of Sutureless Scleral Fixation *204*
- Sutured versus Sutureless Scleral Fixation *205*

15. Message from Clinical Trials and How to Adopt them for Real Life Situations in Management of Retinal Vascular Disorders **211**
Lingam Gopal
- Efficacy versus Effectiveness *211*
- Bilateral Diabetic Macular Edema *218*
- Proliferative Diabetic Retinopathy *219*
- Retinal Vein Occlusions *220*
- Retinopathy of Prematurity *223*
- Neovascular Age Related Macular Degeneration *223*
- Dry Age Related Macular Degeneration *223*

16. Optical Coherence Tomography—Angiography in Retinal Diseases **236**
Chaitra Jayadev, Arpitha Pereira, Santosh GK Gadde
- Principle *236*
- Phase-Based Optical Coherence Tomography Angiography *237*
- Amplitude-Based Optical Coherence Tomography Angiography *238*
- Complex Signal-Based Optical Coherence Tomography Angiography *238*
- Image Processing *239*
- Optical Coherence Tomography Angiography of Normal Eyes *240*

- Artifacts *241*
- Optical Coherence Tomography Angiography of Retinal Disorders *243*

17. Optical Coherence Tomography in Diabetic Retinopathy **260**
Manila Khatri, Sandeep Saxena

- Spectral Domain-Optical Coherence Tomography Analysis in Diabetic Retinopathy *260*
- Bioimaging Biomarkers in Diabetic Macular Edema *268*

18. Necrotizing Retinopathies **274**
Rajesh Babu B, Saurabh Mistry, Sudharshan S

- Herpetic Retinitis *274*
- Historical Background *274*
- Etiology *276*
- Clinical Features *276*
- Acute Retinal Necrosis *276*
- Progressive Outer Retinal Necrosis *277*
- Surgical Management of Acute Retinal Necrosis *280*
- Cytomegalovirus Retinitis *280*
- Other Retinitis/Retinopathies *282*
- Other Rare Causes *283*

19. Nyctalopia **287**
Avinash Pathengay, Sharat Hegde, Shreyansh Doshi

- Etiology *287*
- Clinical Features of Specific Disorders causing Nyctalopia *288*
- Pathophysiology *295*
- Approach to the Patient of Nyctalopia *296*
- Treatment *296*

20. Management of Ocular Burns: A Practical Approach **302**
Jayesh Vazirani

- Emergency and Acute Phase Management *302*
- Ocular Surface Reconstruction and Vision Restoration after Severe Ocular Burns *305*

21. Cerebral Angiography in Neuro-Ophthalmology **309**
Hima Pendharkar

- Indications for Cerebral Angiography *310*
- Contraindications *310*
- Preprocedural Workup *310*
- Procedure *311*
- Complications *312*
- Advances in Cerebral Angiography: 3D-Digital Subtraction Angiography *315*
- Case Studies *317*

Index *323*

CHAPTER

2

Recent Advances in Lamellar Keratoplasty

Casey J Randleman, Soosan Jacob

JAYPEE BROTHERS

INTRODUCTION

Though penetrating keratoplasty (PK) is known to have a high success rate and is technically easy, it does carry disadvantages such as a higher risk of intraoperative complications such as expulsive hemorrhage and vitreous loss secondary to being an open sky procedure. It is also associated with post-operative complications such as prolonged visual rehabilitation, unpredictability, induced refractive error including irregular astigmatism, higher risk of rejection as well as increased surface issues, and a neurotrophic cornea. It also has the weakest wound, thereby being prone to a higher risk of traumatic graft dehiscence. For these reasons, of late, lamellar keratoplasty (LK) has replaced PK for many indications. Endothelial keratoplasty (EK) in the form of Descemet's stripping automated endothelial keratoplasty (DSAEK), Descemet's membrane endothelial keratoplasty (DMEK), and pre-Descemet's endothelial keratoplasty (PDEK) are a better option for diseases that selectively involve the endothelium where there is no stromal scarring. Similarly, in cases with healthy endothelium and purely stromal pathology, stromal replacement in the form of a deep anterior lamellar keratoplasty (DALK), superficial anterior lamellar keratoplasty (SALK) or tucked-in lamellar keratoplasty (TILK) are better and offer advantages of retention of healthy host endothelium, decreased risk of rejection and secondary failure.

RECENT ADVANCES IN ENDOTHELIAL KERATOPLASTY

Descemet's Membrane Endothelial Keratoplasty

Unlike DSAEK, where some stroma is also transferred together with Descemet's membrane (DM) and endothelium, in DMEK, only the DM with endothelium is replaced. This avoids the disadvantages that DSAEK has of additional thickness added to host cornea, induced hyperopia, interface haze, etc. It also has a lesser risk of rejection. However, it is more complex to perform and has a longer learning curve. It also has higher chances of detachment in complex cases such as when DMEK is combined with tubes, aphakia, secondary intraocular lens (IOL) fixation, vitrectomy, etc.

Pre-Descemet's Endothelial Keratoplasty

Description of the pre-Descemet's layer (PDL) in 2013 by Harminder Dua enabled a new kind of EK which also included transplantation of the PDL along with endothelium and DM. Injection of air into a donor corneoscleral graft can result in a type 1, type 2 or a type 3 big bubble (BB) (Figs. 1A to C). A type 1 BB refers to cleavage of a plane between the donor stroma on one side and the PDL, DM, and endothelium on the other side, thus giving a PDEK graft. This type of bubble is formed more commonly in younger donor corneas. A type 2 BB refers to cleavage between the DM and endothelium on one side and the PDL and donor stroma on the other side, thus forming a DMEK graft and this is more commonly formed in older donor corneas. A type 3 BB is when both types of BB are formed simultaneously, i.e. a combination of both in the same donor cornea.[1]

Pre-Descemet's endothelial keratoplasty as described by Amar Agarwal and Harminder Dua grafts have advantages over DMEK grafts in the ability to use young donors,[2] thus giving a more substantial quantum of endothelial cell transfer. The PDL also acts as a splint for the PDEK graft, thus making it a stronger and sturdier graft that is less likely to tear as opposed to the DMEK graft, which is very flimsy and can tear easily. The resilience of the PDEK graft also makes it amenable to easier unfolding and handling within the anterior chamber (AC), thus making surgery easier and faster while still giving comparable results.

Three techniques which have helped make PDEK as well as DMEK surgery easier are—(1) the endoilluminator-assisted PDEK or DMEK (E-PDEK/E-DMEK), (2) the air pump assisted PDEK and (3) the host Descemetic scaffolding techniques, which were described by one of the authors (SJ).

E-PDEK or E-DMEK

As DM is elastic, both DMEK and PDEK grafts scroll toward the DM with endothelium on the outside. It is therefore, essential to have the graft placed in a scrolls-up position before unscrolling and floating it up against the overlying stroma. This is to ensure that the endothelium is transplanted in the right orientation facing the AC. However, the thin nature of DMEK and PDEK grafts, as compared to DSAEK grafts, makes it challenging to identify orientation under the microscope light. This difficulty is compounded by the flimsy nature of the graft, AC currents that easily cause the graft to move and poor visualization in eyes with severe corneal edema. Microscope light that falls perpendicular to the cornea does not provide the ability to distinguish between the layers of the graft's folds, presenting a seemingly two-dimensional image. The use of a vitreoretinal light pipe called an endoilluminator assists with identifying the location and orientation of the graft after injection into the eye. By holding the endoilluminator at an oblique angle, the projected light shines into the AC and onto the graft, providing a three-dimensional view. Reflections bounced off the folds in the graft helps easily identify graft orientation (Figs. 2A and B; Video 1*). The adaptable nature of this technique lets the surgeon check orientation before loading into the cartridge as well

JAYPEE BROTHERS

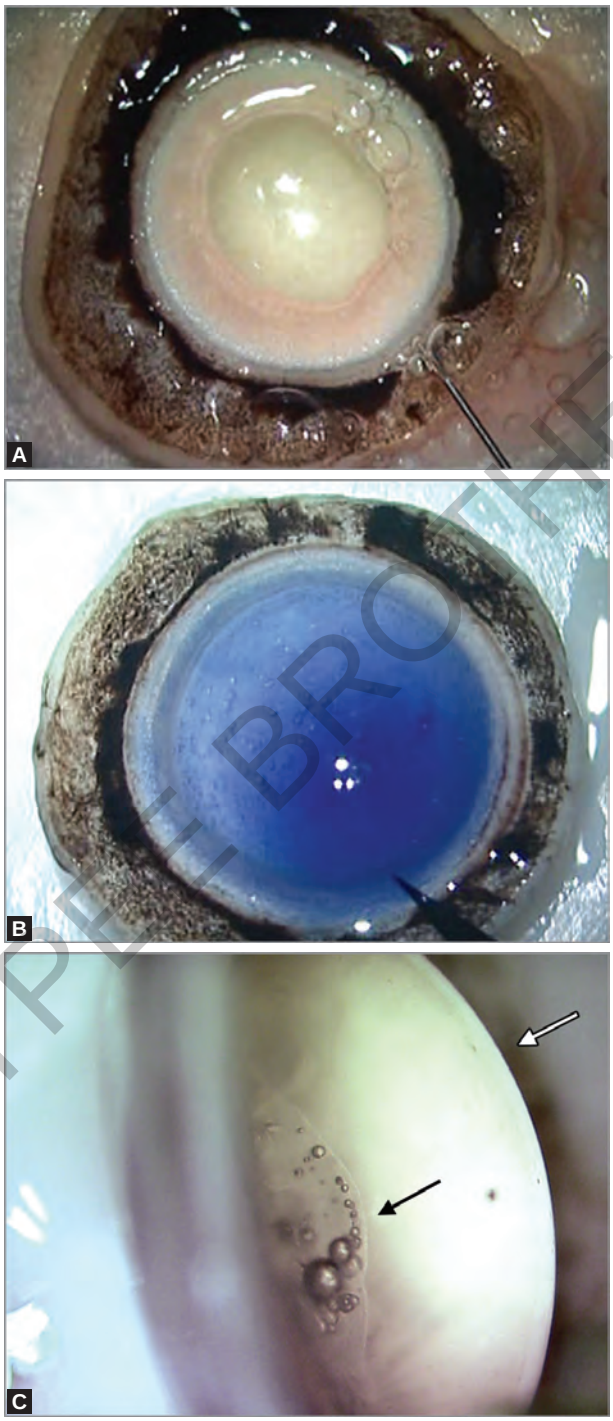

Figs. 1A to C: (A) Type 1 big bubble; (B) Type 2 big bubble; (C) Type 3 big bubble.

JAYPEE BROTHERS

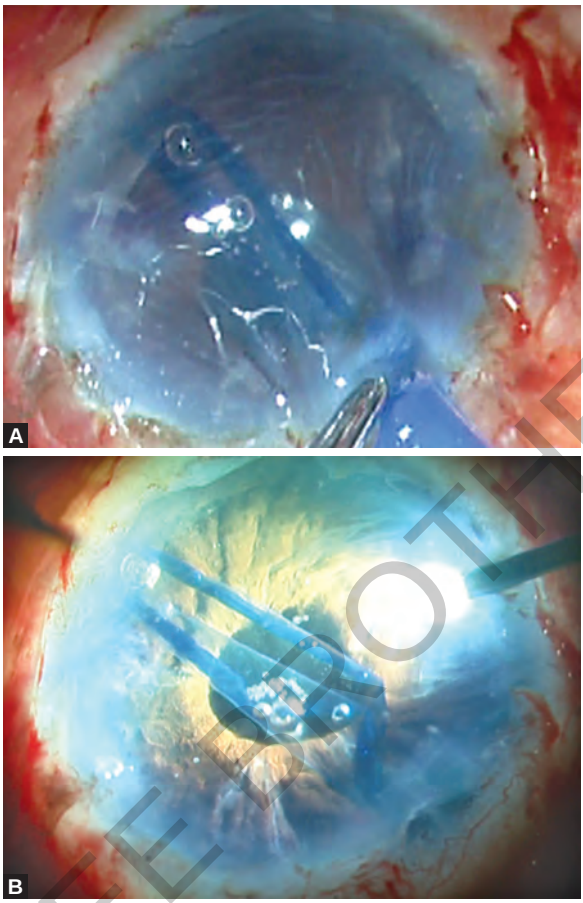

Figs. 2A and B: (A) View with microscope light; (B) View with the endoilluminator-assisted Descemet's membrane endothelial keratoplasty (E-DMEK) technique showing better visualization and depth perception.

as while still within the injector cartridge and also once the graft is inside the AC. By checking the direction of the graft before injection, the surgeon can correct placement within the injector and prevent unnecessary manipulation of the graft in the AC. The light is used to place the graft in a scrolls-up position, which ensures the PDL is stationed flush against the recipient's stroma. It also allows the surgeon to appreciate the entire graft at once, showing both the fold and orientation while also showing the length and graft dimensions. This leads to a faster surgery with more control of the graft and lower chances of damage. Graft unfolding can be done under endoilluminator light, thus eliminating any possibility of graft rotation going unnoticed. Used internally, it can also be used to confirm the patency of the peripheral iridectomy (PI) and is particularly beneficial in cases with a blurred visual inside the AC due to a cloudy cornea. Having the microscope light off during these steps makes three-dimensional perception even better.[3-5]

JAYPEE BROTHERS

There are other techniques that are used to help determine the orientation of thinner grafts in the AC. While some of these techniques do allow the surgeon to determine graft orientation prefloatation, each of these techniques also presents challenges not seen with the use of the endoilluminator. The hand held slit lamp may be used once the graft has been injected into the eye. While this does allow prefloatation assessment, it only displays parts of the graft at a time, removing the ability to appreciate the graft in its entirety. It has a lower magnification as compared to the operating microscope and does not allow surgical maneuvers to be performed while using the technique, both because of lack of dexterity and less magnification. It is also a less sterile option with a higher risk of contamination and must be handled using additional sterile methods.

Techniques that do not utilize light have also been described using either a physical marking on the graft itself or an additional object within the AC. The Moutsouris sign[6] is a technique that involves inserting a cannula into the eye, under the graft to determine if it is inverted. If the scroll of the graft falls on top of the cannula, then the graft is determined to be in the correct orientation. The disadvantages of this method include the potential for AC shallowing, induction of AC currents and consequent undesired graft movement due to the insertion of an additional object into the intraocular space, as well as potential damage to the graft secondary to intra-ocular manipulation. The S-stamp approach uses an irreversible sign applied on the graft before injection. After the graft is harvested the surgeon marks an "S" on the Descemetic side which can be used to determine an inverted graft by the direction of the "S" after injection.[7] While this method allows for higher confidence in graft orientation, it has the disadvantage of physical manipulation of the graft outside of the AC. To mark the graft, it must first be folded in half, the donor cornea punched, the graft laid back again and the "S" marked from the epithelial side. This can increases the potential for damage to the endothelial cells, together with potential damage from the marking ink. It also does not allow easy prefloatation determination of the graft orientation as the S may be within the folds and therefore, present a confusing view.

In our experience, the E-PDEK or E-DMEK technique provides accurate determination with few disadvantages. It decreases the need for intraocular manipulation of the graft or physical alterations, increases visibility to allow a full graft appreciation with depth dimensions and allows better visibility through even severe corneal edema.

Air Pump Assisted PDEK

Identification of the orientation of the graft is only one step of EK procedure and is followed by unfolding and placing the graft within the recipient's eye. Though young grafts are ideal in these procedures due their higher endothelial cell counts; however, they are also more elastic, which combined with their thin nature leads to fast and tight scrolling within the AC. The tighter scroll leads to difficulties when approaching centration and unscrolling of a PDEK graft.[8-10]

JAYPEE BROTHERS

The air pump assisted PDEK technique utilizes continuous pressurized air infusion delivered via an AC maintainer (ACM) placed through a limbal paracentesis to help certain surgical maneuvers. Air injection can be performed using either a fluid exchange system from a vitrectomy machine or a pressurized air infusion from certain phaco machines. Though using a single air bubble or low-pressure infusion has been described previously for stripping the DM, the air pump assisted technique helps in many other key steps during surgery. The AC is filled with air in the beginning of surgery and the provided pressure acts to tamponade bleeding within the AC that may occur during synechiolysis or PI. The maintained air pressure prevents and stops bleeding and thus prevents a fibrinous sticky atmosphere from forming within the AC, thus avoiding intraoperative difficulty in unscrolling the graft as well as postoperative inflammation and interface blood or fibrin. It also prevents blood from oozing into the AC from peripheral corneal neovascularization. Performing the Descemetorhexis under air after the PI helps give time for bleeding to clot by the time the rhexis is completed. The air also helps make a continuous Descemetorhexis easier to perform while giving greater control over sizing and centration. The ACM is then removed and air replaced with balanced salt solution (BSS) and the graft injected. The orientation of the graft is checked, the graft is unfolded to a large extent and air injected through a cannula placed below the graft to float it against the recipient stroma. This is unlike DMEK or traditional surgery where it is essential to unfold the graft completely from edge to edge as well as make sure of centration before floating the graft up. The ACM is then reinserted and pressurized air infusion started after making sure that the ACM is placed below the graft. The interior pressure provides resistance against the graft from the inside, which creates a firm surface on the cornea through which the surgeon may center the graft. Once the interior pressure is controlled, it only needs increasing when an instrument is moved in or out of the AC. Using a reverse Sinskey hook, the surgeon may then center the graft on the cornea and unfold the edges, which are made more visible against the air. While the graft is held in place by air, adjustments are more controlled, and any creases or folds present in the graft are also addressed, resulting in a smooth placement. Continuous air pressure decreases chances of the graft becoming detached or moving while also maintaining space within the AC for easier graft manipulation. Adequate operating space in the AC helps ensure graft safety, with a lower risk of damage. This technique makes surgery easier and faster and decreases the learning curve. All manipulations to the graft are kept to a minimum and only to the peripheral edge of the graft to prevent cell loss. The continuous air pressure also helps the graft to adhere better and faster and decreases risk of postoperative detachment (Figs. 3 and 4; Video 2**).

Disadvantages include air bubbles escaping from the incisions which may interfere with visualization. This can be solved by placing a cotton wick at the incision which directs the escaping air bubbles away. Conjunctival emphysema can be prevented by putting a nick on the conjunctiva allowing

JAYPEE BROTHERS

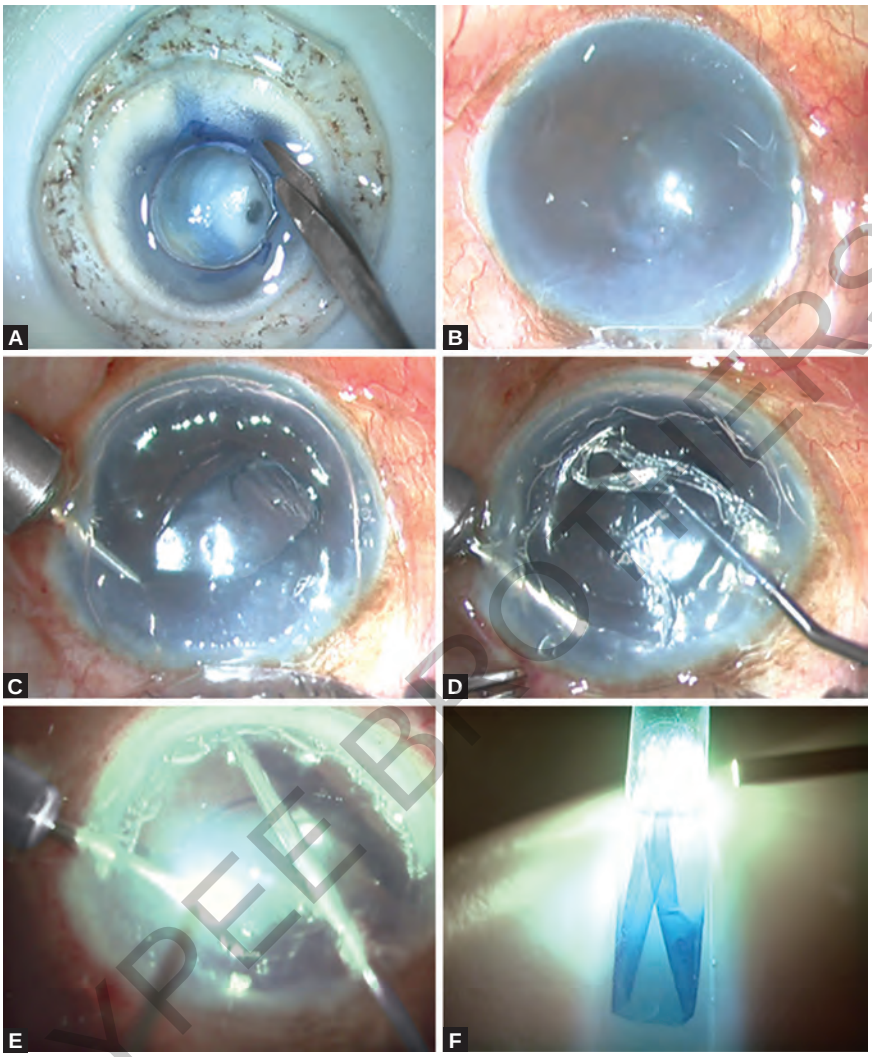

Figs. 3A to F: Air pump assisted pre-Descemet's endothelial keratoplasty. (A) Type 1 big bubble created and PDEK graft dissected; (B) Preoperative view showing endothelial decompensation; (C) Continuous pressurized air infused through an anterior chamber maintainer; (D) Descemetorhexis done with air pump assisted technique; (E) Peripheral iridectomy done with air pump assisted technique; (F) PDEK graft orientation within the cartridge confirmed with the E-PDEK technique.

air to escape. Any cell loss secondary to graft edge unfolding is offset by the absence of repeated attempts at unfolding and centering the graft completely before floatation. It should be remembered that the pressure within the AC is lower than that set on the machine because of continuous leakage of air from the incisions. The estimated pressure should not be allowed to rise to very high levels.

JAYPEE BROTHERS

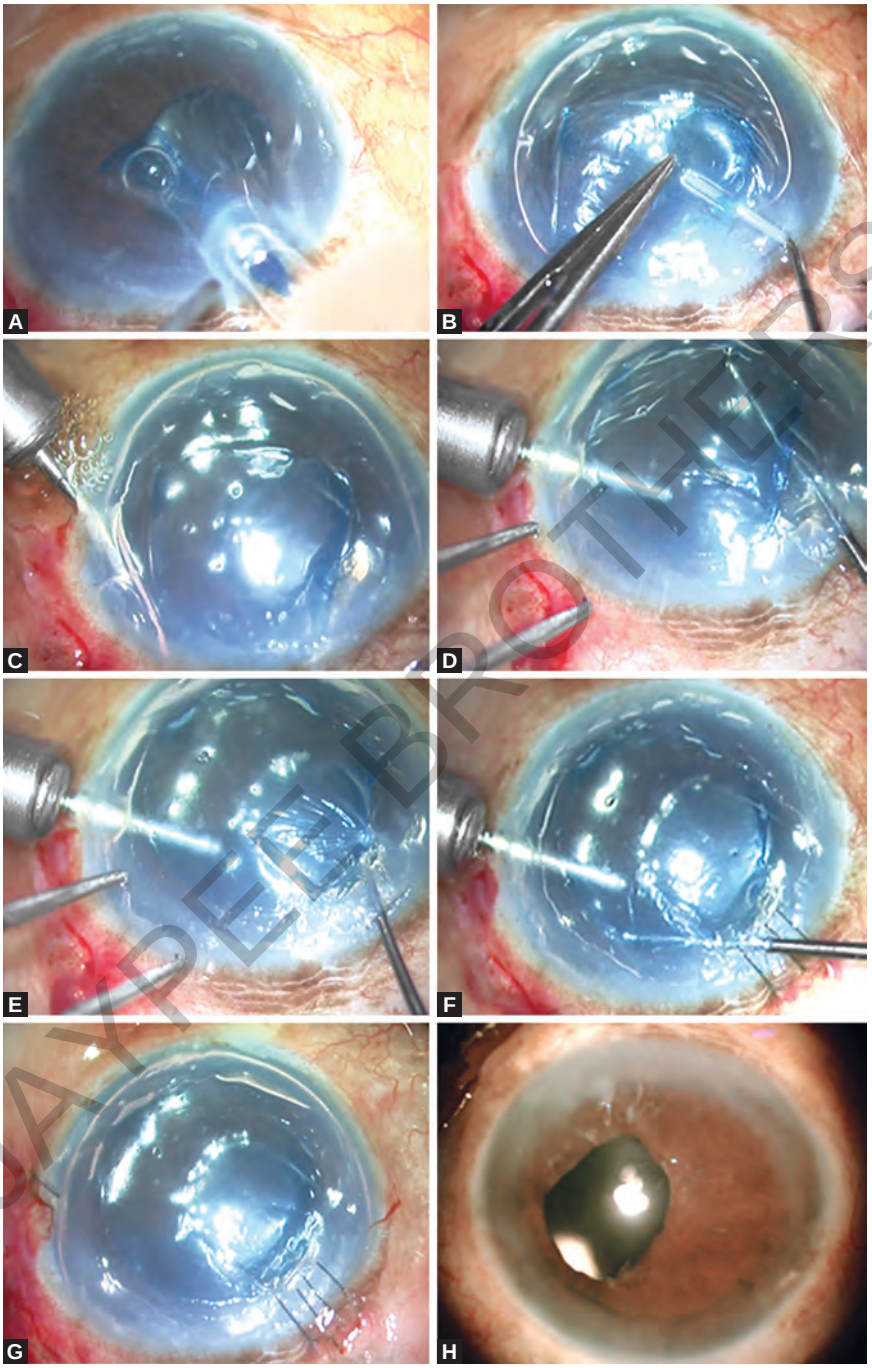

Figs. 4A to H: (A) Graft injected into anterior chamber after removing air; (B) Graft orientation confirmed and then unrolled and floated up with air; (C) Anterior chamber maintainer connected and continuous pressurized air infusion restarted; (D to F) Graft centered and edges unrolled using the air pump assisted technique; (G) Well centered and apposed graft seen at the end of surgery; (H) Postoperative appearance showing a well attached graft and a clear cornea.

JAYPEE BROTHERS

Host Descemetic Scaffolding

One of the problems with both PDEK and DMEK is that it has a higher rate of graft detachment in complex cases such as aphakic eyes, vitrectomized eyes, when combined with secondary IOL fixation, or with glaucoma drainage devices or large incision surgeries such as small incision cataract surgery (SICS).[11]

Traditionally, the area of host descemetorhexis is kept larger than the graft size in order to avoid the possibility of the graft overlapping host DM which could be the cause for a graft detachment. The Host Descemetic scaffolding instead uses an area of DM stripping that is smaller than the graft. The host Descemet is then used as a scaffold below the graft to support the graft and prevent graft detachment (Figs. 5 to 7). This is done by sandwiching the graft edge between the host DM and stroma. This can be done as a two-sided or multipoint host DM scaffolding, near total scaffolding or by using a combination of one point scaffolding with wound scaffolding (Figs. 8A to C).

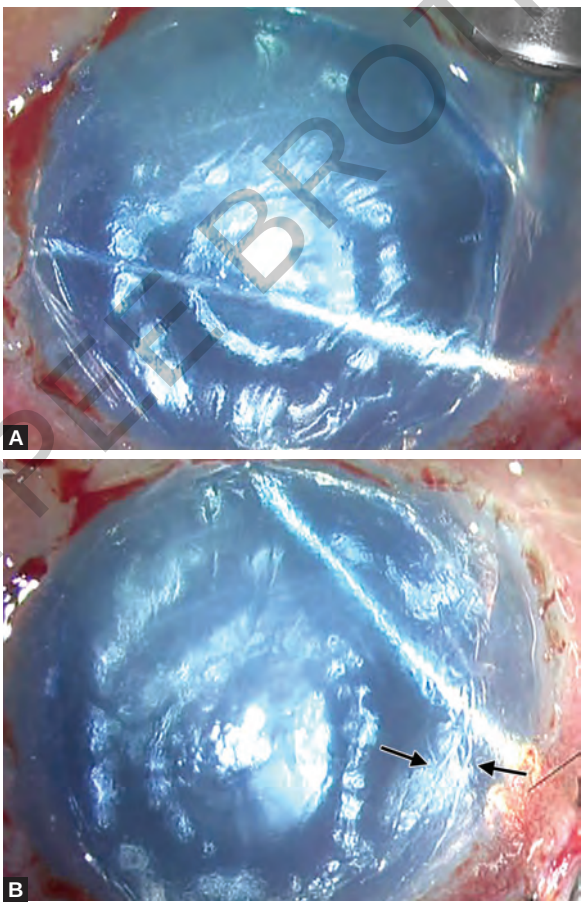

Figs. 5A and B: Host Descemetic scaffolding seen being done for the pre-Descemet's endothelial keratoplasty graft.

JAYPEE BROTHERS

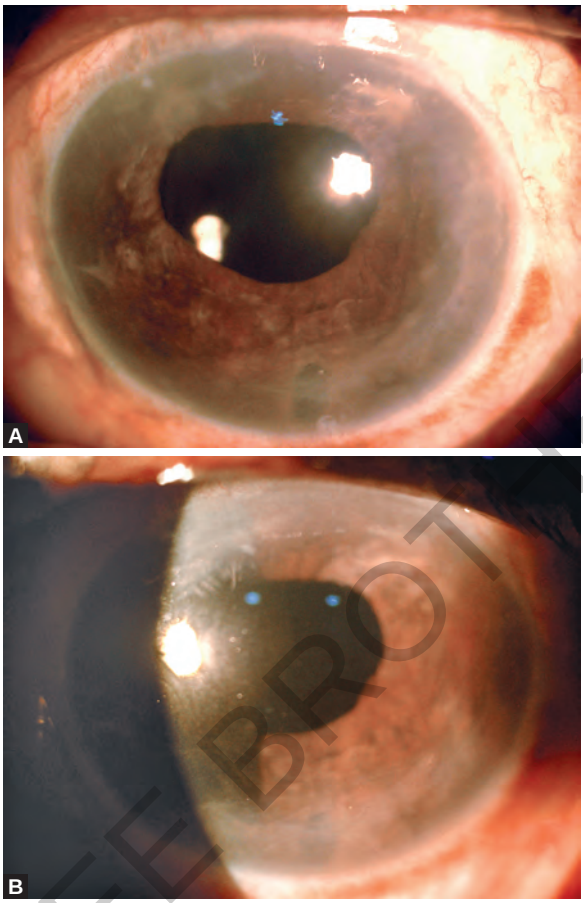

Figs. 6A and B: Postoperative picture showing host Descemetic scaffolding.

This technique is useful in cases with a higher risk of graft detachment. It may also be useful in routine cases as well as during the learning curve.

RECENT ADVANCES IN ANTERIOR LAMELLAR KERATOPLASTY

Modified Primary Pre-Descemetic DALK for Acute Hydrops (Jacob Technique)

In cases with cornea pathology anterior to the endothelium, a DALK may be performed. One of the most common indications is keratoconus. Advanced cases of keratoconus may suffer from a rupture of the DM leading to pain, redness, hydration of the cornea, edema, intrastromal fluid clefts, etc.[12,13] This condition referred to as acute corneal hydrops (CH) is typically approached with a two-part treatment plan, initially with injection of intracameral gas to close the break followed later by a keratoplasty procedure to correct the pathology. This could be either a PK or a DALK depending on the location of the ensuing scar. Traditional conservative treatment in the acute stage is with observation, injection of long-acting gas within the AC,[14-16] compression

JAYPEE BROTHERS

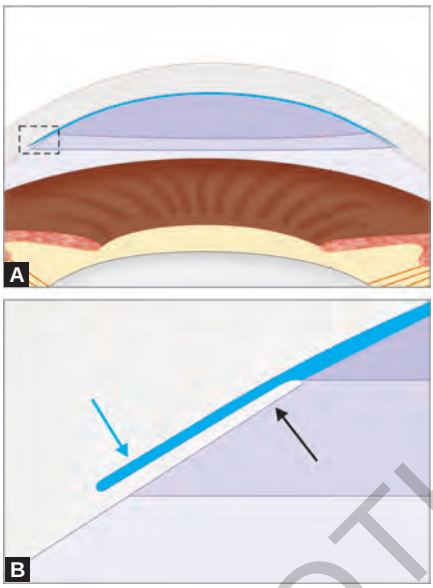

Figs. 7A and B: Host Descemetic scaffolding. Blue arrow shows pre-Descemet's endothelial keratoplasty graft being scaffolded by the host Descemet's membrane (black arrow).

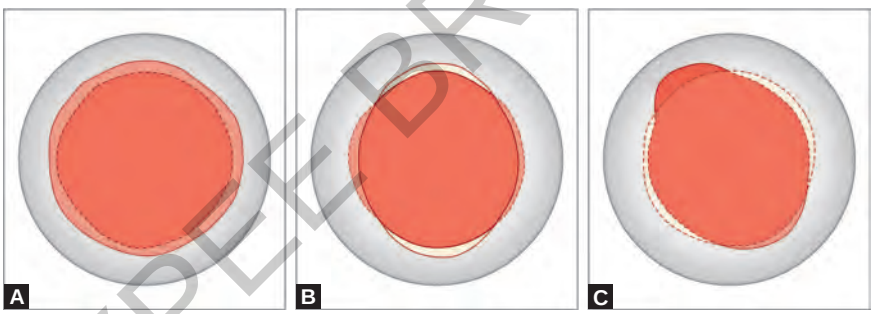

Figs. 8A to C: (A) Total to near total Host Descemetic scaffolding; (B) Two point Host Descemetic scaffolding; (C) Single point Host Descemetic scaffolding with wound scaffolding.

sutures,[17] etc. However, resolution takes time and occurs with scarring. Though scarring may result in some flattening of the cornea and improved contact lens tolerance, the basic pathology remains untreated—the eye still continuing to have all the disadvantages of severe keratoconus—ectasia, poor uncorrected and best spectacle corrected visual acuity, high irregular astigmatism and aberrations, poor corneal topography, thin cornea and the need for contact lens and consequent problems such as limited time of wear, contact lens related scarring, infections, etc. Many patients therefore, need a secondary procedure in the form of a pre-Descemetic DALK. In addition, if post-hydrops scar is over the visual axis, it results in the need for an optical PK, thus exposing the patient to a higher risk of rejection secondary to loss of native endothelium.

JAYPEE BROTHERS

One of the authors (SJ) has described a modified technique of safely and effectively performing a pre-Descemetic DALK at the time of acute hydrops as a primary management technique and as a substitute for the conventional conservative management of acute hydrops.[18,19] This technique has advantages of retaining host endothelium, closing the DM break, simultaneously restoring anatomy and treating the pathology, improving uncorrected and best corrected visual acuity, decreasing irregular astigmatism, correction of ectasia and thinning, and most important of all resolution without scarring (Figs. 9A to F; Video 3***).

In the modified technique, the cornea is partially trephined using manual trephine, suction trephine or femtosecond laser. In cases with extensive edema or severe thinning with minimal retained stroma above the tear, an inked trephine is used to mark the corneal surface and a groove is then deepened using a sharp dissector. Graded emphysema is induced by injecting small aliquots of air through a bevel up 30-gauge needle directed away from the break. The emphysema induced acts as a guide to the depth of dissection. Manual deep dissection using a mildly blunt dissector is then done in a centripetal fashion leaving the area of DM tear for the last. The superficial lamellar keratoplasty performed to remove the anterior aspects of the cornea must proceed slowly and carefully, dissecting as close to the tear as possible while maintaining a thin layer of stroma above to support the AC. Minimal stroma is retained above the tear in order to avoid entering the AC. The donor corneoscleral graft is sutured and the DM tear is tamponaded with air in the AC (Figs. 10A to D).

To conclude this technique is associated with success in restoring visual acuity, corneal structure, clarity, topography, pachymetry while at the same time avoiding a lengthy two-staged process that often results in two procedures rather than approaching the entire issue at one time. It also allows the cornea and the DM tear to heal without scarring which is a major advantage over conventional treatment of acute hydrops.

The alternative approaches to repairing CH damage such as pneumodescemetopexy, compressive sutures, and cyanoacrylate glue take significantly longer and often lead to corneal scarring, resulting in decreased visual success. These procedures often occur in two stages over a longer time frame, preventing visual rehabilitation for more time and leading to increased costs and morbidity. Though a more immediate approach such as a PK corrects both CH damage and keratoconus at the same time, it includes removal of the entire recipient cornea, which results in a higher risk of graft failure due to the removal of the patient's endothelium. The modified pre-Descemetic DALK procedure shows the most significant visual rehabilitation with a decreased treatment time. The more direct approach to treatment allows for treatment of

JAYPEE BROTHERS

for detailed information on ophthalmology books, visit our website **www.jaypeebrothers.com,** for detailed informati

Recent Advances in OPHTHALMOLOGY–14

Salient Features

- Contains 21 well-illustrated chapters on current topics in ophthalmology
- Describes causes and management of post-LASIK ectasia
- Many forms of lamellar keratoplasty have been introduced
- Describes step-by-step use of glaucoma drainage devices in management of intractable glaucoma
- Describes recent advances in calculation of IOL power for implantation
- Includes chapters on cataract surgery in challenging situations
- Discusses how to adopt the results of clinical trials in real-life situations
- Describes the role of optical coherence tomography-angiography in retinal diseases
- Students and ophthalmologists can upgrade their knowledge effectively for the better care of their patients.

HV Nema MS has a distinguished academic career and is well known for teaching, research and publications. Formerly, he was Professor and Head, Department of Ophthalmology, Institute of Medical Sciences, Banaras Hindu University, Varanasi, Uttar Pradesh, India. He has served as a Consultant Editor/Advisory Editor to Indian Journal of Ophthalmology, Afro–Asian Journal of Ophthalmology and Indian Journal of Optometry. He has published more than 6 dozen papers in the national and international journals. He is an established author in the field of ophthalmology. *Ophthalmic Syndromes* (Butterworth, London, UK, 1973) and *Textbook of Ophthalmology* (6th edition, 2012, Jaypee Brothers Medical Publishers, New Delhi, India) are some of his popular books. He has edited 14 volumes of *Recent Advances in Ophthalmology*, 3 editions of *Diagnostic Procedures in Ophthalmology, Eye in Systemic Disorders* (Wiley India), and books on *Cornea and Sclera, Diseases of Uvea, Glaucoma, Cataract Surgery* and *Retina* which were well received by readers and favorably reviewed in national and international journals. He has delivered guest-lectures in many universities.

Nitin Nema MS DNB is a Professor, Department of Ophthalmology, Sri Aurobindo Institute of Medical Sciences, Indore, Madhya Pradesh, India. He is an experienced Vitreoretinal Surgeon. He did his Fellowship from Aravind Eye Hospital and PG Institute, Madurai, Tamil Nadu. He gained clinical and research experience from the University of Illinois at Chicago, and the University of Wisconsin at Madison in the USA. He was awarded a Fellowship by the All India Ophthalmological Society to work on a Project on Uveitis at Sankara Nethralaya, Chennai. He was awarded Dr Mohan Lal Gold Medal for the best paper by UP State Ophthalmological Society. He had authored (in collaboration with Dr HV Nema) 2 textbooks: *Anatomy of the Eye and Adnexa* (3rd edition) and *Textbook of Ophthalmology* (6th edition), and edited 13 volumes of *Recent Advances in Ophthalmology*, 3 editions of *Diagnostic Procedures in Ophthalmology*, and books on *Cornea and Sclera, Diseases of Uvea, Glaucoma, Cataract Surgery* and *Retina*.

Available at all medical bookstores
or buy online at www.jaypeebrothers.com



JAYPEE BROTHERS
Medical Publishers (P) Ltd.
www.jaypeebrothers.com

Join us on facebook.com/JaypeeMedicalPublishers

Shelving Recommendation
OPHTHALMOLOGY

