s & gynecology books, visit our website www.jaypeebrothers.com, for detailed information on obstetrics & gynecology books



Step by Step®

Step by Step® Ultrasound in Obstetrics

Editor-in-Chief
Narendra Malhotra

Associate Editors
Nidhi Gupta
Neharika Malhotra
Jaideep Malhotra
Kuldeep Singh

3rd Edition

JAYPEE

Contents

1. Basics in Ultrasonography **1**

1.1 Basic Physics *1*
1.2 Instrumentation *7*
1.3 Knobology *20*
1.4 Doppler and Color Flow Principles *22*
1.5 Equipment Care and Quality Control *39*
1.6 Malpractice and Ultrasound *42*

2. Training **49**

2.1 Theoretical Aspects *50*
2.2 Training Parameters *50*
2.3 Suggested Training Schedule *51*
2.4 Prerequisite Criteria for a Trained Ultrasonologist *52*
2.5 Mandatory Proposed Certification for an Ultrasonologist (Obstetrics and Gynecology) *53*
2.6 Syllabus for FOGSI-ICOG Certificate Course in Ultrasound Medicine *54*

3. Introduction **77**

3.1 Filling up of Forms *77*
3.2 Relevant History *78*
3.3 Preparation and Positioning of Patient *78*
3.4 Machine and Transducers *79*
3.5 Reporting *80*

4. First Trimester **83**

4·1 Indications *84*
4.2 Normal First Trimester Embryonic/Fetal Evaluation *84*
4.3 Normal Parameter Evaluation in the First Trimester *92*
4.4 Abnormal Intrauterine Pregnancy *92*

4.5 Impending Early Pregnancy Failure *95*
4.6 Ectopic Gestation *97*
4.7 Extra-Fetal Evaluation *100*
4.8 Abnormal Intrauterine Pregnancy Forms *100*
4.9 Complete Abortion *100*
4.10 Incomplete Abortion *105*
4.11 Molar Change *106*
4.12 Sonoembryology Chart *109*
4.13 Nuchal Translucency *120*
4.14 Abnormal Fetus *123*
4.15 First Trimester Scan Checklist *128*
4.16 Dilemmas *128*
4.17 First Trimester Key Points *128*
4.18 Transvaginal Decision Flowchart *129*
4.19 Decision-Making in the First Trimester *130*
4.20 Ultrasound Markers of Chromosomal Anomalies in First Trimester *130*
4.21 First Trimester Biochemical Markers and Noninvasive Screening *136*
4.22. First Trimester: Detection of Non-Chromosomal Anomalies *141*
4.23 Three Dimensional Sonoembryology *152*
4.24 Color Doppler in First Trimester *155*
4.25 Early Fetal Echocardiography *163*
4.26 First Trimester Cervicometry *167*
4.27 Invasive Procedures in First Trimester *169*
4.28 Screening for Preeclampsia in First Trimester *175*

5. Second Trimester **178**

5.1 Indications *179*
5.2 Fetal Evaluation *179*
5.3 Fetal Evaluation (Malformations) *179*
5.4 Cranium *180*

5.5 Nuchal Skin *181*
5.6 Fetal Orbits and Face *181*
5.7 Fetal Spine *211*
5.8 Fetal Thorax *219*
5.9 Fetal Heart *228*
5.10 Fetal Abdomen *228*
5.11 Fetal Skeleton *258*
5.12 Fetal Biometry *265*
5.13 Extra-Fetal Evaluation *265*
5.14 Color Doppler in Second Trimester *276*
5.15 3D and 4D Scan *276*
5.16 Abnormal Second Trimester *276*
5.17 Dilemmas *276*

6. Third Trimester **277**
6.1 Indication *278*
6.2 Fetal Evaluation *278*
6.3 Extra-Fetal Evaluation *279*
6.4 Placental Checklist *285*
6.5 Amniotic Fluid Assessment *286*
6.6 Causes of Oligohydramnios *287*
6.7 Causes of Polyhydramnios *287*
6.8 Fetal Growth *287*
6.9 Fetal Surveillance or Fetal Wellbeing *289*
6.10 Biophysical Profile *289*
6.11 Evaluation by Biophysical Profile *290*
6.12 Interpretation of Biophysical Profile *291*
6.13 Serial Evaluation *291*
6.14 Color Doppler *292*
6.15 Indications for Color Doppler *292*
6.16 Interpretation of the Waveforms *292*
6.17 Indications of Delivery *301*
6.18 Mode of Delivery *301*

6.19 Abnormal Third Trimester *301*
6.20 Checklist *302*
6.21 Dilemmas *302*
6.22 Sonographic Diagnosis of IUGR *302*
6.23 Ultrasonic Measurements used in the Diagnosis of IUGR *304*
6.24 Color Doppler in IUGR *315*

7. PCPNDT Act **331**

8. Ergonomics in Reducing Injury Risk in Sonography **361**

9. 3D in Obstetric Imaging (The World is Changing) **374**

Appendices **445**

Appendix 1: *Normal Values 447*

Appendix 2: *Measurement Methodology 449*

Appendix 3: *Reporting 451*

Appendix 4: *Schematic Analysis for Fetal Anomalies 454*

Appendix 5: *Fetal Abnormalities in Trisomy 21, 18 and 13 456*

Appendix 6: *Fetal Abnormalities in Triploidy and Turner's Syndrome 458*

Appendix 7: *Fetal Abnormalities in Maternal Infections 459*

Ready Reckoner **460**

Index *483*

4

CHAPTER

First Trimester

4.1 Indications
4.2 Normal First Trimester Embryonic/Fetal Evaluation
4.3 Normal Parameter Evaluation in the First Trimester
4.4 Abnormal Intrauterine Pregnancy
4.5 Impending Early Pregnancy Failure
4.6 Ectopic Gestation
4.7 Extra-fetal Evaluation
4.8 Abnormal Intrauterine Pregnancy Forms
4.9 Complete Abortion
4.10 Incomplete Abortion
4.11 Molar Change
4.12 Sonoembryology Chart
4.13 Nuchal Translucency
4.14 Abnormal Fetus
4.15 First Trimester Scan Checklist
4.16 Dilemmas
4.17 First Trimester Key Points
4.18 Transvaginal Decision Flowchart
4.19 Decision Making in the First Trimester
4.20 Ultrasound-markers of Chromosomal Anomalies in First Trimester

JAYPEE BROTHERS

4.21 First Trimester: Biochemical Markers and Noninvasive Screening
4.22 First Trimester: Detection of Nonchromosomal Anomalies
4.23 Three-dimensional Sonoembryology
4.24 Color Doppler in First Trimester
4.25 Early Fetal Echocardiography
4.26 First Trimester Cervicometry
4.27 Invasive Procedures in First Trimester
4.28 Screening for Preeclampsia in First Trimester

4·1 INDICATIONS

- Confirmation of pregnancy
- Vaginal bleeding in pregnancy (threatened abortion)
- Estimation of gestational age
- Suspected ectopic pregnancy
- Suspected hydatidiform mole
- Adjunct to cervical cerclage
- Suspected multiple gestation
- Adjunct to chorionic villus sampling.

4.2 NORMAL FIRST TRIMESTER EMBRYONIC/FETAL EVALUATION

- Location of sac:
  - Fundus (Fig. 4.1)
  - Corpus (Fig. 4.2)
  - Cornual (Fig. 4.3)
  - Superior to the cervix.
- Number of sacs:
  - Single
  - Multiple (Twin/triplet/high order multiple) (Fig. 4.4).
- Size of sac:

JAYPEE BROTHERS

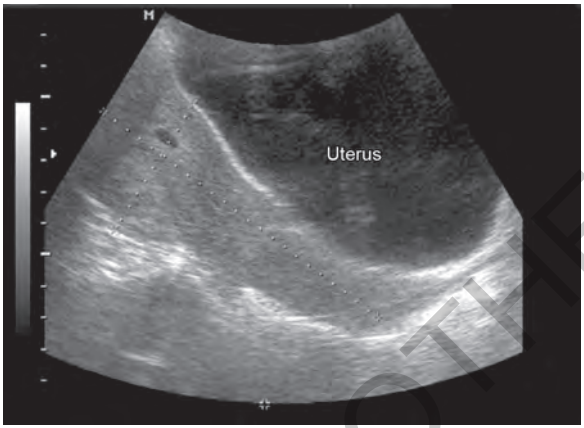

Fig. 4.1: Gestational sac located in the uterine fundus.

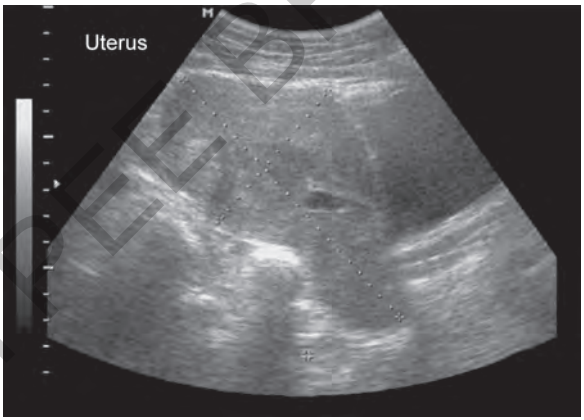

Fig. 4.2: Gestational sac located in the uterine corpus.

- In toto, measure inner to inner diameter of gestational sac on all three sides and calculate the size and corresponding gestational age (Figs. 4.5A and B)

JAYPEE BROTHERS

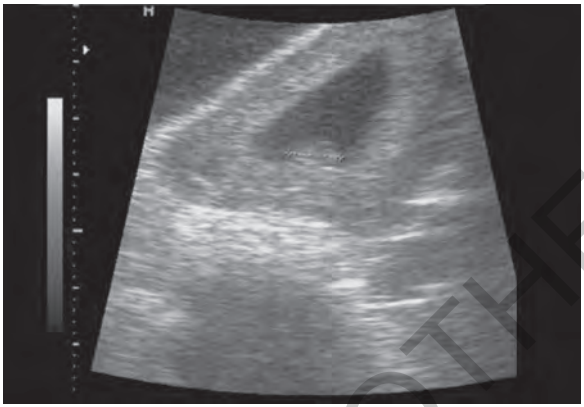

Fig. 4.3: Gestational sac located in the uterine cavity in the cornual area. Note the amount of myometrium lateral to the gestational sac differentiating it from a cornual ectopic.

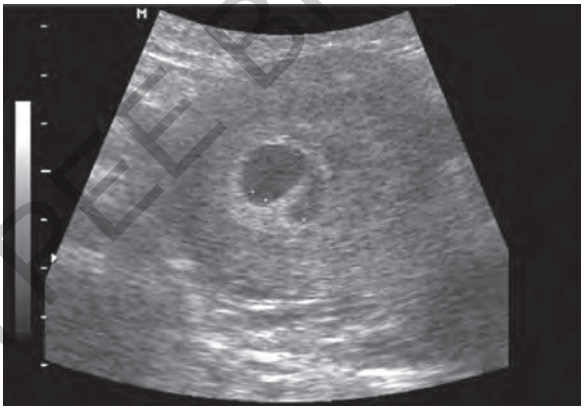

Fig. 4.4: Two gestational sacs both located in the uterine fundus.

  - Size of gestational sac in comparison to the embryo/fetus size (Fig. 4.6).
- Embryo/fetal size (crown rump length) (Figs. 4.7 and 4.8).

JAYPEE BROTHERS

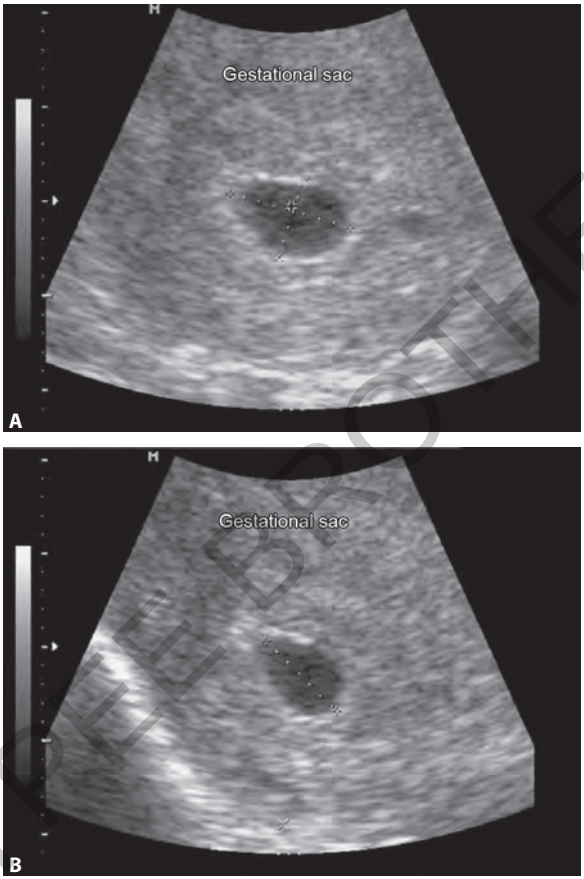

Figs. 4.5A and B: Gestational sac measurement in all three planes and calculation of gestational age done by the ultrasound machine.

- Embryonic cardiac activity. To begin with, the heart rate is around 85 beats/minute at 5 to 5½ weeks (Fig. 4.9) increasing to around 160 beats/minute (Fig. 4.10) at nine weeks.
- Yolk sac:

JAYPEE BROTHERS

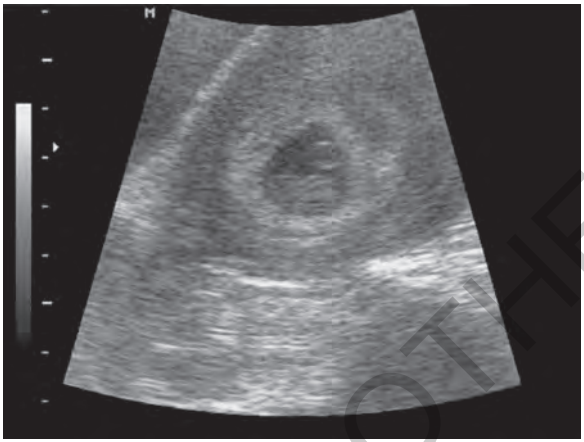

Fig. 4.6: Note that the sac is oligoamniotic with the gestational sac corresponding less than the embryo size.

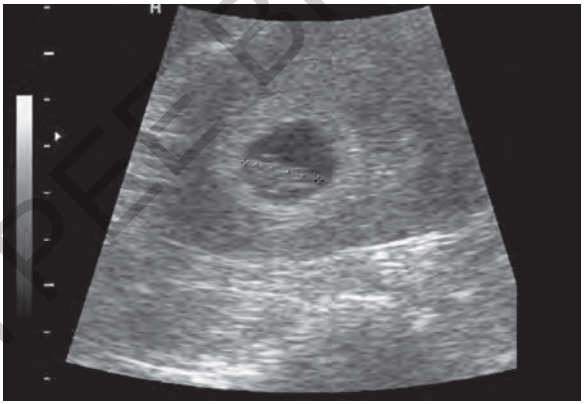

Fig. 4.7: Measurement of crown rump length in a 7 weeks and 6 days embryo.

- Size
- Shape
- Any calcification.

JAYPEE BROTHERS

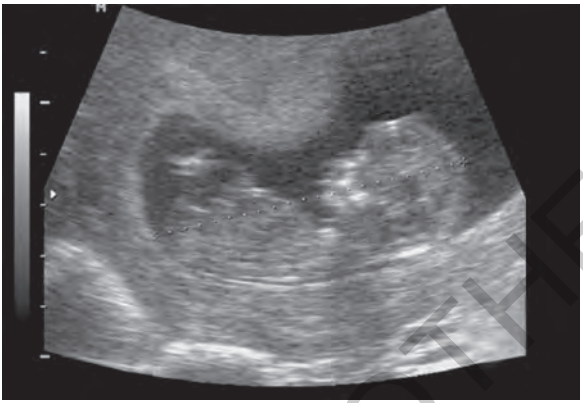

Fig. 4.8: Measurement of crown rump length in an 12 weeks and 4 days fetus.

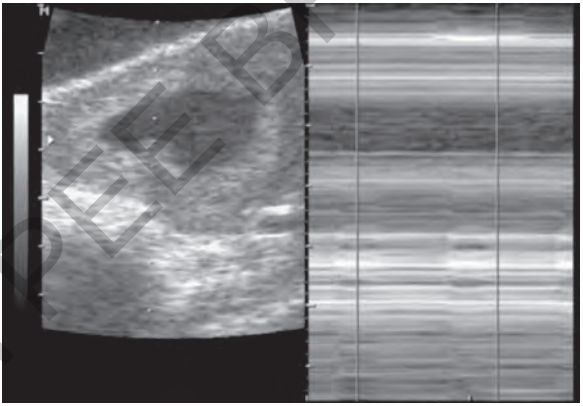

Fig. 4.9: Heart rate of 143 beats per minute in a 6 weeks and 0 day embryo.

- Trophoblastic reaction:
  - Whether wrapping around and thick reaction (Fig. 4.11)
  - Locate site (Fig. 4.12).

JAYPEE BROTHERS

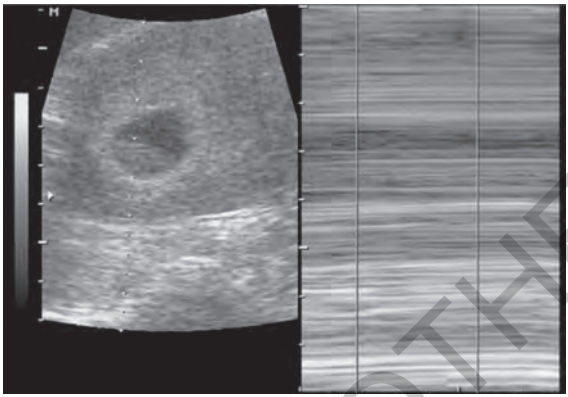

Fig. 4.10: Heart rate of 151 beats per minute in an 8 weeks and 1 day fetus.

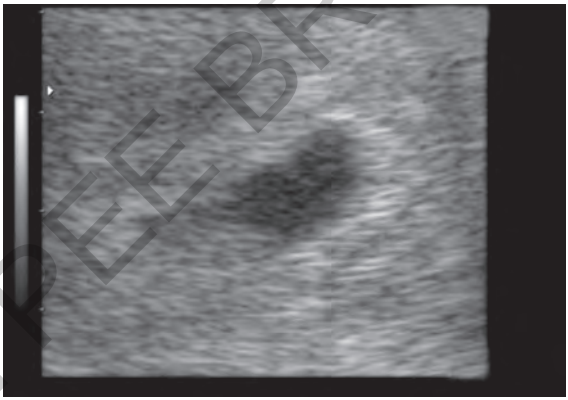

Fig. 4.11: Wrapping around thick trophoblastic reaction seen in a gestational sac of 6 weeks 4 days.

JAYPEE BROTHERS

- Separation:
  - Amniodecidual separation (Fig. 4.13)
  - Choriodecidual separation (Fig. 4.14).
- To identify any gross anomalies:

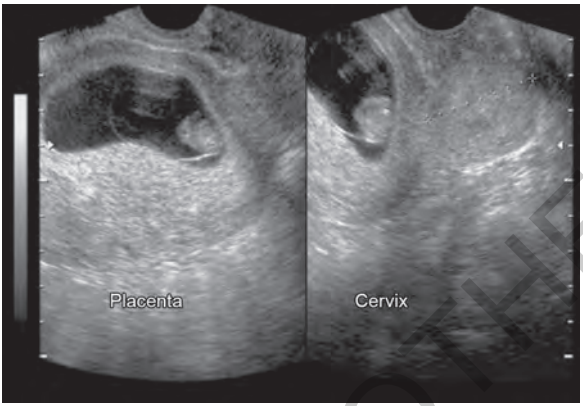

Fig. 4.12: Note the thickened trophoblastic echoes on one wall of the gestational sac. This is the placental site location.

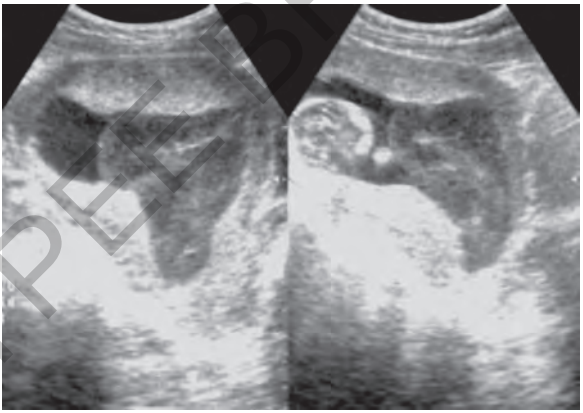

Fig. 4.13: The placenta is anterior with an amniodecidual separation seen in the anterior wall superior to the cervix. This has an associated collection of 8.35 mL.

- Gross abnormalities of the cranium, spine, abdomen and limbs can be detected even in the late first trimester

JAYPEE BROTHERS

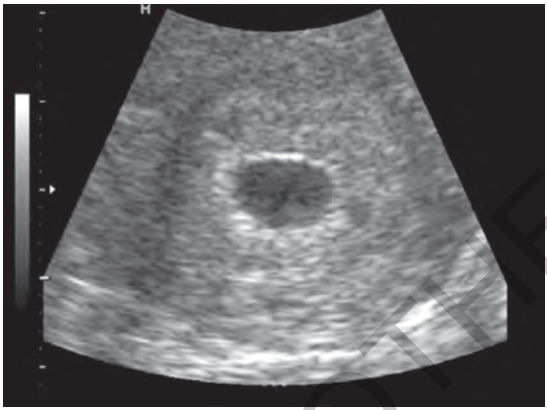

Fig. 4.14: Multiple foci of choriodecidual separation seen in a 6–7 weeks size missed abortion.

  - Nasal bone ossification
  - Nuchal translucency.
- Color Doppler evaluation of the ductus venosus and both maternal uterine arteries.

4.3 NORMAL PARAMETER EVALUATION IN THE FIRST TRIMESTER

- *Gestational sac:* Seen as early as 4½ weeks by transvaginal scan and 5½ weeks by transabdominal scan (Fig. 4.15).
- *Yolk sac:* Seen as early as 5 weeks by transvaginal scan and 6 weeks by transabdominal scan (Fig. 4.16).
- *Embryo:* Seen at 5½ weeks by transvaginal scan and at 6–6½ weeks by transabdominal scan (Fig. 4.17).
- *Cardiac activity:* Appears at 5 weeks and 4 days.

4.4 ABNORMAL INTRAUTERINE PREGNANCY

- No embryonic cardiac activity with a CRL >5 mm. (missed abortion) (Fig. 4.18)

JAYPEE BROTHERS

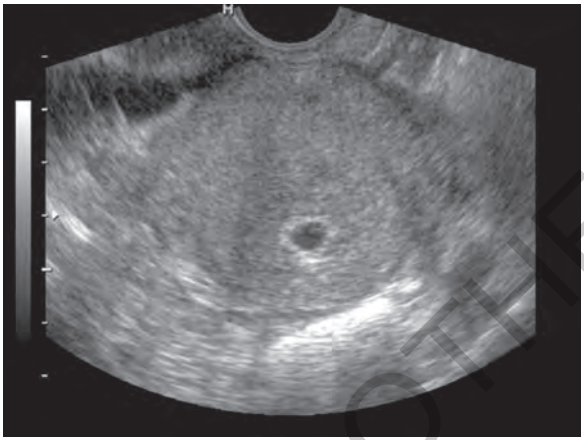

Fig. 4.15: Transvaginal scan of a gestational sac of 5 weeks size.

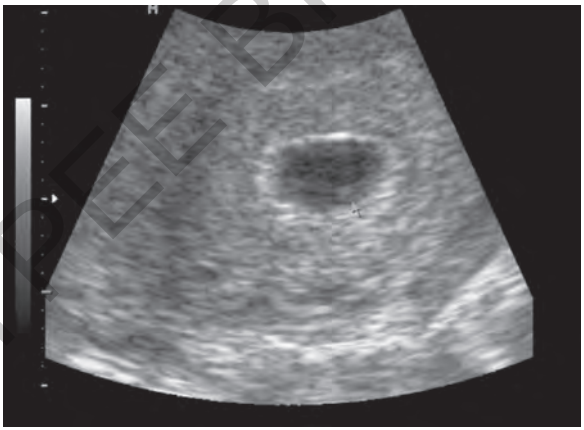

Fig. 4.16: Gestational sac of 5 weeks and 2 days with a yolk sac clearly delineated.

- Gestational sac larger than 8 mm without a yolk sac. (blighted ovum) (Fig. 4.19).

JAYPEE BROTHERS

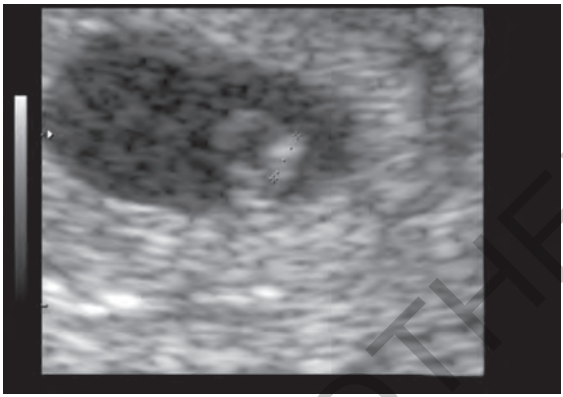

Fig. 4.17: Pregnancy of 5 weeks and 6 days gestation showing a yolk sac and an embryo.

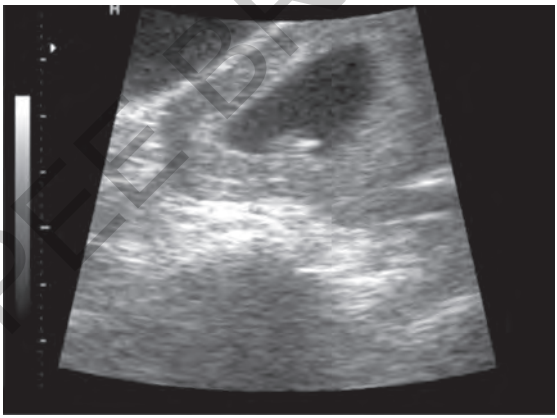

Fig. 4.18: No cardiac activity seen in this 8 mm pulseless attenuated embryo.

- Gestational sac larger than 16 mm without an embryo. (anembryonic pregnancy) (Fig. 4.20).
- Abnormally large or irregular or small amniotic sac (Fig. 4.21).

JAYPEE BROTHERS

for detailed information on obstetrics & gynecology books, visit our website www.jaypeebrothers.com, for detailed informatio

Step by Step®
Ultrasound in Obstetrics

Salient Features

- Ultrasonography is a very important diagnostic tool in obstetrics to access fetal wellbeing congenital anomalies, presentation, biometric measurement, placental localization and uteroplacental flow
- Today ultrasound has move from the radiology department to the labor room and obstetrician's office
- After the great enthusiasm and response shown by readers to the previous editions, the authors have come out with the third edition adding new chapters and upgrading it with recent ultrasound images, flowcharts and tables to act as a ready-reckoner for the busy obstetricians.

Narendra Malhotra is a great academician and medical teacher of this field and has given many practical tips for these procedures. He is currently President of INSARG. He is Past President of FOGSI, ISAR, ISPAT, IFUMB; Vice President of WAPM & SAFOG and a stalwart in the field of infertility has been teaching the subject for years.

Nidhi Gupta is a Professor of Obstetrics and Gynecology at SN Medical College, Agra with a vast experience in the field of Obstetrics and Gynecology. She is an excellent teacher and academician with a passion for teaching.

Neharika Malhotra is a young dynamic obstetrician and gynecologist from Agra. She is a bright upcoming star in the field of infertility with new ideas and methodology of teaching. Chair YTP committee FOGSI.

Jaideep Malhotra is a great academician and medical teacher of this field and has given many practical tips for these procedures. She is Past President of FOGSI, ASPIRE, ISAR, IMS; President of SAFOM & ISPAT and a stalwart in the field of infertility has been teaching the subject for years.

Kuldeep Singh is an experienced sonologist of India.

Available at all medical bookstores
or buy online at www.jaypeebrothers.com



JAYPEE BROTHERS
Medical Publishers (P) Ltd.
www.jaypeebrothers.com

Join us on facebook.com/JaypeeMedicalPublishers

Shelving Recommendation
OBSTETRICS & GYNECOLOGY

