osite www.jaypeebrothers.com, for detailed information on pediatrics books, visit our website www.jaypeebrothers.com

INDIAN ACADEMY OF PEDIATRICS

Celebrating 50 years
Passion, Quality and Innovation in Healthcare Publishing

IAP Textbook of Pediatric Neurology

Editors-in-Chief
Anoop Verma
PAM Kunju

Associate Editors
TM Anandakeshavan
Sujata Kanhere

Forewords
Santosh T Soans
Digant D Shastri
Remesh Kumar R

SECOND EDITION



Get Supplementary Videos Access at **emedicine360.com**

Common Neurological Disorder

JAYPEE

Contents

Chapter 1. Approach to Neurological Assessment in Children 1

PAM Kunju

- History 1
- Neurological Examination 2
- General Examination 2
- Higher Cortical Function Tests 2
- Examining the Motor System 4
- Reflexes 7
- Coordination and Abnormal Movement 8

Chapter 2. Approach to Localization of Neurological Disorders 10

PAM Kunju

- Anatomy 10
- Brain 11
- Limbic System 12
- Subcortical Structures 12
- Spinal Cord 16
- Localization of Neurological Lesion 16

Chapter 3. Approach to Congenital Malformation of Brain 20

TM Anandakeshavan

- Incidence 20
- Etiology 20
- Classification 20
- Treatment of Congenital Brain Malformations 30

Chapter 4. Approach to Abnormal Head: Size and Shape 33

Anoop Verma

- Head Circumference Measurement 33
- Abnormal Head Circumference 33
- Clinical Pointers for Abnormal Head Growth 34
- Abnormal Shape of Head 37

Chapter 5. Approach to Developmental Delay in Children 42

PAM Kunju

- Global Developmental Delay 42
- Examination 44
- Developmental Assessment in Office Practice 47
- Developmental Observation Card 49
- Hemisyndromes 51
- Formulating the Diagnosis 52
- Causes of Developmental Delay 53
- Investigations 54
- Treatment 55
- Prognosis 55
- Certain Anatomical Patterns 56
- Some Developmental Disorders 56

Chapter 6. Approach to Intellectual Disability and Specific Learning Disorder 63

Himani Bhasin, Suvasini Sharma

Intellectual Disability 63

- Definition 63
- Epidemiology 64
- Etiology 64
- Clinical Features 64
- Differential Diagnosis 64
- Diagnosis 64
- Management 65

Specific Learning Disorder 66

- Definition 66
- Epidemiology 66
- Clinical Features 67
- Severity Classification of Specific Learning Disorder 68
- Diagnosis 68
- Management 69
- Interventions for Specific Learning Disabilities 69

- Special Education Services 69
- Other Treatments 69

Chapter 7. Approach to Autism 71

PAM Kunju

- Autism Features 71
- Autism 71
- Social Communication Deficits 73
- Repetitive Behavior and Restricted Interests 73
- Severity Ratings 74
- Communication Deficits in Autism 74
- Autism: Play 74
- Cognitive Dysfunction in Autism 74
- Restricted and Repetitive Patterns 74
- Tools for Diagnosis of Autism Spectrum Disorder 75
- Comorbid Medical Conditions 75
- Early Recognition 75
- Management 76
- Pharmacologic Therapies 77
- Autism: Differential Diagnoses 77
- Childhood Disintegrative Disorder (Heller Dementia) 79
- Some Investigations 80

Chapter 8. Approach to Inborn Errors of Metabolism in Neonate, Infant, and Children 81

Ramesh Konanki, Lokesh Lingappa

- Inborn Errors of Metabolism: Overview 81
- Classification of Inborn Errors of Metabolism 81
- Common Presentations of Inborn Errors of Metabolism 82
- Approach and Evaluation of Children with Suspected Inborn Errors of Metabolism 84
- Investigations 87
- Management 87
- Asymptomatic Neonate with Inborn Errors of Metabolism Suspected due to Previous Sibling Death 90
- Metabolic Autopsy 91

Chapter 9. Approach to Neuronal Migration Disorders 92

Arundhathi Patil

- Lissencephaly 93
- Heterotopia 96
- Polymicrogyria 97
- Schizencephaly 98
- Focal Cortical Dysplasia and Hemimegalencephaly 98
- Tubulinopathies 99

Chapter 10. Approach to Acute Febrile Encephalopathy 101

D Kalpana, PAM Kunju

- Clinical Presentation 103
- Investigations 103
- Sepsis-associated Encephalopathy 105
- Febrile Infection-related Epilepsy Syndrome 105

Chapter 11. Approach to Acute Encephalitis (Indian Scenario) 109

Kalpana Dutta, Supratim Dutta

- Epidemiology 110
- Etiology 110
- Pathogenesis and Pathology 111
- Clinical Manifestations 112
- Diagnosis 113
- Differential Diagnosis 114
- Investigations 114
- Management 116
- Treatment of Specific Cause if Any Role of Steroids 118
- Prevention 118
- Prognosis 119

Chapter 12. Approach to Childhood Neurotuberculosis in Children 121

Rajeshwar Dayal, Madhu Singh

- Epidemiology 121
- Etiopathogenesis 121
- Classification 122
- Clinical Presentation 122
- Medical Research Council Staging of Tuberculous Meningitis 123
- Diagnosis 123

- Investigations 124
- Cerebrospinal Fluid Sampling and Testing 125
- Differential Diagnosis of Tuberculous Meningitis 126
- Treatment 126
- Course and Complications of Tuberculous Meningitis 129
- Sequelae of Tuberculous Meningitis 130
- Tuberculoma 130
- Spinal Tuberculosis in Children 132
- Paradoxical Response to Chemotherapy 133
- Control of Infection 133
- Prevention of Infection—BCG Vaccine 133

Chapter 13. Approach to Cerebral Malaria 135

AK Rawat

- Cerebral Malaria 135
- Definition 135
- Pathophysiology 135
- Clinical Features 136
- Diagnosis of Cerebral Malaria 136
- Investigations 136
- Management 137
- Prevent Recrudescence and Transmission 138
- Prognosis 139

Chapter 14. Approach to Neurocysticercosis in Children 140

Anoop Verma, Nitin Maheshwari

- When to Suspect Neurocysticercosis? 140
- What are the Different Types of Neurocysticercosis? 141
- What are the Different Stages of the Cysticercus Cyst? 141
- How to Confirm the Diagnosis of Neurocysticercosis? 141
- How to Differentiate Between Tuberculoma and Neurocysticercosis? 145
- How to Treat Neurocysticercosis? 145
- How to Treat Seizures in Neurocysticercosis? 146

Chapter 15. Approach to Fungal Infections of Central Nervous System 149

Vineet Bhushan Gupta, Mahak Bansal

- Etiology 149
- Epidemiology and Risk Factors 149
- Pathogenesis 152
- Clinical Syndromes 152
- Diagnosis 154
- Treatment 158

Chapter 16. Approach to Altered Sensorium 164

Nitish Vora

- Epidemiology 164
- Definitions: Coma and Other States of Impaired Consciousness 164
- Etiology 165
- Evaluation of the Comatose Child 165
- Algorithm 166
- Investigations 167
- Management 169
- Differential Diagnosis 169
- Prognosis 171

Chapter 17. Approach to Acute Stroke Syndrome 172

Shekhar G Patil

- Definition 172
- Arterial Ischemic Strokes 172
- Venous Sinus Thrombosis 179
- Hemorrhagic Strokes 180

Chapter 18. Approach to Febrile Seizures and Fever-related Epilepsies 183

Sujata Kanhere

- Definition 183
- Classification of Febrile Seizures 183
- Fever-related Epilepsies 184
- Etiology of Febrile Seizures and Fever-related Epilepsies—Genetic Basis and Risk Factors 186
- Approach to a Child with Febrile Seizures 187
- Prognosis 190

Chapter 19. Approach to a Child with Epilepsy 192
KN Shah
- Definition 192
- Stepwise Approach in a Child with Suspected Seizure Disorder 192

Chapter 20. Approach to Self-limited Focal Epilepsies of Childhood 205
Neelu Desai
- Childhood Epilepsy with Centrotemporal Spikes 205
- Early-Onset Childhood Occipital Epilepsy (Panayiotopoulos Syndrome) 208
- Benign Partial Epilepsy of Infancy 210

Chapter 21. Approach to Intractable Seizures 213
Anaita Udwadia Hegde, Trupti Jadhav
- Definition 213
- Factors Determining Intractable Epilepsy 213
- Mechanism of Drug Resistance 214
- Management of Refractory Epilepsy 215

Chapter 22. Approach to Seizures Imitator and Seizure Mimics 222
Neeta Naik
- Neonatal Seizure Mimics 222
- Infantile Mimics 222
- Paroxysmal Torticollis 225
- Benign Paroxysmal Vertigo 225
- Alternating Hemiplegia of Childhood 225
- Benign Myoclonus of Infancy 226
- Shuddering Attacks 226
- Hyperekplexia 227
- Spasmus Nutans 228
- Gastroesophageal Reflux 228
- Jactatio Capitis 228
- Self-gratification 228
- Childhood Mimics 229
- Cyclic Vomiting Syndrome 230
- Nonepileptic Seizure 231
- Syncope 231
- Tics 232

Chapter 23. Approach to Dizziness and Vertigo in Children 234
Kavita Srivastava
- Outlines 234
- What do You Mean by "Dizziness"? 234
- Faints/Light Headedness/ Presyncope 234
- Vertigo 235

Chapter 24. Approach to Neonatal Seizures 242
Sujata Kanhere
- Epidemiology/Incidence 242
- Definition 242
- Pathophysiology 242
- Classification of Neonatal Seizures 243
- Relation of Seizure to Electroencephalogram 245
- Etiology of Neonatal Seizures 246
- Differential Diagnosis 248
- Approach to Neonatal Seizures 249
- Management of Neonatal Seizures 250
- Prevention of Neonatal Seizures 251
- Long-term Outcome 252

Chapter 25. Approach to Management of Status Epilepticus 254
Arun Agrawal, Pranati Sharma Agrawal
- Definition 254
- Outcome of Status Epilepticus 254
- Morbidity and Mortality 254
- Classification of Status Epilepticus 255
- Etiology 255
- Causes 255
- Drugs which can Cause Seizures 255
- Hemodynamics 255
- Pathophysiology 256
- Management Goals 256
- Supportive Care 256
- Anticonvulsants 256
- Treatment 256
- Rapid-acting Anticonvulsants 257
- Treatment of Refractory Status Epilepticus 259
- Treatment of Status Epilepticus: What Now? 259
- Nonintravenous Status Epilepticus 259

- Management after Stopping of Convulsions 259
- Complications 261
- Additional Therapies in Management of Refractory Status Epilepticus 261
- Surgical Management of Refractory Status Epilepticus 262

Chapter 26. Current Guidelines for Diagnosis and Management of Childhood Epilepsy 265

Sheffali Gulati, Priyanka Madaan, Prateek Kumar Panda, Rachana Dubey, Vishal Sondhi

- Objectives 265
- Recommendations 266
- Status Epilepticus 281
- Domiciliary Management of Acute Seizure and Epilepsy Awareness 284

Chapter 27. Approach to Neurological Emergencies in Children 293

Amarjeet Wagh, Vasant Khalatkar

- Raised Intracranial Pressure in Children 293
- Approach to Acute Stroke Management 296
- Acute Movement Disorders in Children 298
- Neuromuscular Emergencies in Children 299

Chapter 28. Approach to Child with Cerebral Palsy 302

Sharad Sharma, Nitin Maheshwari

- How to Recognize Cerebral Palsy? 302
- Does this Child have Cerebral Palsy? 303
- Types of Cerebral Palsy 304
- Parts of the Body Affected 305
- Could it be a Progressive or Treatable Neurological Disorder rather than Cerebral Palsy? 306
- What is the Functional Status of the Child? 307
- Does this Child have any Other Comorbidity Associated with Cerebral Palsy? 309
- Does this Child Need Medicines? 309
- Could any Multidisciplinary Support/ Surgical Intervention Help? 310
- Can Stem Cell Therapy Help? 311

Chapter 29. Approach to Early Intervention Therapy in Cerebral Palsy 312

DY Shrikhande, Sheila Shrikhande

- Definition of Early Intervention 312
- Stimulation 313
- Physiotherapy and Occupational Therapy 316
- Orthotic Aids 317
- Drooling 317
- Activities of Daily Living 317
- Cognitive and Adaptive Development 318
- Parental Role 318

Chapter 30. Approach to Neurodegenerative Disorders 321

PAM Kunju

- Clinical Clues of Neurodegeneration 321
- Inheritance 322
- Approach to a Child with Acute Encephalopathy (Small Molecule Disorders) 322
- Organic Acid Disorders 323
- Urea Cycle Defects 325
- Approach to a Child with Chronic Encephalopathy 327
- Formulating the Diagnosis 329
- Investigations 332
- Treatment 337

Chapter 31. Approach to Demyelinating Disorders of Central Nervous System 339

Vineet Wankhede, Sanjeev Joshi

- Etiologies 339
- Acquired Demyelinating Encephalomyelitis 340

- Transverse Myelitis 343
- Neuromyelitis Optica 343
- Schilder's Disease/Myelinoclastic Diffuse Sclerosis 345
- Multiple Sclerosis 345
- Clinically Isolated Syndromes 347
- Prognosis after an Initial Event of Demyelination 347
- Differential Diagnosis of Demyelination in Children 348

Chapter 32. Approach to Movement Disorders in Children 351

Anoop Verma

- Definition 351
- Types 351
- Differences from Epilepsy 352
- Approach to Diagnosis 352
- Pathophysiology 352
- Clinical Presentation and Etiology 353
- Classical Signs of Chorea 353
- Paroxysmal Movement Disorders 354
- Self-injurious Behavior 355
- Drug-induced Movement Disorders 355
- Genetics in Movement Disorders 356
- Odd Movement Disorders 358
- Management 359
- Drugs Used in Movement Disorders 360

Chapter 33. Approach to Opsoclonus Myoclonus Syndrome 363

Jitendra Sahu, Razia A Kadwa

- Historical Note 363
- Incidence and Associations 363
- Clinical Features 363
- Investigations 365
- Pathogenesis 366
- Management 366
- Outcome 367

Chapter 34. Approach to a Child with Ataxia 368

D Kalpana

- Points to be Noted in the History 368
- Head-to-Foot Examination 369
- Onset of Ataxia 369
- Etiology 369
- Investigations 373
- Treatment 374

Chapter 35. Approach to Neuromuscular Diseases 375

D Kalpana, Bindu Thankappan

- Approach to Diagnosis 376
- Floppy infant 376
- Child with Musle Weakness 378

Chapter 36. Approach to Child with Acute Flaccid Paralysis 380

Arijit Chattopadhyay

- Clinical Approach to a Child with Acute Flaccid Paralysis 380
- Common Causes of Acute Flaccid Paralysis 383

Chapter 37. Approach to Paraplegia 386

Arpita Thakker Adhikari

- Classification 386
- Clinical Approach to a Child with Paraplegia 387
- Examination 389
- Approach to a Child with Acute Paraplegia 389
- Supportive Therapy 392
- Approach to Chronic Paraplegia 392

Chapter 38. Approach to Floppy Infant 401

Lokesh Lingappa, Ramesh Konanki

- Clinical Presentation and Appearance 401
- Diagnostic Approach 401
- Investigations 403
- Therapeutic Approach 405

Chapter 39. Approach to a Child with Myopathy and Myositis 406

Anju Agarwal, Neha Garg

- Congenital Myopathies 406
- Muscular Dystrophies 409
- Inflammatory Myopathies 410
- Metabolic Myopathy 411
- Channelopathies 412

Chapter 40. Approach to Headache in Children 414
Vrajesh Udani, Payal Shah
- Childhood Headache Patterns 414
- Classification of Headaches 414
- Evaluation of a Child with Headache 416
- Red Flags for Secondary Headache 417
- Treatment 417

Chapter 41. Approach to Neurocutaneous Syndrome 420
Siddharth Shah, Nitin Maheshwari
- Neurofibromatosis Type 1 420
- Neurofibromatosis Type 2 422
- Tuberous Sclerosis Complex 423
- Sturge-Weber Syndrome 425
- Ataxia Telangiectasia 426
- Von Hippel-Lindau Syndrome 427

Chapter 42. Approach to Nutritional Disorders of Nervous System 429
Sanwer Agrawal
- Protein-Calorie Malnutrition 429
- Cobalamin (Vitamin B_{12}) 429
- Folate Deficiency 432
- Thiamine 433
- Niacin 434
- Pyridoxine 435
- Vitamin E 436
- Vitamins A and D 436
- Copper Deficiency 437

Chapter 43. Approach to Rabies 439
SM Dewangan, G Malini
- Epidemiology 439
- Mode of Transmission 439
- Etiopathology 440
- Clinical Features 440
- Decision to Treat 441
- Management of Animal Bite Wound 443
- Treatment of Clinical Rabies 448
- Few Words for Pet Owners 449
- Recent Advances 449
- Research Priorities 450

Chapter 44. Approach to Neurotoxic Snake Envenomation 451
Meenakshi Girish, Girish Subramanium
- Mechanism of Neurotoxicity 452
- Management 455
- First Aid 455
- Initial Treatment 455

Chapter 45. Fundus Examination in Children 460
Kiran Makhija
- Normal Fundus—Child 460
- Pathophysiological Changes 460
- Common Findings in Fundus 460
- Few Case Studies in Fundus 465

Chapter 46. Approach to Cerebrospinal Fluid Interpretation in Children 467
KP Sarbhai
- What does the Cerebrospinal Fluid do? 468
- Blood-Brain Barrier 469
- Lumbar Puncture 469
- Cisternal Puncture 470
- Analyzing Cerebrospinal Fluid 471

Chapter 47. Approach to Neurophysiological Investigations 475
Amarjeet Wagh
- Electroencephalography 475
- Evoked Potentials 491
- Nerve Conduction Study and Electromyography 495
- Motor Unit Recruitment 499

Chapter 48. Approach to Basics of MRI and CT Scan 500
PAM Kunju, Jayashri L
- Computed Tomography 500
- Magnetic Resonance Imaging 501
- CT and MRI Techniques 505
- MRI Techniques 505
- Some Neuroimaging Features 509
- Some Comparative Scans 514

***Drugs Appendix* 517**
Jeeson Unni

Index *559*

CHAPTER 2

Approach to Localization of Neurological Disorders

PAM Kunju

INTRODUCTION

As in any other system, central nervous system (CNS) disorders also have a predilection for region, i.e. tropism. Thus, exactly localizing to a particular part of neuraxis, pathology and etiology can be predicted, e.g. localizing weakness to anterior horn cell in a child with fever would be poliomyelitis. Similarly, in a child with impaired speech and focal seizures one can localize to one side of cerebral hemisphere and with fever it could be Herpes simplex encephalitis. This is because polio virus affects anterior horn cell and Herpes simplex produces focal encephalitis. Similarly, all etiological processes have such a tropism and in neurology many disorders are also termed according to the site of involvement. Examples are "cerebral" palsy, "spinal" muscular atrophy, "facioscapulohumeral" muscular dystrophy, etc. Adult disorders like amyotrophic lateral sclerosis also describe the site of involvement. Amyotrophy means muscle wasting without sensory involvement and lateral sclerosis means degeneration of the lateral column (corticospinal tract of spinal cord). Thus, if one can identify the muscle wasting and pyramidal signs together with absence of sensory involvement, disease can be localized to anterior horn cell and pyramidal tract and etiology can be easily understood. That is the power of localization.

In all the above examples, the course of the illness, acute, subacute, intermittent, or chronic (static, or progressive), has provided a clue to the nature of the pathologic process.

So, localization is not for harassing the students but for an easy accurate diagnosis, thereby avoiding unwanted highly expensive investigations.

For pediatric neurology diagnosis, follow these steps:

- Recognize the functional impairment
- Identify each site of nervous system involvement = localization
- Etiological diagnosis or a diagnostic list
- Expert referrals and investigation for a final diagnosis.

A working knowledge of anatomy is required for the better understanding of the disorders of the nervous system and will help further in localization. It is the nervous system that receives and interprets various sensory information, formulates and executes a variety of complex motor movements, and engages in deductive and inductive logic. Thus, it is the most complex and elegant computing device that exists.

ANATOMY

The nervous system is divided into three parts: Central, peripheral, and autonomic.

The *CNS* is formed by the brain and spinal cord and the term *peripheral nervous system*

JAYPEE BROTHERS

refers to cranial nerves (CNs), the spinal nerves, the ganglia associated with the cranial and spinal nerves, and the peripheral receptor organs. The autonomic nervous system (sympathetic and parasympathetic) is the part of the nervous system involved in the regulation of visceral function; its component parts are located partly within the CNS and partly within the peripheral nervous system.

Meninges and Intervening Spaces

The brain is protected by skull, meninges, and cerebrospinal fluid (CSF). The meninges are organized into three layers named in order from outside: Dura mater, arachnoid mater and pia mater. It is the pia and arachnoid mater that is involved in meningitis. The epidural space is located between the dura mater and the bony skull (Fig. 1). Trauma to the skull with rupture of the middle meningeal artery leads to epidural hemorrhage [lens shaped in computed tomography (CT) scan]. The subdural space lies between the dura mater and arachnoid mater. Trauma to the skull may rupture the bridging veins leading to subdural hemorrhage (concavo convex in CT scan). The subarachnoid space is located between the arachnoid mater and pia mater which contains CSF and cerebral blood vessels. Rupture of these vessels leads to subarachnoid hemorrhage (in the cisterns and sulcal spaces). The subarachnoid space underlying the superior sagittal sinus contains arachnoid granulations, sites of CSF absorption into the superior sagittal sinus.

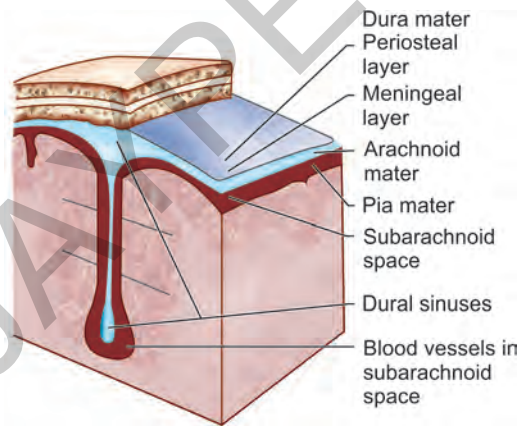

Fig. 1: Organization of meningeal layers and dural sinus.

BRAIN

Each hemisphere of the brain is divided into four lobes. The frontal lobe is separated from the parietal lobe by the central sulcus (Rolandic). The lateral (Sylvian) fissure separates the frontal lobe from the temporal lobe. A line drawn from the parieto-occipital sulcus down to the preoccipital notch separates the parietal lobe from the occipital lobe. The cerebral cortex is divided into sensory, motor, and association areas. Sensory areas receive sensory input and motor areas control movement of muscles. Association areas are involved with more complex functions, such as learning, decision-making, and complex movements, such as writing. The frontal lobe is associated with movement (precentral gyrus—primary motor area), motor speech (Broca area), and planning (problem solving, reasoning, and emotions).

The parietal lobe is associated with perception of touch, temperature, pressure, and pain [postcentral gyrus—primary sensory (somesthetic) area], behavioral interaction of an individual with the surrounding space (superior parietal lobule), and sensory integration (supramarginal gyrus and angular gyrus).

The temporal lobe is associated with hearing (gyri of Heschl—primary auditory area), comprehension of speech (Wernicke area), and forming memories.

The occipital lobe subserves visual perception. The primary visual cortex located in the walls and depths of the calcarine fissure is concerned with initial stages of visual processing and the form and color of objects are perceived by surrounding higher order visual areas on the occipitotemporal gyrus (fusiform gyrus).

JAYPEE BROTHERS

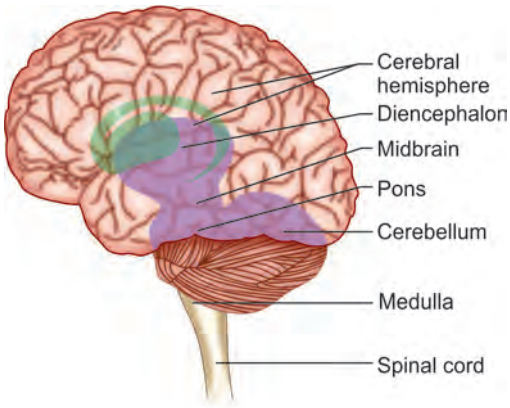

Fig. 2: Simplified organization of the brain and spinal cord for the localization of a lesion.

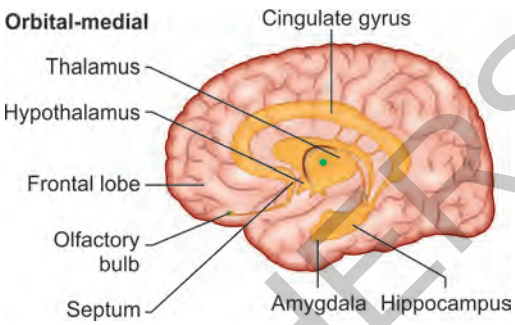

Fig. 3: Diencephalon and limbic lobe.

Hemispheric dominance—certain parts of the cortex show dominance in their function. Left is dominant for speech, writing, calculation, abstraction, logical analysis and right for music, stereognosis, spatial perception, nonverbal ideation, and intuition (Fig. 2).

LIMBIC SYSTEM

The structures for emotions, learning, memory, and their interconnections are grouped into a single system called limbic system. Limbic lobe [structures that form a limbus (ring or border) around the brainstem] includes the subcallosal gyrus, cingulate gyrus, isthmus, parahippocampal gyrus, and uncus. The limbic lobe and the structures connected to it are collectively called limbic system.

SUBCORTICAL STRUCTURES

The subcortical structures include the basal ganglia (caudate, putamen and globus pallidus), thalamus, subthalamic nucleus, hypothalamus, red nucleus, substantia nigra, cerebellum, and brainstem, and their interconnecting pathways.

Gray versus White Matter

Gray matter = cell bodies. It is found in cerebral cortex, deep nuclei, and ganglia. Lesions in gray matter are profound and permanent.

White matter = axons covered with myelin. Found in tracts, radiations, commissures, roots. Lesions often recover well.

Diencephalon

Di = two encephalon, i.e. thalamus and hypothalamus (Fig. 3)

- Thalamus is the sensory input relay station
  - The lateral geniculate body (visual relay station) and medial geniculate body (auditory station) are in the thalamus
- Hypothalamus is the autonomic control center. It controls neuroendocrine/pituitary functions. Sympathetic nerve cell bodies are housed here
  - Mammillary bodies are part of the memory circuit, act as a relay for impulses coming from the amygdalae and hippocampi, via the mammillothalamic tract to the thalamus and are

JAYPEE BROTHERS

the major site of memory-disturbing pathology (Wernicke and Korsakoff syndromes).

Brainstem and Cranial Nerves

The brainstem consists of the midbrain, pons, and medulla. It contains the nuclei of the CN in an ascending order and tracts running to and from the brain, cerebellum, and spinal cord. Autonomic centers that regulate cardiovascular function, breathing, and eating behavior as well as acoustic and vestibular relay nuclei are also in the brainstem. CN can be remembered as third and fourth in midbrain, fifth, sixth, seventh, and eighth in pons and ninth, tenth, eleventh, twelfth in medulla (Fig. 4).

The rule of four of the brainstem: A simplified method for understanding brainstem anatomy:

1. There are four structures in the midline "beginning with M"
2. There are four structures to the side beginning with S
3. There are four CN in the medulla, four in the pons, and four above the pons (two in the midbrain)

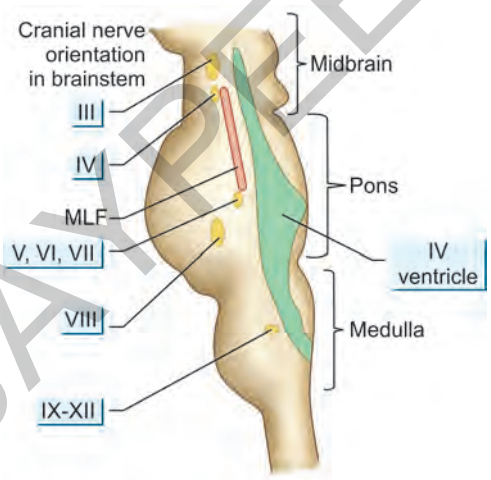

Fig. 4: Brainstem and the distribution of the cranial nerves.

4. The four motor nuclei that are in the midline are "3, 4, 6" and 12 (5, 7, 9, and 11 are in the lateral brainstem)

The four medial structures and the associated deficit are:

1. The motor pathway (or corticospinal tract): Contralateral weakness of the arm and leg
2. The medial lemniscus: Contralateral loss of vibration and proprioception in the arm and leg
3. The medial longitudinal fasciculus: Ipsilateral internuclear ophthalmoplegia (failure of adduction of the ipsilateral eye toward the nose and nystagmus in the opposite eye as it looks laterally)
4. The motor CN nucleus: Ipsilateral loss of the CN that is affected (3, 4, 6, or 12)

The four lateral structures (side) and the associated deficit are:

1. The spinocerebellar pathways: Ipsilateral ataxia of the arm and leg
2. The spinothalamic pathway: Contralateral alteration of pain and temperature affecting the arm, leg, and rarely the trunk
3. The sensory nucleus of the fifth: Ipsilateral alteration of pain and temperature on the face in the distribution of the fifth CN (this nucleus is a long vertical structure that extends in the lateral aspect of the pons down into the medulla)
4. The sympathetic pathway: Ipsilateral Horner syndrome, that is partial ptosis and a small pupil (miosis).

Anteroposterior Brainstem Anatomy

Anterior ("basis")—descending corticospinal tracts go down through the cerebral peduncles (midbrain) to the basis pontis (pons) to the pyramids (medulla). Posterior ("tectum" and "velum") has the CSF spaces, including cerebral aqueduct (midbrain), fourth ventricle (pons), and subarachnoid openings (medulla). The tectum is the roof over the cerebral aqueduct.

JAYPEE BROTHERS

Middle ("tegmentum") has long sensory tracts, CN nuclei, visceral and special motor centers.

Sensory tracts for pain/temperature travels laterally (spinal lemniscus), and touch/vibration (medial lemniscus) travels medially. Sensory tracts in the brainstem are called lemnisci. They travel to thalamus and lies medial to lateral throughout brainstem in this order: Medial lemniscus, trigeminal lemniscus, spinal lemniscus, lateral lemniscus (MTSL).

Rostrocaudal Brainstem Anatomy

Midbrain (top of the brainstem) includes substantia nigra, and periaqueductal gray matter, and is closely linked to basal ganglia and thalamus. The midbrain also regulates vertical gaze and eye convergence (Fig. 5).

Pons (middle of the brainstem) (Fig. 6) includes the locus coeruleus and raphe nuclei (arousal, mood). Pons is closely linked to the cerebellum.

The pons also regulates horizontal gaze. Medulla (bottom) regulates respiratory and visceral functions (Fig. 7). It also regulates gaze-holding.

Cranial Nerves

Twelve pairs of CN and their specific functions in the body:

1. Olfactory nerve—smell

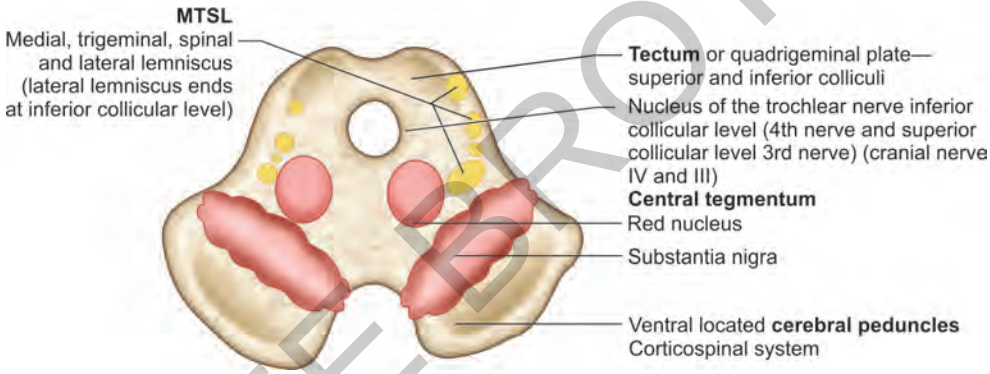

Fig. 5: Section through the midbrain.
(MTSL: medial, trigeminal, spinal, and lateral lemnisci).

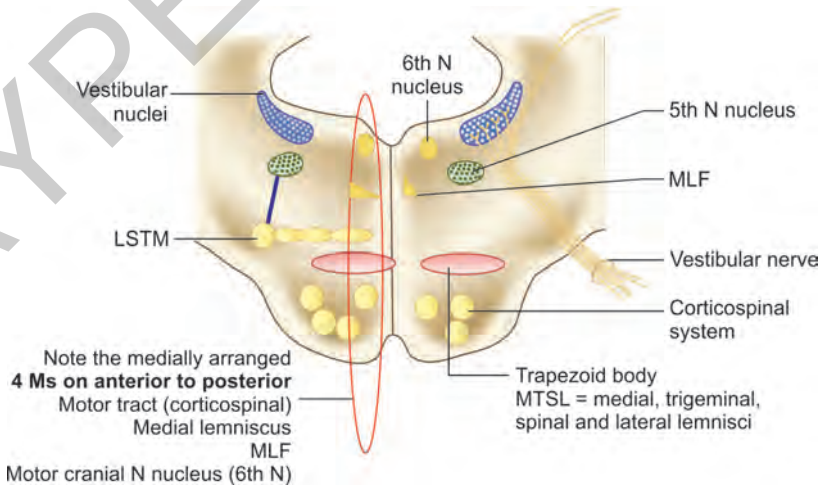

Fig. 6: Simplified plan of pons.

JAYPEE BROTHERS

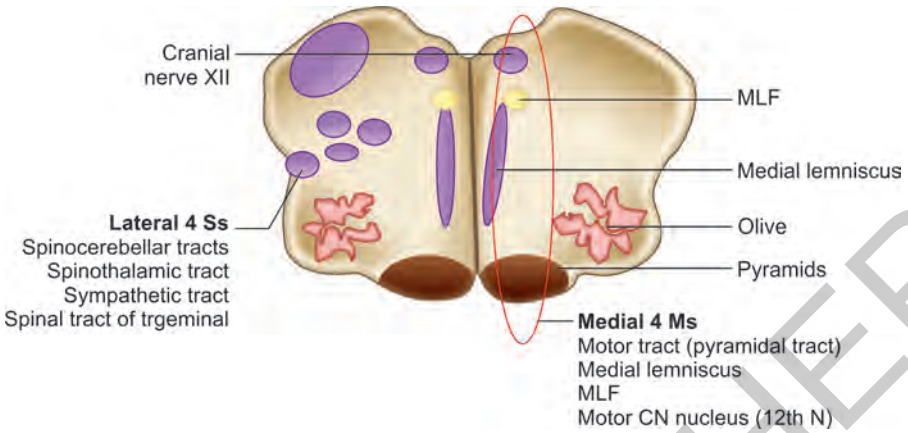

Fig. 7: Section of medulla.

2. Optic nerve—vision
3. Oculomotor—medial and upward eye movements, eyelid opening
4. Trochlear—down movement when the eye is adducted
5. Trigeminal—muscles of mastication (chewing), facial sensations
6. Abducens—lateral eye movements
7. Facial—facial expressions, taste
8. Vestibulocochlear—hearing, balance
9. Glossopharyngeal—taste, swallowing
10. Vagus—swallowing, taste, visceral function
11. Accessory—neck and shoulder muscles
12. Hypoglossal—tongue movement.

Cerebellum

Behind the cerebrum in the posterior fossa is the cerebellum. It is separated from the cerebral hemispheres by the tentorium cerebelli. The cerebellum is primarily a movement control center, responsible for:

- Voluntary muscle movements
- Fine motor skills
- Maintaining balance, posture, and equilibrium. The cerebellum also plays a role in the regulation of gaze-related movements of the eyes and in ensuring the smooth complementary functioning of agonist and antagonist muscle groups.

These information are processed in three parts of the cerebellum (Fig. 8):

1. *Neocerebellum (cortical)*: Impulses from the cerebral cortex for the initiation and planning of voluntary movement travel in the *corticopontocerebellar pathway*, by way of the middle cerebellar peduncle, to the neocerebellum (lateral cerebellar hemispheres). This part of the cerebellum is mainly responsible for the fine control of very precise movements particularly of the limbs (especially the hands and fingers) and of the motor apparatus of speech.
2. *Paleocerebellum (spinal)*: Information regarding joint position and muscle tone from peripheral proprioceptors (muscle spindles and Golgi tendon organs) travels by the way of *anterior and posterior spinocerebellar tracts*, through the inferior and superior cerebellar peduncles to the paleocerebellum (vermis and the paraflocculus).
   - This part controls the smooth, synergistic functioning of the muscles when the individual stands or walks.
3. *Archicerebellum (vestibular)*: Impulses from the *vestibular system* travel by way of the inferior cerebellar peduncle to

JAYPEE BROTHERS

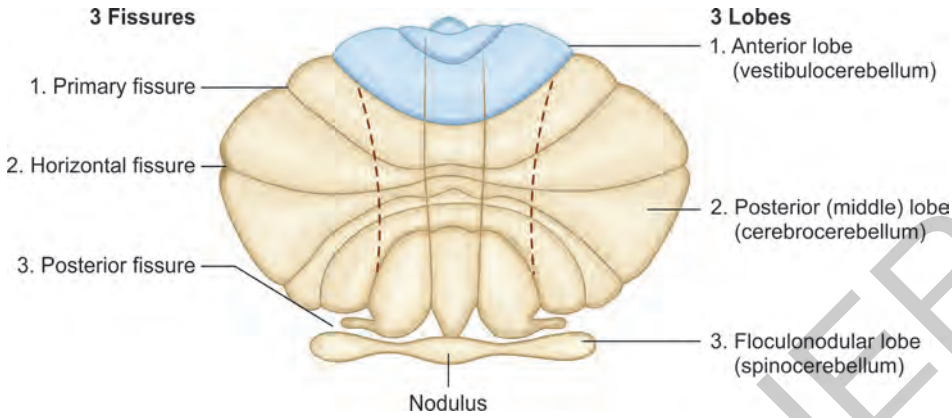

Fig. 8: Easy 3s to understand the cerebellum.

the archicerebellum (nodulus and flocculus).
  - This part of the cerebellum serves to keep the upright body in balance during standing and walking. [Anatomical details can be remembered as easy 3s (Fig. 8)]
- Lesions and effects:
  - Basal lesions near the midline (nodulus and flocculus) produce truncal ataxia and the postural imbalance, which are particularly evident when the patient tries to sit
  - Lesions near the midline vermis produce impaired coordination of stance and gait
  - Lesions of the cerebellar hemispheres (mainly affecting the neocerebellum) produce impaired coordination of (fine) movements of the limbs on the side of the lesion.

SPINAL CORD

Spinal cord extends from the level of the cranial border of the atlas, where it is continuous with the medulla, to the lower border of the first lumbar vertebra. At birth, it extends to the upper border of the third lumbar vertebra. It has 31 segments corresponding to the spinal nerves (8 cervical, 12 thoracic, 5 lumbar, 5 sacral, and 1 coccygeal). Owing to the different growth rates of the spinal cord and the vertebral column, even though in the cervical region, the spinous process of a particular vertebra matches the level of the corresponding cord segment; in the upper thoracic region, there is a discrepancy of two segments (e.g. the fourth thoracic spinal segment overlies the sixth) and in the lower thoracic region, there is a discrepancy of three segments. The eleventh thoracic spinous process overlies the third lumbar cord segment, and the twelfth overlies the first sacral cord segment. Corresponding bodily sensory distribution is shown in Figure 9A.

Cross-sectional anatomy of the spinal cord: Spinal cord consists of the centrally placed gray matter surrounded by white matter which has the ascending and descending tracts. Major tracts are shown in the Figure 9B.

LOCALIZATION OF NEUROLOGICAL LESION

Classically, neurological lesion localization is described using motor deficit. Weakness of one side, i.e. hemiplegia can be associated with same side facial weakness or sensory deficit. Weakness of one side with upper motor neuron

JAYPEE BROTHERS

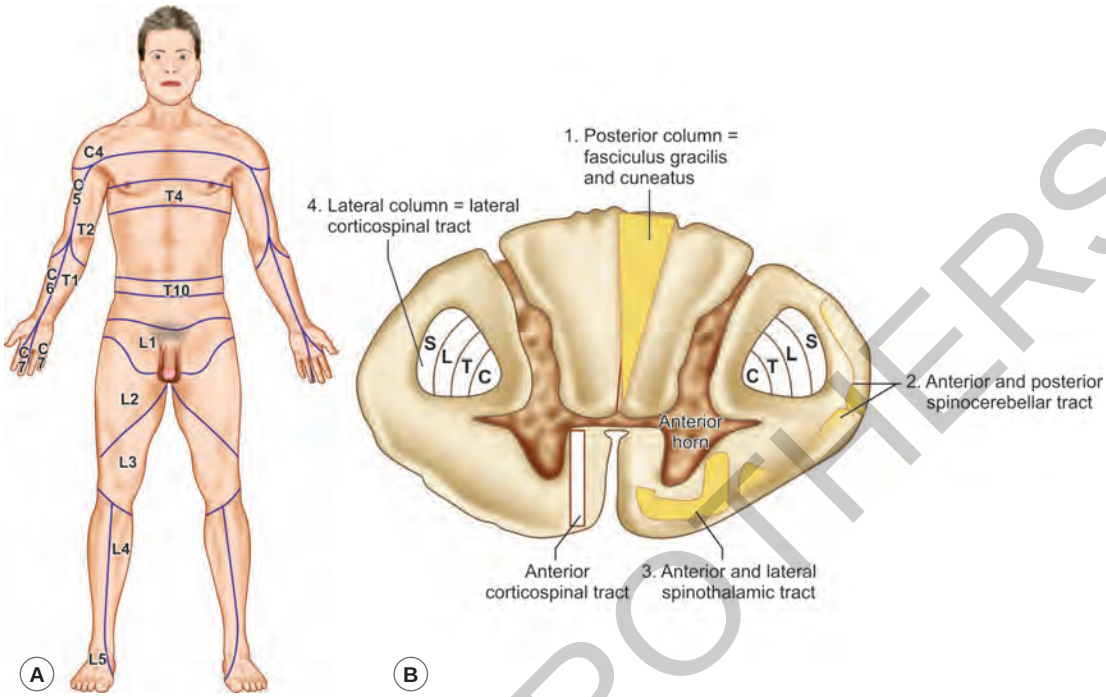

Figs. 9A and B: (A) Sensory segmental distribution; (B) Simplified spinal cord tracts can be learned as pairs. (S: sacral; L: lumbar; T: thoracic; C: cervical)

(UMN) manifestation means pyramidal tract lesion above cervical spinal cord. Further sites can be decided by looking for UMN or lower motor neuron (LMN) CN involvement. Lower motor CN finding means lesion will be at that level and side. For example, twelfth CN palsy is in the medulla. Cranial nerve fifth, sixth, seventh, eighth palsy localizes to pons and third with/without fourth to midbrain. If there is upper motor neuron facial palsy, lesion will always be above pons. Then localization can be done by looking for additional signs like aphasias, apraxias, agnosia, or history of seizure= cortical: Pure hemiplegia = subcortical. Dense hemiplegia will be in favor of internal capsular lesion and associated hemianopia suggests a retrolentiform pathology.

Motor weakness due to spinal cord lesion will usually be associated with sensory tract or root symptoms. Level of spinal cord lesion can be ascertained by looking for reflex or sensory level. Band like sensation or a root symptom or sign is present, easily site of affection can be considered as that segment.

Further delineation of hemicord involvement is determined by finding out motor sign on one side, pain and temperature, sensory loss on opposite side. Lesion will be on the side of motor involvement.

The following constellations of clinical features can help in common situations:

- *Static encephalopathy*: Global developmental delay with dominant motor manifestations—spasticity of extremities in varying degree; speech abnormality, seizures, sensory integration defects
- *Subcortical (e.g. internal capsule) versus cortical lesion*: Weakness affecting the face, arm, and leg with more involvement of upper limb is suggestive of involvement of posterior limb and genu of internal

JAYPEE BROTHERS

capsule. Sensory deficits will be seen, if full posterior limb of the internal capsule is affected. Cortical lesions produce lesser degree of weakness, but higher cortical sensory manifestations, such as aphasia, agnosia, apraxia, and sensory inattention. Cortical lesion will have sensorial changes and seizures also.

- *Brainstem lesions:* In brainstem involvement, commonly seen features are:
  - Lower motor neuron CN lesion
  - Fixed combination of CN palsy
  - Contralateral motor and sensory deficits (crossed hemiplegia)
  - Cerebellar signs
  - Gaze palsy
  - Nystagmus
  - Somnolence
  - Extrinsic brainstem compression—early spasticity, increased intracranial pressure
  - Intrinsic lesion—late increased intracranial pressure, gaze palsy, internuclear ophthalmoplegia, partial third nerve palsy, etc.

Spinal Cord Lesions

- Bladder dysfunction
- Motor and sensory level
- Bilateral or unilateral weakness
- Absence of CN abnormalities
- Spinal tenderness.

Table 1: Sites of lesions causing hemiparesis, and corresponding clinical features.

Cerebrum	• Spastic hemiparesis with facial palsy characterized by: Increased muscle tone • Increased reflexes • Pyramidal tract signs • No atrophy • Associations—cortical sensory deficit, seizure, speech defects
Brainstem	• Spastic hemiparesis, face involved or not depending on level of lesion • LMN cranial nerve deficits contralateral to hemiparesis
Upper cervical spinal cord	Spastic hemiparesis, face spared, possible ipsilateral loss of position and vibration sense and contralateral loss of pain and temperature sense below the level of the lesion (Brown-Séquard syndrome)
Sites of lesions causing para- or quadriparesis, and corresponding clinical features	
Site of lesion	***Clinical features***
Cerebrum (bilateral lesion)	• Clinical picture of "bilateral hemiplegia," (both upper limbs more affected) or cerebral diplegia (both lower limbs more affected) due to a bilateral parasagittal/periventricular cortical lesion
Corticobulbar pathway in the brainstem (bilateral lesion) (e.g. lacunar state)	• Bilateral spasticity with only mild weakness, spastic, small-stepped gait hyper-reflexia, pyramidal tract signs • No sensory deficit • Usually accompanied by pseudobulbar signs (dysarthria, hyper-reflexia of the facial musculature)
Corticospinal pathways in the spinal cord (bilateral lesion), e.g. hereditary spastic paraplegia	• Para- or quadriparesis, face spared, hyper-reflexia, pyramidal tract signs • No sensory deficit • Only mild weakness
Spinal cord transverse, e.g. transverse myelitis—paraplegia or quadriplegia, bladder symptoms at the level of lesion band like hyperesthesia and below, diminished sensation	

JAYPEE BROTHERS

Lower Motor Neuron Localization

After ascertaining that the motor weakness is due to LMN (weakness, wasting, absent reflex, and fasciculations), exact site of affection like anterior horn cell, root, nerve, myoneural junction, or muscle is determined by verifying the distribution of weakness. Proximal weakness is due to either anterior horn cell, root or muscle. Universal reflex loss with fasciculation suggests anterior horn cell and retained ankle jerk suggests muscle disease. Root lesion will have sensory sign or symptom. Symmetric distal weakness denotes peripheral nerve disease. Glove and stocking type of sensory involvement will be seen in such disorders. Myoneural junction disorders will have pure motor weakness with fatigability.

- *Anterior horn cell lesion:*
  - Patchy or segmental weakness
  - Asymmetric muscle weakness with greater involvement of proximal muscle group
  - Muscle atrophy and fasciculation
  - Universal hyporeflexia in SMA
  - Absence of sensory signs
- *Peripheral polyneuropathies*
  - Symmetrical, distal weakness (glove and stocking)
  - Absent ankle jerk
  - Distal sensory
- *Neuromuscular junction disorder:*
  - Fluctuating, asymmetric, oculobulbar, and proximal limb weakness
  - Normal muscle tone, bulk, sensory, and reflexes
- *Muscle disease*:
  - Proximal symmetrical muscle weakness
  - Specific muscle group involvement:
    - Normal or atrophied muscle
    - Normal sensory examination
    - Knee jerk absent with retained ankle jerk

The sites of lesions causing hemiparesis, paraparesis, and quadriparesis and corresponding clinical features are described in Table 1.

SUGGESTED READING

1. Bhuiyan PS, Rajgopal L (Eds). Inderbir Singh'S Textbook Of Human Neuroanatomy (Fundamental and Clinical), 10th edition Jaypee Brothers Medical Publishers.
2. Brazis PW, Masdeu JC, Biller J. Localization in Clinical Neurology, 7th edition. Lippincott Williams & Wilkins (LWW); 2016.
3. Goldberg SB. Clinical Neuroanatomy made ridiculously simple, 5th edition. Medmaster; 2014.

JAYPEE BROTHERS

for detailed information on pediatrics books, visit our website **www.jaypeebrothers.com,** for detailed information on pe

IAP Textbook of
PEDIATRIC NEUROLOGY

Salient Features

- A comprehensive collection of important pediatric neurological diseases, which are quite often seen in clinics
- Covers some precious topics such as developmental delay, autism, cerebral palsy, congenital anomalies, infections of central nervous system, childhood epilepsy, movement disorders, neuroimaging, electrophysiological examinations, neurodegeneration, diseases of muscle, diseases of neuromuscular junctions, headache in children, nutritional diseases affecting the nervous system, pediatric drug formulary pertaining to neurological disorders which appeals most to general pediatricians
- This edition has expanded and emerged to cover 13 new topics to have wider coverage of the subject. The addition of clinical pearl will help readers to grasp and understand the topic quickly
- Videos of common neurological disorders are given online at emedicine360.com. Enjoy learning the basics of recognition of various conditions with excellent commentary in the background, which gives an idea of examining the patient in real time
- The book is an effective tabletop reference and is very useful to undergraduates, postgraduates, general practitioners, pediatricians, pediatric neurologists, and to all those clinicians who are interested in pediatric neurology
- The scientific contents in this book are contributions from eminent pediatric neurologists and famous clinicians. The vast experience and vision of whom are adequately depicted in each page.

Anoop Verma MD FIAP FIAMS FCGP FPNC FPAI is Director, Swapnil Institute of Child Health, Raipur, Chhattisgarh, India. He was National Chairperson of Neurology Chapter from 2009 to 2012, National Convener of IAP Taskforce on Epilepsy and Movement Disorders and National Coordinator Neuroimaging Module of IAP. He was conferred the prestigious FIAP in 2003, FIAMS in 2005, FCGP in 2008, FPAI and FPNC in 2018. He authored well-known books like *Spotters in Pediatrics, Pediatrics Secrets, Clinical Pediatric Neurology*. He was the Editor in *IAP Textbook of Pediatric Radiology, Neurology,* Section Editor in *IAP Color Atlas of Pediatrics,* Chapter Contributor in *IAP Textbook of Pediatrics and* Editor-in-Chief of *IAP Textbook of Pediatric Neurology,* first edition. He has 30 publications in national and international journals and books to his credit. He was conferred "Best Doctor of the Year Award" 2015 by National IMA at Delhi. He was National Vice-President of IAP in 2005.

PAM Kunju MD DM (Neuro) WHO Fellow (USA) is Dean, Faculty of Medicine, University of Kerala, Thiruvananthapuram, Kerala, India, and Professor and Head, Department of Pediatric Neurology, Medical College, Thiruvananthapuram. He has 31 years of experience exclusively in pediatric neurology, and is one of the pioneers in establishing pediatric neurology in India. Simultaneously, he is the Kerala President of Indian Academy of Pediatrics and Association of Neurology. He completed WHO fellowship in pediatric neurology from Pennsylvania University (USA), and has bagged the Best Doctor Award from Government of Kerala in 2017. He has presented hundreds of papers in national and international conferences and published eminent research papers. He is one of the constant contributors of various "Partha's Pediatric Textbooks". He is a very student-friendly teacher and part of the postgraduate training programs in many states. His method of simplified approach to difficult neurologic problems and the neuroanatomy is widely appreciated.

Available at all medical bookstores
or buy online at www.jaypeebrothers.com

JAYPEE BROTHERS
Medical Publishers (P) Ltd.
www.jaypeebrothers.com

Join us on facebook.com/JaypeeMedicalPublishers

Shelving Recommendation
PEDIATRICS

ISBN 978-93-5270-979-3