atrics books, visit our website **www.jaypeebrothers.com,** for detailed information on pediatrics books

Indian Academy of Pediatrics
NEONATOLOGY CHAPTER

# Atlas & Synopsis of Neonatology



*Editors-in-Chief*
**Rhishikesh Thakre**
**Srinivas Murki**

*Foreword*
**YK Amdekar**

**2nd Edition**

JAYPEE

# Contents


**1. Normal Newborn** **1**

*Abhishek PV, Rhishikesh Thakre, Srinivas Murki*

**2. Clinical Phenomenon** **19**

*Abhishkek PV, Anup Acharya, Ashish Mehta, Brajesh Jha, Col RK Thapar, Deepak Pande, Laxman Basani, Lt Col RK Singh, Naveen Bajaj, Rahul Gosavi, Ramesh Sitaram Bajaj, Ravi Shankar, Rhishikesh Thakre, Sandeep Kadam, Sandeep Reddy CHS, Sanjeev RK, Sheila Mathai, Srinivas Murki, Tonny Mampilly, Trupti Joshi, Vinod Krishnan*

**3. Skin Disorders** **55**

*Abhishek PV, Alok Kumar, Anirudh Reddy, Anjali Kale, Anup Acharya, Ashish Mehta, Asim Mallick, Atul Kulkarni, Col Ritu Agarwal, Col RK Gupta, Col RK Thapar, Deva Patel, Laxman Basani, Maj Narender Sharma, Mukut Banerjee, Naveen Bajaj, Nusrat Deshmukh, Phanish Kaushik, Rajesh Kumar, Ram Mohan G, Ramesh Sitaram Bajaj, Ranjan Pejaver, Rhishikesh Thakre, Roja Aepala, Sandeep Reddy CHS, Sanjay Wazir, Sheila Mathai, Snehal Nagre, Srinivas Murki, Sudhanshu Tiwary, Suman Rao, Surender Kumar, Tejopratap Oleti*

**4. Infections** **113**

*Abhishek PV, Anilkumar Khamkar, Anjali Kale, Atul Kulkarni, Deva Patel, Kanishka Das, Laxman Basani, Lt Col RK Singh, Mukut Banerjee, Rajeeb Chatterjee, Rajesh Kumar, Ramesh Sitaram Bajaj, Ravi Shankar, Rhishikesh Thakre, Roja Aepala, Sachin Dhule, Sandeep Kadam, Sanjeev RK, Shrabani Mandal, Snehal Thakre, Suman Rao, Trupti Joshi*

**5. Systemic Disorders** **149**

*Alok Kumar, Anilkumar Khamkar, Anjali Kale, Anup Acharya, Col Ritu Agarwal, Col RK Thapar, Rajesh Kumar, Ram Mohan G, Rhishikesh Thakre, Sachin Dhule, Sandeep Reddy CHS, Sanjay Aher, Snehal Thakre, Suman Rao, Trupti Joshi*

**6. Associations, Malformations and Genetic Disorders** **239**

*Abhishek PV, Amit Jagtap, Amol Joshi, Anil Kumar Poonia, Anilkumar Khamkar, Anjali Kale, Arjit Mohapatra, Ashish Mehta, Asim Mallick, Atul Kulkarni, Col RK Thapar, Geeta Bhat, Jeat Abraham, K Sankaranaryanan, Kanishka Das, Kavish Mehta, Lt Col RK Singh, Madhavi V, Maj Narender Sharma, Mukut Banerjee, Naveen Bajaj, Phanish Kaushik, Rajath Pejaver, Raktima Chakraborty, Ram Mohan G, Ramesh Sitaram Bajaj, Ranjan Pejaver, Rhishikesh Thakre, Sandeep Kadam, Sanjay Aher, Sanjeev RK, Shrabani Mandal, Snehal Nagre, Srinivas Murki, Suman Rao, Tonny Mampilly, Vinod Krishnan, Yogesh Shewale*

**7. Iatrogenic Disorders** **305**
*Abhishek PV, Col RK Thapar, Lt Col RK Singh, Rajesh Kumar, Ram Mohan G, Ramesh Sitaram Bajaj, Rhishikesh Thakre, Sanjeev RK, Suman Rao*

**8. Miscellaneous** **323**
*Rhishikesh Thakre, Suman Rao*

*Index* *331*

SECTION 2

# Clinical Phenomenon

*Abhishkek PV, Anup Acharya, Ashish Mehta, Brajesh Jha, Col RK Thapar, Deepak Pande, Laxman Basani, Lt Col RK Singh, Naveen Bajaj, Rahul Gosavi, Ramesh Sitaram Bajaj, Ravi Shankar, Rhishikesh Thakre, Sandeep Kadam, Sandeep Reddy CHS, Sanjeev RK, Sheila Mathai, Srinivas Murki, Tonny Mampilly, Trupti Joshi, Vinod Krishnan*

JAYPEE BROTHERS

## SECTION OUTLINE


2.1 Absent Depressor Angularis Oris
2.2 Chest Indrawing
2.3 Capillary Refill Time
2.4 Complete Heart Block
2.5 Conduction Block–2:1
2.6 Cortical Thumb
2.7 Cutis Marmorata
2.8 Cyanosis
2.9 Fresh Stillbirth
2.10 Giant Umbilical Cord
2.11 Hypotonia
2.12 Infant of Diabetic Mother
2.13 Intrauterine Growth Restriction
2.14 Jaundice
2.15 Large-for-Gestational-Age
2.16 Macroglossia
2.17 Macrocephaly
2.18 Microcephaly
2.19 Natal Tooth
2.20 Patent Vitellointestinal Duct
2.21 Pedal Edema
2.22 Preauricular Tag
2.23 Postmaturity Syndrome
2.24 Posture
2.25 Sternal Indrawing
2.26 Squint
2.27 True Umbilical Knot
2.28 Tuft of Hair
2.29 Umbilical Cord Cyst
2.30 Umbilical Granuloma
2.31 Visible Peristalsis Wave


JAYPEE BROTHERS

# 2.1 ABSENT DEPRESSOR ANGULARIS ORIS

## Description

- There is facial asymmetry, especially on crying and facial symmetry at rest. Angle of mouth is deviated to one side on crying (to right side in Fig. 2.1).
- There is forehead wrinkling, nasolabial fold depth and eye closure remain intact and equal on both side.
- Sucking is normal and there is no drooling. No other focal deficit. No history of birth trauma.



**Fig. 2.1:** Absent depressor angularis oris.

## Etiopathogenesis

The etiology is probably multifactorial. There is congenital deficiency or absence of the depressor anguli oris muscle.

## Clinical Features

Depressor anguli oris muscle draws the corner of mouth downward and everts the lower lip. While it can be an isolated phenomenon, coexisting major anomalies are seen in 10% with cardiovascular system and head and neck anomalies being the most common. Skeletal, genitourinary, gastrointestinal, central nervous system anomalies occur less frequently.

## Investigations

To rule out associated anomalies, e.g. brainstem evoked response audiometry (BERA) for hearing, two-dimensional (2D) echo for cardiac defect, etc. should be performed.

## Differential Diagnosis

Facial palsy is characterized by asymmetrical forehead wrinkling, inability to close eye and loss of nasolabial fold depth on the affected side.

## Treatment

No definitive treatment; parental assurance; treat comorbid conditions, if any.

## Prognosis

This is a benign condition and mainly a cosmetic problem. It does not interfere with feeding or speech and improvement is seen within a month. It eventually disappears in the great majority of cases (as the muscle does not contribute significantly to facial expression in childhood/adulthood). Follow-up is required if coexisting anomalies exist.

JAYPEE BROTHERS

## 2.2 CHEST INDRAWING

### Description

There is recession of the subcostal space and intercostal space. The sensorium is altered—drowsy or bouts of irritability (Fig. 2.2).



**Fig. 2.2:** Chest indrawing.

### Etiopathogenesis

Chest indrawing is a sign of breathing difficulty and a marker of hypoxia. It is due to increased use of the chest muscles for breathing. In a normal breath, when an infant breaths in, the whole chest wall (upper and lower) and the abdomen move out. With chest indrawing, the lower chest wall goes in while the upper chest and abdomen move out.

### Clinical Features

It is a sign of increased work of breathing and is associated with hypoxia. It manifests as subcostal or intercostal in drawing. There may be audible sounds like grunt or stridor. It suggests moderate to severe lung disease and is a "danger sign". It is best detected in a quiet infant.

### Differential Diagnosis

Lung disease and cardiac disease (history suggestive of heart disease, viz. cyanosis, murmur, congestive cardiac failure, cardiomegaly or abnormal heart sound).

### Investigations

X-ray chest; further tests based on clinical suspicion.

### Treatment

Supportive care, oxygen, antibiotics and specific treatment of the underlying cause.

### Prognosis

While prognosis depends on the diagnosis, it is generally good with prompt recognition and intervention.

## 2.3 CAPILLARY REFILL TIME

### Description

The limb is elevated above the heart level. After applying digital pressure over the foot, there is blanching lasting more than 3 seconds suggesting delayed capillary refill time (CRT) (Fig. 2.3).

JAYPEE BROTHERS



**Fig. 2.3:** Delayed capillary refill time.

### Etiopathogenesis

Capillary refill time is an indirect marker of circulatory stability. Normally, the capillaries refill instantly (<2 seconds) with adequacy of perfusion.

### Clinical Features

Hypothermia, infection, shock lead to delayed CRT. One-time assessment and relying only on CRT for adequacy of perfusion is usually not conclusive. More the parameters deranged in addition to CRT (e.g. heart rate, pulse volume, central peripheral pulse volume, respiratory rate, skin temperature, core peripheral temperature mismatch, sensorium, blood pressure, urine output, pulse oximetry) more is the possibility of shock.

### Differential Diagnosis

Hypothermia, shock.

### Investigations

Tests are done depending on the cause suspected (e.g. sepsis screen, evaluation for congenital heart defect, etc.).

### Treatment

Treatment is of the underlying cause. Correction of temperature (hypothermia), and early antibiotics, fluid resuscitation and inotropes for shock are indicated.

### Prognosis

Prognosis is dependent on the underlying cause. Early recognition and prompt treatment has good outcome.

## 2.4 COMPLETE HEART BLOCK

### Description

Note the variable atrial and ventricular rate (Fig. 2.4).

### Etiopathogenesis

Complete atrioventricular (AV) block can be congenital or acquired. Congenital causes are fibrosis of the AV nodal structures by maternal anti-SSA/Ro, anti-SSB/La in a mother with overt or, more often, asymptomatic SLE or Sjögren syndrome, L-TGA, complex congenital heart defect (CHD), long QT syndrome, myocardial tumors and myocarditis. The most common causes of acquired complete heart block are infections, neonatal myocarditis or complication of neonatal cardiac surgery. No impulses from the atria reach the ventricles. An

JAYPEE BROTHERS




**Fig. 2.4:** Variable atrial and ventricular rate.

independent escape rhythm is usually present but may or may not be adequate.

### Clinical Features

Arrhythmia is often diagnosed in the fetus by fetal echocardiography and can manifest with fetal hydrops and fetal demise due to congestive cardiac failure. In neonates, it can present as irritability and cardiac failure (respiratory distress, poor perfusion, low urine output and edema). Most of the fetuses and neonates are asymptomatic as the junctional escape rate often can be 60–80 bpm and can provide adequate cardiac output. Complete heart block may go undetected in the newborn period and remains asymptomatic for many years.

### Investigations

Electrocardiogram (ECG) confirms the diagnosis; the P waves and QRS complexes have no constant relationship. The QRS complex may be wide if there is extensive damage to the junctional region and escape rhythm arise. Echocardiography should be done to look for associated heart defects. Ro, La antibodies should be tested in asymptomatic mothers.

### Differential Diagnosis

Long QT syndrome, metabolic causes like hyperkalemia, hypokalemia.

### Treatment

Permanent pacemaker implantation is indicated if there is ventricular dysfunction or low cardiac output in the neonate with a heart rate less than 55 bpm (or <70 bpm in the setting of concurrent CHD) or with wide QRS complex escape rhythm. Isoproterenol, atropine, or epinephrine increase the heart rate temporarily until pacemaker placement.

### Prognosis

The prognosis for congenital complete heart block is good in majority. Rarely, it can cause sudden severe symptoms.

## 2.5 CONDUCTION BLOCK–2:1

### Description

The 2:1 atrioventricular (AV) block is a second-degree heart block characterized by dropped beats, i.e. P-waves randomly are followed by QRS complex. A QRS complex follows every second P-wave, resulting in 2:1 AV block. In contrast in a third-degree complete AV block, some P-waves continue to be conducted to the ventricle and the PR interval of conducted beats is constant (Fig. 2.5).

JAYPEE BROTHERS




**Fig. 2.5:** Conduction block.

## Etiopathogenesis

Myocarditis, cardiomyopathy, ischemia, congenital heart defect, cardiac surgery and digitalis toxicity. It can occur in an otherwise healthy neonate.

## Clinical Features

The infant is usually asymptomatic, often identified as a skipped beat on physical examination or routine monitoring. It may progress to complete heart block. Higher grade second-degree AV block (3:1, 4:1) should always be regarded as abnormal. A high-grade AV block has clinical significance similar to that of complete AV block.

## Investigations

Electrocardiogram (ECG) shows the typical pattern. Electrophysiologic studies may be necessary to determine the level of the block. ECHO should be done to look for congenital heart defect, myocardial activity. In suspected myocarditis CPK-MB should be done.

## Treatment

The treatment is directed to the underlying causes. Atropine, isoproterenol and temporary pacing may be required for symptomatic blocks. Pacemaker therapy is reserved for non-drug responsive significant second-degree AV block

## Prognosis

Prognosis depends on the underlying cause of the disease and progression to higher degree AV block.

# 2.6 CORTICAL THUMB

## Description

Note the thumb in fist position in well newborn (Figs. 2.6A and B). There were no other abnormalities on examination.

## Etiopathogenesis

It is a soft neurologic sign noted in infancy suggestive of cortical insult. The condition is benign till first 4 months and persistence or asymmetry should warrant detail neurologic evaluation.

## Clinical Features

In majority the sign is detected on routine evaluation. The sign is benign in early infancy. The infant is asymptomatic with no other abnormality. It may be isolated finding or part of multiple defects.

JAYPEE BROTHERS

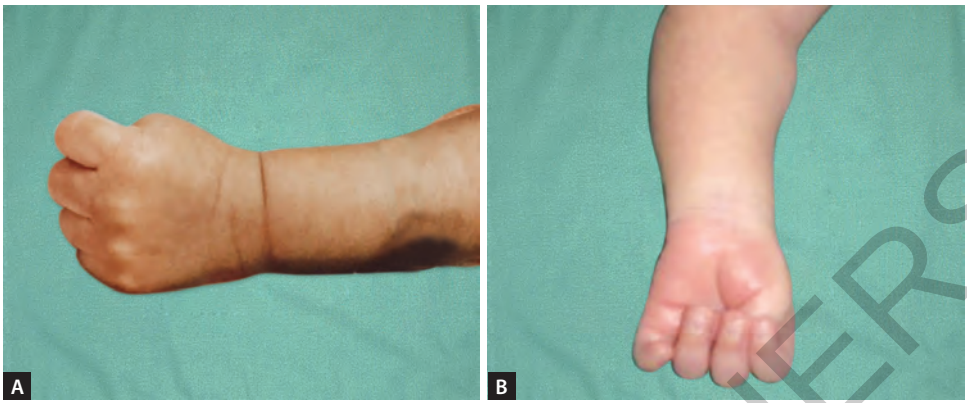


**Figs. 2.6A and B:** The thumb in fist position in well newborn.

Persistence beyond 4 months suggests an upper motor neuron lesion.

### Investigations

None for isolated finding. Needed only if persistence or asymmetry is noted.

### Differential Diagnosis

Congenital trigger thumb, distal arthrogryposis, Freeman-Sheldon syndrome (a congenital, heritable affection of the face, the hands, the feet and some joints, Waardenburg syndrome, X linked hydrocephalus, multiple pterygium syndrome, leukodystrophy).

### Treatment

None for isolated finding in newborn.

### Prognosis

Self-limiting.

## 2.7 CUTIS MARMORATA

### Description

- Symmetric, reticular mottling of the skin of the extremities and trunk was noted in the newborn on day 3 after birth (Fig. 2.7)
- Vital parameters are stable. The infant is asymptomatic
- The lesions disappeared spontaneously after few hours.

### Etiopathogenesis

It is caused by a vascular response to cold and usually resolves with warming. Sometimes, it may be a vasomotor phenomenon.

### Clinical Features

The lesions appear spontaneously over the legs, arms or the trunk. They are

JAYPEE BROTHERS

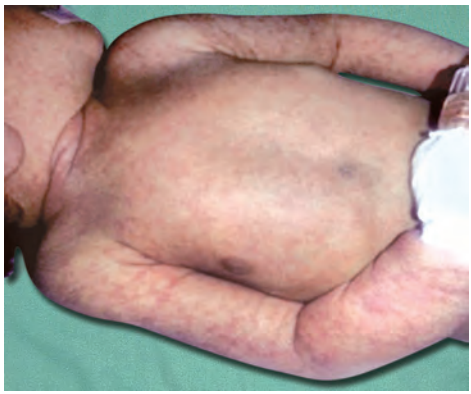

**Fig. 2.7:** Cutis marmorata.

transient and self-limiting. The infant is asymptomatic. There are no signs or symptoms. There are no associated anomalies.

### Investigations

No specific investigations are required. It is a clinical diagnosis.

### Differential Diagnosis

Physiologic cutis marmorata must be distinguished from cutis marmorata telangiectatica congenita, a vascular malformation in which the lesions do not resolve with warming. Cutis marmorata telangiectatica congenita is associated with extracutaneous findings.

### Treatment

Resolves with warming. No treatment is required.

### Prognosis

It is a benign condition.

## 2.8 CYANOSIS

### Description

There is bluish discoloration of mucous membrane and skin (Fig. 2.8). This is associated with low oxygen saturation ($SpO_2$) and hypoxia (low $PaO_2$).

### Etiopathogenesis

Cyanosis is a reflection of the absolute concentration of reduced hemoglobin. It is detected when the amount of reduced hemoglobin in the blood exceeds 5 g%. It is not influenced by oxygen saturation or the ratio of reduced hemoglobin to oxyhemoglobin. While oxygenated hemoglobin is bright red, reduced hemoglobin is dark blue or purple in color,



**Fig. 2.8:** Cyanosis.

and is what produces the dusky or blue color of the skin and mucous membranes.

JAYPEE BROTHERS

### Clinical Features

Cyanosis is a marker of severity of illness and a "red flag" sign prompting urgent evaluation and stabilization. It is best visualized over mucous membranes. Infants with polycythemia may exhibit cyanosis at relatively high arterial saturations, while it is more difficult to discern cyanosis in a severely anemic infant unless the oxygen saturation is extremely low. Peripheral cyanosis, also known as acrocyanosis, is transient bluish discoloration of hands and feet caused by peripheral vasoconstriction.

### Differential Diagnosis

Acrocyanosis, polycythemia, cyanotic heart defect, upper airway malformation (e.g. atresia, stenosis or stricture), severe congenital or acquired lung disease (e.g. pulmonary hypoplasia, respiratory distress syndrome, meconium aspiration syndrome, pneumonia, air leak syndrome, persistent pulmonary hypertension of the neonate), sepsis, hypoventilation, abnormal hemoglobin (e.g. congenital methemoglobinemia).

### Investigations

Pulse oximeter; further tests depending upon clinical suspicion.

### Treatment

Supportive care—assess, support and maintain airway, breathing and circulation, initiate oxygen and monitor the vitals—temperature, pulse rate, respiration, blood pressure and oxygen saturation. Treat the underlying cause, viz. partial exchange for polycythemia, prostaglandin infusion for critical cyanotic heart defect and definitive surgery, intercostals drain for air leak, etc.

### Prognosis

While prognosis depends on the diagnosis, it is generally good with prompt recognition and intervention.

## 2.9 FRESH STILLBIRTH

### Description

- There are no signs of life-spontaneous breathing or circulation or movements
- Fresh stillborn baby does not show signs of maceration, i.e. peeling of skin or collapse of skull bones (Fig. 2.9).

### Etiopathogenesis

Definition varies from country to country. Definition recommended by the World Health Organization for international comparison is a baby born with no signs of life at or after 28 weeks of gestation. At least half of all stillbirths occur in the intrapartum period, representing the greatest time of risk. A fresh stillbirth has usually died during labor. Causes of fresh stillbirths include anoxia, birth trauma, instrumentation during delivery and rupture of the uterus. Anoxia may be acute or acute on chronic. Acute anoxia is due to prolonged labor, cord prolapse and cord compression. Chronic hypoxia states include pregnancy-induced hypertension, diabetes, systemic lupus erythematosus

JAYPEE BROTHERS



**Fig. 2.9:** Fresh stillbirth.

and other maternal systemic disease and infection. Premature and intrauterine growth restriction (IUGR) babies are more prone to asphyxia and trauma-related deaths. Stillbirth rate is defined as the number of stillbirths per thousand of total births.

### Investigations

A complete workup for maternal conditions leading to chronic fetal hypoxia states and strict intrapartum fetal monitoring by nonstress test and cardiotocography are necessary. Histopathological examination of the placenta and autopsy of the baby can help at times.

### Clinical Features

The condition is not compatible with life. There are no signs of life—absent respiration, heart rate and movements to stimuli.

### Differential Diagnosis

Sometimes live births with poor Apgar scores and severe fetal and prolonged acidosis may be confused with fresh stillbirths.

### Treatment

A prompt delivery by cesarean section or assisted vaginal delivery, if the cervix is fully dilated, will save the baby. Once the fetal death is expected, vaginal delivery is preferred.

### Prognosis

Prognosis depends on the etiology of the stillbirth. A sound antenatal workup and good intrapartum fetal monitoring may decrease the incidence of fresh stillbirths in future pregnancies.

## 2.10 GIANT UMBILICAL CORD

### Description

- Note the large size of the umbilical cord at birth—diameter of 5 cm and length of 20 cm (Fig. 2.10).
- The umbilical vessels within the cord are normal. There is no palpable fascial defect. No contents were noted within the cord.
- The infant is asymptomatic.

JAYPEE BROTHERS



**Fig. 2.10:** Note the large size of the umbilical cord at birth.

## Etiopathogenesis

The exact etiology is unknown. Diffuse enlargement of the umbilical cord more than 5 cm in diameter is labeled as giant umbilical cord. Prenatally and during labor the fetus is at risk for cord compression leading to fetal hypoxia.

## Clinical Features

It may be an isolated phenomenon or there may be associated communication with the bladder as patent urachus. There are no associated malformations.

## Investigations

Prenatal ultrasonography (USG) may detect the lesion. Postnatally a thorough investigation of the umbilical stump, including histology, abdominal USG and if required, cystourography is recommended.

## Differential Diagnosis

Pseudocysts (degeneration of Wharton's jelly), omphalomesenteric duct cysts (absence of complete obliteration of the omphalomesenteric duct) and umbilical hernia.

## Treatment

Close fetal monitoring is required if prenatally detected. The mode of delivery is based on the severity of the defect and fetal well being. Operative exploration must be carried to repair the associated urachal remnant, if present. Isolated lesions do not require any intervention.

## Prognosis

Self-limiting condition.

# 2.11 HYPOTONIA

## Description

When pulled to sit, note the complete head lag (Fig. 2.11).

## Etiopathogenesis

Hypotonia is poor muscle tone. It may be secondary to cerebral anoxia, intracranial pathology (hemorrhage or infection or malformations), primary muscle disorder (myopathy, congenital myotonic dystrophy), hereditary neuropathy, neuromuscular disorders (myasthenia gravis, infant botulism), spinal disorder (trauma, spinomuscular atrophy), metabolic disorder (Tay-Sachs disease,

JAYPEE BROTHERS



**Fig. 2.11:** Note the complete head lag, showing poor muscle tone.

carnitine deficiency), maternal exposure to drugs (magnesium sulfate) or part of genetic syndrome (Down's syndrome, Prader willi syndrome).

### Clinical Features

The infant appears limp like a ragged doll or has a complete head lag or lies in frog legged posture. There is paucity of spontaneous movements. There may be associated weak cry, shallow respiration, dysmorphism, absent deep tendon reflexes, fasciculations with feeding difficulty and poor weight gain. These infants are at risk for recurrent chest infections. There may be history of decreased fetal movements or need for resuscitation at birth. Examination of the mother may give a clue towards some etiology. Subtle markers include hepatosplenomegaly, abnormal odor, congenital cataract, renal anomalies, hypopigmentation and dysmorphism. If the infant is hypotonic but has a degree of strength (presence of antigravity movements), a central cause is most likely. If the infant is hypotonic and weak a peripheral cause is most likely.

### Investigations

Clinical suspicion should direct the tests: CT or MRI brain (if suspected brain pathology), EMG study or muscle biopsy (for myopathy), NCV study (for neuropathy), genetic testing (for syndromes) or metabolic workup.

### Differential Diagnosis

Arthrogryposis.

### Treatment

There is no specific therapy. Treatment is directed towards underlying cause and comorbid conditions. Strengthening the muscles and tone and rehabilitation is achieved by physiotherapy and occupational therapy.

### Prognosis

Depends on the underlying aetiology of hypotonia and comorbid conditions.

## 2.12 INFANT OF DIABETIC MOTHER

### Description

- Macrosomia (weight >90th percentile for gestational age).
- Large, plethoric baby with increased body fat in the abdominal and scapular regions (Figs. 2.12A to C).

JAYPEE BROTHERS

detailed information on pediatrics books, visit our website **www.jaypeebrothers.com,** for detailed info

# Atlas & Synopsis of Neonatology

The 2nd edition of *Atlas & Synopsis of Neonatology* is thoroughly revised, updated to provide a practical must have book for newborn health care providers—pediatricians, fellows, neonatologists and neonatal nurses. With each photograph the book provides concise, precise and up-to-date information on common and uncommon neonatal conditions seen in clinical practice.

***Salient Features***

- Divided into eight sections—Normal Newborn, Clinical Phenomenon, Skin Disorders, Infections, Systemic Disorders, Associations, Malformations and Genetic Disorders, Iatrogenic Disorders and Miscellaneous
- Each topic provides brief description of the photograph and provides information on the disorder covering etiopathogenesis, clinical features, investigations, differential diagnosis, treatment and prognosis
- An essential book for teaching, self-learning clinical neonatology
- Covers over 300 neonatal topics
- More than 600 superb quality color photographs of common and uncommon neonatal conditions
- Up-to-date information.

**Rhishikesh Thakre** DM (Neo) MD DNB DCH FCPS is currently working as a Director at Neo Clinic and Hospital, Aurangabad, Maharashtra, India and former Chairperson of Neonatology Chapter of IAP. He obtained his specialty training (DM) in Neonatology at Lokmanya Tilak Municipal Medical College and Hospital (LTMMCH), Mumbai, Maharashtra. He is an astute clinician, good academician, respectable teacher and an excellent team maker. He is known for his meticulous desire for details and organizing skills. He is extensively involved in training of undergraduates, postgraduates, fellows, nurses and practicing fellow pediatricians. His passion for spreading the knowledge base in neonatology is evident in his publications, presentation of papers at several scientific forums and being a key speaker at many conferences.

**Srinivas Murki** DM (Neo) MD DNB is currently working as Senior Consultant at Fernandez Hospital, Hyderabad, Telangana, India. He is an alumni of JIPMER (Puducherry) and PGIMER (Chandigarh). He received his special training (DM and DNB) in Neonatology at PGIMER, Chandigarh. He was honored with Gold Medals both during his undergraduate and postgraduate training. He is extensively involved in teaching and training of undergraduates, postgraduates, fellows, nurses and practicing pediatricians. He is a recognized examiner and teacher for neonatology training programs in India. He authored many international and national publications, presented papers at several scientific forums and was an invited faculty for many conferences. His passion for teaching neonatology is admirable. This Atlas is a continuation of his pursuit in improving the clinical skills and knowledge base of professionals in neonatology.

**Available at all medical bookstores or buy online at www.jaypeebrothers.com**

**JAYPEE BROTHERS**
**Medical Publishers (P) Ltd.**
**www.jaypeebrothers.com**
Join us on facebook.com/JaypeeMedicalPublishers

Shelving Recommendation
**PEDIATRICS**

ISBN 978-93-5270-984-7