our website www.jaypeebrothers.com, for detailed information of dermatology books, visit our website www.jaypeebrothers.com

IADVL



Under the Aegis of IADVL Academy

IADVL Recent Advances in DERMATOLOGY

Editor-in-Chief
Shital Poojary

Associate Editor
Yasmeen Jabeen Bhat

Assistant Editor
Anupam Das

Foreword
Uday Khopkar

2nd Edition



Contents

SECTION 1: DIAGNOSTIC DERMATOLOGY

1. **Skin Imaging Techniques** 3
   Rochelle C Monteiro, Merwyn Fernandes
2. **Immunohistochemistry in Dermatology** 20
   Nandakumar Gopinathan Nair
3. **Dermoscopy** 30
   Biswanath Behera
4. **Immunofluorescence in Dermatology** 54
   Raghavendra Rao, Madhumitha V

SECTION 2: GENODERMATOSES

5. **Genetic Testing in Dermatology and Prenatal Diagnosis** 65
   Aayush Gupta
6. **Mosaicism in Dermatology** 73
   Nilendu Sarma
7. **Gene Therapy** 85
   Aayush Gupta
8. **Epidermolysis Bullosa** 92
   Gomathy Sethuraman, Vamsi K Yenamandra, Neha Taneja, Neetu Bhari
9. **Congenital Disorders of Keratinization** 104
   Anupam Das, Abheek Sil
10. **DNA Instability and Congenital Photosensitivity Disorders** 111
    Arun C Inamadar
11. **Miscellaneous Genodermatoses** 121
    Maitreyee Panda, Akash Agarwal

SECTION 3: INFECTIONS

12. **Bacterial Infections** 135
    Gopikrishnan Anjaneyan
13. **Viral Infections of the Skin** 144
    Rita Vipul Vora, Aishni Shah, Trisha Patel
14. **Fungal Infections** 156
    Shital Poojary, Manjunath Shenoy M

JAYPEE BROTHERS

15. **Leprosy and Mycobacterial Diseases** 173
P Narasimha Rao, Santoshdev P Rathod, Sujai Suneetha

16. **Sexually Transmitted Infections** 185
Yogesh S Marfatia, Rashmi Mahajan, Kajal Mehta, Apexa Jain

17. **HIV Infection** 200
Ajithkumar Kidangazhiathmana, Rakesh T Parakadavathu

SECTION 4: INFLAMMATORY DERMATOSES

18. **Urticaria** 215
Malathi Munisamy

19. **Autoinflammatory Disorders** 228
Shital Poojary, Anupam Das

20. **Vasculitis** 240
Brig Dr Manas Chatterjee, Ruchi Hemdani

SECTION 5: PAPULOSQUAMOUS DISORDERS

21. **Psoriasis** 253
Bela J Shah, Shikha R Shah

22. **Lichen Planus** 263
Arun Joshi, Sanjay Kumar Rathi, Rajesh Kumar

SECTION 6: PIGMENTARY DISORDERS

23. **Vitiligo: Pathogenesis** 281
Nilendu Sarma, Sayantani Chakraborty

24. **Vitiligo: Classification, Clinical Evaluation, and Assessment of Stability** 290
Madhulika Avinash Mhatre, Rashmi Sharma, Aseem Sharma, Sanjeev Mulekar

25. **Medical Management of Vitiligo** 297
Anuradha Bishnoi, Hitashi Mehta, Ankur Guliani

26. **Melasma** 307
Madhuri Agarwal

SECTION 7: PEDIATRIC DERMATOLOGY

27. **Atopic Dermatitis in Childhood** 317
Bhumesh Kumar Katakam

28. **Alopecia Areata in Children** 325
Rashmi Agarwal, Prarthana B Desai

JAYPEE BROTHERS

SECTION 8: VESICULOBULLOUS DISORDERS

29. Pemphigus (Intraepidermal Immunobullous Disorders) 339
Sanjeev Handa, Vishal Thakur

30. Subepidermal Immunobullous Disorders 348
Sujay Khandpur, Chirag Ashwin Desai

SECTION 9: DISORDERS OF CUTANEOUS APPENDAGES

31. Disorders of Sebaceous Glands (Including Acne) 365
Shishira R Jartarkar

32. Sweat Gland Disorders 377
Krina Bharat Patel, Khushbu Chauhan

33. Alopecias 387
Aseem Sharma, Shilpa Kanathur, Veenu Jindal, Madhulika Avinash Mhatre

34. Trichoscopy 402
Yasmeen Jabeen Bhat, Faizan Younus Shah

35. Acquired Disorders of Nail 413
Archana Singal, Priyesh Thakran

SECTION 10: SKIN NEOPLASMS

36. Nonmelanoma Skin Cancers 437
Kinjal D Rambhia, Amit S Gulati, Sweta H Rambhia

37. Melanoma: Recent Advances 452
Anita Takwale, Vishal Anand Bhalla

38. Primary Cutaneous Lymphomas 464
Shital Poojary, Shreya Singh, Snehal Pardeshi

SECTION 11: RHEUMATIC DERMATOLOGY

39. Systemic Lupus Erythematosus 481
Smitha Prabhu S, M Mukhyaprana Prabhu

40. Systemic Sclerosis 501
Angoori Gnaneshwar Rao, Kotla Saikrishna, Marepally Naresh

41. Dermatomyositis and Miscellaneous Connective Tissue Disorders 512
Iffat Hassan, Shazia Jeelani

JAYPEE BROTHERS

SECTION 12: DERMATOSURGERY, COSMETIC DERMATOLOGY, AND LASERS

42. Grafting in Vitiligo 525
Sanjeev Gupta, Aastha Sharma

43. Nail Surgery 536
Chander Grover, Shikha Bansal

44. Hair Restoration Surgery 546
Kavish Chouhan, Amit Kerure, Nitika Deshmukh

45. Lasers: New Machines and New Techniques 557
Abhishek De, Komal Agarwal, Aarti Sarda

46. Newer Chemical Peels 567
Neerja Puri

SECTION 13: DRUGS IN DERMATOLOGY

47. Cutaneous Adverse Drug Reactions 581
Lalit Kumar Gupta, Manisha Balai

48. Drugs in Pregnancy 596
Ranjan C Raval, Kalgi Baxi, Nayan Harshadbhai Patel

49. Newer and Investigational Drugs in Dermatology 624
Swetalina Pradhan, Anupam Das

50. Newer Biologics 642
Brig Dr Manas Chatterjee, Dipali Rathod

SECTION 14: NEWER PARADIGMS IN DERMATOLOGY

51. Newer Entities in Dermatology 657
Shital Poojary, Anupam Das

52. Biomechanics in Dermatology 667
Lt Col Sivasankari M, Senthil Kumaran C

53. Artificial Intelligence in Dermatology 674
Kumaresan Muthuvel, Shanmuga Sekar

54. Teledermatology and Teledermatopathology 682
Pragya Ashok Nair, Dhruv Ramanlal Patel, Jinal Jainendra Tandel

55. 3D Printing in Dermatology 698
Shital Poojary, Asim Syed Sheeraz, Nilotpal Majumder, Manjunath Shenoy M

56. Cutaneous Manifestations in COVID-19 Infection 709
Shital Poojary, Saurabh Jaiswal, Sumit Hajare, Yasmeen Jabeen Bhat

Index 727

JAYPEE BROTHERS

CHAPTER

39 Systemic Lupus Erythematosus

Smitha Prabhu S, M Mukhyaprana Prabhu

INTRODUCTION

Systemic lupus erythematosus (SLE) is the most common autoimmune disease affecting skin and internal organs. Due to clinical heterogenecity, abundance of abnormal immune cells and antibodies and atypical manifestations in the early course, the disease often poses a diagnostic and therapeutic challenge.

RECENT ADVANCES IN EPIDEMIOLOGY

Systemic lupus erythematosus is a disease with a complex interplay of genetic, hormonal, ethnic, and environmental factors.

Age, gender, and SLE: The disease commonly affects females (9:1 ratio), and peaks at mid adulthood, though 10–20% of all SLE patients develop LE in childhood.[1] SLE is more common and severe in women with early menarche, who are on oral contraceptive pills, who have had a surgical menopause, received blood transfusion and have taken hormonal therapy.[2]

Hyperestrogenemia as well as increase in progesterone and prolactin are associated with SLE. The incidence and prevalence in men were found to be higher in a comparatively older age-group.[3]

Childhood SLE (cSLE): F:M ratio is 4–5:1 in younger children, 8–9:1 in older children. Incidence is 3.3–9/100,000 in children.

In India, a study in Chennai revealed the most common age-group to be between 2nd and 3rd decades with a female to male ratio of 9:1.[4] Another study from Chennai reports incidence as 0.08%.[5]

Genetic susceptibility is well known with multiple polymorphisms in human leukocyte antigen (HLA) locus of chromosome 6, with a high concordance in monozygotic twins (24–57%). HLA DR, DQ, and B8 were found to be commonly associated. Recently, >100 genes have been isolated including *interferon regulatory factor 5* (*IRF5*), signal transducers and *activators of transcription-4* (*STAT4*) genes, *TREX1*, and *BLK* gene involved in B-cell signaling.[3] Inherited mutations in complement components C1q, C2, and C4 in immunoglobulin receptor FcγRIIIb or in DNA exonuclease TREX1 occur rarely. Genetic susceptibility accounts only for up to 18% of causes, environmental and epigenetic factors having a greater role in the pathogenesis.[6]

JAYPEE BROTHERS

RECENT ADVANCES IN PATHOGENESIS

- In SLE, both innate and cellular immunity have a role to play. The B-cell activating factor (BAFF) regulates B-cell differentiation, maturation, and antibody production, and is elevated in circulation in SLE patients along with reduced and dysfunctional regulatory B cells (Bregs).[7] There is upregulation of proinflammatory signaling pathways increasing cytokine activity.
- In recent years, neutrophils with a new structure, the neutrophil extracellular traps (NETs) have been implicated in autoimmune conditions. Here, nuclear and granular components project from activated neutrophil membrane to form fibrous NET-like membrane. SLE involves suboptimal clearance and excessive formation of NETs.[7]
- There is Th1 predominance with imbalance in Th17/Treg cells.
- T-cell receptor (TCR)—CD3 (TCR-CD3) signaling pathway, which is the normal immune response pathway to antigen stimulation is found to be diminished in SLE, CD3 being replaced by FcRγ which leads to increased influx of Ca^{++} intracellularly, thereby increasing inflammation.[8]
- The *IRF5*, a central mediator of innate immunity, has been found to be defective in SLE.[9]
- Monogenic lupus, due to genetic defects in complement systems, though rare, is seen more commonly in childhood LE at an age <5 years, in those with consanguineous parents and with resistant skin manifestations. This is associated with increased risk of recurrent infection.[10]
- The overaction of cyclic GMP-AMP synthase (cGAS)—STING pathway signaling which induces interferon 1 (IFN-1) leading to inflammation and autoimmunity has been found to be active in a subset of LE.[11,12]
- In CLE, gene polymorphisms related to IFN, antigen presentation, proinflammatory cytokines, apoptosis and adhesion molecules are seen. *TREX1* mutation is associated with familial chilblain lupus. Subacute cutaneous lupus erythematosus (SCLE) has strong association with extended haplotype of HLA DR3.[13]

  The pathogenesis of SLE is depicted in **Flowchart 1**.

CLINICAL SPECTRUM OF LUPUS ERYTHEMATOSUS AND RECENT ADVANCES IN CLINICAL FEATURES/CHANGING CLINICAL PATTERNS

Cutaneous findings abound in 75–80% of all LE patients and are the first to occur in up to 28% cases.

Variations in clinical presentation of LE:

- *Incomplete lupus*: It can be either preclinical form or incomplete LE (ILE). In preclinical LE, associated antibodies are present without clinical symptoms. In ILE, certain symptoms occur, but diagnostic criteria are not fulfilled. Oral ulcers, arthritis, malar rash, persistent proteinuria with casts in urine, anti-double-stranded (dsDNA), anticardiolipin, and decreased C4 can be considered as predictors for progression to florid SLE.[14]

JAYPEE BROTHERS

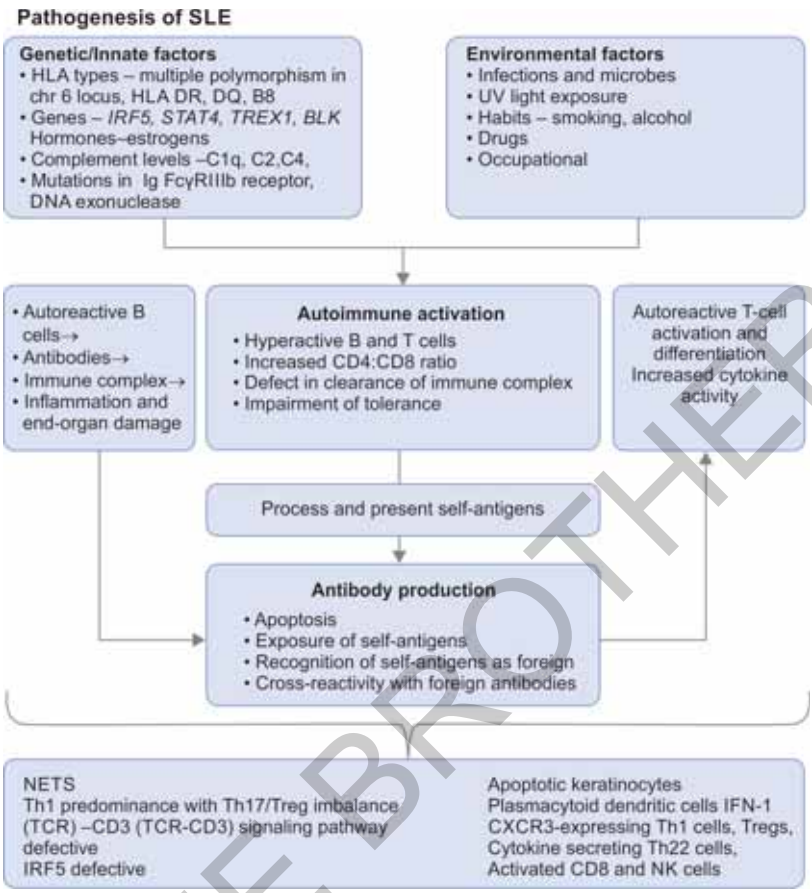

(HLA: human leukocyte antigen; IFN-1: interferon-1; NK: natural killer; SLE: systemic lupus erythematosus; Treg: regulatory T cells)

FLOWCHART 1: Pathogenesis of SLE.

- *Late-onset lupus*: It occurs beyond 50 years of age, and constitutes 12–18% of cases. Gender discrepancy is less, pulmonary, cardiovascular, sicca-like, and ocular manifestations are more common in comparison to cutaneous symptoms.[14]
- *Male lupus*: It has a 4–22% prevalence in various clinical series, especially more so in familial lupus. The disease is more severe with renal, neurological, cardiovascular and cutaneous involvement, thrombocytopenia, serositis, and anti-dsDNA.[14]
- *Childhood LE (cSLE)*: It is basically same as in adults, but is more severe due to cumulative organ damage with more of hematological, renal, and neurological manifestations, though photosensitivity and discoid lesions are less common in Indian studies.[14] Classical malar rash may be absent or may extend to involve chin and ears, or present as hypopigmented patch in dark-skinned patients. Nonspecific constitutional symptoms are common. Mean age of presentation is 9.2 years.[15]

JAYPEE BROTHERS

Cutaneous lesions in LE: Cutaneous LE has been classified by Sontheimer and Gilliam into three forms—chronic cutaneous, subacute cutaneous, and acute cutaneous LE based on morphology and similar histology, and later modified to include specific and nonspecific clinical and histological features[16,17] (**Table 1**). Lupus nonspecific lesions are more seen

Table 1 Classification of LE.

Cutaneous		Systemic
LE specific	**LE nonspecific**	**Organ systems involvement**
ACLE	*Nonspecific lesions that serve as classification criteria for SLE*	• Hematologic • Musculoskeletal • Renal • Neurologic • Pulmonary • Cardiac • Gastrointestinal • Immune
• Localized—malar rash • Generalized—morbilliform rash • TEN-like ACLE • Bullous LE	• Photosensitivity • Mucosal ulceration • Alopecia	
SCLE	*Cutaneous vascular reactions*	
• Annular • Papulosquamous/psoriasiform • Vesiculobullous annular • TEN-like SCLE	• *Vasculitis*: ○ Small vessels—palpable purpura, urticarial vasculitis ○ Medium and large vessels—purpuric plaques with/without necrosis and ulceration, subcutaneous nodules • *Vasculopathies*: ○ Raynaud phenomenon ○ Antiphospholipid antibodies—livedo reticularis, superficial thrombophlebitis, ulcers, purpura/ecchymoses, subungual splinter hemorrhages, and digital gangrene ○ Cryoglobulins—purpura/necrosis, hemorrhagic skin necrosis, and ulcers • Other vascular reactions—urticaria, periungual telangiectasia, erythromelalgia/palmar erythema	

Continued

JAYPEE BROTHERS

Continued

Cutaneous		Systemic
LE specific	**LE nonspecific**	**Organ systems involvement**
CCLE	*Other cutaneous lesions*	
• Classic DLE • Localized DLE • Generalized DLE • Hypertrophic/verrucous DLE • Lupus panniculitis/lupus profundus • Mucosal DLE ○ Oral, conjunctival, nasal, genital • Tumid LE • Chilblain LE • LE–lichen planus overlap	• Papulonodular mucinosis • Calcinosis cutis • Nail changes • Anetoderma • Interstitial granulomatous dermatitis/palisaded neutrophilic granulomatous dermatitis	

(ACLE: acute cutaneous lupus erythematosus; CCLE: chronic cutaneous lupus erythematosus; DLE: discoid lupus erythematosus; LE: lupus erythematosus; SCLE: subacute cutaneous lupus erythematosus; TEN: toxic epidermal necrolysis)

in SLE, whereas lupus specific lesions are seen more in cases where systemic involvement is mild. Clinical manifestations and prognosis differ among the various subtypes of cutaneous lupus erythematosus (LE), and many patients often have more than one type of specific/nonspecific cutaneous lesion at a given time or sequentially.[18]

Acute cutaneous lupus erythematosus (ACLE): Usually presents as malar rash (approximately 52%) typically sparing nasolabial fold. Generalized ACLE presents with symmetrical maculopapular erythematous, sometimes edematous rash, mimicking drug rash or rarely toxic epidermal necrolysis (TEN). Lesions of the hand typically spare the knuckles.

TEN-like acute cutaneous LE is a rare presentation of generalized ACLE that manifests as widespread erythema, symmetrical maculopapular or sometimes edematous rash with photo-aggravation and secondary skin detachment[19] (**Fig. 1**).

Rowell's syndrome: Here erythema multiforme-like lesions occur and denote a severe variant of ACLE, or rarely SCLE. This is further characterized by speckled antinuclear antibodies (ANA), positive anti-Ro/Sjögren's syndrome A (SSA), anti-La/Sjögren's syndrome B (SSB) and rheumatoid factor.[13,20]

Bullous SLE (BSLE): It is a rare subtype of ACLE, occurring in <5% cases either as initial clinical presentation or in the course of LE, as acute tense vesiculobullous eruptions on normal or erythematous/urticated skin (**Fig. 2**).

JAYPEE BROTHERS



FIG. 1: Toxic epidermal necrolysis (TEN)-like lesions of acute lupus erythematosus (LE).

Courtesy: Dr Surabhi KS, Assistant Surgeon, CHC, Pampakuda.



FIG. 2: Bullous systemic lupus erythematosus (SLE).

JAYPEE BY OTHERS

It is hypothesized to be autoimmune-mediated subepidermal condition, with LE-nonspecific histopathology. It is diagnosed in the presence of (i) SLE, (ii) vesiculobullous lesions, (iii) subepidermal blister and neutrophilic dermal infiltrate in histopathology, (iv) positive basement membrane zone (BMZ) immunofluorescence on direct immunofluorescence (DIF). It was found to be the initial presentation of SLE in up to one-third cases, and more predominant in darker skin types.[21] Lesions predominate on trunk and extensors, blisters on vermilion of lips are characteristic. Urticated plaques, which occur in 25% cases, are now considered as neutrophilic urticated dermatoses (NUD) and it is hypothesized that bullous systemic lupus erythematosus (BSLE) and NUD share a common pathogenesis

involving recruitment of neutrophils, and BSLE may be a neutrophilic autoimmune blistering disease associated with SLE, and not a type of LE. Erythema gyratum repens such as lesions and esophagitis dessicans superficialis may also complicate the course. BSLE is an indicator of activity of LE, and may be a pointer to renal (50%), hematological (45%), and neuropsychiatric (19%) involvement.[21]

Mild-to-moderate pruritus is seen in up to 75% of acute inflammatory CLE, and in 45% of SLE patients. The pathogenesis is linked to interleukin 18 (IL-18) in chronic cutaneous lupus erythematosus (CCLE) and TLR7 in SLE, which have a role in pruritus induction.[22]

Subacute cutaneous LE (SCLE) symmetrically involves photoexposed areas, and is of two subtypes: Annular and papulosquamous. Papulosquamous variant is more frequent, though both can coexist in the same patient. The photosensitivity spares midface but involves sides of the face, V of the neck and extensor arms and forearms.[13] Up to 50% cases show systemic symptoms like arthralgia and myalgia, though severe involvement such as nephritis, vasculitis, and central nervous system (CNS) lupus is seen only in approximately 10%.[4] SCLE can be a paraneoplastic condition linked to solid and nonsolid organ tumor. Sjögren's syndrome can coexist with SCLE, as both share the common anti-Ro antibody, and sometimes severe pulmonary or neurological symptoms occur.

Chronic cutaneous LE (CCLE) is subdivided into the following subsets: Classical discoid lupus erythematosus (DLE) (localized, generalized, and hypertrophic/verrucous), lupus panniculitis/profundus, mucosal DLE, LE tumidus, Chilblain LE, and LE-lichen planus (LP) overlap[13] (**Table 1**).

Discoid lupus erythematosus is the most common subtype and lesions occur mostly on face, scalp, ears, i.e., lesions above the clavicles, denoted as localized DLE (80%).

If lesions occur below the neck, it is generalized or disseminated DLE (DDLE). DDLE may be associated with laboratory abnormalities and can progress to SLE (15–20% cases) whereas only up to 5% cases of DLE progress to SLE, generally a mild variant with very low chance of renal involvement.[23]

Rarely lesions may present on palms (**Fig. 3**). Rarely, long-standing DLE transforms to squamous cell carcinoma (**Fig. 4**).

Mucosal DLE is seen in 25% cases and involves lip, buccal, conjunctival, and genital mucosa. Here, ulceration can occur.[13]

Other Types of Discoid Lupus Erythematosus

Hypertrophic/Verrucous DLE occurs on face and arms with thick scales and may be mistaken for other conditions such as keratoacanthoma, prurigo nodularis, or hypertrophic lichen planus and may require histopathology for confirmation.[13] It has propensity for malignant transformation after a prolonged course.

Lupus panniculitis and profundus: These present on areas with increased subcutaneous fat, especially face, breasts, buttocks, and limb girdles as

JAYPEE BROTHERS



FIG. 3: Discoid lupus erythematosus (DLE) on palms.
Courtesy: Dr Surabhi KS, Assistant Surgeon, CHC, Pampakuda.



FIG. 4: Chronic discoid lupus erythematosus (DLE) face, with squamous cell carcinoma (SCC) transformation on right cheek.

JAYPEE BROTHERS

indurated subcutaneous nodules and plaques adherent to overlying skin, usually associated with DLE (1–3%), and rarely with SLE. In panniculitis only subcutis is involved, whereas in profundus, there is overlying DLE lesions. Deep biopsy is mandated to differentiate from subcutaneous panniculitis like T-cell lymphoma.

Chilblain LE presents as symmetrical itchy or painful, erythematous to dusky blue plaques or nodules on acral areas such as digits, heel, calves, ear, nose, precipitated by cold, and may develop superficial erosions and ulcers. It is similar to frostbite, but persists beyond cold season and is associated with DLE lesions, Raynaud's phenomena, positive ANA, anti-Ro/SSA, and rheumatoid factor (RF). Up to 20% of cases are associated with SLE.[13]

for detailed information of dermatology books, visit our website www.jaypeebrothers.com, for detailed information of dermatology

IADVL Recent Advances in DERMATOLOGY

Key Features

- A ready reckoner for all the recent updates in Dermatology, Venereology, and Leprology in the last 4 years.
- Useful updates on all innovations and technological advances in dermatology in recent years.
- Concise and easily readable format with useful key practice points.



Shital Poojary is a Professor and Head, Department of Dermatology, KJ Somaiya Medical College, Mumbai. She has been the Honorary Secretary of the Indian Association of Dermatologists, Venereologists, and Leprologists (IADVL) Maharashtra Branch, coordinator of SIG pigmentary disorders, Convener of the IADVL SOP committee, and presently chairs the IADVL Maharashtra Academy. She has received the Dr LN Sinha Memorial award and several national and state awards for best paper presentations. She is on the editorial board of several journals. She has been the Assistant Editor of *IADVL Manual on Management of Dermatophytoses* and Section Editor of *IADVL Textbook of Dermatology*.



Yasmeen Jabeen Bhat is an Associate Professor, Department of Dermatology, Venereology, and Leprosy at Government Medical College, Srinagar. She is a recipient of the International Fellowship Exchange Program (IFEP) Award by the American College of Physicians, IADVL Presidential Award, Dr Senthalmil Selvi Award, and the World Congress of Dermatology (WCD) 2019 Scholarship. To her credit, she has fellowships in Skin Cancers and Lasers, 25 chapters, 115 indexed publications, and 70 invited faculty presentations. She has been the past IADVL Academy Member and Vice President of IADVL J&K. She is currently the Convener of SIG Dermoscopy and Board Member of the International Dermoscopy Society. She is the Section Editor of IJDVL, *IADVL Textbook of Trichology*, and Editorial Board Member of many national and international journals.



Anupam Das is an Assistant Professor, Department of Dermatology, Venereology, and Leprosy at KPC Medical College and Hospital, Kolkata. He has authored 40 chapters, 240 indexed publications, and presented as invited faculty in more than 25 national and international conferences including WCD 2019. He is the Co-editor of *Case-based reviews in Dermatology* and *Atopic Dermatitis: Text and Atlas* and Associate Editor of *Concise Dermatology*. He is a recipient of several international scholarships including Imrich Sarkany Non-European Memorial scholarship.

Printed in India

Available at all medical bookstores or buy online at www.jaypeebrothers.com

JAYPEE BROTHERS
Medical Publishers (P) Ltd.
EMCA House, 23/23-B, Ansari Road, Daryaganj, New Delhi - 110 002, INDIA
www.jaypeebrothers.com

Join us on facebook.com/JaypeeMedicalPublishers

Shelving Recommendation
DERMATOLOGY

ISBN 978-93-5465-018-5

9 789354 650185