othopedics books, visit our website www.jaypeebrothers.com, for detailed information on othopedics books



ORTHOPEDIC NAVIGATOR

An Orthopedic Guide for Postgraduates

Editors
Jacob Ipe
Febin Ahamed PI
Jacob Eapen

Forewords
Edward L Nazareth
George Abraham
Rajesh Purushothaman

JAYPEE

Contents

1. Upper Limb Trauma 1

- Clavicle Fracture *1*
- Scapula Fractures *2*
- Proximal Humerus Fracture *3*
- Glenohumeral Dislocation *5*
- Intercondylar Humerus Fracture *6*
- Elbow Dislocation *7*
- Coronoid Fracture *7*
- Olecranon Fracture *8*
- Radial Head Classification *9*
- Monteggia Fracture *9*
- Galeazzi Fracture *11*
- Distal Radius Fracture *11*
- Scaphoid Fracture *12*
- Perilunate Dislocations and Fracture Dislocations *13*
- Triangular Fibrocartilage Injuries *14*
- Fingertip Injuries *15*

2. Lower Limb Trauma 17

- Pelvic Fractures *17*
- Acetabulum Fracture *18*
- Hip Dislocation *20*
- Head of Femur Fracture *21*
- Neck of Femur Fracture *22*
- Intertrochanteric Fractures *23*
- Subtrochanteric Femur Fractures *24*
- Femoral Shaft Fractures *25*
- Distal Femur Fracture *25*
- Patella Fracture Classification *26*
- Proximal Tibial Fractures *27*
- Floating Knee (Ipsilateral Fractures of Femur and Tibia) *28*
- Knee Dislocation (KD) *28*
- Tibiofibular Shaft Fractures *29*
- Foot and Ankle Fractures *30*
- Tibial Pilon Fracture *33*
- Talar Neck Fractures *34*
- Talar Body Fracture *34*

JAYPEE BROTHERS

- Calcaneus Fracture *35*
- Lisfranc Fracture *35*
- Chopart Fracture *36*
- Navicular Fracture *36*
- 5th Metatarsal Fracture *37*

3. Pediatric Trauma 38

- Salter–Harris Physeal Injury *38*
- Proximal Humerus Fracture *39*
- Supracondylar Elbow Fracture *40*
- Lateral Condyle Humerus Physeal Fractures *41*
- Medial Condyle Humerus Physeal Fractures *41*
- Radial Head and Neck Fractures *42*
- Pediatric Pelvic Fracture *43*
- Fractures of the Neck of Femur *43*
- Tibial Tubercle Fractures *44*

4. Spine Trauma 45

- Spinal Cord Injury *45*
- American Spinal Injury Association (ASIA) Impairment Scale *45*
- Occipital Condyle Fracture *45*
- Atlanto-occipital Dislocation *46*
- Atlas Fracture (Jefferson's Fracture) *46*
- Atlantoaxial Rotatory Subluxation and Dislocation *47*
- Fractures of the Odontoid Process (DENS) *47*
- Traumatic Spondylolisthesis of C-2 (Hangman's Fracture) *48*
- Thoracolumbar Fractures *49*
- Sacral Fractures *50*

5. Upper Limb Regional Conditions 51

- Frozen Shoulder *51*
- Impingement Syndrome *51*
- Calcific Tendinitis *51*
- Superior Labrum Anterior and Posterior (SLAP) Tear *52*
- Dupuytren's Contracture *53*
- Trigger Finger *53*
- Brachial Plexus Injury *53*
- Rotator Cuff Tears *54*
- Elbow Instability *55*
- Scaphoid Lunate Advanced Collapse (SLAC) *56*
- Perilunate Dislocation *57*
- Kienbock's Disease *57*
- Reflex Sympathetic Dystrophy (RSD) *58*

JAYPEE BROTHERS

6. Lower Limb Regional Conditions 59

- Perthes Disease *59*
- Slipped Capital Femoral Epiphysis *63*
- Developmental Dysplasia of Hip *63*
- Avascular Necrosis *65*
- Femoroacetabular Impingement *67*
- Osteoarthritis *67*
- Chondromalacia Patella *68*
- Bipartite Patella *69*
- Accessory Navicular *69*
- Hallux Valgus *70*
- Osteochondritis Dissecans of Talus *70*
- Diabetic Foot *71*
- Charcot's Arthropathy *71*
- Tendoachilles Disorders *72*
- Tibialis Posterior Insufficiency *72*

7. Spinal Disorders..... 73

- Lumbar Canal Stenosis *73*
- Spondylolisthesis *73*
- Kyphosis *75*
- Intervertebral Disk Prolapse *75*
- Spinal Tuberculosis *76*

8. Congenital Anomalies 78

- Winging of Scapula *78*
- Sprengel's Shoulder *78*
- Torticollis *79*
- Congenital Radioulnar Synostosis *79*
- Congenital Hand Anomalies *80*
- Radial Club Hand *81*
- Thumb Anomaly Types *81*
- Hypoplasia of Thumb *82*
- Syndactyly *82*
- Apert Syndrome *82*
- Ring Constriction Syndrome *83*
- Ulnar Club Hand *83*
- Madelung Deformity *83*
- Proximal Femoral Focal Deficiency *84*
- Blount's Disease/Congenital Tibia Vara *84*
- Congenital Pseudarthrosis of Tibia *85*
- Congenital Talipes Equinovarus *87*

JAYPEE BROTHERS

- Congenital Vertical Talus *88*
- Tibia Hemimelia *88*
- Fibular Hemimelia *89*

9. Miscellaneous Conditions 90

- Open Fracture *90*
- Gait *91*
- Mangled Extremity Severity Score (MESS) *91*
- Injury Severity Score *92*
- Ganga Hospital Scoring System *92*
- Glasgow Coma Scale (GCS) *93*
- Nonunion *94*
- Femur Neck Nonunion *96*
- Osteomyelitis *96*
- Septic Arthritis Sequelae *97*
- Pin Tract Site Infection *99*
- Malignant Tumor *99*
- Hereditary Multiple Exostoses *100*
- Giant Cell Tumor *100*
- Pattern of Bone Destruction *101*
- Periprosthetic Fracture of Hip *101*
- Periprosthetic Fracture around Knee *102*
- Periprosthetic Infection *103*
- Limb Length Discrepancy *103*
- Functional Classification of Rheumatoid Arthritis *103*
- Heterotopic Ossification of Elbow *103*
- Osteogenesis Imperfecta (OI) *104*
- Hemophilia *104*

10. Diagnostic Criteria 105

- Kanavel's Sign *105*
- Kocher Criteria *105*
- Morrey and Peterson's Criteria *105*
- Peltola and Vahvanen's Criteria *105*
- Rheumatoid Arthritis *106*
- Ankylosing Spondylitis *106*
- Mirels' Criteria *107*
- Spine at Risk *107*
- Juvenile Rheumatoid Arthritis (JRA) *107*
- Diffuse Idiopathic Skeletal Hyperostosis *108*
- Neurofibromatosis *108*
- Spine Instability *108*
- Multiple Myeloma *109*

JAYPEE BROTHERS

- Fat Embolism *109*
- Hyperlaxity *110*
- Adult Respiratory Distress Syndrome *110*

11. Formulas in Orthopedics 111

- Biomechanics of Hip *111*
- Baumgartner Index (Tip-Apex Distance) *111*
- Osteotomy Wedge *111*
- Change in Length after Osteotomy *112*
- Menelaus Method (Limb Length Discrepancy) *112*
- Calculation of Nail Size (Pediatric) *112*
- Ilizarov Lengthening *112*
- Tibial Tuberosity Index *113*
- Radial Bow Calculation *113*
- Insall–Salvati Index *113*
- Tourniquet Pressure *113*
- Flexibility Index (Scoliosis) *114*
- Tuberculosis Spine (Calculation of Final Deformity) *114*

12. Radiological Lines 115

- Shoulder *115*
- Elbow *116*
- Wrist *119*
- Hip *123*
- Knee *128*
- Ankle *132*
- Foot *135*
- Spine *136*

13. DNB Practical Examination 148

Question Bank 155

- Basic Sciences and General Orthopedics *155*
- Arthrodesis *157*
- Arthroplasty *157*
- Amputation *159*
- Infections *159*
- Tumor *161*
- Congenital/Developmental Anomalies *162*
- Pediatric Orthopedics *163*
- Neuromuscular Disorders *164*

JAYPEE BROTHERS

- Fracture and Dislocation *165*
- Spine *169*
- Sports Medicine *171*
- Nerve Injuries *172*
- Microsurgery *173*
- Hand and Wrist *173*
- Foot and Ankle *174*
- Hip and Pelvis *175*
- Arthropathy and Inflammatory Disorders *175*
- Investigations and Clinical Tests *176*
- Orthotics and Prosthesis *176*
- Implants and Surgical Techniques *177*
- Physiotherapy *179*
- Metabolic Disorders *179*
- PSM *180*
- Miscellaneous *180*

Index..... *183*

JAYPEE BROTHERS

CHAPTER

6

Lower Limb Regional Conditions

PERTHES DISEASE

Salter-Thompson Classification

- *Group A:* It includes Catterall groups I and II, where the crescent sign involves less than 50% of the femoral head.
- *Group B:* It includes Catterall groups III and IV, where the crescent sign involves more than 50% of the femoral head.

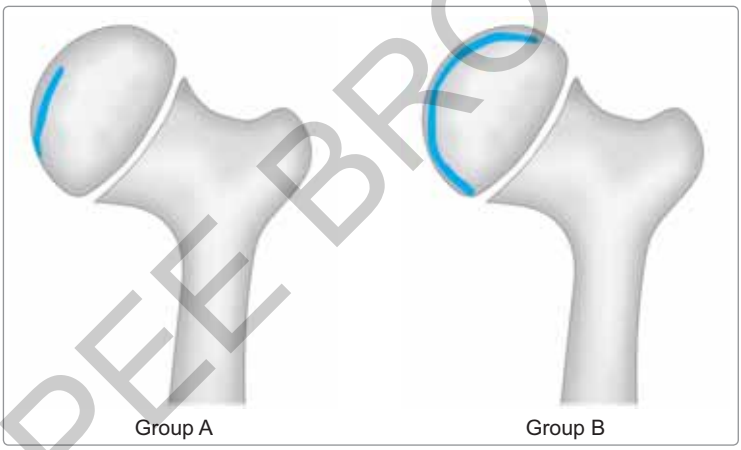

Catterall Classification

- *Stage I:* Bone resorption changes visible in the anterior aspect of the epiphysis of femoral head, changes are visible best in frog leg lateral view, no sclerosis is seen.
- *Stage II:* Further bone resorption with slight femoral head collapse in the anterior aspect of femoral head, sclerosis seen.
- *Stage III:* Almost entire femoral head involved in collapse with characteristic head within head appearance, sclerosis seen.
- *Stage IV:* Complete collapse of femoral head with flattening and formation of dense sclerosis; additional metaphyseal changes may be visible, sclerosis seen, posterior remodeling.

JAYPEE BROTHERS

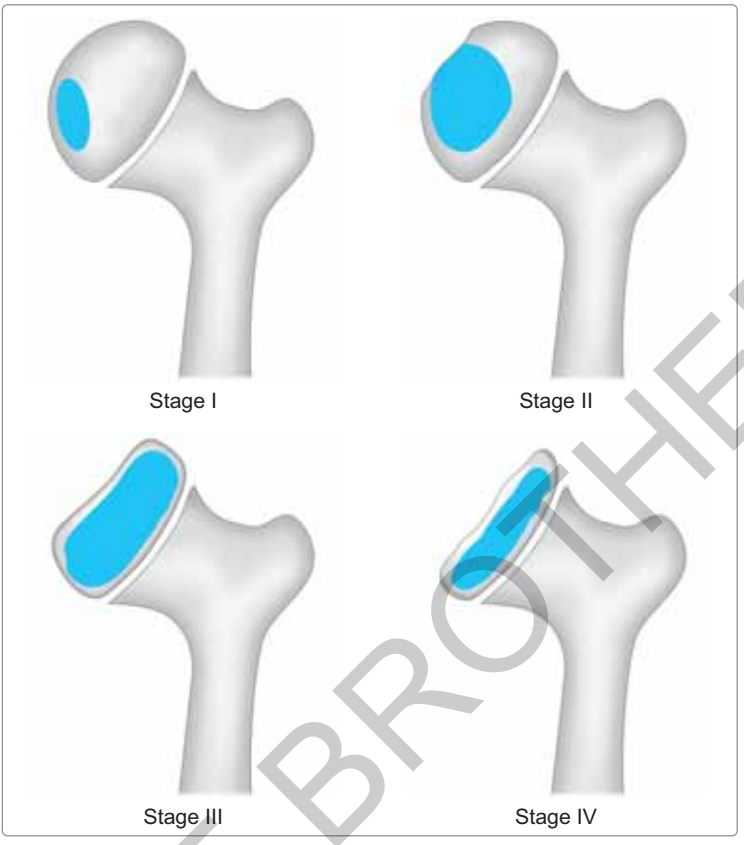

Herring Lateral Pillar Classification

- *Group A:* Lateral pillar maintains full height with no density changes identified.
- *Group B:* Maintains >50% height.
- *Group C:* Less than 50% of lateral pillar height is maintained.

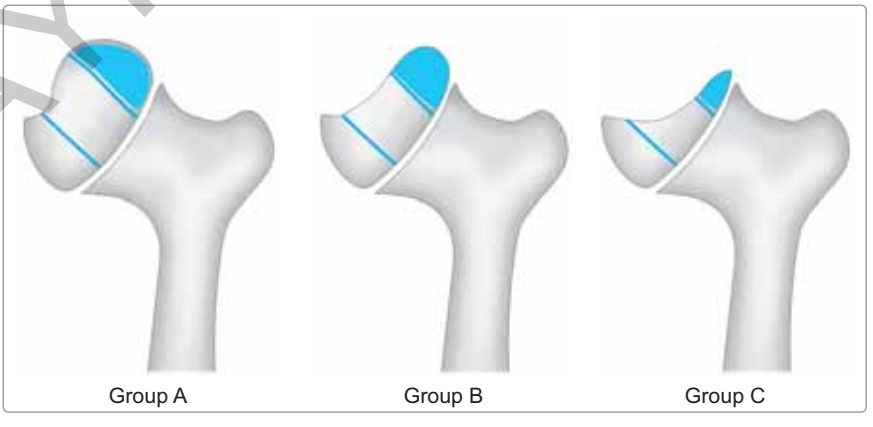

JAYPEE BROTHERS

Stulberg Classification

STULBERG CLASSIFICATION			
Class	***Description***	***Radiologic aspect***	***Prognosis***
I	Spherical congruency	Normal	Good
II	Spherical congruency Loss of head shape <2 mm	*Spherical head with one or more of the following findings:* Coxa magna, short femoral neck, upriding greater trochanter, oblique acetabulum	Good
III	Aspherical congruency Loss of head shape >2 mm	Non-spherical head but not flat	Mild-to-moderate arthritis
IV	Aspherical congruency	Flat head and acetabulum	*Poor:* Moderate arthritis
V	Aspherical incongruency	Flat head Normal neck and acetabulum	*Bad:* Severe early arthritis

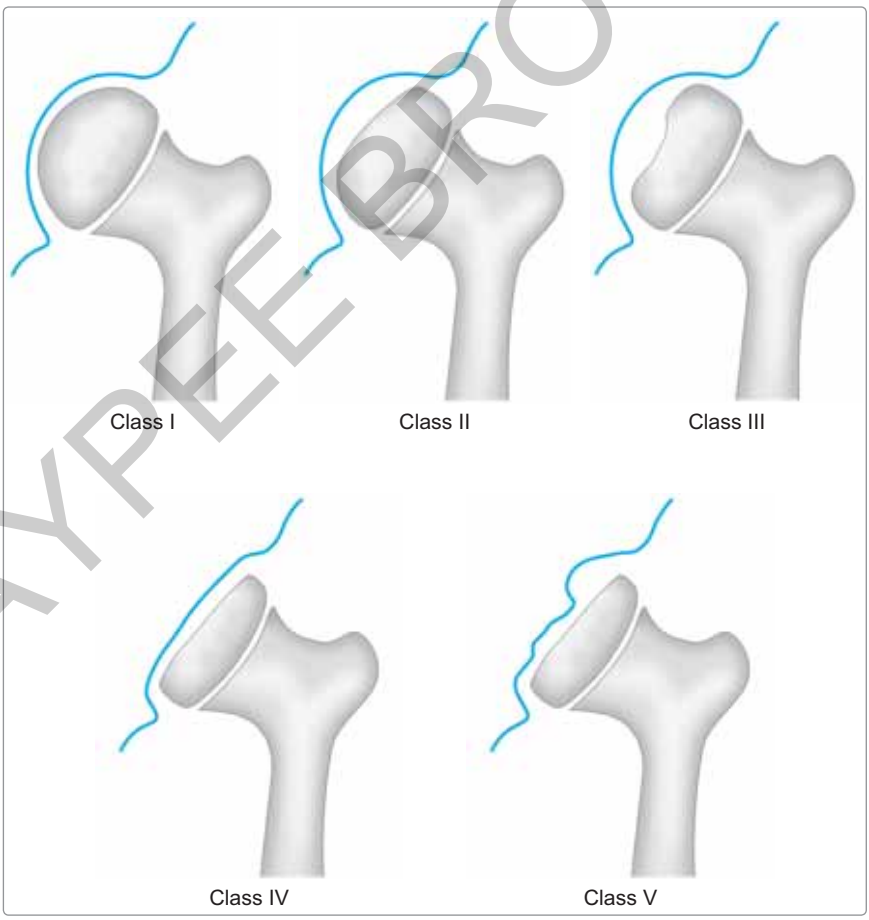

JAYPEE BROTHERS

Elizabethtown Classification

I. *Sclerotic:*
   - *Stage Ia:* Part or whole of the epiphysis is sclerotic. There is no loss of height of the epiphysis.
   - *Stage Ib:* The epiphysis is sclerotic and there is loss of epiphyseal height. There is no evidence of fragmentation of the epiphysis.

II. *Fragmentation:*
   - *Stage IIa:* The sclerotic epiphysis has just begun to fragment. One or two vertical fissures are seen in either the anteroposterior (AP) or the lateral views.
   - *Stage IIb:* Fragmentation is advanced. No new bone is visible lateral to the fragmented epiphysis.

III. *Healing:*
   - *Stage IIIa:* Early new bone formation is visible on the periphery of the necrotic epiphysis. The texture of the new bone is not normal; it is "porotic" and covers less than a third of the width of the epiphysis.
   - *Stage IIIb:* The new bone is of normal texture and has grown over a third of the width of the epiphysis.

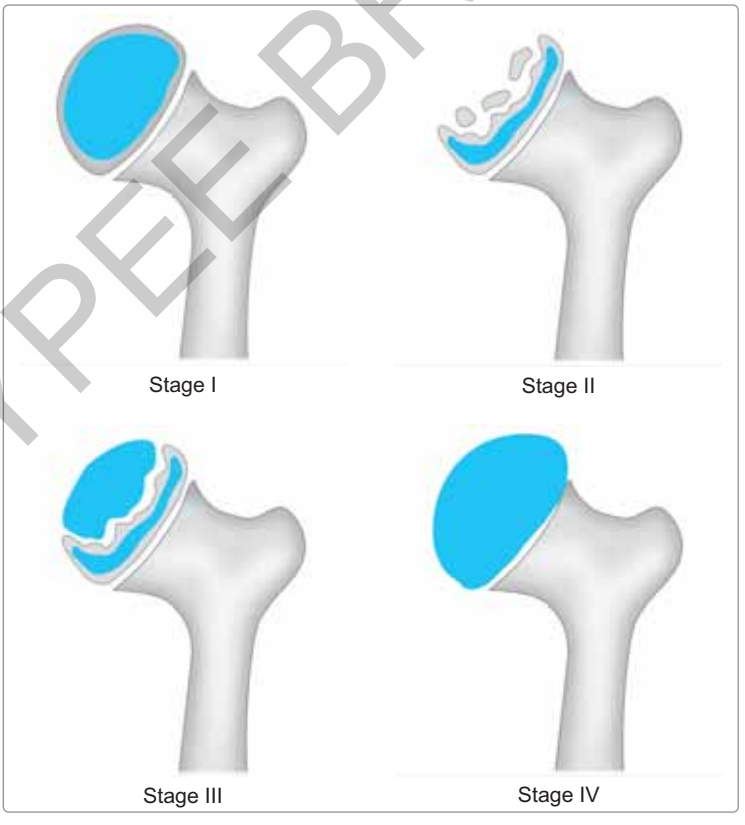

JAYPEE BROTHERS

IV. *Healed:*
- *Stage IV:* Healing is complete and there is no radiologically identifiable avascular bone.

SLIPPED CAPITAL FEMORAL EPIPHYSIS

Grading of slipped capital femoral epiphysis (SCFE) can be made on both AP and true lateral projections.

On an AP radiograph: A line along the superior margin of the femoral neck (line of Klein) should intersect the lateral corner of the epiphysis. It is also known as **Trethowan's sign**.
- *Mild:* Lateral edge of epiphysis is within the lateral third of the metaphysis.
- *Moderate:* Middle third
- *Severe:* Medial third

On a true lateral radiograph: The angle (slip angle) which the epiphysis makes with the metaphysis is measured.
- *Normal:* 0°
- *Mild:* 0–30°
- *Moderate:* 30–60°
- *Severe:* >60°

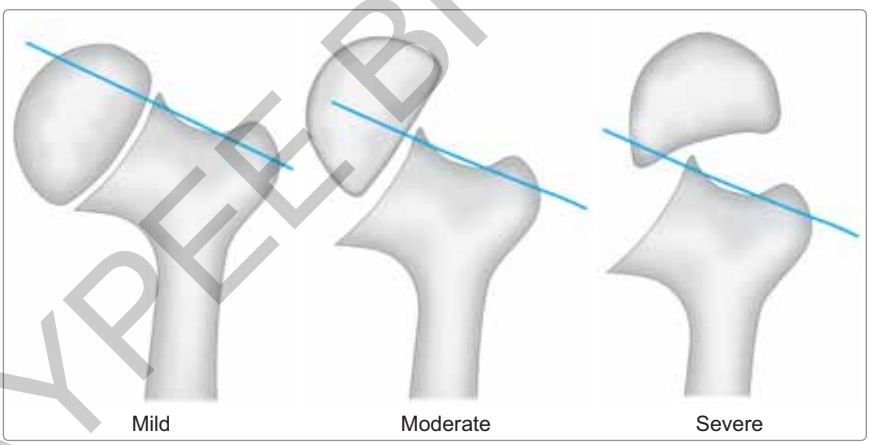

DEVELOPMENTAL DYSPLASIA OF HIP

Crowe Classification

Type of classification for severity of adult developmental dysplasia of hip (DDH):
- *Grade 1:* Hips have less than 50% subluxation.
- *Grade 2:* Hips have between 50% and 75% subluxation.
- *Grade 3:* Hips have between 75% and 100% subluxation.
- *Grade 4:* Hips have more than 100% subluxation.

JAYPEE BROTHERS

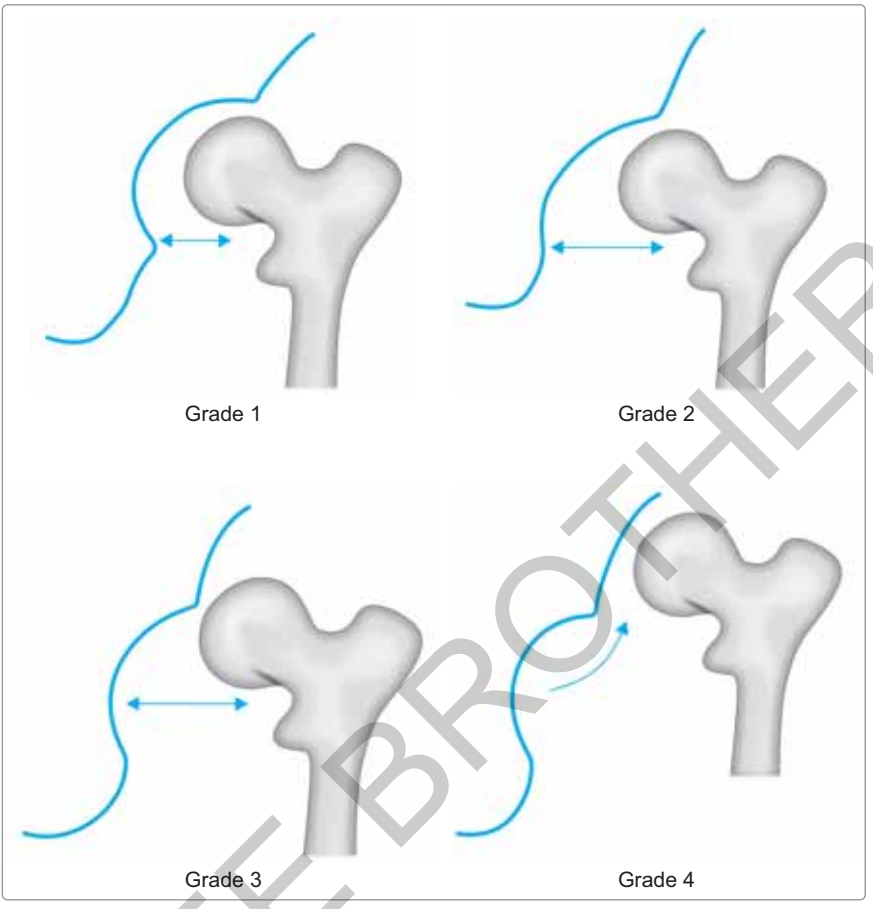

The Graf method for ultrasound classification system: It is for DDH in infants, combines both alpha and beta angles.

The infant remains in a lateral decubitus position and coronal images are taken with ultrasound probe and the two angles are measured.

The alpha angle refers to the angle between the acetabular roof and vertical cortex of the ilium. The beta angle is the angle formed between the vertical cortex of the ilium and the triangular labral fibrocartilage (echogenic triangle). In general, bigger the beta angle, greater the dysplasia. Therefore, **B**ig **B**eta **B**ad.

- *Type I:* Alpha angle > 60° (normal)
- *Type II:*
  - *Type IIa:* Alpha angle 50–59° (<3 months)
  - *Type IIb:* Alpha angle 50–59° (>3 months)
  - *Type IIc:*
    - Alpha angle 43–49°
    - Beta angle 70–77°

JAYPEE BROTHERS

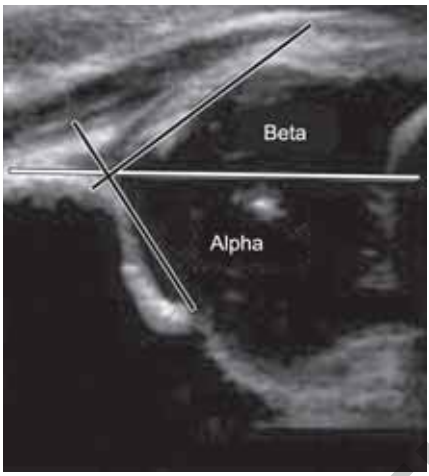

Ultrasound of the affected hip in sagittal plane showing alpha and beta angles.

- *Type IId:*
  - Alpha angle 43–49°
  - Beta angle > 77°

- *Type III:*
  - Alpha angle < 43°
  - Type IIIa and IIIb distinguished on the grounds of structural alteration of the cartilaginous roof
- *Type IV:*
  - Alpha angle < 43°
  - Dislocated with labrum interposed between the femoral head and acetabulum
  - Inverted labrum

AVASCULAR NECROSIS

The Ficat and Arlet Classification

- *Stage 0:* No clinical features with no findings in X-ray and MRI scan.
- *Stage I:* Pain typically in the groin region with plain radiograph showing normal or minor osteopenia, MRI shows bone edema and increased uptake in bone scan.
- *Stage IIa:* Pain and stiffness present.
  - X-ray shows subchondral cysts, without any subchondral lucency.
  - *MRI:* Geographic defect
  - *Bone scan:* Increased uptake
- *Stage IIb:* Pain and stiffness. Pain may be radiating to knee associated with limp.
  - *X-ray* crescent sign (subchondral lucency) and eventual cortical collapse
  - *MRI:* Same as plain radiograph

JAYPEE BROTHERS

- *Stage III:* Broken contour of femoral head, bone sequestrum, joint space normal
- *Stage IV:* Pain associated with limp
  - X-ray and MRI scan shows end-stage with evidence of secondary degenerative changes in femur and acetabulum with joint space narrowing.

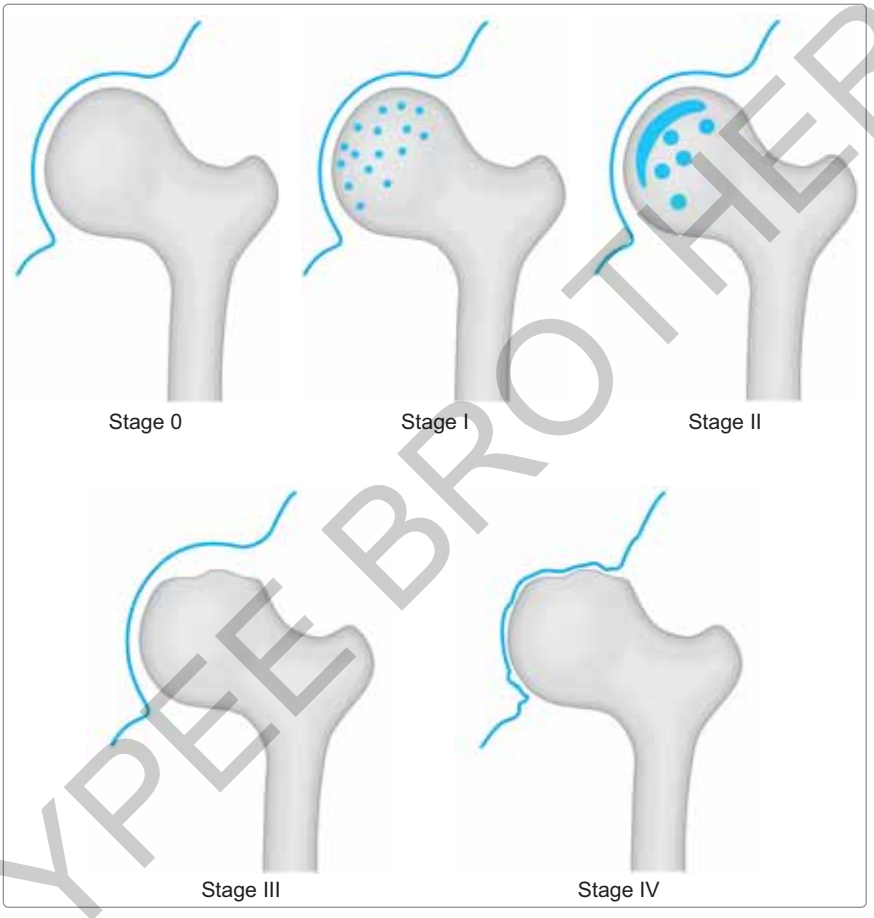

Steinberg Classification

- *Stage 0:* Normal or nondiagnostic radiographs, MRI and bone scan of at risk hip (often contralateral hip involved, or patient has risk factors and hip pain)
- *Stage I:* Normal radiograph, abnormal bone scan and/or MRI
- *Stage II:* Cystic and sclerotic radiographic changes
- *Stage III:* Subchondral lucency or crescent sign
- *Stage IV:* Flattening of femoral head, with depression graded into mild: <2 mm, moderate: 2–4 mm; severe: >4 mm

JAYPEE BROTHERS

- *Stage V:* Joint space narrowing with or without acetabular involvement
- *Stage VI:* Advanced degenerative changes

Association Research Circulation Osseous (ARCO) Classification

Stage	*Radiological findings*
0	*Positive:* Histology; negative/normal: Radiograph/CT/MRI/scintigraphy
I	*Positive:* MRI and/or bone scintigraphy; negative/normal: radiograph/CT
II	*Radiograph:* Sclerotic, cystic or osteoporotic changes of femoral head
III	*Radiograph:* Subchondral fracture ("crescent sign")
IV	*Radiograph:* Flattening of femoral head++
V	*Radiograph:* Flattening of femoral head and osteoarthritic changes decreased joint space and acetabular changes++
VI	Complete joint destruction

FEMOROACETABULAR IMPINGEMENT

Ganz Subtypes

- *Cam impingement:* Due to abnormal shape of the femur head which is nonspherical.
- *Pincer impingement:* In this type, acetabular rim covers over the femur head. Shape of head normal.

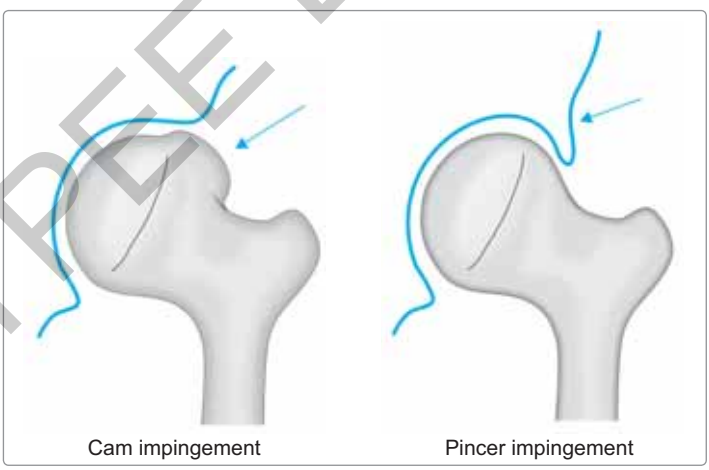

OSTEOARTHRITIS

The Kellgren and Lawrence Classification

- *Grade 0:* No radiographic features of OA are present
- *Grade 1:* Doubtful joint space narrowing and possible osteophytic lipping

JAYPEE BROTHERS

- *Grade 2:* Definite osteophytes and possible joint space narrowing on AP weight-bearing radiograph
- *Grade 3:* Multiple osteophytes, definite joint space narrowing, sclerosis, possible bony deformity
- *Grade 4:* Large osteophytes, marked joint space narrowing, severe sclerosis and definite bony deformity

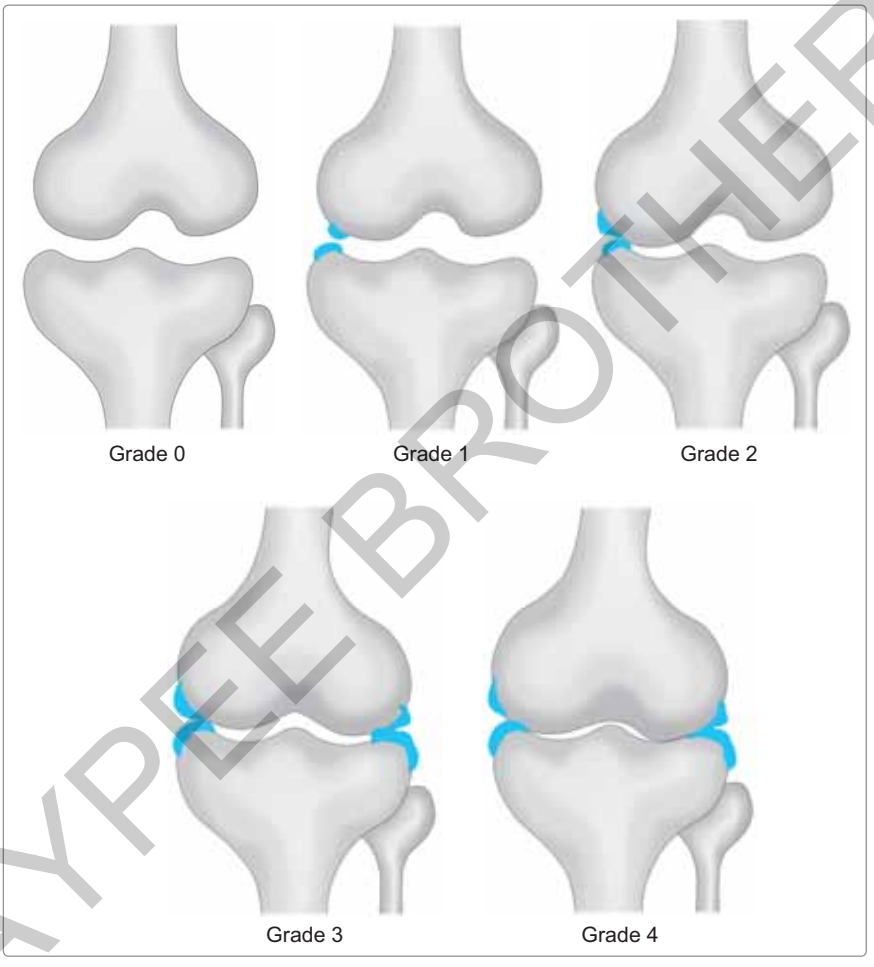

CHONDROMALACIA PATELLA

Outerbridge Classification

- *Grade 1:* Articular surfaces are soft
- *Grade 2:* Articular fissures and clefts with diameter < 1 cm
- *Grade 3:* Deep fissures with diameter extending > 1 cm
- *Grade 4:* Exposed subchondral bone

JAYPEE BROTHERS

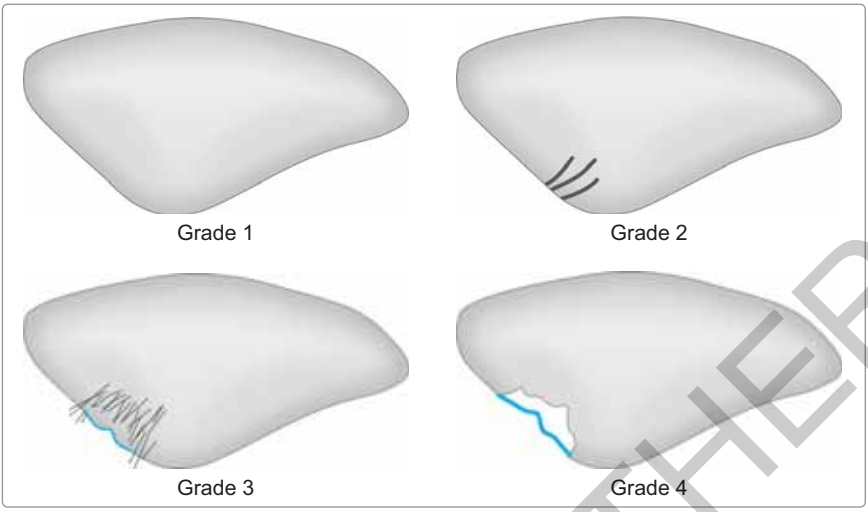

BIPARTITE PATELLA

Saupe Classification

- *Type 1:* Accessory center at the inferior pole
- *Type 2:* Occurs at the lateral border associated with nonunion of patella fracture
- *Type 3:* Occurs at the superolateral margin

ACCESSORY NAVICULAR

Kidner Classification

- *Type 1:* Round sesamoid within the tibialis posterior tendon
- *Type 2:* Synchondrosis within the body of navicular. Most common type (50%).
- *Type 3:* Fusion of accessory bone to the body of navicular.

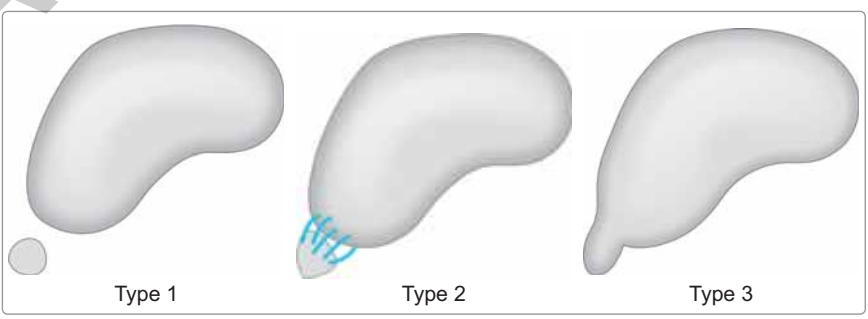

JAYPEE BROTHERS

HALLUX VALGUS

Mann's Classification

- *Mild:* <25°
- *Moderate:* >25°, <40°
- *Severe:* >40°

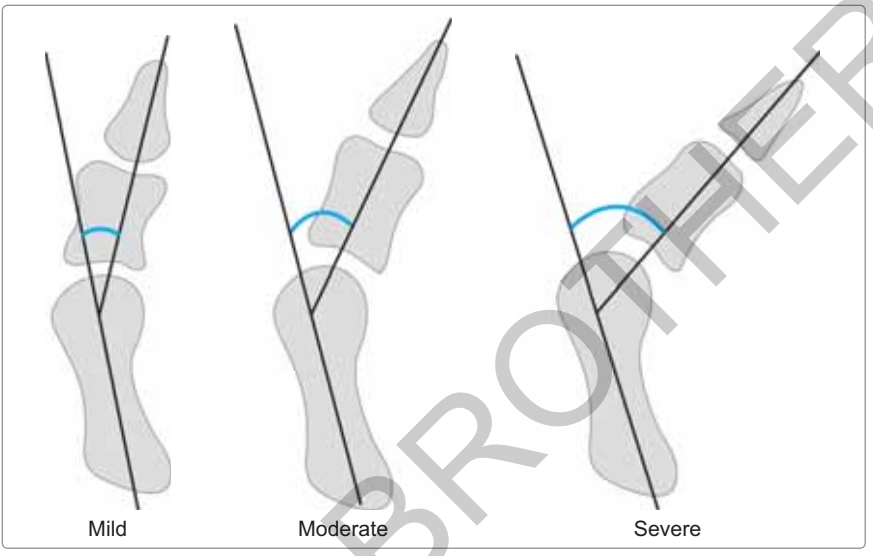

OSTEOCHONDRITIS DISSECANS OF TALUS

Berndt and Harty Classification

- *Stage I:* Subchondral bone compression (marrow edema)
- *Stage II:*
  - *Stage IIa:* Subchondral cyst
  - *Stage IIb:* Incomplete separation of fragment

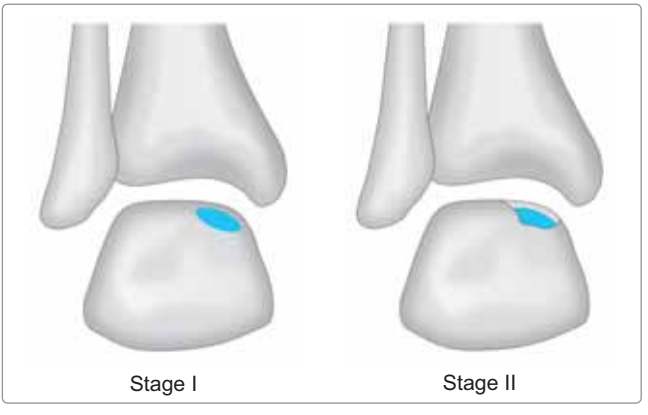

JAYPEE BROTHERS

- *Stage III:* Complete separation but no displacement
- *Stage IV:* Displaced fragment

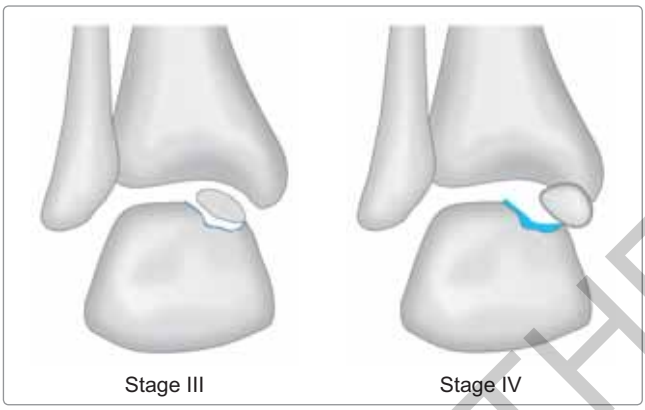

DIABETIC FOOT

Wagner Classification

It assesses ulcer depth and the presence of osteomyelitis or gangrene.

- *Grade 0:* Intact skin
- *Grade 1:* Superficial ulcer of skin or subcutaneous tissue
- *Grade 2:* Ulcers extend into tendon, bone, or capsule
- *Grade 3:* Deep ulcer with osteomyelitis, or abscess
- *Grade 4:* Partial foot gangrene
- *Grade 5:* Whole foot gangrene

Ganga Diabetic Foot Classification

- *Class 1:* Foot at risk
- *Class 2:* Superficial ulcers without infection
- *Class 3:* Crippled foot
- *Class 4:* Critical foot

CHARCOT'S ARTHROPATHY

Eichenholtz Classification

- *Stage 0:* Clinically, there is joint edema, but radiographs are negative. Note that a bone scan may be positive before a radiograph is, making it a sensitive but not very specific modality.
- *Stage 1:* Osseous fragmentation with joint dislocation seen on radiograph ("acute Charcot").

JAYPEE BROTHERS

- *Stage 2:* Decreased local edema, with coalescence of fragments and absorption of fine bone debris.
- *Stage 3:* No local edema, with consolidation and remodeling (albeit deformed) of fracture fragments. The foot is now stable.

TENDOACHILLES DISORDERS

- *Insertional tendinitis:* Retrocalcaneal bursitis
- *Noninsertional tendinitis:*
  - Peritendinitis
  - Peritendinitis with tendinosis
  - Tendinosis

TIBIALIS POSTERIOR INSUFFICIENCY

Tendo Achilles Chronic Injury Classification

Myerson Algorithm

- *Type 1:* 1–2 cm tear (Direct repair)
- *Type 2:* 2–5 cm tear (V-Y advancement/Tendon transfer)
- *Type 3:* >5 cm tear (Tendon transfer)

Kuwada Algorithm

- *Type 1:* Partial tears (Conservative management)
- *Type 2:* Complete tears with <3 cm gap (Direct repair)
- *Type 3:* 3–6 cm gap (tendon graft)
- *Type 4:* >6 cm gap (Gastrocnemius recession with tendon graft)

Johnson and Strom Classification

- *Stage 1:* It is characterized by swelling, pain, inflammation, and effusion of the tendon sheath. No deformity of the foot. Able to invert the foot.
- *Stage 2:* It is characterized by loss of function of tibialis posterior and inability to perform single-toe raise.
- *Stage 3:* Loss of function with fixed hindfoot deformity. Degenerative changes present.
- *Stage 4:* Degenerative changes with valgus positioning of the ankle.

JAYPEE BROTHERS

or detailed information on othopedics books, visit our website **www.jaypeebrothers.com,** for detailed inform

ORTHOPEDIC NAVIGATOR

An Orthopedic Guide for Postgraduates

This book contains an intricate, exhaustive, and comprehensive compilation of classification systems used in orthopedics (trauma, regional conditions of upper and lower limbs, pediatric orthopedic, spine, sports, congenital conditions, etc.) explained with simple line diagrams useful for any student to reproduce in their examination papers. In addition, it also contains Orthopedic Formulas, Diagnostic Criteria, Radiological Lines and Signs, which are important from an examination and knowledge point of view.

Not to forget an updated Question Bank of over 500 questions covering MS and DNB questions over the past years arranged topic-wise for easy reading. The book also provides tips on the new pattern of DNB Practical Examination and its *Do's and Don'ts.*

All in all, an all in one book!

Jacob Ipe MBBS Dip (Ortho) DNB (Ortho) completed his Diploma in Orthopedics from Father Muller Medical College (FMMC), Mangaluru, Karnataka, India, and went on to do his Masters in DNB in Bangalore Baptist Hospital, Bengaluru, Karnataka. Having gained experience in both MS and DNB fields, his inputs on DNB pattern of examinations and questions make this book whole. Besides practicing Orthopedics, he enjoys sketching as his hobby as a result of which this book is now equipped with the most simple and easy diagrams, which were hand-drawn by the author himself with the sole purpose of easy reproducibility of the same during the examinations by the students.

Febin Ahamed PI MBBS MS (Ortho) completed his MS in Orthopedics from Father Muller Medical College, Mangaluru, Karnataka, India, and worked alongside a few prestigious names in the field of Orthopedics. Having a keen interest in Limb Reconstruction and Microvascular Surgery, he pursued it ardently and is on his way to becoming a Hand Surgeon from Ganga Hospital, Coimbatore, Tamil Nadu, India. Besides academics, he pursues his passion in creative ideologies, business, and administrative work.

Jacob Eapen MBBS MS (Ortho) DNB (Ortho) Fellow in Arthroplasty (Depuy) is a qualified Orthopedic Surgeon who graduated from Father Muller Medical College, Mangaluru, Karnataka, India, and went on to pursue Fellowship in Joint Replacement. Alongside a roaring practice, he also kindled a spirit in research and academics, which made him a crucial factor in writing this book. His thirst for knowledge and skill has seen him pursue FNB in Hand and Microvascular Surgery in the prestigious Ganga Hospital, Coimbatore, Tamil Nadu, India.

Printed in India

Available at all medical bookstores
or buy online at www.jaypeebrothers.com

JAYPEE BROTHERS
Medical Publishers (P) Ltd.
EMCA House, 23/23-B, Ansari Road,
Daryaganj, New Delhi - 110 002, INDIA
www.jaypeebrothers.com

Join us on facebook.com/JaypeeMedicalPublishers

Shelving Recommendation
ORTHOPEDICS

ISBN 978-93-5465-203-5