l information on ophthalmology books, visit our website www.jaypeebrothers.com, for detailed information on ophthalmology books, visit our website www.jaypeebrothers.com

Current Concepts in Refractive Surgery

Comprehensive Guide for Decision Making & Surgical Techniques



Editors
Jeewan S Titiyal
Manpreet Kaur
Sridevi Nair

Foreword
Walter Sekundo

Get Full Access with added features at *emedicine360.com*

JAYPEE

Contents

SECTION 1

HISTORICAL PERSPECTIVE

Chapter 1. Evolution of Refractive Surgery 3
Sridevi Nair, Manpreet Kaur, Jeewan S Titiyal

- The Past: A Historical Overview of Refractive Surgery *3*
- The Present: Current Trends in Refractive Surgery *5* • The Future of Refractive Surgery *5*

SECTION 2

PREOPERATIVE WORKUP AND DECISION MAKING

Chapter 2. Corneal Wound Healing in Keratorefractive Surgery 11
Sridevi Nair, Harika Regani, Manpreet Kaur, Jeewan S Titiyal

- Anatomy of the Cornea *11* • Corneal Wound Healing Following Surface Ablation *11*
- Corneal Wound Healing Following LASIK *13* • Corneal Wound Healing Following SMILE *14*
- Clinical Relevance of Corneal Wound Healing after Keratorefractive Surgery *15*

Chapter 3. Corneal Topography 18
Sridevi Nair, Manpreet Kaur, Jeewan S Titiyal

- Keratometry *18* • Keratoscopy *18* • Elevation-based Topography Systems *23*
- Color LED Ray Tracing Topography *31*

Chapter 4. Corneal Biomechanics 33
Saurabh Verma, Sridevi Nair, Manpreet Kaur, Jeewan S Titiyal

- Corneal Biomechanics and Refractive Surgery *33* • Corneal Biomechanical Assessment *33*
- Limitations and Future Directions *40* • Emerging Technologies *40*

Chapter 5. Aberrometry and Wavefront Analysis 42
Anand Singh Brar, Manpreet Kaur, Sridevi Nair, Jeewan S Titiyal

- Lower- and Higher-order Aberrations *42* • Wavefronts *43* • Zernike Polynomials *44*
- Aberrometry *44* • Importance in Refractive Surgery *46* • Future Developments *50*

Chapter 6. Posterior Segment Screening and Refractive Surgery 52
Priyanka, Brijesh Takkar, Manpreet Kaur, Jeewan S Titiyal

- Preoperative Posterior Segment Screening *52*
- Postrefractive Surgery Vitreoretinal Complications *54*

Chapter 7. Preoperative Evaluation, Patient Counseling, and Decision Making 58
Sridevi Nair, Manpreet Kaur, Jeewan S Titiyal

- Clinical History *58* • Clinical Examination *60* • Decision Making *62*
- Patient Counseling *65*

SECTION 3

CORNEAL ABLATIVE PROCEDURES

Chapter 8. Surface Ablation 71
Neelam Runda, Manpreet Kaur, Jeewan S Titiyal, Sridevi Nair
♦ Patient Selection *71* ♦ Surgical Techniques *71* ♦ Excimer Laser Ablation *74*
♦ Outcomes *75* ♦ Complications *76*

Chapter 9. Complications of Surface Ablation 78
Manpreet Kaur, Sridevi Nair, Jeewan S Titiyal
♦ Postoperative Pain *78* ♦ Corneal Haze *78* ♦ Delayed Epithelial Healing *81*
♦ Epithelial Flap-related Complications *81* ♦ Glare and Halos *81* ♦ Decentered Ablation *81*
♦ Central Islands *82* ♦ Corneal Infiltrates *82* ♦ Infectious Keratitis *82* ♦ Ectasia *82*
♦ Dry Eyes *82* ♦ Raised Intraocular Pressure *82*

Chapter 10. Laser-assisted in Situ Keratomileusis 84
Anubha Rathi, Manpreet Kaur, Jeewan S Titiyal, Sridevi Nair
♦ Indications and Patient Selection *84* ♦ Lasik Flap Creation *84*
♦ Excimer Laser Ablation *90* ♦ Clinical Outcomes *92*

Chapter 11. Complications of Flap-Based Corneal Ablation 94
Sridevi Nair, Manpreet Kaur, Jeewan S Titiyal
♦ Intraoperative Complications *94* ♦ Postoperative Complications *100*

Chapter 12. Customized Corneal Ablation 111
Sridevi Nair, Manpreet Kaur, Jeewan S Titiyal
♦ Classical Ablation Profiles and Need for Customization *111* ♦ Customized Corneal Ablation Profiles *111*
♦ Wavefront-optimized Ablation *111* ♦ Wavefront-guided Ablation *114*
♦ Topography-guided Ablation *116* ♦ Aspheric or Q Factor Adjusted Ablation Profile *119*
♦ Ray Tracing-based Ablation *119*

SECTION 4

SMALL INCISION LENTICULE EXTRACTION

Chapter 13. Small Incision Lenticule Extraction 125
Manpreet Kaur, Jeewan S Titiyal, Sridevi Nair
♦ Evolution of Refractive Lenticule Extraction *125* ♦ Patient Selection *125*
♦ Machine and Laser Settings *126* ♦ Surgical Technique *129*
♦ Outcomes *132* ♦ SMILE for Astigmatism *132* ♦ SMILE for Hyperopia *132*

Chapter 14. Complications of Small Incision Lenticule Extraction 135
Manpreet Kaur, Jeewan S Titiyal, Sridevi Nair
♦ Intraoperative Complications *135* ♦ Postoperative Complications *141*

SECTION 5

LENS-BASED REFRACTIVE SURGERIES

Chapter 15. Phakic Intraocular Lenses 151
Manpreet Kaur, Jeewan S Titiyal, Sridevi Nair
♦ Types of Phakic IOLs *151* ♦ Preoperative Evaluation and Case Selection *155*
♦ Surgical Techniques *157* ♦ Postoperative Assessment of Vaulting *158* ♦ Outcomes *159*

Chapter 16. Complications of Phakic Intraocular Lenses.....161
Manpreet Kaur, Jeewan S Titiyal, Sridevi Nair
♦ Intraoperative Complications *161* ♦ Postoperative Complications *162*

SECTION 6
ENHANCEMENTS AND RETREATMENTS

Chapter 17. Retreatment after Corneal Laser Ablation 173
Sridevi Nair, Manpreet Kaur, Jeewan S Titiyal
♦ Incidence *173* ♦ Indications *173* ♦ Risk Factors *173*
♦ Preoperative Evaluation and Decision Making *174* ♦ Surgical Techniques of Retreatment *175*
♦ Outcomes *177*

Chapter 18. Retreatment after SMILE 179
Manpreet Kaur, Jeewan S Titiyal, Sridevi Nair
♦ Incidence *179* ♦ Risk Factors *179* ♦ Management *179*

SECTION 7
PRESBYOPIA

Chapter 19. Refractive Surgery for Presbyopia: An Overview.....187
Manpreet Kaur, Jeewan S Titiyal, Sridevi Nair
♦ Cornea-based Refractive Surgical Procedures *187* ♦ Lens-based Approach for Presbyopia Correction *189* ♦ Sclerociliary Complex Based Procedures for Presbyopia *192*

Chapter 20. Presbyopic Excimer Laser Ablation 193
Sana Tinwala, Manpreet Kaur, Sridevi Nair, Jeewan S Titiyal
♦ Patient Selection *193* ♦ Corneal Approach to Presbyopia Correction *194*
♦ Multifocal Laser Vision Correction *194* ♦ Laser-blended Vision *197* ♦ Counseling *198*

Chapter 21. Corneal Inlays 200
Sana Tinwala, Manpreet Kaur, Jeewan S Titiyal, Sridevi Nair
♦ Corneal Inlays *200* ♦ Corneal Onlays *204*

SECTION 8
MISCELLANEOUS

Chapter 22. Bioptics.....207
Farin Shaikh, Manpreet Kaur, Jeewan S Titiyal, Sridevi Nair
♦ Patient Selection and Preoperative Work-up *207*
♦ Classification of Surgical Techniques of Bioptics *207*
♦ Surgical Outcomes with Different Procedure Combinations *209*

Chapter 23. Corneal Collagen Cross-linking and Refractive Surgeries.....213
Sridevi Nair, Harathy Selvan, Manpreet Kaur, Jeewan S Titiyal
♦ Corneal Collagen Cross-linking Xtra *213* ♦ Corneal Collagen Cross-linking Plus *217*

Chapter 24. Refractive Surgery in Challenging Scenarios 221
Sridevi Nair, Manpreet Kaur, Jeewan S Titiyal
♦ Refractive Surgery in Pediatric Patients *221* ♦ Refractive Surgery for Hyperopia *222*
♦ Refractive Surgery in Post-keratoplasty Patients *225* ♦ Refractive Surgery in Pseudophakia *226*

Chapter 25. Intrastromal Corneal Ring Segments 229
Rinky Agarwal, Manpreet Kaur, Sridevi Nair, Jeewan S Titiyal
♦ Mechanism of Action *229* ♦ Indications and Patient Selection *230*
♦ Intrastromal Corneal Rings and Ring Segments *230* ♦ Surgical Technique *231*
♦ Additional Procedures *232* ♦ Outcomes *232* ♦ Complications *232*

Chapter 26. Incisional Refractive Surgery 235
Meghal Gagrani, Manpreet Kaur, Jeewan S Titiyal, Sridevi Nair
♦ Radial Keratotomy *235* ♦ Astigmatic Keratotomy *236*

Index 241

SECTION 2

Preoperative Workup and Decision Making

2. **Corneal Wound Healing in Keratorefractive Surgery**
   Sridevi Nair, Harika Regani, Manpreet Kaur, Jeewan S Titiyal
3. **Corneal Topography**
   Sridevi Nair, Manpreet Kaur, Jeewan S Titiyal
4. **Corneal Biomechanics**
   Saurabh Verma, Sridevi Nair, Manpreet Kaur, Jeewan S Titiyal
5. **Aberrometry and Wavefront Analysis**
   Anand Singh Brar, Manpreet Kaur, Sridevi Nair, Jeewan S Titiyal
6. **Posterior Segment Screening and Refractive Surgery**
   Priyanka, Brijesh Takkar, Manpreet Kaur, Jeewan S Titiyal
7. **Preoperative Evaluation, Patient Counseling, and Decision Making**
   Sridevi Nair, Manpreet Kaur, Jeewan S Titiyal

JAYPEE BROTHERS

CHAPTER 2

Corneal Wound Healing in Keratorefractive Surgery

Sridevi Nair, Harika Regani, Manpreet Kaur, Jeewan S Titiyal

INTRODUCTION

Corneal wound healing is an important determinant of the visual and anatomical outcomes after keratorefractive surgeries such as photorefractive keratectomy (PRK), laser-assisted in situ keratomileusis (LASIK), and small incision lenticule extraction (SMILE). Post-refractive surgery wound healing may be influenced by various factors including the type of surgery, anatomical level of treatment, amount of refractive correction, postoperative inflammatory response and the patient's genetics. A more comprehensive understanding of this aspect may help us to further improve the refractive predictability and safety of keratorefractive procedures.

ANATOMY OF THE CORNEA

The knowledge of the anatomical structure of cornea is a prerequisite for understanding the corneal wound healing response following refractive surgeries. The corneal epithelium is the uppermost layer having a 5–6-layered structure. The epithelial basement membrane (EBM) is a highly specialized extracellular matrix (ECM), about 40–60 nm in thickness composed of laminins, collagens, heparan sulfate proteoglycans, and nidogens. The Bowman's layer lies beneath the epithelial layer and is composed of randomly oriented type-1 collagen fibrils. The anterior one-third of stromal layer is made of collagen lamellae, which are oriented in an oblique direction to the surface. The stromal lamellae show extensive branching and are interwoven with each other both horizontally and anteroposteriorly. Posterior stromal lamellae are oriented parallel to the surface and are thicker and wider as compared to the anterior lamellae. Peripheral cornea exhibits more extensive and deeper lamellar interweaving, unlike the central cornea with less interwoven posterior lamellae.[1] Keratocytes within the corneal stroma are interspersed between these lamellae. The density of keratocytes is higher in the anterior as compared to the middle and posterior stroma. The cornea is densely packed with nerve fibers that originate from the ophthalmic division of the trigeminal nerve. The nerves enter the corneal limbus in a radial centripetal manner parallel to the collagen fibers and form bundles in the anterior one-third of stroma. The nerves then run perpendicularly toward the epithelium to form a sub-basal plexus between the basal epithelial cells and Bowman's membrane. Fine terminals arising from this plexus innervate the epithelial cells.[2]

The corneal epithelial cells and the keratocytes are the two main cell types involved in wound healing after keratorefractive surgeries **(Fig. 1)**. The basic elements of corneal wound healing following keratorefractive procedures are as follows:[3]

- Epithelial changes including hypertrophy
- Keratocytes apoptosis, activation and differentiation into fibroblasts
- Conversion of fibroblasts to myofibroblasts
- Absorption, remodeling, and deposition of ECM
- Formation of hyper- and hypocellular stromal scar.

CORNEAL WOUND HEALING FOLLOWING SURFACE ABLATION

Photorefractive keratectomy remains a popular procedure for correcting myopic and hyperopic refractive errors. The surgery involves the removal of corneal epithelium followed by excimer laser ablation of the stroma.

Epithelial Changes

The damage to the corneal epithelial cells initiates the wound healing response by inducing apoptosis of the stromal keratocytes lying beneath it **(Flowchart 1)**. Epithelial cells migrate and proliferate from the limbus to reestablish the layer within the next 3–5 days. The regenerated epithelial layer following PRK is about 20% thicker than preoperative levels and its stabilization may take up to 1 year. This is in contrast to the epithelial thickening observed after LASIK, which stabilizes earlier, in about a month. The thickening of the epithelium is more in areas with deeper stromal ablation and is probably a biological response to restore the original curvature of the cornea and smoothen out the stromal surface irregularities created by excimer laser ablation. The increase in epithelial thickness is associated with myopic regression observed after

JAYPEE BROTHERS

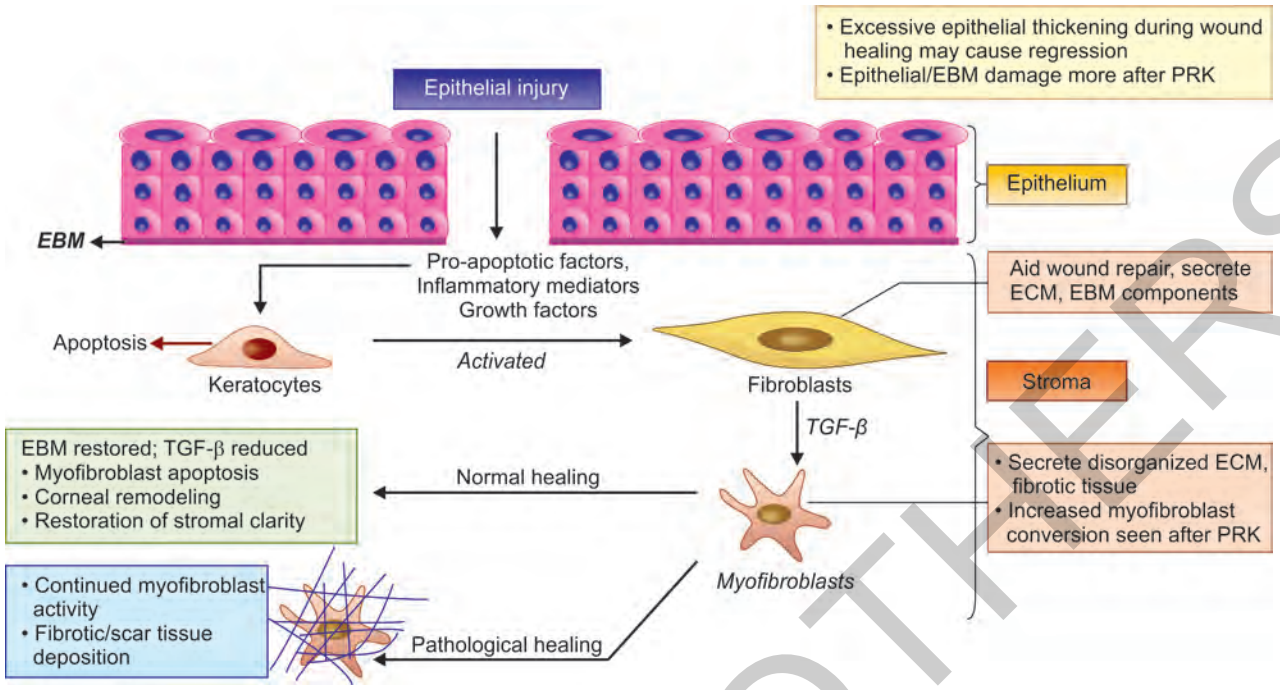

Fig. 1: Anatomy of cornea and elements of corneal wound healing. (EBM: epithelial basement membrane; ECM: extracellular matrix; PRK: photorefractive keratectomy; TGF-β: transforming growth factor-beta)

Flowchart 1: Corneal wound healing after keratorefractive surgeries.

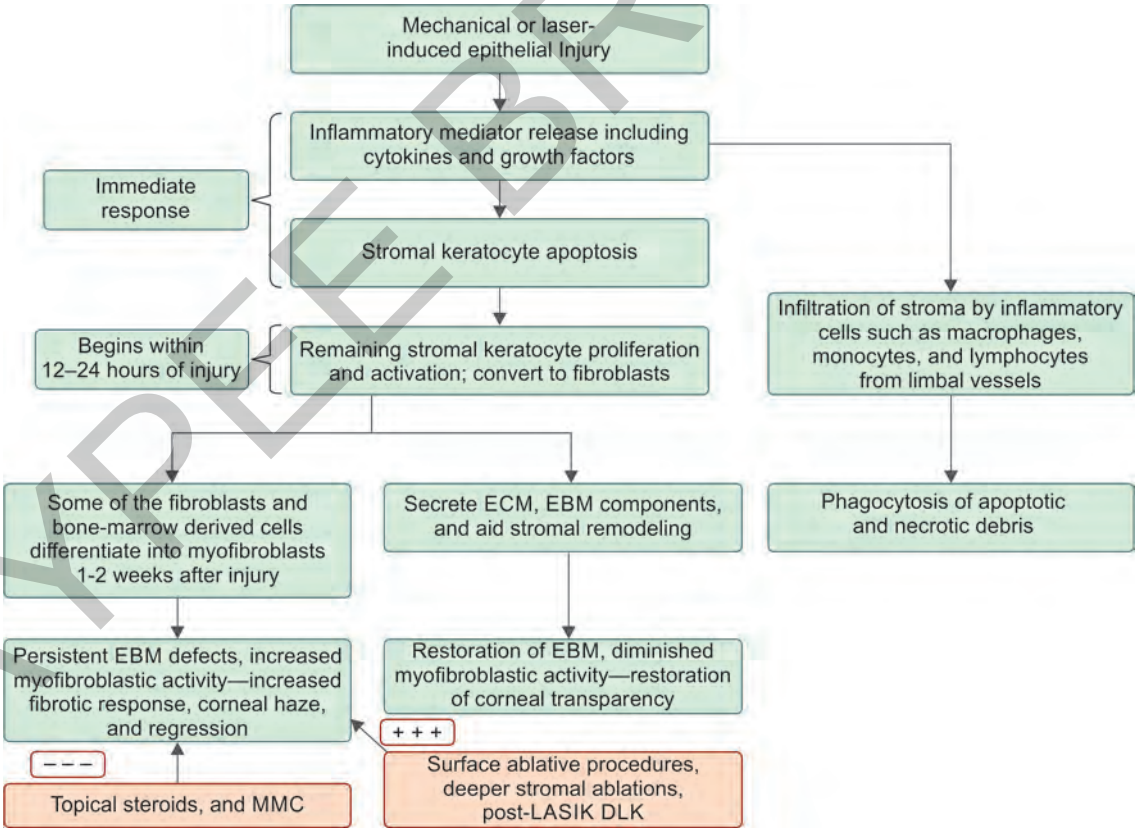

(EBM: epithelial basement membrane; ECM: extracellular matrix; LASIK: laser-assisted in situ keratomileusis; DLK: diffuse lamellar keratitis; MMC: mitomycin C)

the procedure.[4] Various factors have been attributed for epithelial thickening after keratorefractive surgeries including the elongation of basal epithelial cells, thickening of superficial epithelial cells, absence of the mechanical influence of the upper lid on the epithelial layer owing to the corneal flattening, and the abrupt curvature changes observed with smaller optical zone and deeper ablations.

JAYPEE BROTHERS

Stromal Changes

Stromal keratocytes are instrumental in facilitating corneal wound healing after PRK. They play an important role in stromal remodeling and EBM deposition. Epithelial cell damage leads to release of pro-apoptotic mediators that trigger an initial wave of apoptosis followed by necrosis of stromal keratocytes in the involved region. An influx of inflammatory cells including monocytes, polymorphonuclear cells, fibrocytes, and other bone marrow-derived cells from the limbal vessels is noted immediately after the ablation. A compromised epithelial barrier potentiates the effects of cytokines such as interleukin 1 (IL-1), tumor necrosis factor (TNF), fibroblast growth factor (FGF), platelet-derived growth factor (PDGF), epidermal growth factor (EGF), transforming growth factor-beta (TGF-β) derived from epithelial cells, lacrimal glands, and bone marrow-derived cells, by providing an unhindered access to the stroma. Following the initial stage of apoptosis, surviving keratocytes from the adjacent areas proliferate, transform into fibroblasts, and repopulate the stroma under the influence of these cytokines. The stromal fibroblasts actively participate in the process of repair by secreting ECM components such as fibronectin, proteinases, and integrins. During the subsequent weeks, TGF-β facilitates the conversion of some of the stromal fibroblasts into myofibroblasts. These cells are characterized by the expression of smooth muscle α-actin and play a role in the reparative phase by facilitating the development of fibrotic tissue and deposition of disorganized collagen and glycosaminoglycans (GAGs). Myofibroblasts may also be derived from bone marrow derived cells sequestered from limbal blood vessels. Myofibroblasts are the main effectors of the corneal fibrotic response. A transient reduction in the corneal transparency mediated by stromal hypercellularity, decreased intracellular crystallins in the fibroblasts, and the deposition of disorganized components of the matrix are observed during this phase. Deeper stromal ablation for higher myopic corrections has been associated with greater keratocyte apoptosis and myofibroblast cell conversion.[5-7]

Epithelial basement membrane regeneration is an important component of corneal remodeling. The regularity of the stromal surface is an important factor, which influences its assembly. Stromal keratocytes, fibroblasts derived from keratocytes, and epithelial cells mainly contribute to the secretion of EBM. Complete restoration of basement membrane is essential to stem the inflow of factors such as TGF-β and PDGF and promote the gradual apoptosis and disappearance of the myofibroblasts. This heralds the phase of corneal remodeling. The normal transparency of the cornea is restored during the remodeling phase. It is characterized by a prolonged process of synthesis, degradation, and resynthesis, which entails the regularization of the diameter of the collagen fibrils and a spatial reorganization of stromal fibrils. During the remodeling process, collagen fibril size becomes progressively more regular and attains a more orderly arrangement.[8] The failure of the EBM to regenerate properly may lead to the persistent dissemination of TGF and PDGF into the anterior stroma, resulting in the development of opacity generating myofibroblasts, which may contribute to late postoperative corneal haze. Since anterior stromal keratocytes secrete components of EBM and play an important role in its regeneration, deeper stromal ablations with greater associated keratocyte apoptosis could lead to slower regeneration of EBM.[9]

Corneal Nerve Regeneration

Excimer laser ablation during PRK sever the nerves at the sub-basal plexus and the superficial anterior stromal level. The advent of confocal microscopy has allowed us to qualitatively and quantitatively study in vivo corneal nerve regeneration after keratorefractive surgeries. New neurites have been shown to arise from the severed endings on confocal microscopy as early as the first postoperative week following PRK. Though about 50% of subepithelial nerve regeneration is completed by 6–8 months, structural and morphological changes may be observed on confocal microscopy for up to an year after surgery **(Figs. 2A to F)**.[10] The sub-basal density of nerve fibers approaches the preoperative levels at about 2 years postoperatively; the degree and rate of corneal nerve regeneration are inversely proportional to the amount of refractive correction.[11,12] While corneal stromal fibroblasts exert neurotrophic effects and promote nerve regeneration, an increased fibrotic response during the corneal wound healing may lead to delayed reinnervation due to the inhibitory effect of myofibroblasts on corneal nerve regeneration.[13,14]

CORNEAL WOUND HEALING FOLLOWING LASIK

The corneal wound healing response and the associated fibrotic response are usually less pronounced after LASIK as compared with PRK. LASIK, being a lamellar procedure, does not entail the disruption of the central epithelium or the EBM. The complex epithelial-stromal interactions, fibroblast generation, and myofibroblast-related haze that are observed with PRK are essentially limited to the flap edge area after LASIK. This is clinically characterized by a circumferential haze at the flap edge **(Fig. 3)**.[8]

The lamellar cut created by a microkeratome or femtosecond (FS) laser induces localized keratocyte apoptosis and necrosis at the site of epithelial injury and just in the vicinity of the lamellar interface. Localized apoptosis and necrosis observed around the interface by the microkeratome blade are due to the tracking of epithelial debris with IL-1 into the interface.[15] Cytokines from the injured peripheral epithelium could also diffuse along the lamellar interface and into the central stroma. This may be important

JAYPEE BROTHERS

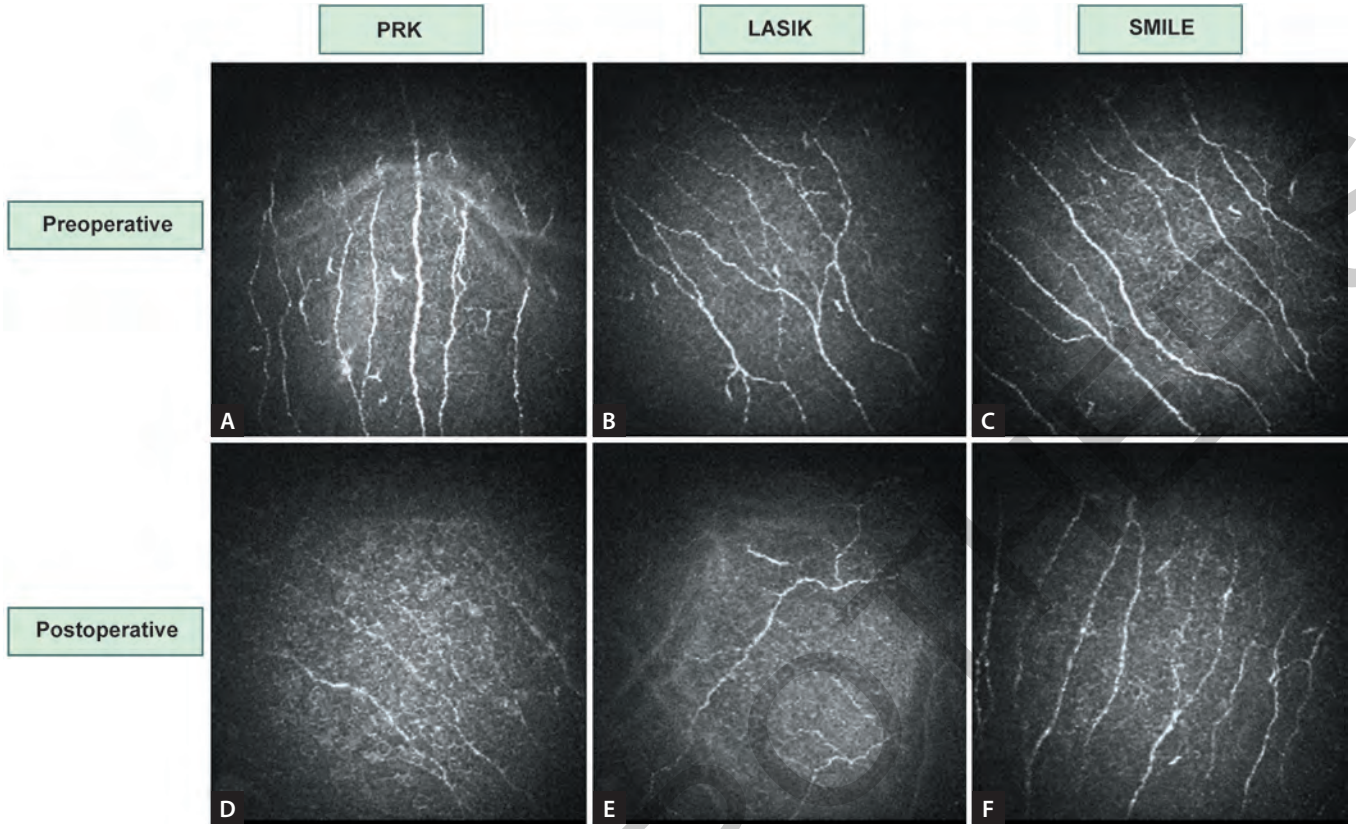

Figs. 2A to F: Sub-basal corneal nerve fiber layer regeneration after photorefractive keratectomy (PRK), laser-assisted in situ keratomileusis (LASIK), and small incision lenticule extraction (SMILE): (A) Preoperative sub-basal corneal nerve fiber layer in a patient undergoing PRK; (B) Preoperative sub-basal corneal nerve fiber layer in a patient undergoing LASIK; (C) Preoperative sub-basal corneal nerve fiber layer in a patient undergoing SMILE; (D) Postoperative sub-basal corneal nerve fiber layer at 1 year after PRK; (E) Postoperative sub-basal corneal nerve fiber layer at 1 year after LASIK; (F) Postoperative sub-basal corneal nerve fiber layer at 1 year after SMILE.

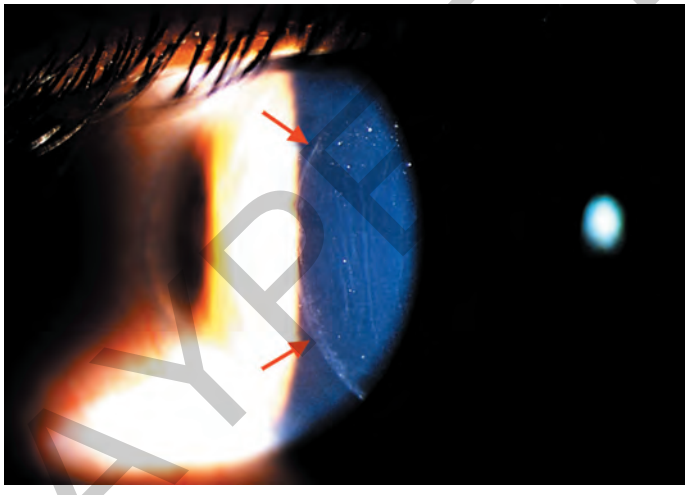

Fig. 3: Circumferential haze at flap edge after laser-assisted in situ keratomileusis (red arrows—fibrosed flap edge).

since it influences the localization of other events such as proximity between myofibroblasts and wound healing fibroblasts that produce hepatocyte growth factor (HGF), which tends to promote epithelial hyperplasia. This is one of the mechanisms of post-LASIK regression.

The wound healing response following FS-LASIK differs from that observed with microkeratome LASIK. The older, high-energy, low-frequency FS laser systems resulted in increased stromal keratocyte cell death. The cell death in these cases was mediated by necrosis rather than apoptosis and incited a greater inflammatory and fibrotic response as compared to microkeratome LASIK.

Stromal nerve bundles and sub-basal nerve plexus (at flap edge) are transected during LASIK owing to lamellar flap creation. In addition, the early postoperative period is marked by degeneration of the remaining sub-basal nerve plexus within the flap. Confocal microscopy has demonstrated intense denervation for up to 3 months following surgery. The nerve regeneration commences at the flap edge and progresses in a centripetal manner towards the center. The sub-basal nerve fiber regeneration is slower as compared to PRK, taking up to 5 years to reach the preoperative levels. Also, the nerve fibers regenerating from the residual stromal bed are not capable of crossing over the interface and connecting to the fibers within the flap.[11]

CORNEAL WOUND HEALING FOLLOWING SMILE

Corneal wound healing following SMILE has been less extensively studied than LASIK or PRK. Current evidence on the subject is derived from animal or human ex vivo studies

JAYPEE BROTHERS

and is suggestive of a less robust wound healing response as demonstrated by lesser keratocyte apoptosis, proliferation, and inflammation compared with FS-LASIK. Unlike FS-LASIK and PRK, SMILE does not employ excimer laser or require the creation of a lamellar corneal flap. This results in less trauma to the epithelial cells, reduced stromal tissue damage and cytokine release, which may contribute to the significantly milder healing response after SMILE. There is less damage to stromal nerves, better preservation of the sub-basal nerve plexus, and faster nerve recovery compared to LASIK.[16,17]

CLINICAL RELEVANCE OF CORNEAL WOUND HEALING AFTER KERATOREFRACTIVE SURGERY

Post-refractive surgery regression, corneal haze, and dry eye are primarily influenced by corneal wound healing. A more severe wound healing response is associated with a higher incidence of regression and haze. Postoperative haze and regression are higher in cases undergoing PRK and higher refractive error corrections. Postoperative dry eye has been reported to be more severe after LASIK than PRK or SMILE. **Table 1** compares the corneal wound healing after LASIK and PRK with emphasis on its clinical relevance.

Refractive Regression

Postoperative regression is the gradual complete or partial loss of the attempted refractive correction following a keratorefractive procedure. The reported incidence varies from 6.7 to 13.8% after PRK and 3 to 11.9% after LASIK.[8] Postoperative regression is attributed to differential changes in the thickness of the cornea due to a combination of stromal remodeling and epithelial hyperplasia. These processes predominate in regions of greater tissue removal leading to relative "reversal" of the initial correction. The relative contributions of the stroma and the epithelium in regression appear to be a function of postoperative time, type of refractive surgery, and type of refractive error in addition to other factors. The more robust wound healing response observed with deeper stromal ablations and PRK may lead to a higher associated potential for regression.[8,18]

Postoperative Haze

Corneal haze following keratorefractive surgery is characterized by a reduction in corneal transparency. Two types of postoperative haze are observed following PRK. The first is the transient, clinically insignificant corneal haze seen during the initial weeks of corneal repair, mediated by the fibroblasts, stromal hypercellularity and disorganized deposition of stromal matrix components. This haze gradually clears up within a year of surgery during the remodeling phase that follows. The second is the late haze, which usually develops around 2–3 months, peaks at about 6 months, and may persist for more than 3 years after surgery. This haze can cause clinical symptoms such as decreased visual acuity, glare, or haloes. Myofibroblasts derived from keratocytes and bone marrow-derived precursor cells as well as the opaque ECM secreted by these cells are thought to be responsible for late haze after PRK. Risk factors for development of increased haze include higher refractive correction (>6D myopia), stromal surface irregularity associated with persistent defects in EBM, delayed healing of epithelial defect, ultraviolet (UV) light exposure, decreased tear production, use of older excimer lasers with larger spot sizes, and certain genetic predispositions.[9,19] The use of a rotating brush to remove the epithelium as compared to a blade has been associated with increased cellular infiltrates postoperatively, owing to increased release of interleukins into the stroma.[6] Studies have reported a lesser incidence of postoperative haze with the use of excimer laser for epithelial ablation (in transepithelial PRK) as compared to mechanical debridement.[20]

The reported incidence of postoperative haze and regression after LASIK is much lower owing to the preservation of the central epithelium and basement membrane.

TABLE 1: Comparative evaluation of corneal wound healing response after laser-assisted in situ keratomileusis (LASIK) and photorefractive keratectomy (PRK).

Corneal wound healing	*PRK*	*LASIK*	*Clinical significance*
Epithelial healing	Increased damage to epithelial cells, EBM, and keratocytes; associated with increased inflammatory mediator release	Lesser damage to epithelial cells, EBM, and keratocytes	Increased thickening of the regenerated epithelial layer after PRK, leading to *increased regression*
Stromal healing and remodeling	Increased keratocyte damage, apoptosis, inflammatory mediator release, and myofibroblast conversion	Lesser keratocyte damage, apoptosis, and activation	Increased ECM deposition leading to *higher incidence of stromal haze and regression* after PRK
Nerve regeneration	Lesser corneal nerve damage; limited to sub-basal plexus and superficial stromal bundles	More extensive nerve damage involving the sub-basal plexus (at flap edge) and anterior stromal nerve bundles	Higher incidence of *postoperative dry eye* with LASIK due to increased damage and slower regeneration of corneal nerves

(EBM: epithelial basement membrane; ECM: extracellular matrix)

JAYPEE BROTHERS

However, direct implantation or ingrowth of epithelium into the lamellar interface provides a local source of epithelial cytokines and can result in interface haze, regression, and diffuse lamellar keratitis (DLK).[21] An increased risk of haze and regression has also been observed with thin flaps (<100 microns) or donut-shaped flaps. This is attributed to the closer proximity of the photodisruptive laser application to the EBM, which may cause damage to this layer, affecting the penetration of cytokines into the stroma and potentiation of the wound healing by complex epithelial-stromal interactions.[22]

Postoperative Dry Eye after Keratorefractive Surgery

Postoperative dry eye after keratorefractive surgery is mainly caused by the interruption of the corneal reflex arc due to laser-induced corneal nerve damage, which leads to impaired lacrimal gland function. It results in decreased basal and reflex tearing, reduced blink rate, and impairment of the neurotrophic effect on the epithelial cells. The latter may manifest as persistent epithelial staining indicative of epitheliopathy even in the absence of aqueous deficiency. Incidence and severity of dry eye after PRK and SMILE is less than LASIK, owing to the more extensive nerve damage and slower nerve regeneration following LASIK.[23] Some of the potential risk factors that have been associated with post-LASIK dry eye include flap creation method, hinge location, hinge width, ablation profile, and depth of ablation. Though there are reports of increased dry eye with the use of microkeratome for flap creation, superior (versus nasal/temporal) hinge location, hyperopic ablation profiles, narrower hinge width, thicker flaps, and deeper stromal ablations, conclusive evidence establishing the role of these factors in post-LASIK dry eye is lacking.[24,25]

CONCLUSION

Our understanding of the complexities of corneal wound healing after keratorefractive surgery has improved over the decades. This has facilitated advancements in research focused on targeted therapy to minimize the occurrence of complications such as postoperative haze, regression, and dry eye that have been associated with the wound healing response and corneal nerve regeneration. Inhibition of TGF-β signaling by targeted gene therapy has been shown to treat post-PRK haze in animal models.[26] Agents such as nerve growth factor (NGF), pigment epithelial derived factor (PEDF), and docosahexaenoic acid (DHA) have been found to promote nerve regeneration in animal models. These agents may have a potential therapeutic role in reducing the incidence and severity of dry eye symptoms in post-refractive surgery patients.[27] Therapeutic advances enabled by an improved understanding of corneal wound healing after keratorefractive procedures are expected to further improve the predictability and safety of these procedures.

REFERENCES

1. Meek KM, Knupp C. Corneal structure and transparency. Prog Retin Eye Res. 2015;49:1-16.
2. Sridhar MS. Anatomy of cornea and ocular surface. Indian J Ophthalmol. 2018;66(2):190-4.
3. Kaji Y, Yamashita H, Oshika T. Corneal wound healing after excimer laser keratectomy. Semin Ophthalmol. 2003; 18(1):11-6.
4. Erie JC. Corneal wound healing after photorefractive keratectomy: a 3-year confocal microscopy study. Trans Am Ophthalmol Soc. 2003;101:293-333.
5. Tomás-Juan J, Murueta-Goyena Larrañaga A, Hanneken L. Corneal regeneration after photorefractive keratectomy: a review. J Optom. 2015;8(3):149-69.
6. Wilson SE. Biology of keratorefractive surgery—PRK, PTK, LASIK, SMILE, inlays and other refractive procedures. Exp Eye Res. 2020;198:108136.
7. Dupps WJ, Wilson SE. Biomechanics and wound healing in the cornea. Exp Eye Res. 2006;83(4):709-20.
8. Spadea L, Giammaria D, Trabucco P. Corneal wound healing after laser vision correction. Br J Ophthalmol. 2016; 100(1):28-33.
9. Marino GK, Santhiago MR, Torricelli AAM, Santhanam A, Wilson SE. Corneal molecular and cellular biology for the refractive surgeon: the critical role of the epithelial basement membrane. J Refract Surg. 2016;32(2):118-25.
10. Kauffmann T, Bodanowitz S, Hesse L, Kroll P. Corneal reinnervation after photorefractive keratectomy and laser in situ keratomileusis: an in vivo study with a confocal videomicroscope. Ger J Ophthalmol. 1996;5(6): 508-12.
11. Erie JC, McLaren JW, Hodge DO, Bourne WM. Recovery of corneal subbasal nerve density after PRK and LASIK. Am J Ophthalmol. 2005;140(6):1059-64.
12. Bandeira F, Yusoff NZ, Yam GH-F, Mehta JS. Corneal re-innervation following refractive surgery treatments. Neural Regen Res. 2019;14(4):557-65.
13. Jeon KI, Hindman HB, Bubel T, McDaniel T, DeMagistris M, Callan C, et al. Corneal myofibroblasts inhibit regenerating nerves during wound healing. Sci Rep. 201828;8(1): 12945.
14. Yam GH, Williams GP, Setiawan M, Yusoff NZ, Lee XW, Htoon HM, et al. Nerve regeneration by human corneal stromal keratocytes and stromal fibroblasts. Sci Rep. 2017;7: 45396.
15. Wilson SE, Mohan RR, Hong JW, Lee JS, Choi R, Mohan RR. The wound healing response after laser in situ keratomileusis and photorefractive keratectomy: elusive control of biological variability and effect on custom laser vision correction. Arch Ophthalmol. 2001;119(6):889-96.
16. Luft N, Schumann RG, Dirisamer M, Kook D, Siedlecki J, Wertheimer C, et al. Wound healing, inflammation, and corneal ultrastructure after SMILE and femtosecond laser-assisted LASIK: a human ex vivo study. J Refract Surg. 2018; 34(6):393-9.
17. Dong Z, Zhou X, Wu J, Zhang Z, Li T, Zhou Z, et al. Small incision lenticule extraction (SMILE) and femtosecond

JAYPEE BROTHERS

laser LASIK: comparison of corneal wound healing and inflammation. Br J Ophthalmol. 2014;98(2):263-9.
18. Lohmann CP, Güell JL. Regression after LASIK for the treatment of myopia: the role of the corneal epithelium. Semin Ophthalmol. 1998;13(2):79-82.
19. Lipshitz I, Loewenstein A, Varssano D, Lazar M. Late onset corneal haze after photorefractive keratectomy for moderate and high myopia. Ophthalmology. 1997;104(3):369-73; discussion 373-374.
20. Celik U, Bozkurt E, Celik B, Demirok A, Yilmaz OF. Pain, wound healing and refractive comparison of mechanical and transepithelial debridement in photorefractive keratectomy for myopia: results of 1 year follow-up. Cont Lens Anterior Eye. 2014;37(6):420-6.
21. Ambrósio R, Periman LM, Netto MV, Wilson SE. Bilateral marginal sterile infiltrates and diffuse lamellar keratitis after laser in situ keratomileusis. J Refract Surg. 2003;19(2):154-8.
22. Segev F, Mimouni M, Sela T, Munzer G, Kaiserman I. Risk factors for sporadic diffuse lamellar keratitis after microkeratome laser-assisted in situ keratomileusis: a retrospective large database analysis. Cornea. 2018;37(9): 1124-9.
23. Sambhi RDS, Sambhi GDS, Mather R, Malvankar-Mehta MS. Dry eye after refractive surgery: a meta-analysis. Can J Ophthalmol. 2020;55(2):99-106.
24. Raoof D, Pineda R. Dry eye after laser in-situ keratomileusis. Semin Ophthalmol. 2014;29(5-6):358-62.
25. Shtein RM. Post-LASIK dry eye. Expert Rev Ophthalmol. 2011;6(5):575-82.
26. Gupta S, Fink MK, Ghosh A, Tripathi R, Sinha PR, Sharma A, et al. Novel Combination BMP7 and HGF gene therapy instigates selective myofibroblast apoptosis and reduces corneal haze in vivo. Invest Ophthalmol Vis Sci. 2018; 59(2):1045-57.
27. He J, Cortina MS, Kakazu A, Bazan HEP. The PEDF neuroprotective domain plus DHA induces corneal nerve regeneration after experimental surgery. Invest Ophthalmol Vis Sci. 2015;56(6):3505-13.

JAYPEE BROTHERS

For detailed information on ophthalmology books, visit our website www.jaypeebrothers.com, for detailed information on ophthalmology books, visit our website www.jaypeebro

Current Concepts in
Refractive Surgery

Salient Features

- A comprehensive compilation of the entire armamentarium of modern-day refractive procedures, including corneal laser ablation, refractive lenticule extraction and lens-based surgeries
- Systematic organization into sections highlighting the evolution of refractive surgery, preoperative assessment and diagnostics, and current refractive techniques with their outcomes, advantages and limitations
- Highlights comprehensive preoperative assessment, patient counseling and decision-making with a special emphasis on the role of latest diagnostics and investigative modalities to optimize refractive practice
- Detailed description of the technical aspects of different refractive procedures including the specifications of various laser platforms, recommended parameters and laser settings, and treatment protocols
- High-quality clinical photographs, schematic diagrams, concise tables and self-explanatory, descriptive flowcharts to elucidate various aspects of refractive surgeries and recapitulate the salient points at a glance
- A reference guide for refractive surgeons providing an in-depth understanding of the refractive techniques, with surgical tips and tricks.



Jeewan S Titiyal MD began his academic sojourn as an undergraduate at the All India Institute of Medical Sciences (AIIMS), New Delhi, India, and currently Professor and Head, Department of Cornea, Cataract and Refractive Surgery, Dr Rajendra Prasad Centre for Ophthalmic Sciences, AIIMS, New Delhi. He has dedicated his academic career to the pursuit of excellence in the field of ophthalmology, and this book is a culmination of his endeavors to transmit knowledge and skills to the generation of ophthalmologists. He has been honored with invitation from various organizations to deliver keynote addresses, orations and guest lectures, and chair scientific sessions. He has been the 'teacher of teachers', and is the first Indian to perform live surgery in American Society of Cataract and Refractive Surgery (ASCRS), USA. He has to his credit numerous publications in peer-reviewed journals, and various books and chapters as well. He has been awarded the 'Senior Achievement Award' by the American Academy of Ophthalmology (2016), the 'Achievement Award' by the Asia-Pacific Academy of Ophthalmology (2015), the APACRS Educator Award (2015), the prestigious RP Dhanda Award and P Siva Reddy Award by the All India Ophthalmological Society and numerous gold medals. He was conferred the 'Padma Shri', one of the highest civilian awards in 2014, in recognition of his exemplary contributions in the field of medicine by the Government of India.



Manpreet Kaur MD received her medical training at the All India Institute of Medical Sciences (AIIMS), New Delhi, India. She developed a keen interest in academic research during her undergraduate days at AIIMS, New Delhi and was awarded the 'Dr Atm Prakash Gold Medal' in the field of surgery. Her interest in microsurgery led her to pursue further training in ophthalmology at her alma mater, and she is currently working as Assistant Professor specializing in Cornea, Cataract and Refractive Surgery Services, Dr Rajendra Prasad Centre for Ophthalmic Sciences, AIIMS, New Delhi. She was honored with the 'Achievement Award' by the American Academy of Ophthalmology as well as the 'International Heroes Award' by All India Ophthalmological Society and 'IJO Honor Award for Peer Review' by the Indian Journal of Ophthalmology. Her doctoral thesis received widespread recognition at international forums and was awarded the 'best free paper'. She was awarded the 'Best Senior Resident Award' in recognition of her dedication to patient care, research and teaching. She has numerous publications to her credit in peer-reviewed international journals, co-authored a book and penned several book chapters.



Sridevi Nair MD completed her undergraduate degree from the All India Institute of Medical Sciences (AIIMS), New Delhi, India and went on to pursue her postgraduation in Ophthalmology from Dr Rajendra Prasad Centre for Ophthalmic Sciences, AIIMS, New Delhi. She specialized in the field of Cornea, Cataract and Refractive Surgery during her Senior Residency at the same institute, which allowed her to pursue her passion for academics, clinical research and patient care. She is presently working as a Research Officer while also pursuing a PhD in Ophthalmology at her alma mater. Her doctoral thesis was awarded the AIIMS Oncology Research Award in 2019 and her research has received acclaim at various international and national scientific forums. She has numerous publications in peer-reviewed indexed journals and several book chapters to her credit.

Printed in India

Available at all medical bookstores
or buy online at www.jaypeebrothers.com

JAYPEE BROTHERS
Medical Publishers (P) Ltd.
EMCA House, 23/23-B, Ansari Road,
Daryaganj, New Delhi - 110 002, INDIA
www.jaypeebrothers.com

Join us on facebook.com/JaypeeMedicalPublishers

Shelving Recommendation
OPHTHALMOLOGY

ISBN 978-93-5465-213-4

9 789354 652134