our website www.jaypeebrothers.com, for detailed information on obstetrics & gynecology books, visit our website www.jaypeebrothers.com

Practical Guide to Ultrasound in Obstetrics and Gynecology

A comprehensive book

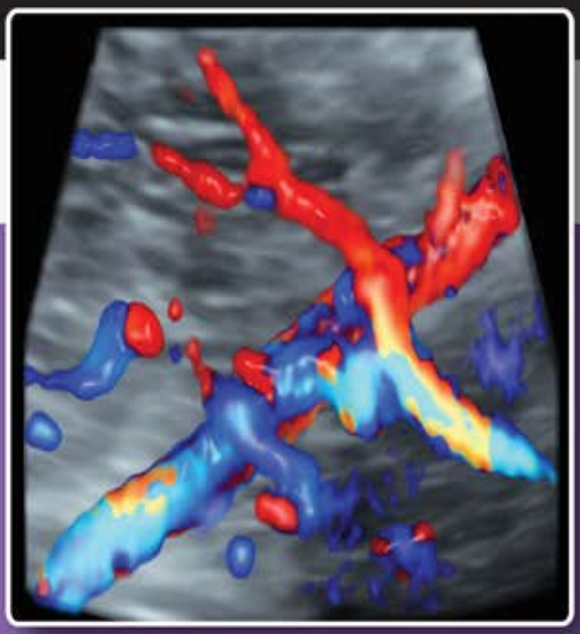

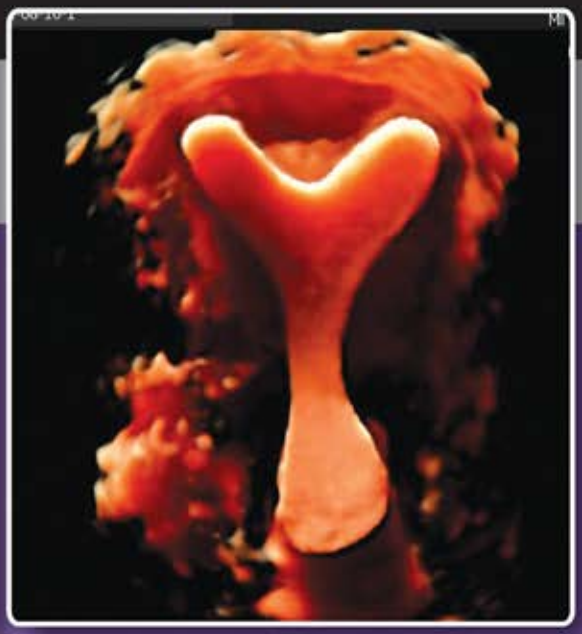

Sonal Panchal
Chaitanya Nagori

JAYPEE

Practical Guide to Ultrasound in Obstetrics and Gynecology

A Comprehensive Book

Sonal Panchal MD
Ultrasound Consultant
Dr Nagori's Institute for Infertility and IVF
Ahmedabad, Gujarat, India

Chaitanya Nagori MD DGO
Director
Dr Nagori's Institute for Infertility and IVF
Ahmedabad, Gujarat, India

JAYPEE BROTHERS



JAYPEE BROTHERS MEDICAL PUBLISHERS
The Health Sciences Publisher
New Delhi | London

Contents

1. **Basics of Ultrasound and Safety Concerns** 1
Sonal Panchal, Chaitanya Nagori
- Safety of Diagnostic Ultrasound *2*
- Norms for Safe Use of Ultrasound in 11–14 Weeks Scan (WFUMB, ISUOG, and American Institute of Ultrasound in Medicine) *3*

2. **Know the Scanner and its Controls to Optimize the Image** 5
Sonal Panchal, Chaitanya Nagori
- Equipment Settings *5*
- Optimizing the Image *5*
- Basic Understanding of Knobs and their Settings *5*

3. **Doppler Basics for a Gynecologist** 11
Sonal Panchal, Chaitanya Nagori
- What is Doppler? *11*
- Color Doppler *11*
- Power Doppler *12*
- Spectral Doppler *13*
- Color/Power Doppler Settings *14*
- Settings for Pulsed Wave Doppler *18*
- Setting the Speed of the Trace *21*
- Artifacts *22*
- Safety of Doppler *23*

4. **Ultrasound in First Trimester Pregnancy** 25
Sonal Panchal, Chaitanya Nagori
- Confirmation of Pregnancy *26*
- Location of Gestational Sac *27*
- Early Detection of Multiple Gestations *31*
- Growth and Progress of Pregnancy *32*

5. **11–14 Weeks Scan** 40
Sonal Panchal, Chaitanya Nagori
- Ultrasound as a Screening Modality *41*
- Neural Tube Anomalies *42*
- Facial Anomalies *44*
- Ocular Abnormalities *45*
- Cardiac Abnormalities *46*
- Abdominal Abnormalities *47*
- Skeletal Abnormalities *48*
- Miscellaneous Abnormalities *49*
- Chromosomal Markers *49*
- Noninvasive Prenatal Tests *62*

6. **Screening for Aneuploidy** 69
Darshan Wadekar, Zalak Mehta
- Markers of Aneuploidy *70*
- Biochemical Markers *83*
- Screening Policy for Aneuploidy *83*

7. **Second Trimester Scan** 87
Sonal Panchal
- Primary Essentials of Scanning *87*

8. **Placental Evaluation and Trophoblastic Tumors** 104
Sonal Panchal, Chaitanya Nagori
- Abnormalities of Placenta and Umbilical Cord *104*

9. **Role of Doppler in IUGR and Pregnancy-induced Hypertension** 125
Sonal Panchal, Chaitanya Nagori
- Uteroplacental Vascular Anatomy *128*
- Technique of Doppler Assessment *130*
- Silent Period of Increased Resistance *132*
- Aortic Isthmus Flow *137*
- Umbilical Artery *139*
- Middle Cerebral Artery *139*
- Ductus Venosus *139*
- Obstetric Management Depending on Doppler Findings *140*

10. **Role of Ultrasound in Medical Disorders in Pregnancy** 145
Darshan Wadekar, Zalak Mehta
- Classification *145*
- Thyroid Disease and Pregnancy *145*
- Diabetes and Pregnancy *145*
- Gestational Diabetes Mellitus *161*
- Hypertension in Pregnancy *162*
- Seizure Disorders in Pregnancy *162*
- Cardiac Disease in Pregnancy *164*
- HIV Infection *164*
- Post-test Counseling of Seropositive Women *165*
- Perinatal Infections *165*
- Sickle Cell Disease *165*
- Beta-thalassemia Disease *166*
- Management During Pregnancy *166*

JAYPEE BROTHERS

- Genetic Evaluation *166*
- Systemic Lupus Erythematosus *166*

11. Fetal Thoracic Abnormalities 171
Khurshid Alam, Rafat Jamal
- Anatomy of Thoracic Cage *171*
- Bronchopulmonary Sequestration *174*
- Congenital Pulmonary Airway Malformation *177*
- Congenital Diaphragmatic Hernia *184*
- Bronchogenic Cyst *192*
- Bronchial Atresia *194*
- Congenital High Airway Obstruction *195*
- Pleural Effusion *197*
- Pulmonary Hypoplasia *200*

12. Abnormalities of Cardiovascular System 206
Binodini M Chauhan
- Embryology of the Human Heart *206*
- Timings *208*
- Technical Factors *208*
- Cardiac Examination *212*
- Specific Cardiac Abnormalities *220*
- Cardiac Examination in 1st Trimester *237*
- Indications for Early Fetal Echocardiography *237*
- Benefits and Disadvantages of Early Fetal Echocardiography *240*

13. Fetal Urinary Tract Anomalies 242
KV Sridevi, Binodini M Chauhan
- Ultrasound Imaging of Fetal Urinary Tract *242*
- Renal Agenesis *245*
- Ectopic Kidney *248*
- Urinary Tract Dilatation *249*
- Fetal Pelviureteric Junction Obstruction *252*
- Ureterovesical Junction Obstruction *252*
- Urethral Obstruction *254*
- Cystic Renal Disease *256*
- Autosomal Recessive Polycystic Disease *257*
- Autosomal Dominant Polycystic Kidney Disease *259*
- Glomerulocystic Kidney Disease *260*
- Nephronophthisis *260*
- Nonvisualized Urinary Bladder *261*
- Renal Anomalies with Syndromes *262*
- Vacterl Syndrome *264*

14. Gastrointestinal Tract Abnormalities 267
Darshan Wadekar, Zalak Mehta
- Gastrointestinal Tract *267*
- Normal Embryologic Development *267*
- Normal Sonographic Appearance *267*
- Abnormalities of Gastrointestinal Tract *267*
- Gallbladder Duplication *272*

15. Skeletal Dysplasia: Abnormalities of Skeletal System 275
Binodini M Chauhan, Kairavi Desai
- Ultrasound Evaluation *275*
- Nomenclature of the Bone Defects *276*
- Cause of 2nd Trimester Short Femur: Intrauterine Growth Restriction and Small for Gestational Age *278*
- Counseling for Short Femur in Second Trimesters *279*
- Counseling for Short Femur in Third Trimester *279*
- Assessment of Long Bones *279*
- Evaluation of Hands and Feet *280*
- Terminology *280*
- Thanatophoric Dysplasia *281*
- Achondrogenesis *282*
- Campomelic Dysplasia *284*
- Osteogenesis Imperfecta *284*
- Asphyxiating Thoracic Dystrophy (Jeune's Syndrome) *286*
- Achondroplasia *287*
- Tips to Differential Diagnosis (Short Long Bones) *288*
- Diastrophic Dysplasia *288*
- Radial Ray Anomaly *289*
- Jarcho-Levin Syndrome/Spondylocostal Dysplasia *290*
- Chondroectodermal Dysplasia *291*
- Hypophosphatasia *291*
- Short Rib Polydactyly Syndrome *292*
- Reduction Defects *292*
- Proximal Femoral Focal Deficiency *292*
- Femoral Hypoplasia-Unusual Facies Syndrome *294*
- Split Hand and Split Foot Malformation (Ectrodactyly) *294*
- Abnormalities of Joints *296*
- Sacral Dysgenesis/Caudal Regression Syndrome *296*
- Skeletal Dysplasias (Shortcut to Diagnosis) *298*
- Differential Diagnosis: Abnormalities of Extremities *298*
- Differential Diagnosis of Joint Abnormalities *298*

16. Fetal Hydrops 300
KV Sridevi
- Immune Hydrops *300*
- Pathophysiology *300*

JAYPEE BROTHERS

- Isoimmunization *300*
- Management of the First Alloimmunized Pregnancy *301*
- Management of Women with Alloimmunization in Subsequent Pregnancy *305*
- Prevention of an Affected Fetus *306*
- Special Issues *306*
- Summary Points *307*
- Fetal Structural Anomalies *309*
- Fetal Therapy *313*

17. Fetal Central Nervous System Abnormalities 317
KV Sridevi
- Gestational Age *317*
- Ultrasound Transducers *317*
- Imaging Parameters *317*
- Basic Examination *317*
- Anomalies that can be Diagnosed from the Basic Examination Planes *320*
- Neural Tube Defects *329*
- Effectiveness of Ultrasound Examination of the Fetal Neural Axis *331*

18. Fetal Behavior in Normal Pregnancy and Diabetic Pregnancy 334
Asim Kurjak, Sonal Panchal
- Understanding the Normal Fetal Activity *334*
- Why do Fetuses of Diabetic Mothers have Higher Risk of Neurological Derangements? *337*
- What to Observe for? *337*
- Neurological Function in Fetus of a Diabetic Female *339*
- Cyclic Motility *340*
- Effect During Infancy and Childhood *340*
- Can Kanet Predict these Abnormalities *341*

19. Common Ultrasound-guided Invasive Diagnostic Procedures 349
Sonal Panchal, Chaitanya Nagori
- Chorionic Villus Biopsy *349*
- Amniocentesis *352*

20. Three-dimensional and Four-dimensional Ultrasound for Fetal Anomalies 356
Sonal Panchal, Chaitanya Nagori
- Tips for Volume Ultrasound for Second- and Third-Trimester Fetus *356*
- Applications for Detection of Congenital Defects in the Fetuses *357*
- Three-dimensional and Four-dimensional Fetal Echocardiography *379*
- Limitations of Three-dimensional and Four-dimensional Ultrasound *385*

21. Sonography-based Volume Computer-aided Display in Labor 387
Sonal Panchal, Chaitanya Nagori
- Process of Second-stage Labor *387*

22. Basics of Transvaginal Scan 394
Sonal Panchal, Chaitanya Nagori
- Transvaginal Scan *395*
- Transrectal Scan *404*
- Transabdominal Scan *405*

23. Normal Uterus 407
Sonal Panchal, Chaitanya Nagori
- Scanning and Orientation of Image *408*
- Orientation and Position of the Uterus *409*
- Endometrium: Points to Observe and Report *411*
- Myometrium: Points to Observe and Report *414*
- Serosa: Points to Observe and Report *414*
- Cervix: Points to Observe and Report *415*
- Measurements *417*
- Cyclical Changes *417*
- Postmenopausal Uterus *420*

24. Normal Ovaries 423
Sonal Panchal, Chaitanya Nagori
- Selection of Gonads *423*
- Development of the Ovary *423*
- Structure of the Ovary *423*
- Development of the Ovum (Oogenesis) *424*
- Development of the Follicle *424*
- Ovaries and Ultrasound *426*
- Location of Ovaries *428*
- Ovarian Vasculature *428*
- Ovarian Morphology *428*
- Ovarian Follicle Tracking *430*
- Perimenopausal Ovary *433*
- Menopause *434*

25. Uterine Müllerian Abnormalities 437
Sonal Panchal, Chaitanya Nagori
- Müllerian Duct Abnormalities *437*

26. Myometrial Pathologies of Uterus 451
Sonal Panchal, Chaitanya Nagori
- Scan Routes and Modalities *451*
- Method of Assessment of the Uterus *451*
- Measurements *453*
- Description *454*

JAYPEE BROTHERS

- Myometrial Description *455*
- Doppler Studies *460*
- Adenomyosis *462*
- On Ultrasound *468*
- On Doppler *471*
- Volume Ultrasound *471*
- Disseminated Peritoneal Leiomyomatosis *472*
- Benign Metastasizing Leiomyoma *472*

27. Endometrial Lesions and Doppler 474
Sonal Panchal, Chaitanya Nagori
- Inflammatory Lesions *475*
- Abnormal Response to Hormones *481*

28. Ovarian Pathologies and Endometriosis 492
Sonal Panchal, Chaitanya Nagori
- Ovarian Lesions *492*
- Ultrasound-based Classification of Ovarian Lesions *493*

29. Tubal Evaluation by Ultrasound 523
Sonal Panchal, Chaitanya Nagori
- Investigations for Assessment of Tubal Status *524*

30. Ultrasound Diagnosis of PCOS 542
Sonal Panchal, Chaitanya Nagori
- Incidence *542*
- Diagnosis *542*
- Pathophysiology *556*
- Controversies *567*

31. Baseline Scan 572
Sonal Panchal, Chaitanya Nagori
- Technique for Baseline Scan of Ovaries *572*

32. Monitoring of Ovulation Induction by Ultrasound 581
Sonal Panchal, Chaitanya Nagori
- B-mode Features of a Mature Follicle *582*
- Doppler Features of a Good Preovulatory Follicle *582*
- B-mode Features of Endometrium with Good Receptivity *587*
- Doppler Features of Endometrium with Good Receptivity *588*
- Endometrial Vascularity: Its Relation to Implantation Rates *589*
- Secretory Phase Assessment *591*
- Correlation of Progesterone to Ultrasound Findings *593*

33. Ultrasound-guided Procedures in Assisted Reproduction 596
Sonal Panchal, Chaitanya Nagori
- Oocyte Retrieval *596*
- Embryo Transfer *601*
- Cyst Aspirations *605*
- Aspiration of Hydrosalpinx *607*
- Aspiration of Ascitic Fluid in Ovarian Hyperstimulation Syndrome *607*
- Fetal Reduction *608*

34. Transvaginal Assessment of the Cervix 613
Sonal Panchal, Chaitanya Nagori
- Cervical Polyps *614*
- Cervical Fibroids *614*
- Nabothian Cysts *616*
- Cervical Ectopic Pregnancies *617*
- Cervical Malignancy *618*
- Cervical Assessment in Pregnancy *620*
- Technique of Transvaginal Ultrasound Method for Cervical Assessment *623*

35. Ultrasound in Urogynecology 628
Sonal Panchal, Chaitanya Nagori
- Physical Examination *628*
- Investigations *628*
- Anatomy *629*
- Bladder Volume Measurement *633*
- Bladder Wall Thickness as a Marker of Detrusor Overactivity *633*
- Bladder Tumors *634*
- Urethral Diverticula *634*
- Retropubic Hematoma *635*
- Urethral Mobility (Bladder Neck Mobility) *635*
- Cystocele *636*
- Vaginal Wall or Vault Prolapse *636*
- Rectal Intussusception *638*
- Tape Position and Outcome of Suburethral Sling *638*
- Ultrasound for Evaluation of Patients Treated with Vaginal Mesh *639*
- Correlation with Symptoms and Guide to Treatment *639*

Index *645*

JAYPEE BROTHERS

6
CHAPTER

Screening for Aneuploidy

Darshan Wadekar, Zalak Mehta

INTRODUCTION

Screening is a process of surveying a population with specific markers in order to identify those individuals with a higher risk for a particular disorder. For high-risk individuals, a diagnostic test is applied to diagnose the disorder. A successful screening program should be complemented with an accurate diagnostic test to identify those who are truly affected and also with a clear strategy of how to treat the affected individuals.

Every fetus has a chance of having a chromosomal or genetic condition. 20% of all the pregnancies are affected by a chromosomal or genetic condition. But, most of them are not viable and hence they do not lead to a live birth. Only some of them (most common Trisomy 21, 13, and 18) can at times lead to live birth. These aneuploidies are caused by errors during the meiotic cellular division. Down's syndrome (Trisomy 21), most common aneuploidy, leads to mental restriction and functional disability. In Trisomy 13 and 18, fetuses have developmental defects in cardiac and central nervous system defects.[1]

Screening for fetal aneuploidy in pregnancy began in the 1960–1970s with maternal age as the only available marker. As maternal age increases, the chance of delivering a child with Down syndrome (DS) or other major autosomal trisomies such as trisomy 18 (T18; Edwards syndrome) or 13 (T13; Patau syndrome) increases. However, screening with maternal age alone (cut-off >35 years) could detect about 30% of trisomies. But, majority of the babies with DS are born by women <35 years of age.

The first breakthrough in screening for fetal chromosomal abnormalities ocurred in 1988 with the introduction of a multiple marker screening test, based on a "risk" calculation for each pregnant woman using her age and the concentrations of three biochemical markers—human chorionic gonadotropin (hCG), αFP (alpha-fetoprotein), and unconjugated estriol (uE3), commonly known as triple marker test from blood samples in the 2nd trimester of pregnancy.

In 1992, fetal nuchal translucency (NT), by far the single best individual marker, was introduced with the improvement of ultrasound machine and knowledge about first trimester in pregnancy by Professor Kipros Nicolaides. In 1997, a new multiple marker screening test commonly knowns as combined test, using NT, free β-hCG, and pregnancy-associated plasma protein-A (PAPP-A) was started.

Since 2010, cell-free fetal DNA (cffDNA) in maternal plasma, in combination with the next generation sequencing techniques, made a big breakthrough step in screening for Down syndrome and other aneuploidies.

Diagnosis of major fetal chromosomal aneuploidies is done by karyotype of fetal cells, obtained through amniocentesis after the 15th week of pregnancy, or chorionic villus sampling (CVS) between the 12th and 14th weeks.

There are various parameters, which act as markers of aneuploidy in a pregnancy, which includes maternal markers, ultrasound markers, and biochemical markers. The details of each are described below.

JAYPEE BROTHERS

MARKERS OF ANEUPLOIDY (TABLE 1)

Maternal Risk Factors

- *Maternal age*: The maternal age is directly proportional to the risk of aneuploidy. The real reason for such relationship could lie in the fact that in advanced maternal age group women, the residual follicles rupture lead to the increased risk in aneuploidy. Although the risk of trisomy 13, 18, and 21 rises with maternal age, the risk of Turner syndrome is independent of the maternal age.
- *Gestational age*: The in utero (fetal) death rate of aneuploidic fetuses is 30% in case of trisomy 21 and 80% in case of trisomy 13 and trisomy 18. Hence, the risk of aneuploidy decreases with the increasing gestational age **(Fig. 1)**.
- *Maternal comorbidities and body mass index*: The risk of aneuploidy increases with maternal comorbidities such as diabetes, hypertension, and increased maternal weight.
- *Previous history of aneuploidy fetus*: Risk of aneuploidy increases in a female having previous history of aneuploid fetus.

Ultrasound Markers

In today's scenario, ultrasound is the most important investigation during pregnancy. It not only gives maximum information about the fetus, placenta, and pregnancy as a whole, it is also majorly harmless to the fetus. Hence, we perform three major ultrasounds during pregnancy:

- First-trimester scan (genetic/nuchal translucency scan)

TABLE 1: Markers of aneuploidy.

Maternal risk factors	• Maternal age • Maternal comorbidities • Maternal height and weight • Previous history of aneuploidy fetus
Maternal serum markers	*Screening in the first trimester*: • Serum-free β-hCG and PAPP-A • Serum PLGF • Serum αFP *Screening in the second trimester:* Total or free β-hCG, αFP, uE3, and inhibin A
Ultrasound markers	• Nuchal translucency • Nasal bone • Fetal heart rate • Tricuspid flow • Ductus venosus • Other sonographic soft markers of aneuploidy

(αFP: α-fetoprotein; β-hCG: β-human chorionic gonadotropin; PAPP-A: pregnancy-associated plasma protein-A; PLGF: placental growth factor; uE3: estriol)

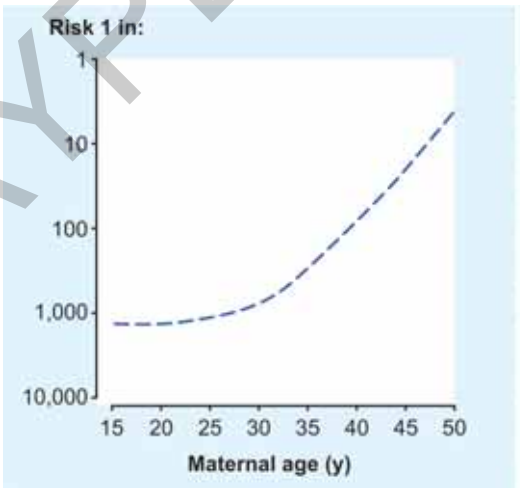

Age (y)	Gestational age		
	12 w	20 w	40 w
20	1100	1300	1500
25	1000	1100	1400
30	650	750	900
31	550	650	800
32	450	550	650
33	400	450	550
34	300	400	450
35	250	300	350
36	200	250	300
37	150	185	220
38	120	140	160
39	90	110	130
40	70	80	100

Fig. 1: Maternal age versus the risk of aneuploidy.

JAYPEE BROTHERS

- Second-trimester scan (anomaly scan)
- Third-trimester scan (growth scan)

They help us to identify structural abnormalities (which will affect the fetus in the life ahead) and nonstructural abnormalities/soft markers (which will not affect the fetus structurally), both of which are markers of aneuploidy.

Soft markers are frequently seen in normal fetuses, often transient and insignificant in regard to outcome; however, their presence points us to look for other anomalies or genetic disorders.

Following are the soft markers of aneuploidy.

Nuchal Translucency

Nuchal translucency is a fluid-filled subcutaneous space at the back of the neck of the fetus **(Fig. 2B)**. It may or may not be septated. However, the size rather than its appearance is of importance.

In the 1990s, it was realized that the excess skin of individuals with Down's syndrome can be visualized by ultrasonography as increased nuchal translucency in the 3rd month of intrauterine life.

Fetal Medicine Foundation (FMF) criteria for nuchal translucency measurement (as points) **(Table 2)**:

The NT is to be measured between 11 and 13 + 6 weeks, i.e., crown–rump length (CRL) of 45–84 mm **(Fig. 2A)**.

TABLE 2: Fetal Medicine Foundation (FMF) criteria for measurement of nuchal translucency.

Timing gestational age	11–13+6 weeks
Crown-rump length	45–84 mm
Magnification	Face thorax occupies the entire screen
Midsagittal view	A midsagittal view of fetus is taken: • Tip of nose and nasal bone should be visible • Diencephalon should be visible • Palate is also visible • However maxilla should not be present
Fetal neck position	Neutral
Caliper placement	Inner border of horizontal line of the caliper should be placed on the line that defines NT
Gain	Optimize gain

- CRL of 45–84 mm
- *Midsagittal view*: A midsagittal view of fetus is taken **(Fig. 2C)**:
  - Tip of nose and nasal bone should be visible.
  - Diencephalon should be visible.
  - Palate is also visible.
  - However, maxilla should not be present.
- *Zoom*: Appropriate zooming so that only head and upper thorax are visible.

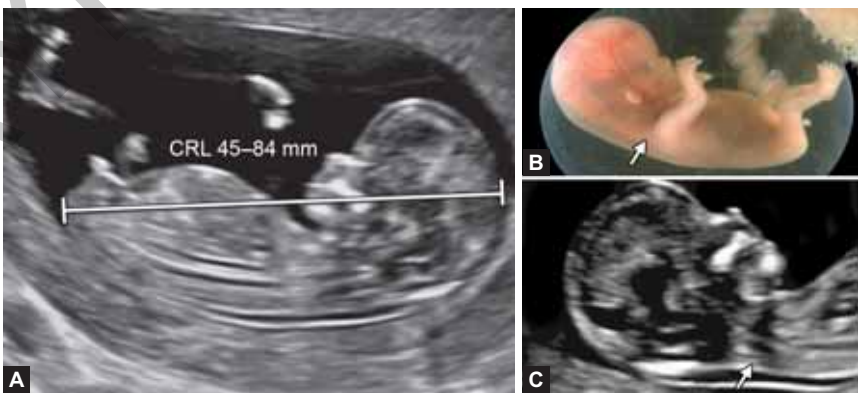

Figs. 2A to C: (A) Measuring correct CRL; (B) Image of the embryo showing nuchal translucency; (C) Nuchal translucency shown on ultrasound image.

JAYPEE BROTHERS

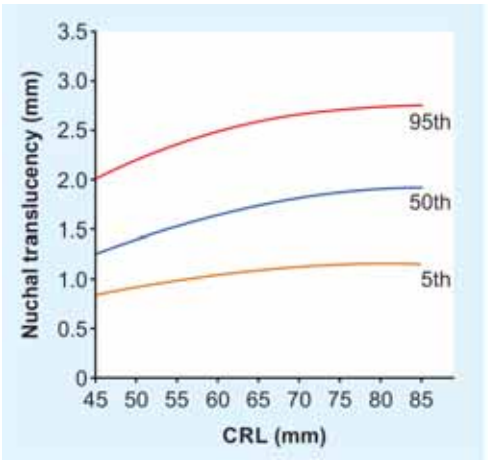

CRL	Median	95th percentile	99th percentile
45 mm	1.2	2.1	3.5
84 mm	1.9	2.7	3.5

Fig. 3: Nuchal translucency versus crown–rump length (CRL).

- *Neutral position*: Fetus should neither be extended (falsely increases NT) nor flexed (falsely decreased NT). The idea is to have a small pocket of liquor between the neck and chin for a neutral position.
- *Caliper placement*: The caliper placement is such that inner borders of calipers are put on echogenic line.
- *Maximum measurement*: The NT is measured in the widest part usually behind the mandible or maxilla.
- *In case of cord around neck*: If there is an amniotic cord around the neck, then NT is measured above and below the cord and the average is taken.

The NT increases as the CRL increases **(Fig. 3)**.

In 75–80% of trisomy 21 fetus, the NT is above the 95 percentile for the given CRL. As gestational age advances, most of the times, increased nuchal translucency may decrease. However, in few cases, they may advance to nuchal thickness or cystic hygroma.

Causes of increased NT: The most common causes of increased nuchal translucency are trisomy 21, trisomy 18, trisomy 13, Turner syndrome, and cardiac abnormalities **(Fig. 4)**.

There are multiple other single gene disorders or syndromes in which nuchal translucency can increase. Hence, in these

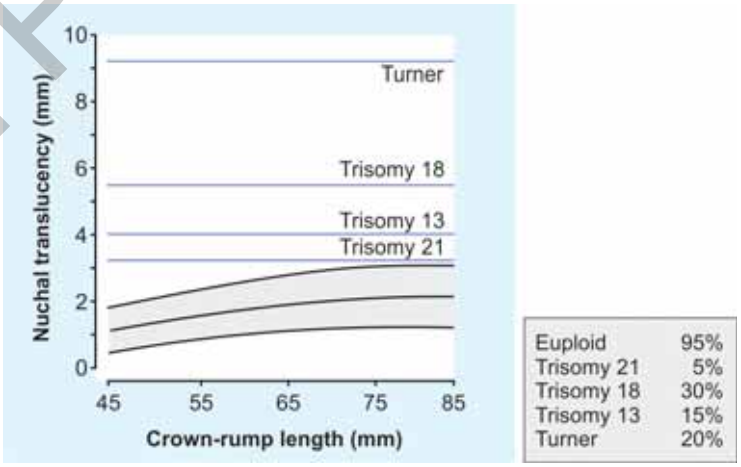

Fig. 4: Nuchal translucency nomogram against CRL, showing normal and abnormal values.

JAYPEE BROTHERS

days along with karyotype, microarray is also recommended.

In cases of isolated increased nuchal translucency and normal karyotype, more than 90% of the fetuses are normal. When additional association with any other markers or congenital anomaly is present, the outcome may not be normal.

Although increased NT thickness is associated with abnormalities and fetal death, the majority of babies survives and develops normally.

After the diagnosis of increased NT, the aim must be to distinguish as accurately and quickly as possible between those that are likely to have problems from those where the baby is likely to be normal.

Tips to measure nuchal translucency:

- *First master profile in anomaly scan:* Fetus in first trimester moves much faster than in second. Hence, your probe movement needs to be swift.
- If you get correct crown rump length image, it is the same image zoomed for NT.
- Try keeping nasal bone horizontal and you will get clear nuchal translucency.
- Keep the probe pressure least so that the fetus can move.
- Best time to get NT is after the fetal jump.

Nasal Bone (Fig. 5)

It was in 1866, that absent or hypoplastic nasal bone was noted as a common characteristic of Down's syndrome. There is defective ossification in Down's syndrome fetuses. However, the nasal bone ossification is maternal race dependent. More than 50% of euploid Asians have unossified nasal bone. In the midsagittal section (nuchal translucency image), nasal bone should be visualized. The three echogenic lines represent tip of nose, skin, and nasal bone.

Nasal bone is unossified or hypoplastic in 60–70% of trisomy 21 fetuses, 50% of trisomy 18 fetuses, and 30% of trisomy 13 fetuses.

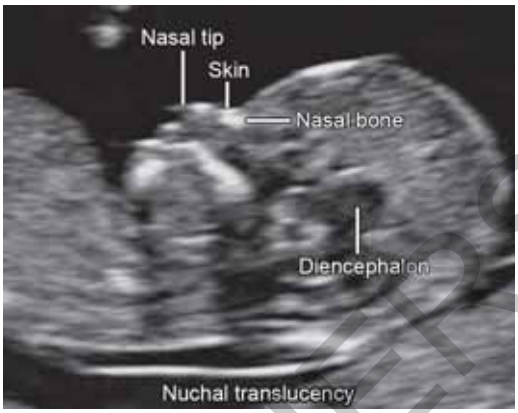

Fig. 5: Midsagittal plane of head and neck.

The length of nasal bone is more important in second trimester. Less than 2.5 mm at 15–21 weeks of gestation is considered hypoplastic.

Tips to measure nasal bone:

- Nasal bone should be kept horizontal to the probe
- Maxilla to be avoided
- Turning the probe 90° from premaxillary triangle image
- Good CRL or NT image should show nasal bone.

Ductus Venosus

Ductus venosus is a small vessel connecting the umbilical vein with the inferior vena cava (IVC).

Its main function is to provide the oxygenated blood to brain.

It shunts oxygenated blood to brain from umbilical vein (IVC to right atrium to left atrium via foramen ovale. From here, blood flows through right ventricle and aorta to fetal organs.)

After birth, when fetal lungs begin to function, there is closure of ductus venosus within few minutes after birth. However, it may be delayed in preterm neonates.

Criteria:

- *Fetus quiescent*: The fetus should not be moving.
- *Midsagittal plane*: Ductus venosus Doppler is performed in midsagittal plane (same as NT an CRL)

JAYPEE BROTHERS

- *Zoom*: Only the thorax and abdomen should cover the whole of screen.
- *Doppler gate*: 0.5–1 mm, larger gate will cause contamination of waves with hepatic vein.
- Angle of insonation—should be <30.
- *Filter*—should be set at low (50–70 Hz), so as to view the whole waveform.
- *Sweep speed*—should be high for better assessment of the a-wave.

The high-velocity S wave is due to ventricular systole and D wave is due to diastole. The forward A wave is due to atrial contraction.

A positive or absent A wave is normal **(Figs. 6A to C)** while reversal of A wave is abnormal **(Figs. 7A and B)**. It is associated with cardiac abnormalities, chromosomal abnormalities, and fetal death.

Tips for measuring ductus venosus:

- Apart from fetal quiescence, ask mother to hold breath.
- On best CRL image place the color box, and apply pulse wave Doppler on the brightest color just below the fetal heart.

Fetal Heart Rate

Fetal heart rate is measured in transverse section of heart.

The normal heart rate is 110 beats/min at 5 weeks and increases to 170 beats/min at 10 weeks and then gradually decreases to 140 beats/min at 14 weeks.

There is an association of fetal heart rate and trisomy 21, 18, and 13.

In trisomy 21 and 13, fetal heart rate increases, whereas in trisomy 18, fetal heart rate decreases **(Table 3 and Fig. 8)**.

This is very important in trisomy 18 and 13 because this is the only feature to differentiate them, as both have increased NT and decreased serum β-hCG and PAPP-A levels in maternal serum.

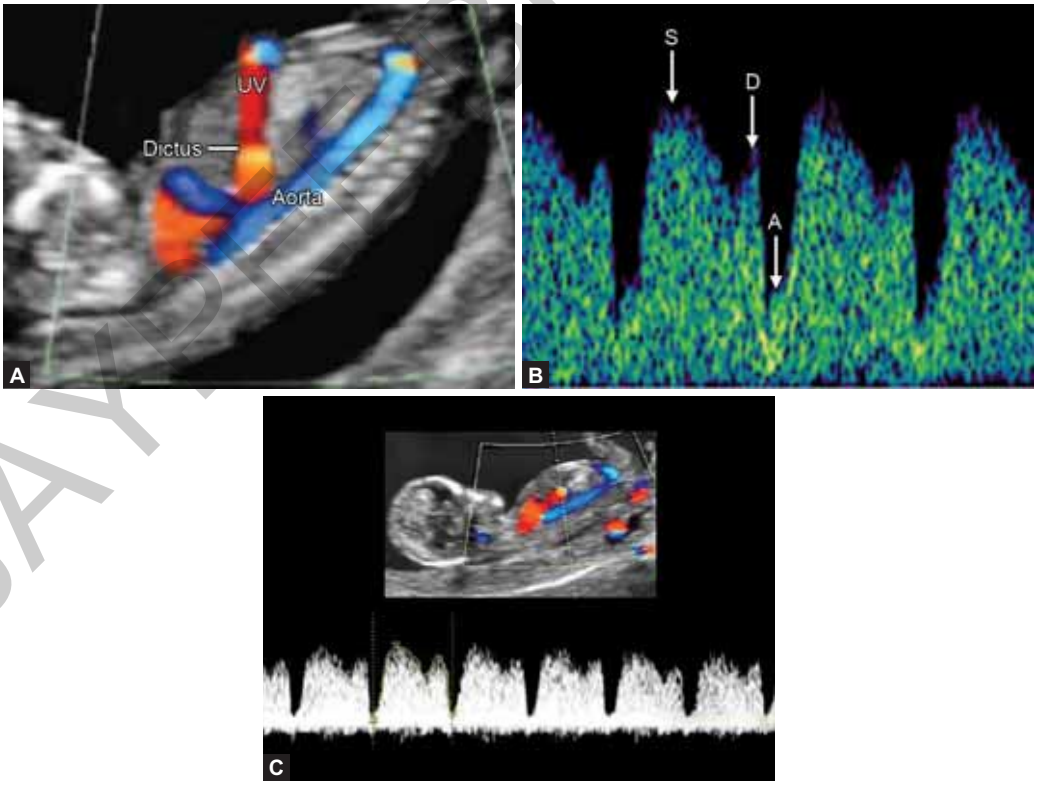

Figs. 6A to C: Normal ductus venosus flow on spectral Doppler.

JAYPEE BROTHERS

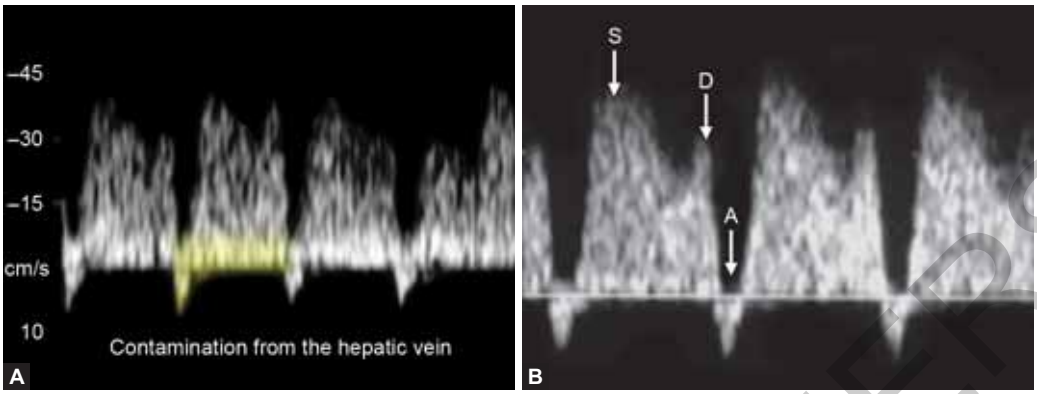

Figs. 7A and B: (A) Ductus venosus flow on spectral Doppler with contamination from the hepatic vein; (B) Abnormal ductus venosus flow on spectral Doppler with reverse A wave.

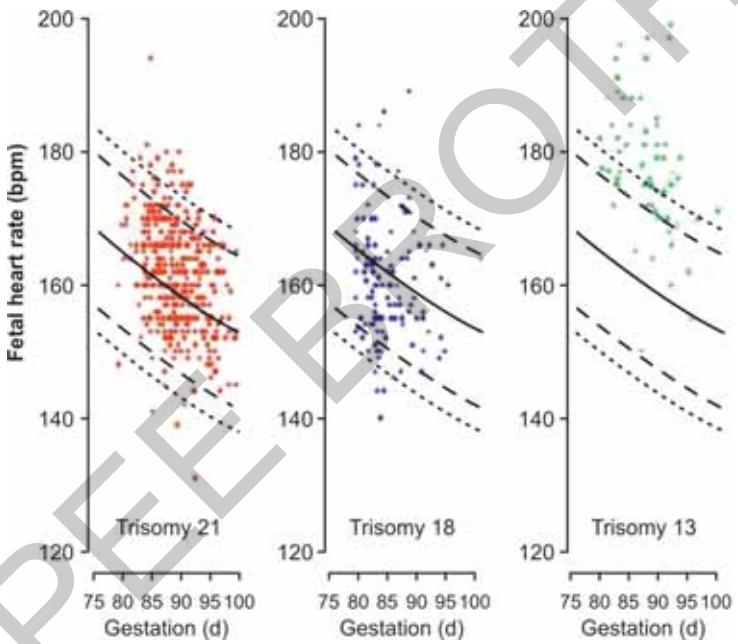

Fig. 8: Distribution of fetal heart rate in different trisomies at different CRL.

TABLE 3: Fetal heart rate variation in trisomy 18, 21, and 13.

Trisomy 21	FHR increased and is above the 95th centile	In 15% of cases
Trisomy 18	FHR is mildly decreased and is below the 5th centile	In 15% of cases
Trisomy 13	FHR increased and is above the 95th centile	In 85% of cases

(FHR: fetal heart rate)

Fetal Tricuspid Flow

Tricuspid valve is located in the right of fetal heart between the atria and ventricle. It is more apical than mitral normally.

FMF criteria:

- The gestation should be 11^{+0} to 13^{+6} weeks and the CRL should be 45–84 mm.
- The fetus should not be moving.
- The magnification of the image should be such that the fetal thorax occupies the whole screen.

JAYPEE BROTHERS

- An apical four-chamber view of the fetal heart should be obtained.
- Color flow mapping should not be used, because it is unreliable for the diagnosis of tricuspid regurgitation in the first trimester.
- The pulsed Doppler sample should be large (2–3 mm) and positioned across the tricuspid valve.
- The insonation angle to the direction of flow should be <30° from the direction of the interventricular septum.
- The tricuspid valve could be insufficient in one or more of its three cusps, and therefore the sample volume should be placed across the valve at least three times, in an attempt to interrogate the complete valve.
- The sweep speed should be high (2–3 cm/s) so that the waveforms are widely spread for better assessment.

Tricuspid regurgitation (TR) is diagnosed when there is reversal of flow with the velocity more than 60 cm/s. However, sometimes, the aortic and pulmonary arterial blood flow may intervene; however, their maximum velocity is not more than 50 cm/s.

Tricuspid regurgitation is seen in fetus with trisomy 21, 18, and 13 and fetal cardiac defects **(Figs. 9A to C)**.

There are other markers like facial angle, which are not much used for screening now.[2]

Second Trimester Soft Markers

The most common soft markers for fetal anomalies (SMFAs) in second trimester are nuchal thickening, hyperechoic bowel, shortened extremities, renal pyelectasis, echogenic intracardiac foci, choroid plexus cyst, strawberry-shaped skull, small, low-set ears, clubfoot, single umbilical artery,

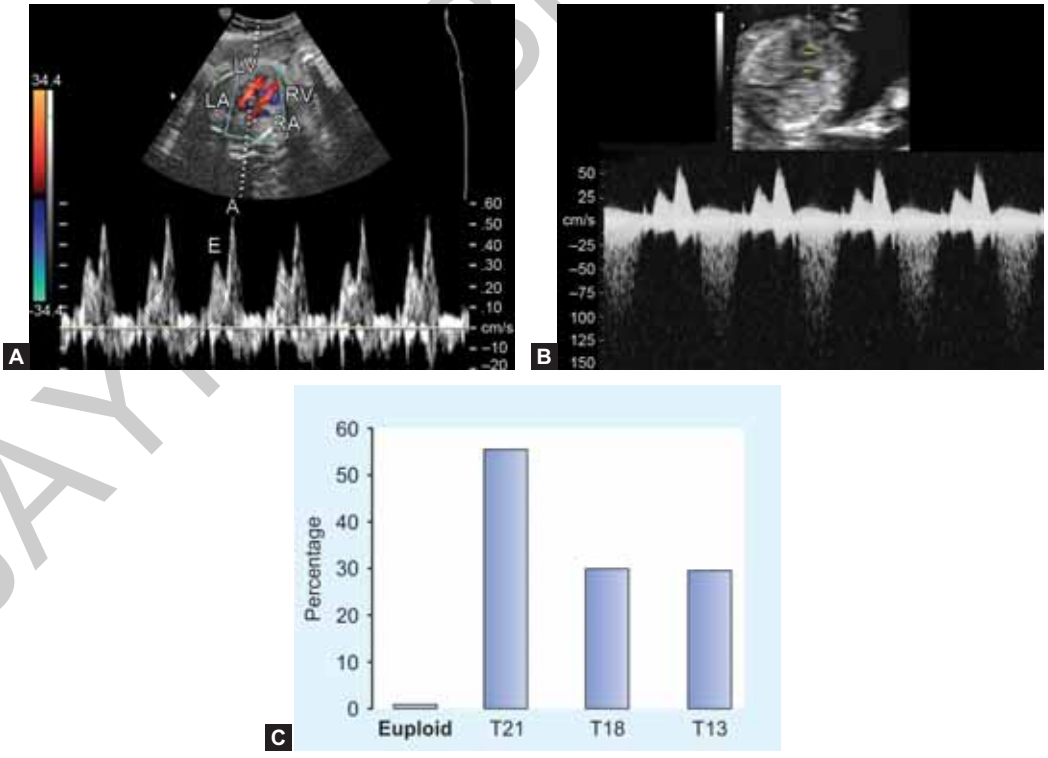

Figs. 9A to C: (A) Normal tricuspid flow with contamination from aorta on spectral Doppler; (B) Tricuspid regurge on spectral Doppler; (C) Incidence of tricustod regurge in normal and aneuploid fetuses.

JAYPEE BROTHERS

TABLE 4: Pooled estimates of detection rate (DR), false positive rate (FPR) and positive and negative likelihood ratios (LR+ and LR-) of sonographic markers for trisomy 21 and estimated likelihood ratio (LR) of individual isolated markers.

Marker	*DR (95% CI) (%)*	*FPR (95% CI) (%)*	*LR+ (95% CI)*	*LR– (95% CI)*	*LR isolated marker**
Intracardiac echogenic focus	24.4 (20.9–28.2)	3.9 (3.4–4.5)	5.83 (5.02–6.77)	0.80 (0.75–0.86)	0.95
Ventriculomegaly	7.5 (4.2–12.9)	0.2 (0.1–0.4)	27.52 (13.61–55.68)	0.94 (0.91–0.98)	3.81
Increased nuchal fold	26.0 (20.3–32.9)	1.0 (0.5–1.9)	23.30 (14.35–37.83)	0.80 (0.74–0.85)	3.79
Echogenic bowel	16.7 (13.4–20.7)	1.1 (0.8–1.5)	11.44 (9.05–14.47)	0.90 (0.86–0.94)	1.65
Mild hydronephrosis	13.9 (11.2–17.2)	1.7 (1.4–2.0)	7.63 (6.11–9.51)	0.92 (0.89–0.96)	1.08
Short humerus	30.3 (17.1–47.9)	4.6 (2.8–7.4)	4.81 (3.49–6.62)	0.74 (0.63–0.88)	0.78
Short femur	27.7 (19.3–38.1)	6.4 (4.7–8.8)	3.72 (2.79–4.97)	0.80 (0.73–0.88)	0.61
ARSA	30.7 (17.8–47.4)	1.5 (1.0–2.1)	21.48 (11.48–40.19)	0.71 (0.57–0.88)	3.94
Absent or hypoplastic NB	59.8 (48.9–69.9)	2.8 (1.9–4.0)	23.27 (14.23–38.06)	0.46 (0.36–0.58)	6.58

*Derived by multiplying the positive LR for the given marker by the negative LR of each of all other markers, except for short humerus
(ARSA: aberrant right subclavian artery; NB: nasal bone)

clenched hands, omphalocele, and polydactyly **(Table 4)**.

In a meta-analysis of second trimester ultrasound markers for trisomy 21, Professor Nicolaides suggested that the combined negative LR of all markers, including short femur but not short humerus, was 0.13, implying that if a systematic ultrasound examination is carried out and all markers are excluded, there is a 7.7-fold reduction in risk.[3]

The most common and most important markers for aneuploidy include absent/unossified nasal bone, aberrant right subclavian artery, and increased nuchal fold thickness.

Soft Markers and their Implication (Table 5)

Absent/Unossified or Hypoplastic Nasal Bone

Absent of hypoplastic nasal bone is defined as one that is not visible in first trimester or with a length of <2.5 mm in the midsagittal section of the fetal profile in second trimester. The absence of a fetal nasal bone warrants a detailed evaluation of fetal anatomy. If there are no other anomalies and normal karyotype, it is reasonable to reassure that the likelihood of a good neonatal outcome is high. However, case reports have described an absent fetal nasal bone in B-cell immunodeficiency, cri-du-chat (5p–) syndrome, and partial trisomy 20q. Considering these cases, microarray studies could be performed in addition to a fetal karyotype when an absent fetal nasal bone occurs with additional sonographic anomalies.[16]

Aberrant Right Subclavian Artery

In aberrant right subclavian artery (ARSA), the usual pattern of development is slightly changed, preventing the typical formation of the three blood vessels. This leads to there being four branches rather than the normal three arising from the left aortic arch, one being the ARSA. It is present in 0.4% of the

JAYPEE BROTHERS

TABLE 5: Proposal of a simple clinical summary for management of specific soft markers in pregnancies.

Marker	*Incidence (%)*	*Conditions*	*Considerations and follow-up*
Ventriculomegaly	3.0–15	• Aneuploidy • Genetic syndrome • Primary brain abnormalities • Congenital infection (CMV and toxoplasma) • Cerebrovascular accidents • Intracranial hemorrhage	• TORCH screening • Follow up scans to look for progression • Consider brain magnetic resonance imaging, if moderate-to-severe ventriculomegaly for detection of additional brain abnormalities
Choroid plexus cyst	2–4	Aneuploidy	Detail evaluation for other markers of aneuploidy
Absent or hypoplastic nasal bone	0.5–2.8	• Aneuploidy (especially trisomy 21) • B-cell immunodeficiency • Cri-du-chat syndrome • Partial trisomy 20q	• Detailed evaluation of fetal anatomy • Consider microarray studies (if with additional sonographic anomalies)
Thickened nuchal fold	0.4–0.6	• Down syndrome • Congenital heart disease	Evaluation of fetal heart, consider fetal echocardiography
Intracardiac echogenic focus	3–4	Down syndrome	• Detail evaluation for other markers of aneuploidy • More attention in multiple and right ventricle involved
Echogenic bowel	0.2–1.8	• Aneuploidy • Intrauterine growth restriction • Intrauterine fetal demise • Cystic fibrosis • Congenital infection (especially CMV) • Gastrointestinal anomaly	• Evaluation for cystic fibrosis • TORCH screening • 32-week ultrasound to assess for bowel dilatation or obstruction
Shortened humerus and femur length	0.4–3.9	• Aneuploidy • Structural abnormalities • Skeletal dysplasia • Preeclampsia • Preterm delivery • Oligohydramnios • Intrauterine growth restriction • Intrauterine fetal demise	• 32-week ultrasound to assess growth and to rule out certain skeletal dysplasia • Frequent blood pressure measurement • Study umbilical and uterine artery Doppler flow • Surveillance in timing of delivery
Pyelectasis	0.1–2.4	• UPJ obstruction • Vesicoureteral reflux • Posterior urethral valves • Ureteral obstruction • Other renal anomalies	• 32-week ultrasound to assess kidneys • Follow-up scans to look for progression • Postnatal follow-up, if >7 mm
Single umbilical artery	0.5–5	• Controversial aneuploidy • SGA • Preterm birth • Increased cesarean section rate	• Undergo targeted anatomical survey (level II ultrasound) • Controversial ultrasound to assess growth

(CMV: cytomegalovirus; TORCH: toxoplasmosis, rubella, cytomegalovirus, and herpes simplex; UPJ: ureteropelvic junction; SGA: small for gestational age)

JAYPEE BROTHERS

for detailed information on obstetrics & gynecology books, visit our website www.jaypeebrothers.com, for detailed information on obstetrics &

Practical Guide to Ultrasound in Obstetrics and Gynecology

A comprehensive book

This book is one more addition in the popular series of *Practical Guide to Ultrasound in Obstetrics and Gynecology—A Comprehensive Book* by the authors and editors Chaitanya Nagori and Sonal Panchal. They are known for their 'to-the-point' writing and crystal clear explanations. This is a comprehensive book that discusses very topic of obstetrics and gynecology related ultrasound 'to-the-point' and with practical approach. It very precisely describes the scanning methods making these easy to understand and master. Differential diagnosis for the ultrasound findings are discussed with practical point of view, mentioning the most common pathologies and abnormalities in the top of the list and also describes simple points to differentiate these conditions. It is a 'must have, quick reference book' for practicing obstetricians and gynecologists and also for radiologists trying to indulge in obstetric and gynecological ultrasound.

Sonal Panchal MD is an Ultrasound Consultant at Dr Nagori's Institute for Infertility and IVF, Ahmedabad, Gujarat, India. She is a versatile ultrasound specialist dedicated to the subject for more than 23 years. She has a high repute for her excellent scanning and teaching skills. She has a deep insight into gynecological and infertility-related ultrasound. She has been one of the pioneers for the use of Doppler and 3D-4D ultrasound for infertility assessment and has several original papers and publications on the same. She is a popular and passionate teacher in the field and is awarded a 'Professor' Dubrovnik International University, Croatia.

Chaitanya Nagori MD DGO is Director at Dr Nagori's Institute for Infertility and IVF, Ahmedabad, Gujarat, India. He is a successful infertility consultant for more than 30 years and is known for a very high success rate in his practice. He has a thorough knowledge of infertility and gynecologic endocrinology. He is a core academician and a teacher of teachers. He is a synonym for to-the-point teaching, with crisp and clear concepts. He is a contributor and author of several books and had several research publications.

Printed in India

Available at all medical bookstores or buy online at www.jaypeebrothers.com



JAYPEE BROTHERS
Medical Publishers (P) Ltd.
EMCA House, 23/23-B, Ansari Road,
Daryaganj, New Delhi - 110 002, INDIA
www.jaypeebrothers.com

Join us on facebook.com/JaypeeMedicalPublishers

Shelving Recommendation
OBSTETRICS & GYNECOLOGY

