formation on radiology books, visit our website www.jaypeebrothers.com, for detailed information on radiology books, visit our website www.jaypeebrothers.com

PEDIATRIC CARDIAC RADIOLOGY

PLAIN RADIOGRAPHIC INTERPRETATION IN CONGENITAL AND STRUCTURAL HEART DISEASES

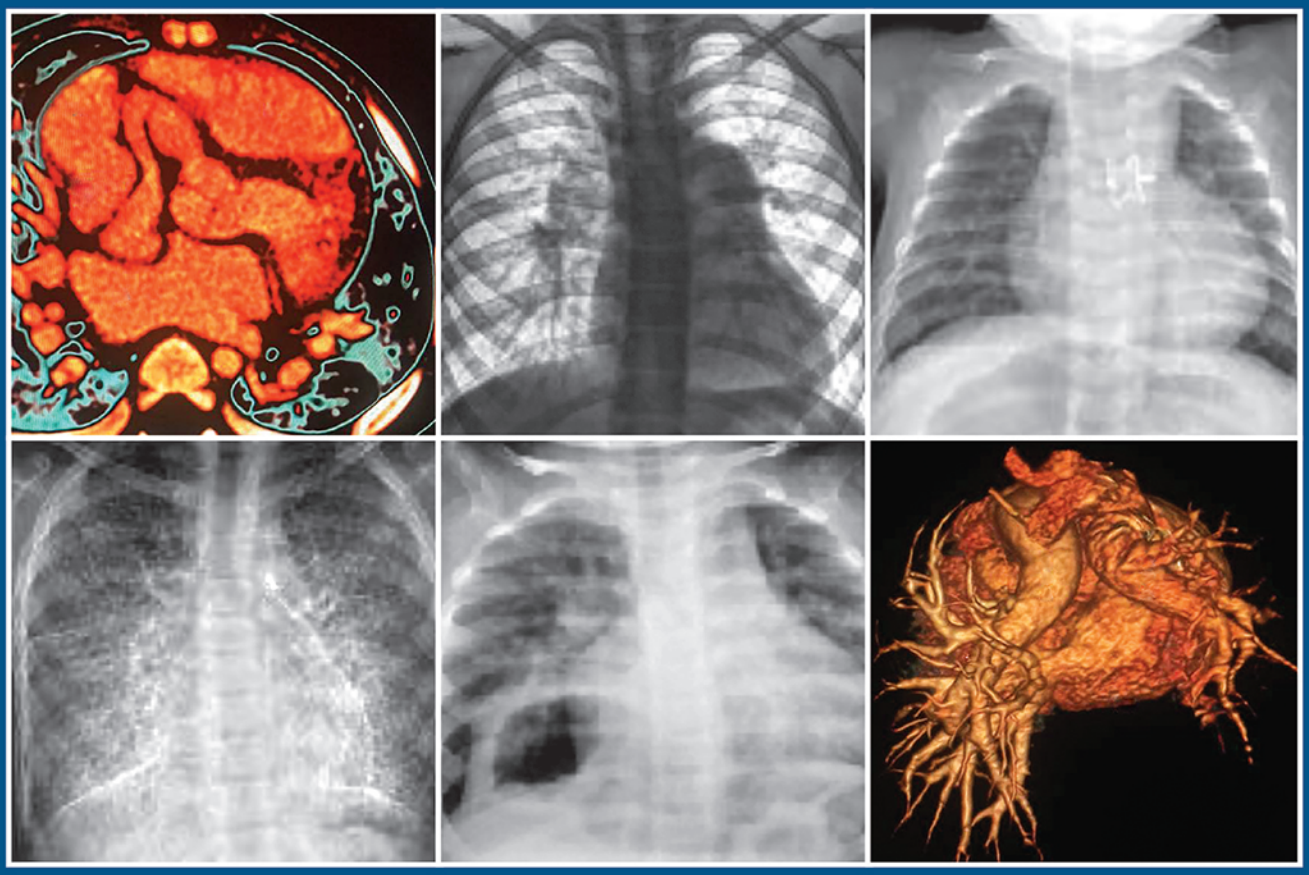

Authors
Sudeep Verma
Neeraj Awasthy

JAYPEE

Contents

SECTION 1: Introduction, Technical Aspects and Approach

1. Technical Aspects of Chest Radiography in Pediatric Cardiac Patients 3
2. Radiographic Views 23
3. Systematic Assessment of Radiographic Film: Step-by-Step Approach 40
4. Classification and Radiographic Approach for Recognition of Congenital Heart Disease 49

SECTION 2: General Assessment

5. Radiographic Assessment of Thymus 61
6. Radiographic Assessment of Diaphragm 73
7. Assessment of Pulmonary Vascularity on Radiograph 97
8. Radiographic Evaluation of Pericardium on Chest Radiograph 141
9. Radiographic Assessment of Airways 158
10. Evaluation of Soft Tissue on Radiograph 187
11. Skeletal Survey in Cardiology 196
12. Cardiac Silhouette Assessment 242
13. Radiographic Assessment of Cardiac Size 269
14. Radiographic Assessment of Cardiac Chambers 295

SECTION 3: Congenital Heart Disease Evaluation

15. Radiographic Evaluation of Situs and its Abnormalities 329
16. Acyanotic Shunt Lesions 347
    - A. Atrial Septal Defect 347
    - B. Ventricular Septal Defect 363
    - C. Patent Ductus Arteriosus 376
17. Cyanotic CHD with VSD-PS Substrate (Tetralogy of Fallot Physiology) 389
    - A. Approach for Radiographic Evaluation of TOF and its Variants 389
    - B. Classical Tetralogy of Fallot and VSD-Pulmonary Atresia 398
    - C. Tetralogy of Fallot with Absent Pulmonary Valve Syndrome 422
    - D. Differential Diagnosis of TOF Substrate and Cardiomegaly 434

18. Cyanotic CHD with Increased Pulmonary Blood Flow (Admixture Lesions) 441
A. Transposition of Great Arteries 441
B. Total Anomalous Pulmonary Venous Connection 452
C. Truncus Arteriosus 467
19. Ebstein, Scimitar and Congenitally Corrected Transposition of Great Arteries 476
A. Ebstein's Anomaly and Related Disorders 476
B. Scimitar Syndrome (Congenital Venolobar Syndrome) and Variants 488
C. Congenitally Corrected Transposition of Great Arteries 505
20. Obstructive Lesions 519
A. Pulmonary Stenosis 519
B. Aortic Stenosis 531
C. Coarctation of Aorta 541
21. Pulmonary Arteriovenous Malformations and Related Lesions 553

SECTION 4: Differential Diagnosis

22. Pulmonary Artery Assessment and Differential of Pulmonary Artery Enlargement 571
23. Assessment of Aorta, Arch Sidedness and Differential Diagnosis of Aortic Enlargement 581
24. Radiological Evaluation of Left Heart Border on Frontal Film 602
25. Radiological Evaluation of Right Heart Border on Frontal Film 618
26. Evaluation of Cardiac Mass on Right Side (Dextrocardia) 635
27. Radiological Evaluation of Unusual Presence of Heart in Left Hemithorax 651
28. Differential Diagnosis for Wall-to-Wall Heart (Massive Cardiomegaly) 657
29. Differential Diagnosis of Rib Notching 667

SECTION 5: ICU and Postoperative Surgical Radiology

30. Radiological Evaluation of Cardiopulmonary Issues in Cardiac Intensive Care Unit 679
31. Radiographic Assessment of Catheters and Tubes in Cardiac Intensive Care Unit 710
32. Radiographic Assessment of Extracorporeal Membrane Oxygenation and Other Mechanical Support Devices 764
33. Radiographic Evaluation of Air Leak Syndromes and Air Trapping 784
34. Radiological Course for Operated (Surgical/Percutaneous/Hybrid) Cardiac Lesions 816

SECTION 6: Prosthesis Assessment on Radiograph (Percutaneous and Surgical)

35. A. Radiographic Evaluation of Occluders/Devices on Plain Radiograph 863
B. Radiographic Evaluation of Stents on Plain Radiograph 909
36. Pacemaker and Conduction Devices Evaluation on Radiograph 939
37. Radiological Evaluation of Percutaneous/Surgically Implanted Valve and Rings 968
38. Sternal Wire and Vascular Clips Assessment on Radiograph 985

SECTION 7: Miscellaneous

39. A. Radiographic Evaluation of Pulmonary Hypertension....1009
B. Radiographic Assessment in Eisenmenger Syndrome....1025
40. Utility of Targeted Barium Swallow (Esophagogram) in Present Era: Vascular Ring Assessment....1048
41. Cardiovascular Calcification Assessment on Radiograph....1059
42. Hemodynamic Assessment from Plain Radiographic Film....1078
43. Visible Signs and Patterns on Radiographs....1091
44. Mixed Bag Case Scenario....1127

Index.... *1137*

CHAPTER 4

Classification and Radiographic Approach for Recognition of Congenital Heart Disease

Congenital heart disease (CHD) refers to the heart disease since birth. It is generally considered to be present when a neonate or an infant presents with cyanosis, congestive cardiac failure (CCF), murmur or associated extracardiac anomalies (syndromic association) irrespective of the age. In CHD murmur are generally more parasternal than apical. Specific differential has to be considered while suspecting heart disease at specific age. Most of the congenital heart defects are well tolerated during the intrauterine life. This is due to the parallel circulation in fetus in contrast to circulation in series after birth. However, there are some lesions that can cause problems during fetal life. These diseases may present with CCF at birth.

CHD causing symptoms during fetal life

- Atrioventricular valve regurgitation (mitral/tricuspid regurgitation).
- Aortic valve regurgitation.
- Critical semilunar valve obstruction.
- Restriction of foramen ovale.
- Restriction of ductus arteriosus.
- Cardiomyopathies (primary or secondary to arrhythmias and anemia).
- Arteriovenous (AV) malformations.

RECOGNITION OF CONGENITAL HEART DISEASE

Assessment of child for the presence of heart disease is facilitated by Nada's criteria, which are divided into major and minor criteria **(Table 1)**. Presence of one major and two minor criteria suggests the presence of heart disease in any child. With heart murmur, the decision should be made whether it is organic or it is the so-called functional murmur. Age at which CHD is suspected or become symptomatic also gives clue for underlying lesion **(Table 2)**. Some of the cardiac disorders may present at any age like cardiomyopathy.

TABLE 1: Nada's criteria for detecting heart disease.

Major criteria	*Minor criteria*
Systolic murmur grade III or more	Systolic murmur less than grade III
Diastolic murmur	Abnormal S2
Cyanosis	Abnormal blood pressure (BP)
Congestive heart failure	Abnormal electrocardiogram (ECG)
	Abnormal X-ray

UTILITY OF X-RAY FOR RECOGNITION OF CARDIAC ISSUE

X-ray is considered as a minor criterion as it depends on various variables; hence, it is to be supplemented by clinical evaluation and additional investigations. Utility of plain radiograph is limited. Laya et al. in their study concluded that chest X-ray (CXR) alone is not diagnostic of specific cardiac lesions, with a low accuracy of only 71% and less emphasis should be placed on the use of radiographs alone in diagnosing specific congenital cardiac lesions. Similarly, Akbar Molaie et al. in their study showed sensitivity, and specificity, and the positive and negative predictive value of 61%, 80%, 53%, 86%, and 42%, respectively for CXR. In addition, gender, age, weight, the presence or absence of clinical signs, and the type of cardiovascular disease had no effect on the diagnostic accuracy of chest X-ray. In study by Chimoriya R et al radiographs and electrocardiograms were evaluated and compared with the diagnostic gold standard echocardiography. Chest radiographs had the highest sensitivity, specificity, and accuracy, with all being 100%, in detecting situs and cardiac position. There was a very good agreement between chest radiographs and echocardiography in the detection of both situs and cardiac position, while moderate agreement was observed for the detection of cardiomegaly, position of aortic knuckle, main

TABLE 2: Age of presentation of congenital heart disease.

First week of life	*Second week of life*	*Third week of life*	*Infancy*
D-TGA	CoA	VSD	VSD
HLHS	VSD	D-TGA	PDA
VSD-PA/Severe TOF	HLHS	CoA	TOF
CoA	D-TGA	TOF	ASD
VSD	VSD-PA/Severe TOF	AVSD	AVSD
PA-IVS	Heterotaxy	Heterotaxy	Myocardial diseases
Heterotaxy	Truncus arteriosus	PDA	PS
	Single ventricle	TAPVR	CoA

(ASD: atrial septal defect; AVSD: atrioventricular septal defect; CoA: coarctation of the aorta; D-TGA: D-transposition of the great arteries; HLHS: hypoplastic left heart syndrome; PAIVS: pulmonary atresia with intact ventricular septum; PDA: patent ductus arteriosus; PS: pulmonic stenosis; TAPVR: total anomalous pulmonary venous return; TOF: tetralogy of Fallot; VSD: ventricular septal defect)

JAYPEE BROTHERS

pulmonary artery dilation, and right pulmonary artery dilation.

Therefore, when a cardiovascular disease is suspected on chest radiography it should be confirmed with echocardiography and, if required, CT angiography/MRI or invasive angiography. X-ray should be always accompanied by physical examination to improve its yield. X-ray is very helpful in understanding the hemodynamic physiology and thus help in making a diagnosis. X-ray is particularly important in postoperative period as it helps to detect catheter and tube positions, detect complications such as air leaks and lung issues and to evaluate changes seen after surgery like improved flow to lungs or pulmonary edema seen after TOF repair.

BASIS OF CLASSIFICATION OF CONGENITAL HEART DISEASE

Congenital heart disease is broadly classified on the basis of presence or absence of cyanosis. Another important consideration is to assess pulmonary vascularity on radiograph. After these two basic variables, cardiac enlargement and great vessel assessment [pulmonary artery (PA) or aorta] should be considered. The detailed classification of CHD on the basis of these variables is presented in this chapter. The approach to CHD utilizing X-ray has been depicted in **Flowcharts 1 to 8**. Another simpler form of approach without considering cyanosis just on the basis of X-ray is shown in **Flowcharts 9 to 11**.

Classification of Congenital Heart Disease

Acyanotic Congenital Heart Disease with Increased Vascularity ***(Flowchart 1)***

- *Pretricuspid shunt*: Atrial septal defect (ASD) and partial anomalous pulmonary venous connection (PAPVC) including Scimitar, and shunt involving coronary sinus (CS)
- *Post-tricuspid shunt at level of ventricles*: Ventricular septal defect (VSD) and VSD-aortic regurgitation (AR)
- *Post-tricuspid shunt at level of great vessels*: Patent ductus arteriosus (PDA), aortopulmonary window (APW), and anomalous origin of PA from aorta
- *Shunt at various level*: Atrioventricular septal defect (AVSD) and multiple shunts
- *Obligatory shunt*: Coronary arteriovenous fistula (CAVF), rupture of the sinus of Valsalva (RSOV), left ventricular to right atrial shunt, and aorta to cardiac chamber tunnel
- **Flowchart 1** depicting approach to a patient of acyanotic congenital heart disease with increased vascularity.

Acyanotic with Normal Vascularity ***(Flowchart 2)***

- *Obstructive lesions*:
  - *Right ventricular outflow obstruction*: Pulmonary valve stenosis, subvalvar or supravalvar pulmonic stenosis (PS) including types of peripheral PA stenosis
  - *Left ventricular outflow obstruction*: Valvar aortic stenosis (AS), subvalvar or supravalvar AS, and coarctation of the aorta (CoA)

Flowchart 1: Radiological approach for acyanotic heart disease with increased pulmonary vascularity.

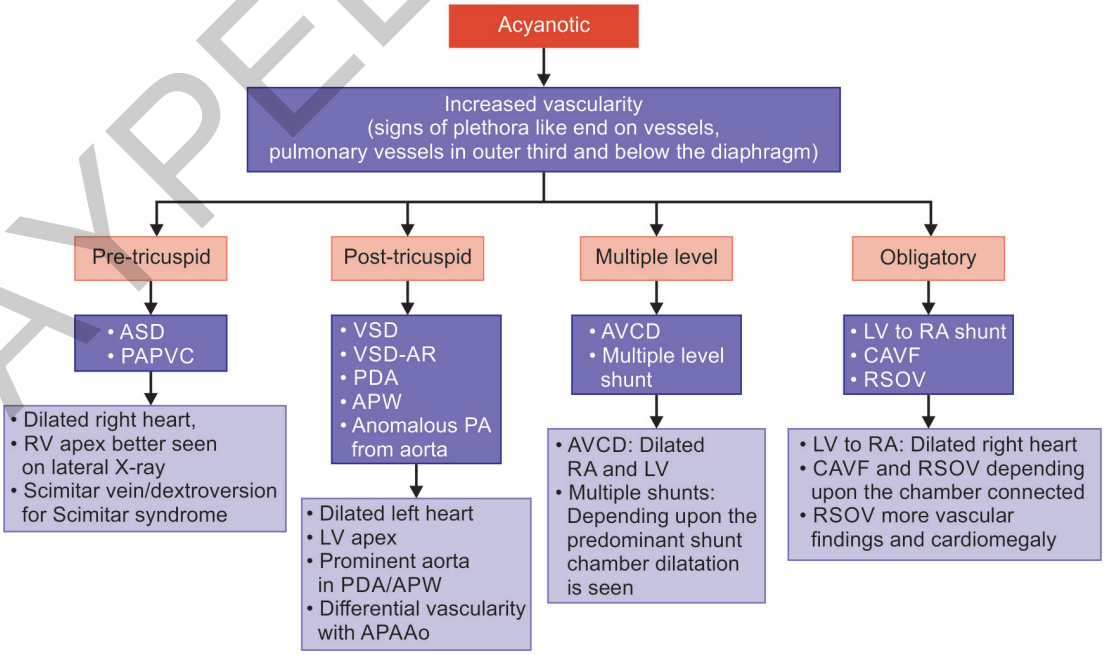

(APAAo: anomlaous PA from aorta; APW: aortopulmonary window; ASD: atrial septal defect; AVCD: atrioventricular canal defect; CAVF: congenital arteriovenous fistula; LV: left ventricle; PA: pulmonary artery; PDA: patent ductus arteriosus; RA: right atrium; RSOV: ruptured sinus of Valsalva; RV: right ventricle; VSD: ventricular septal defect; VSD-AR: VSD and aortic regurgitation)

JAYPEE BROTHERS

Flowchart 2: Radiological approach for acyanotic heart disease with normal lung vascularity.

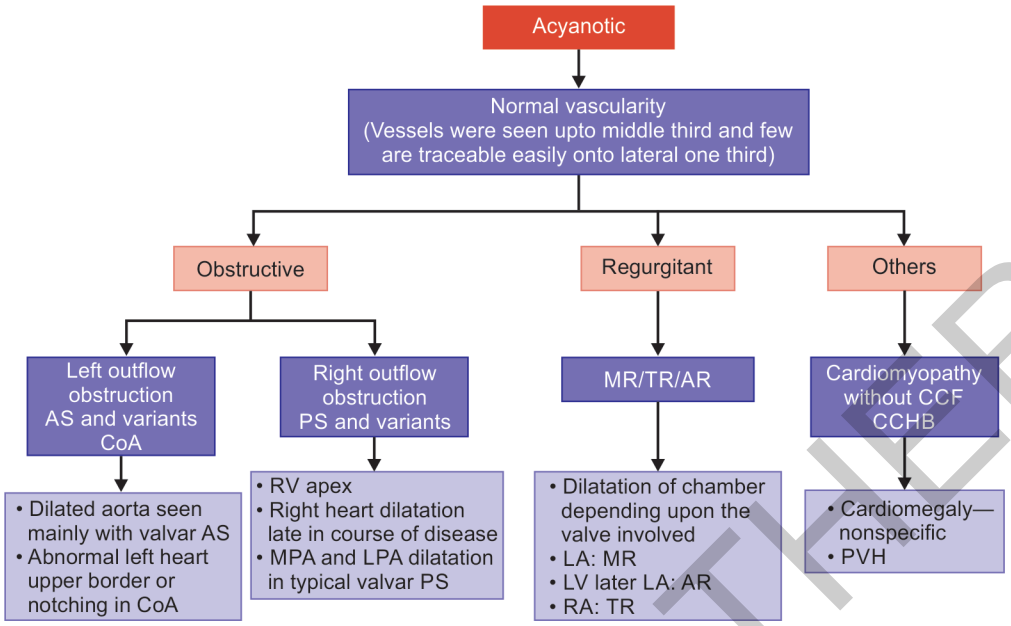

(AR: aortic regurgitation; AS: aortic stenosis; CCF: congestive cardiac failure; CCHB: complete congenital heart block; CoA: coarctation of aorta; LA: left atrium; LPA: left pulmonary artery; LV: left ventricle; MPA: main pulmonary artery; MR: mitral regurgitation; PS: pulmonic stenosis; RA: right atrium; RV: right ventricle; TR: tricuspid regurgitation)

Flowchart 3: Radiological approach for acyanotic heart disease with pulmonary venous hypertension.

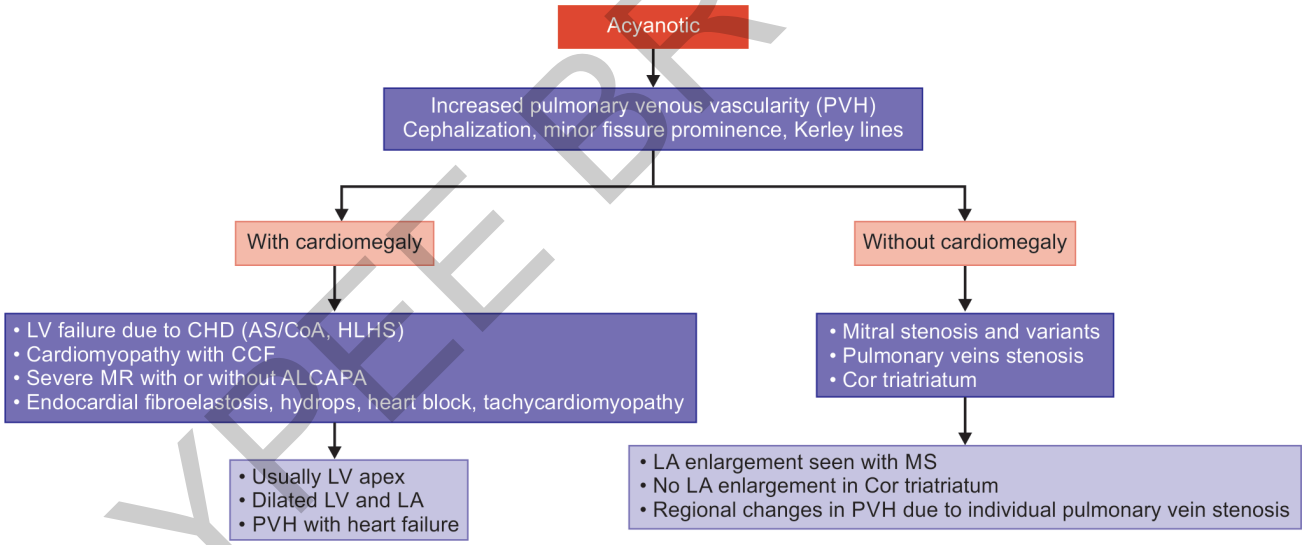

(ALCAPA: anomalous left coronary artery from pulmonary artery; AS: aortic stenosis; CCF: congestive cardiac failure; CHD: congenital heart disease; CoA: coarctation of aorta; HLHS: hypoplastic left heart syndrome; LA: left atrium; LV: left ventricle; MR: mitral regurgitation; MS: mitral stenosis; PVH: pulmonary venous hypertension)

- *Regurgitant lesions*: Congenital mitral regurgitation/tricuspid regurgitation/pulmonic regurgitation (MR/TR/PR)
- Cardiomyopathy without CCF and congenital complete heart block (CCHB)
- **Flowchart 2** showing approach to acyanotic congenital heart disease with normal pulmonary vascularity.

Acyanotic Congenital Heart Disease with Decreased Vascularity

- Technical issues
- Severe PS with RV failure

Acyanotic with Increased Pulmonary Venous Vascularity (Pulmonary Venous Hypertension) ***(Flowchart 3)***

- *With cardiomegaly*: Cardiomyopathy with CCF, LV failure due to CHD, severe MR, anomalous left coronary artery from the pulmonary artery (ALCAPA), endocardial fibroelastosis, and myocarditis.
- *Without cardiomegaly*: Mitral stenosis (MS), supramitral stenosing ring, cor triatriatum, and stenosis of individual pulmonary vein.
- **Flowchart 3** showing approach to acyanotic congenital heart disease with increased pulmonary venous vascularity.

JAYPEE BROTHERS

Flowchart 4: Radiological appraoch for cyanotic heart disease with increased vascularity.

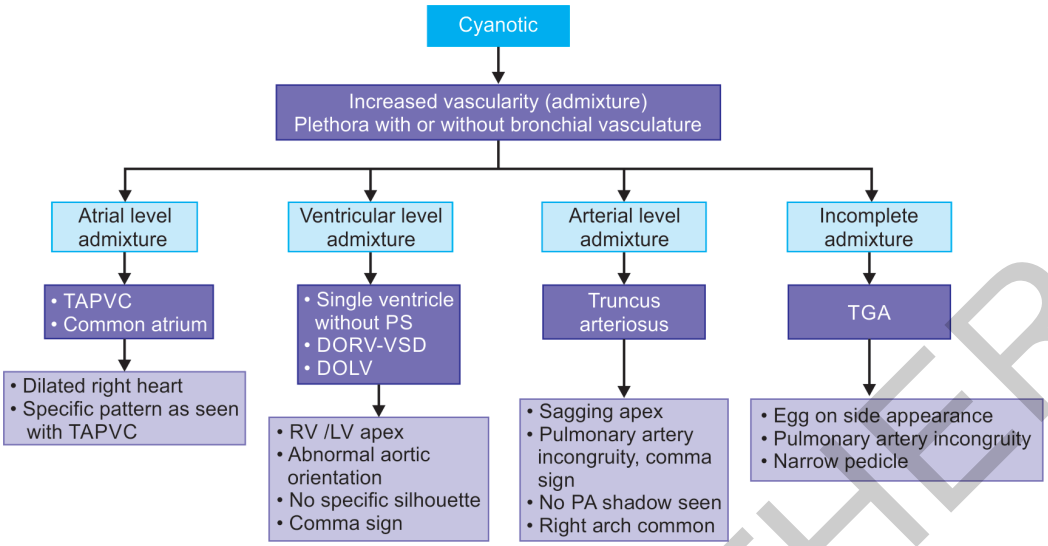

(DOLV: double outlet left ventricle; DORV: double outlet right ventricle; LV: left ventricle; PA: pulmonary artery; PS: pulmonary stenosis; RV: right ventricle; TAPVC: total anomalous pulmonary venous connection; TGA: transposition of great arteries; VSD: ventricular septal defect)

Flowchart 5: Radiological approach for cyanosis with decreased pulmonary vascularity.

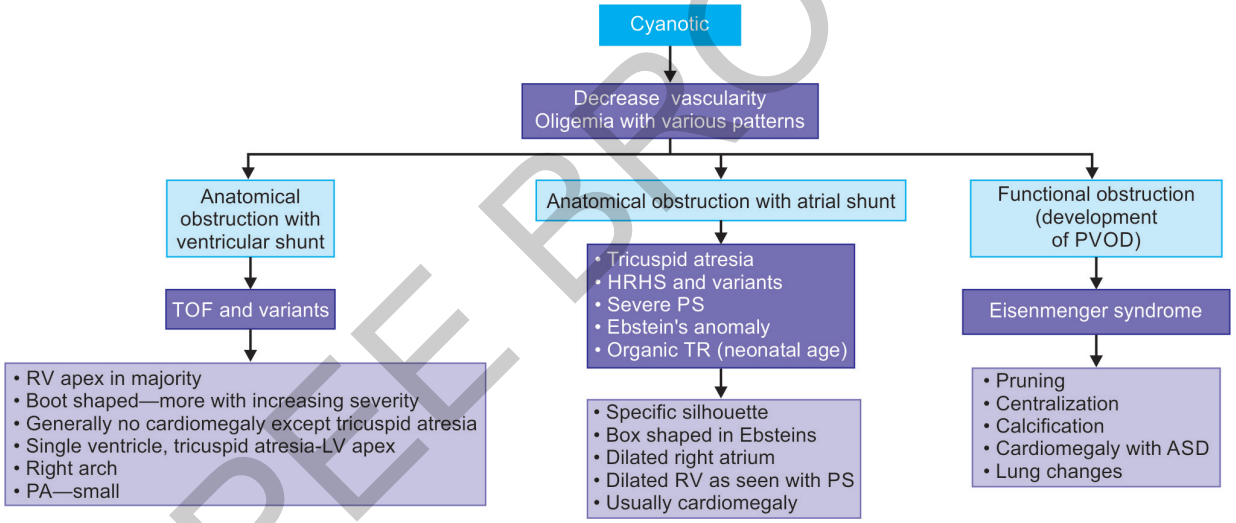

(ASD: atrial septal defect; PS: pulmonary stenosis; PVOD: pulmonary vascular obstructive disease; RV: right ventricle; TOF: tetralogy of Fallot; TR: tricuspid regurgitation)

Cyanotic Congenital Heart Disease with Increased Vascularity (Admixture Lesion) ***(Flowchart 4)***

It involves the presence of a common cardiac chamber for mixing of pulmonary and systemic blood. Admixture lesions referred to cyanotic conditions where all systemic and pulmonary venous blood mixed at common chamber with features of both right to left and left to right shunt. In complete admixture, PA and aorta have same saturation.

- *At the level of atrium*: Common atrium, total anomalous pulmonary venous connection (TAPVC), and tricuspid atresia without PS
- *At the level of ventricle*: Single ventricle without PS including DILV, double outlet right ventricle (DORV), double outlet left ventricle (DOLV)
- *At the level of great arteries*: Truncus
- *Incomplete admixture*: Transposition of the great arteries (TGA).

Cyanotic Congenital Heart Disease with Decreased Vascularity ***(Flowchart 5)***

Obstruction to pulmonary blood flow in presence of another cardiac defect causing shunting of blood away from lungs into the systemic circulation.

- *Anatomical pulmonary flow obstruction with ventricular level shunt (VSD)*: TOF and its variants
- *Anatomical pulmonary flow obstruction with atrial level shunt [ASD/patent foramen ovale (PFO)]*: Tricuspid atresia, hypoplastic right heart syndrome (HRHS) [pulmonary

JAYPEE BROTHERS

Flowchart 6: Radiological approach for cyanotic congenital heart disease with normal lung vascularity.

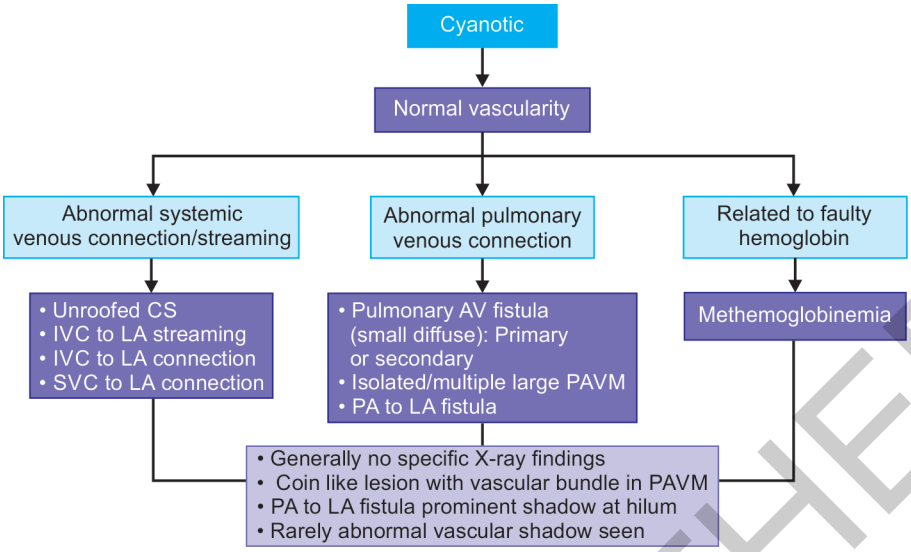

(AV: atrioventricular; CS: coronary sinus; IVC: inferior vena cava; LA: left atrium; PA: pulmonary artery; SVC: superior vena cava)

atresia intact intact ventricular septum (IVS) I and II], severe PS, Ebstein's anomaly, severe TR in neonatal age

- *Obstruction due to development of pulmonary veno-occlusive disease (PVOD) [presence of pulmonary arterial hypertension (PAH)]*: Eisenmenger syndrome.
- **Flowchart 5** showing approach to cyanotic congenital heart disease with decreased pulmonary vascularity

Cyanotic Congenital Heart Disease with Normal Vascularity ***(Flowchart 6)***

- *Abnormal systemic venous connection or streaming:* Unroofed CS [left superior vena cava (LSVC) to left atrium (LA)], right superior vena cava (RSVC) to LA, inferior vena cava (IVC) to LA—abnormal connection or due to prominent Eustachian valve through ASD/PFO
- *Abnormal pulmonary venous connection:* Small diffuse pulmonary arteriovenous malformation (AVM), PA to LA fistula
- Other noncardiac causes should be ruled out such as methemoglobinemia and sulfhemoglobinemia.
- **Flowchart 6** showing approach to cyanotic congenital heart disease with normal pulmonary vascularity.

Cyanotic Congenital Heart Disease with Increased Pulmonary Venous Vascularity (Pulmonary Venous Hypertension) ***(Flowchart 7)***

- *With abnormal pulmonary venous connection*: TAPVC with obstruction and atresia of common pulmonary vein
- *With normal pulmonary venous connection*: Aortic atresia, mitral atresia, and hypoplastic left heart syndrome (HLHS).

Others ***(Flowchart 8)***

Certain CHD may not be classified into above subgroups as they might have their own characteristic presentation/manifestation. These include:

Flowchart 7: Radiological approach for cyanotic heart disease with PVH.

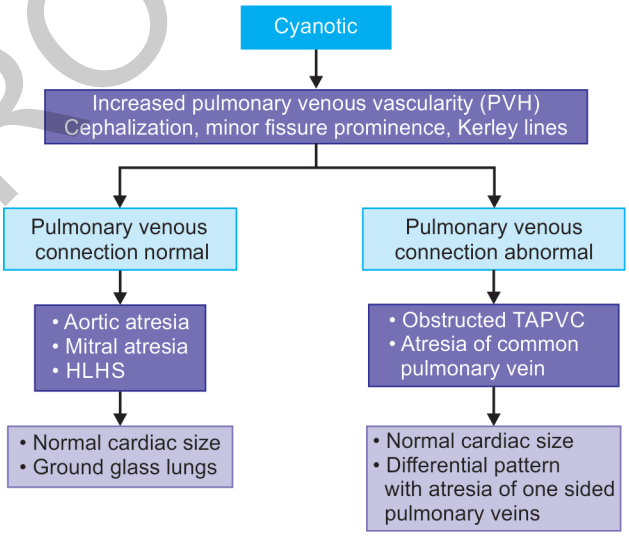

(HLHS: hypoplastic left heart syndrome; TAPVC: total anomalous pulmonary venous connection)

- *Vascular anomalies:* Congenital coronary abnormalities, aortic arch anomalies, vascular ring/PA sling, systemic AV fistula, unusual fistula, and portosystemic shunts
- *Heterotaxy syndrome:* In right heterotaxy situs is never normal. They are usually cyanotic with admixture lesion or with decreased vascularity. Pulmonary venous hypertension is seen in presence of pulmonary venous obstruction. Left heterotaxy is usually non cyanotic with increased flow, difficult to differentiate from left to right shunts
- Cardiac tumors
- Pericardial defects
- *Combination of CHD and acquired disease:* Lutembacher [congenital interatrial communication and acquired rheumatic heart disease (RHD)]

JAYPEE BROTHERS

Flowchart 8: Heart disease not fitting into single particularly group.

Aortic arch anomalies vascular ring and sling	Arch and trachea issues on X-ray Pulmonary vascularity changes with sling
Heterotaxy	Situs, bronchial, visceral abnormalities Plethora or oligemia or reticular pattern
Mass and tumors	Unusual silhouette on X-ray Both frontal and lateral views are useful
Pericardial defects	Cardiomegaly, abnormal silhouette Air in AP window/below heart, right border loss
Coronary abnormalities	No specific pattern Cardiomegaly due to ventricular dysfunction Prominent LA due to high LVEDP/MR Features of PVH
Lutembacher	Combination of congenital and acquired heart disease Calcification of MV, gross right heart enlargement, plethora
Systemic AV fistula, PSS, Unusual connections	No specific pattern

(AP: aortopulmonary; AV: atrioventricular; LA: left atrium; LVEDP: left ventricular end diastolic pressure; MR: mitral regurgitation; MV: mitral valve; PSS: portosystemic shunts; PVH: pulmonary venous hypertension)

- Some congenital heart defects do not present at birth and may develop over the course of disease like infundibular PS or systolic anterior motion (SAM), which developed much later even in absence of detectable muscle or left ventricular outflow tract (LVOT) ridge initially.

Table 3 enlisting the general considerations for different groups of CHDs.

GENERAL CLINICAL AND RADIOLOGICAL FEATURES (TABLE 3)

Acyanotic Congenital Heart Disease with Increased Vascularity (Left-to-Right Shunts)

- The degree of cardiomegaly is usually in proportion to the increase in pulmonary vascularity. The left-to-right shunts are volume overload lesions. Consequently, cardiomegaly is frequent and this cardiomegaly should, in general, be in proportion to the prominence of the pulmonary vascularity.
- When cardiomegaly exists out of proportion to the pulmonary arterial vascularity, one must consider a number of possibilities. One of the possibilities is that the left-to-right shunt is diminishing in size such as decrease in the size of the VSD. Another consideration is the coexistence of additional cardiac lesions, such as primary myocardial disease or coarctation of aorta. Common non-cardiac issues like anemia should also be considered.

TABLE 3: Clinical radiological correlation of common groups of congenital heart disease.

Acyanotic	***Clinical features***	***Typical X-ray findings***
• Left-to-right shunts • 50% of all CHD • VSD accounts for 25% of all CHD • Volume overload conditions	• FTT • Recurrent RTI • Pneumonia • CCF	• Plethora • Venous congestion in addition to plethora for large shunts • Cardiomegaly in proportion to shunt
• Obstructive lesions • 25% of all CHD	• Asymptomatic • 10% causes CCF in neonatal period • Cyanosis in neonatal age with critical PS • RD in presence of CCF	• Normal vascularity till late in disease • Post stenotic dilatation of PA/aorta • Left upper border changes of notching with CoA
Acyanotic with high pulmonary venous vascularity	• Severe symptoms of cardiac failure without cyanosis. Cyanosis may develop later with pulmonary edema • Hemoptysis	• PVH on CXR • Cardiomegaly in lesion distal to MV with cardiac dysfunction or with chronic MR • Normal cardiac size in lesion at or before mitral valve • Dilated PA secondary to PVH • RVH if PV obstruction present from birth
Cyanotic	***Clinical features***	***Typical X-ray findings***
Cyanotic with PVH	• Mild-to-severe cyanosis • Breathing difficulty • CCF	• PVH • Normal cardiac size in lesions such as obstructed TAPVC or atretic pulmonary veins • Cardiomegaly in lesions such as HLHS, aortic/mitral atresia, and AS with small LV
Cyanotic with increased vascularity (admixture lesions)	• Cyanosis • CCF • Acidosis • FTT • Pneumonia	• Feature of both R-L shunt in the form of cyanosis and L-R shunt in the form of plethora are seen • Cardiomegaly is seen

Contd...

JAYPEE BROTHERS

Contd...

Cyanotic	*Clinical features*	*Typical X-ray findings*
Cyanotic with deceased flow due to anatomic obstruction (VSD-PS and TOF physiology)	• Deferred cyanosis in most of the conditions • Single ventricle PS, tricuspid atresia or severe TOF/VSD PA can be cyanotic very early in neonatal age • History of spells present	• Usually no cardiomegaly—RV apex mostly • LV apex and cardiomegaly in selected cases
Cyanotic with obstruction due to PVOD (Eisenmenger syndrome)	• History of CCF and high shunts in the past with improvement of symptoms • Later symptoms of dyspnea, cyanosis, and hemoptysis develops	• Cardiomegaly usually absent (present with lesions like ASD or later with RV dysfunction) • Pruning • Centralization • Calcification

(AS: aortic stenosis; ASD: atrial septal defect; CCF: congestive cardiac failure; CHD: congenital heart disease; CXR: chest X-ray; FTT: failure to thrive; HLHS: hypoplastic left heart syndrome; LV: left ventricular; MR: mitral regurgitation; MV: mitral valve; PA: pulmonary artery; PS: pulmonic stenosis; PVH: pulmonary venous hypertension; PVOD: pulmonary veno-occlusive disease; RTI: respiratory tract infection; RV: right ventricle; RVH: right ventricular hypertrophy; TAPVC: total anomalous pulmonary venous connection; TOF: tetralogy of Fallot; VSD: ventricular septal defect)

- PDA is associated with left atrial enlargement and a prominent aortic arch. In infants, prominence of the aortic arch may be difficult to recognize, so this sign may not always be available. Consequently, since a VSD is a more frequent lesion, this should be the diagnosis when there is left atrial enlargement and no clearly discernible enlargement of the aortic arch. An exception to this rule is in the premature infant, where a PDA is statistically by far the most frequent congenital heart lesion. The radiograph of the premature infant with PDA usually does not disclose signs of left atrial and aortic arch enlargement.
- Of the left to right lesion only PDA has definitive radiographic findings on chest film. A patient with an X-ray with right aortic arch with shunt vascularity almost always has a VSD. Large shunts causes volume overloading with left ventricular failure LVF causing mixed picture of plethora and pulmonary venous hypertension (PVH).

Obstructive Lesions

- Cardiomegaly occurs in neonatal age with critical disease or later after commencement of myocardial dysfunction. It is difficult to diagnose on X-ray without decompenastion or without typical signs which are not often present.

Pulmonary Venous Hypertension

- One of the common features for PVH is minor fissure prominence. Reticular granular and ground glass pattern are common during infantile period.
- In general, PVH beyond mitral valve (i.e. at aortic valve and major vessel) level involves cardiomegaly while lesion at mitral valve causing PVH may cause left atrial dilatation without significant cardiomegaly leading to disproportionate cardiac size in comparison to pulmonary vascularity changes.
- Lesions in these groups have predominant pulmonary venous congestion and altered pulmonary venous vascularity rather than the pulmonary arterial vascularity. Notable examples are obstructed TAPVC, HLHS and variants. Patients with these lesions may have shunts, but inclusion in this group requires that the predominant pathophysiologic event is pulmonary venous congestion.
- The clinical features in such lesions are lack of cyanosis and more symptoms like dyspnea, tachypnea and tachycardia. The salient radiographic findings are indistinctness of the pulmonary vascularity, especially in the perihilar area, or interstitial pulmonary edema.
- Disproportionate cardiomegaly in comparison to PA with myocardial involvement is seen in ALCAPA.
- During neonatal age, noncardiac disease also presents in this group such as hydrops, twin–twin transfusion syndrome (TTS), asphyxia, fluid overload, tachycardiomyopathy, metabolic cause late cord clamp, and myocarditis.

Cyanotic CHD

- In cyanotic CHD the lungs are almost invariably abnormal. The only exception which is likely to be encountered with any frequency is mild Fallot's tetralogy in which the pulmonary blood flow is approximately normal and so pulmonary vessel size will appear within normal limits

Admixture Lesions (Cyanosis with Increased Blood Flow)

- Admixture at various levels decide the radiological features like admixture with atria features like ASD, admixture in ventricle presented likes VSD, and admixture in great vessels behaves like PDA.
- Feature of both R-L shunt in the form of cyanosis and L-R shunt in the form of plethora are seen with admixture lesions.

JAYPEE BROTHERS

Flowchart 9: Radiological approach for increased pulmonary vascularity.

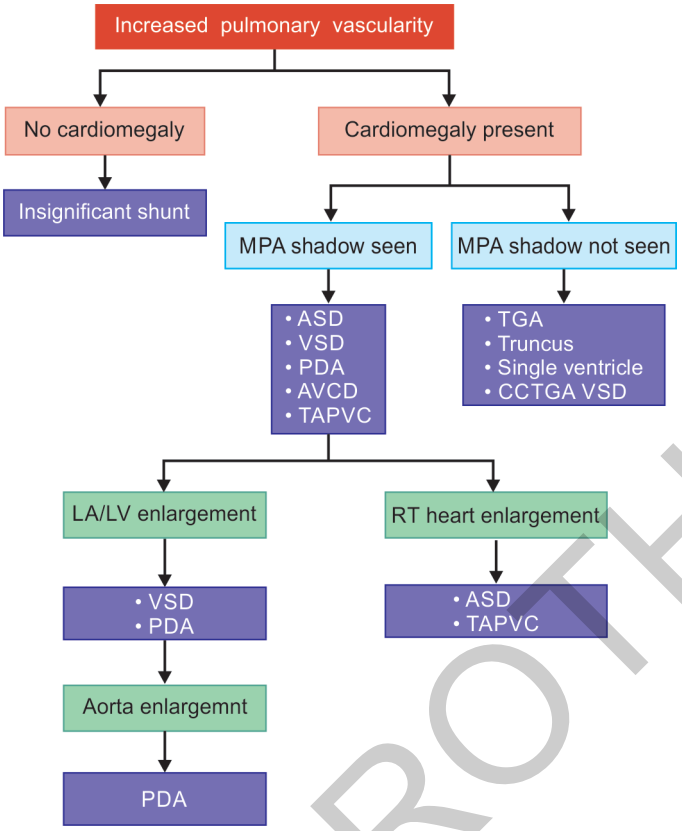

(ASD: atrial septal defect; CCTGA: congenitally corrected transposition of the great arteries; LA: left atrium; LV: left ventricle; MPA: main pulmonary artery; PDA: patent ductus arteriosus; TAPVC: total anomalous pulmonary venous connection; TGA: transposition of the great arteries; VSD: ventricular septal defect)

Flowchart 10: Radiological approach for decreased pulmonary vascularity.

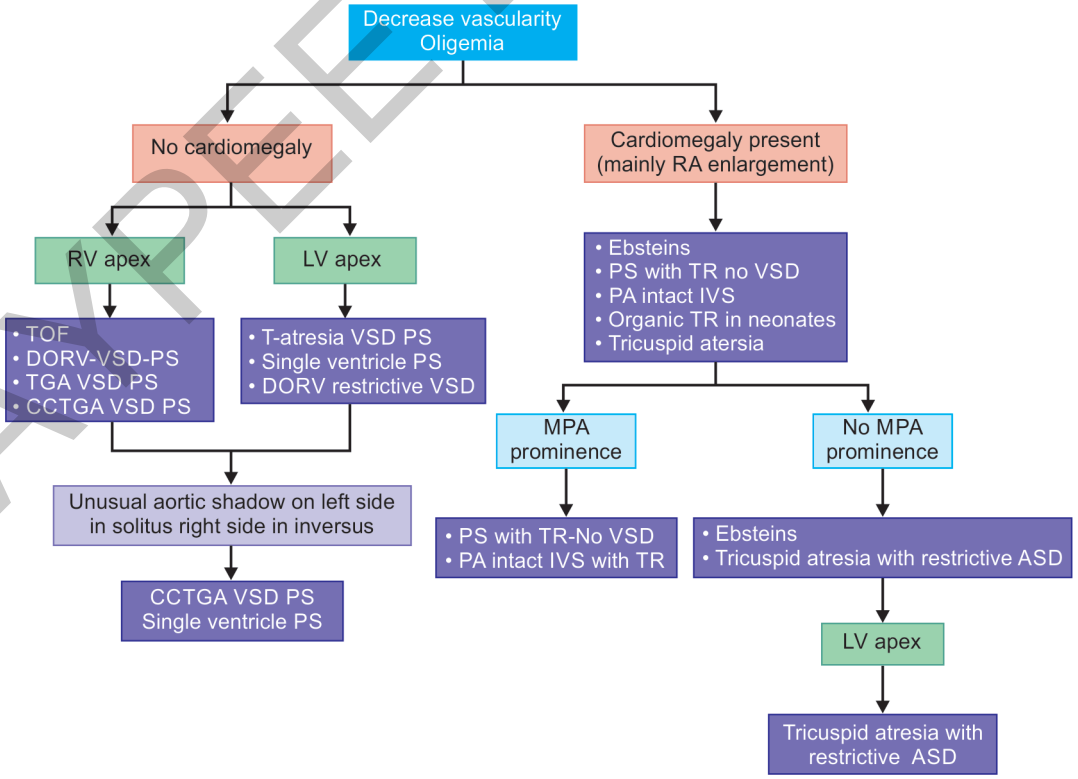

(ASD: atrial septal defect; CCTGA: congenitally corrected transposition of the great arteries; DORV: double outlet right ventricle; IVS: interventricular septum; LV: left ventricle; MPA: main pulmonary artery; PA: pulmonary artery; PS: pulmonary stenosis; RA: right atrium; RV right ventricle; TGA: transposition of the great arteries; TOF: tetralogy of Fallot; TR: tricuspid regurgitation; VSD: ventricular septal defect)

JAYPEE BROTHERS

Flowchart 11: Radiological approach for normal pulmonary vascularity.

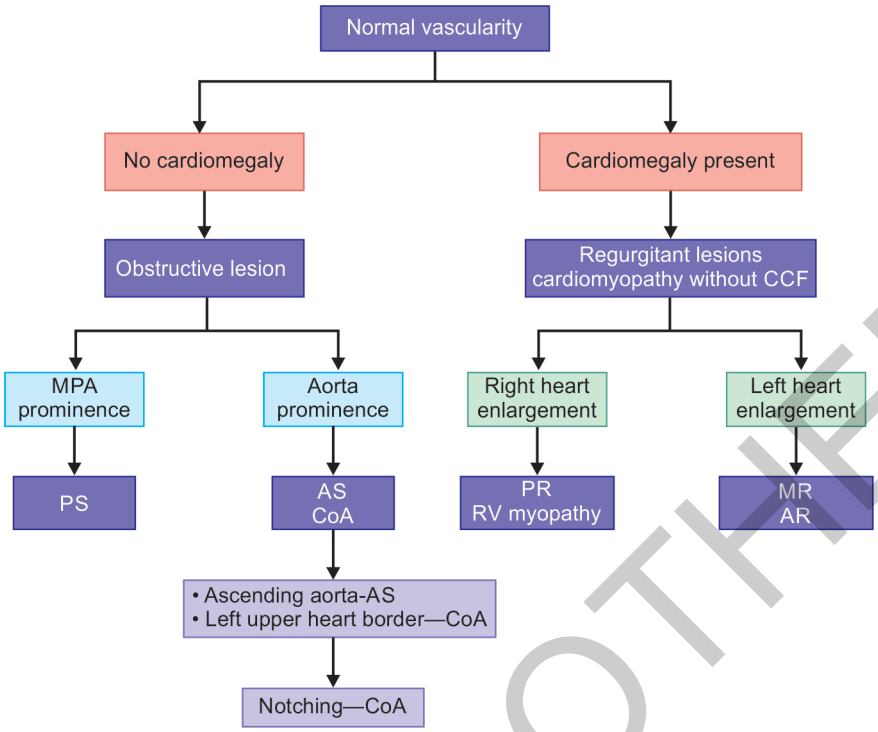

(AS: aortic stenosis; AR: aortic regurgitation; CCF: congestive cardiac failure; CoA: coarctation of aorta; MR: mitral regurgitation; PR: pulmonary regurgitation; PS: pulmonary stenosis)

Another way to assess congenital heart defect on chest X-ray without taken into account the cyanosis is to start with vascularity and cardiomegaly. This is more simplified but differential can be made only in presence of typical full-blown disease. This approach is given in **Flowcharts 9 to 11**.

SUGGESTED READING

1. Ball F, Vettermann H. Synoptic examination of radiologic and cardiologic findings in children with congenital heart defects of the left-right-shunt group. Significance of various criteria of thoracic radiography in newborn and their differential diagnostic dependability. Radiologe. 1970;10(6):226-34.
2. Chimoriya R, Kumar G, Rana K, Chimoriya R, Anand R, Dagar KS, Awasthy N. Role of chest radiographs and electrocardiograms in predicting the hemodynamics of congenital heart disease. Preprints 2022, 2022090185 (doi: 10.20944/preprints202209.0185.v1)
3. Gordon Culham JA, Mawson JB. Chest radiography in pediatric cardiovascular disease. In: Slovis TL (Ed). Caffey's Pediatric Diagnostic Imaging, 11th edition. Missouri: Mosby; 2007.
4. Higgins CB. Cardiac imaging. Radiology. 2000;217:4-10.
5. Laya BF, Goske MJ, Morrison S, Reid JR, Swischuck L, Ey EH, et al. The accuracy of chest radiographs in the detection of congenital heart disease and in the diagnosis of specific congenital cardiac lesions. Pediatr Radiol. 2006;36(7):677-81.
6. Molaie A, Abdinia B, Zakeri R, Talei A. Diagnostic value of chest radiography paediatric cardiovascular disease: A retrospective Study in Tabriz, Northwest of Iran. Int J Pediatr. 2015;3:9-13.
7. REES, RSO, Jefferson KE. 1967, Clin. Radio!.,18, 366.
8. Rosenbaum HD, Lieber A, Hanson DJ, 1966, Seminars in Roentgeno!., 1, 47.
9. Smevik B. Chest radiography in congenital heart disease. Medical Radiology. 2008;261-74.
10. Van Praagh R, 1967, Heart Disease in Infancy and Childhood, eds. John D. Keith, Richard D. Rovve, and Peter Vlad, p. 788 (MacMillan, New York).

JAYPEE BROTHERS

JAYPEE BROTHERS

for detailed information on radiology books, visit our website www.jaypeebrothers.com, for detailed information on radiology books, visit our website www.jaypee

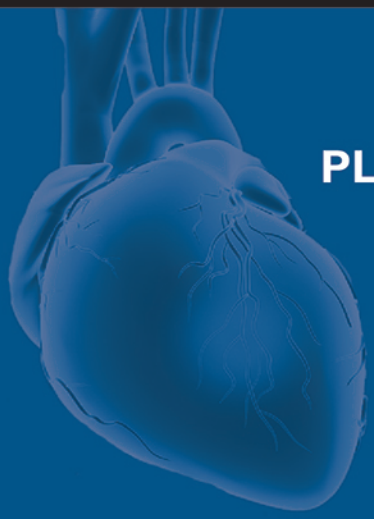

PEDIATRIC CARDIAC RADIOLOGY

PLAIN RADIOGRAPHIC INTERPRETATION IN CONGENITAL AND STRUCTURAL HEART DISEASES

Salient Features

- The book contains nearly 2000 radiographic films to showcase every aspect of pediatric cardiology
- Includes plain radiographic film evaluation of congenital heart diseases and radiological course of operated lesions
- Special emphasis on prosthesis assessment on radiographic films including catheter, valves, occluders, stents, conduction devices, clips, sternal wires, and ECMO cannulae
- Clinical case scenario at the end of each chapter to stimulate readers to show importance of plain radiographic film in patient management
- Special emphasis on topics like pulmonary hypertension, cardiovascular calcification, and barium swallow assessment from radiographic film
- Logical reasoning and conceptual explanation of radiographic findings, appearances and patterns visible with supplemented CT/MRI/echocardiographic and angiogram images wherever needed. Uniform color coding specific to a given structure is applied throughout the text for easy understanding
- Dedicated Chapters summarize hemodynamic evaluation using X-ray and lucid explanation of majority of signs and patterns seen in cardiology
- Simplified and logical approach using charts and diagrams at suitable places to highlight important information
- This book caters readers from various backgrounds including general pediatrics, radiology and cardiology including pediatric cardiology.

Printed in India

Available at all medical bookstores or buy online at www.jaypeebrothers.com

JAYPEE BROTHERS
Medical Publishers (P) Ltd.
EMCA House, 23/23-B, Ansari Road,
Daryaganj, New Delhi - 110 002, INDIA
www.jaypeebrothers.com

Join us on facebook.com/JaypeeMedicalPublishers

Shelving Recommendations
RADIOLOGY/CARDIOLOGY

ISBN 978-93-5465-352-0