d information on dermatology books, visit our website www.jaypeebrothers.com, for detailed information on dermatology books, visit our website www.jaypeebrothers.com

IADVL
INDIAN ASSOCIATION OF DERMATOLOGISTS, VENEREOLOGISTS & LEPROLOGISTS
1973

Under the Aegis of IADVL Academy

IADVL Textbook of Dermatopathology

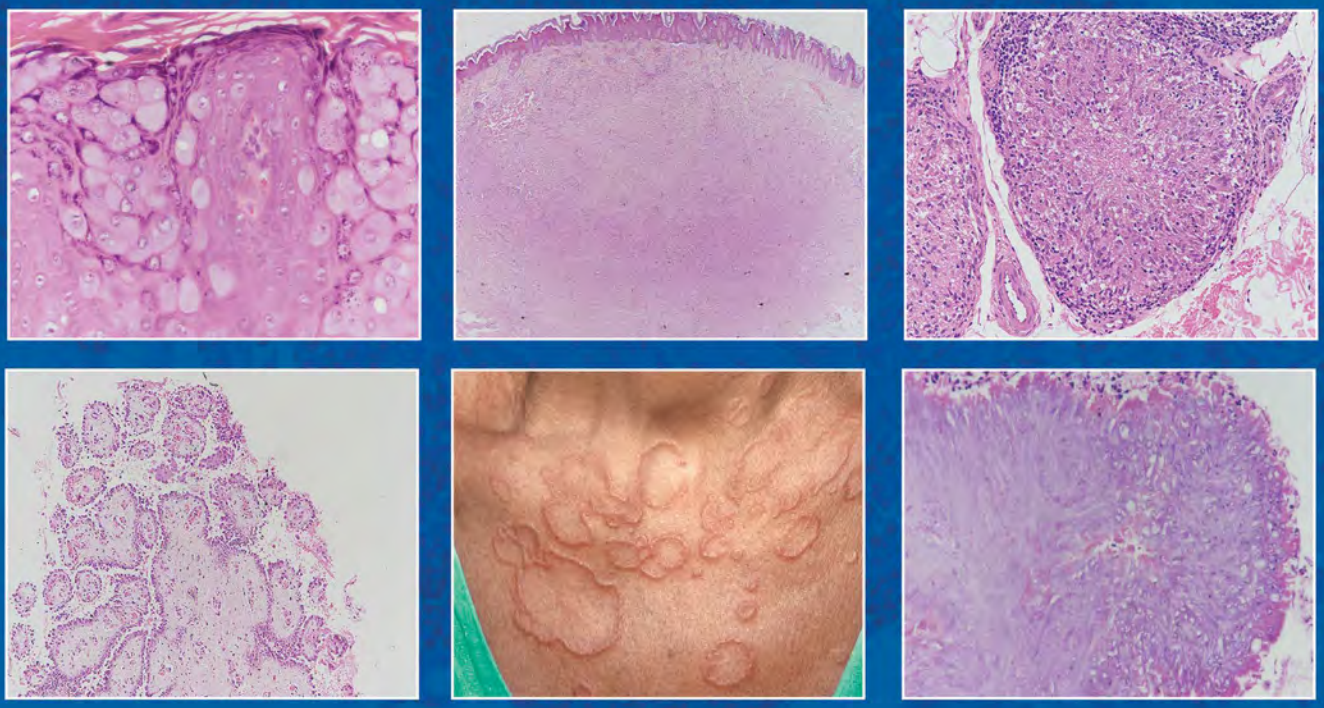

M Ramam
Sujay Khandpur
Neetu Bhari
Vishal Gupta

JAYPEE

CONTENTS

Section 1: Basics

1. **Normal Skin** 3
   Bhavya Swarnkar, Neetu Bhari

2. **Skin Biopsy: Techniques, Special Stains, Immunohistochemistry and Immunofluorescence** 9
   Raghavendra Rao, Manasa Kayarkatte Narayan

Section 2: Reaction Patterns

3. **Psoriasiform Tissue Reaction** 19
   Chirag Desai

4. **Spongiotic Tissue Reaction** 30
   Saurabh Bhatia, Vishal Gupta

5. **Lichenoid Tissue Reaction** 38
   Riti Bhatia, Vishal Gupta

6. **Vesiculobullous Tissue Reaction** 50
   Neha Taneja, Vishal Gupta

7. **Granulomatous Tissue Reaction** 68
   Deepika Yadav, M Ramam

8. **Vasculitis, Vasculopathic and Urticarial Tissue Reactions** 83
   Sujay Khandpur

9. **Interstitial Tissue Reaction** 101
   Bhavya Swarnkar, Neetu Bhari

10. **Panniculitis** 105
    Geeti Khullar, Uma Nahar Saikia

11. **Epidermal Reaction Patterns, Perforating Disorders** 117
    Aanchal Panth, M Ramam

12. **Reaction Patterns in Infectious Diseases** 125
    M Ramam

Section 3: Infections

13. **Leprosy** 133
    Rajiv S Joshi

14. **Cutaneous Tuberculosis and Atypical Mycobacterial Infections** 145
    Riti Bhatia, M Ramam

15. Cutaneous Fungal Infections **153**
Sujay Khandpur

16. Viral Infections **169**
Tekumalla Sindhuja, Neetu Bhari

17. Other Infections: Leishmaniasis, Treponematoses, Arthropod Infestations and Bacterial Infections **178**
Riti Bhatia, Nikhil Mehta, Vishal Gupta, M Ramam

Section 4: Connective Tissue Diseases, Drug Reactions, Pigmentary Disorders

18. Connective Tissue Diseases **189**
Sujay Khandpur

19. Cutaneous Adverse Drug Reactions **200**
Sujay Khandpur, Sanjay Singh

20. Pigmentary Disorders **211**
Riti Bhatia, M Ramam

Section 5: Disorders of Hair Follicle and Nail

21. Hair Follicle Structure and Disorders **229**
Shipra Agarwal, Deepika Yadav

22. Nail Disorders **246**
Geetali Kharghoria, Chander Grover, Sonal Sharma

Section 6: Disorders of Collagen and Elastin

23. Disorders of Collagen **263**
Biswanath Behera, Madhusmita Sethy

24. Elastic Tissue Disorders **266**
Savera Gupta, Neetu Bhari

Section 7: Cutaneous Infiltrates, Lymphomas, Deposition Disorders

25. Neutrophilic and Eosinophilic Infiltrates **275**
Geeti Khullar

26. Mast Cell and Plasma Cell Infiltrates **282**
Sujay Khandpur

27. Histiocytic Infiltrates: Histiocytoses and Xanthomas **290**
Geetali Kharghoria, Neetu Bhari

28. Cutaneous Lymphomas **301**
Anisha Manocha, Rajalakshmi Tirumalae

29. Cutaneous Deposition Disorders **317**
Indu Kumari, Atul Madhusudan Dongre

Section 8: Tumors and Proliferations

30. Cysts **333**
Vishal Gupta

31. Epidermal Nevi **341**
Bhavya Swarnkar, Vishal Gupta

32. Vascular Malformations and Tumors **346**
Tekumalla Sindhuja, Neetu Bhari

33. Keratinocytic Tumors **359**
Sujay Khandpur

34. Appendageal Tumors **369**
Sujay Khandpur

35. Soft Tissue Tumors **382**
Sudheer Arava, Manoj Singh

36. Melanocytic Lesions **393**
Rajalakshmi Tirumalae

37. Cutaneous Metastasis **404**
Savera Gupta, Neetu Bhari

Section 9: Rough Notes

38. Rough Notes: Observations, Clues, Surmises and Hypotheses **409**
M Ramam, Sujay Khandpur, Neetu Bhari, Vishal Gupta

Index **423**

CHAPTER

4 Spongiotic Tissue Reaction

Saurabh Bhatia, Vishal Gupta

- Acute spongiotic reactions
- Subacute spongiotic reactions
- Chronic spongiotic reactions
- Neutrophilic spongiosis
- Eosinophilic spongiosis
- Eczematous disorders
  - Irritant contact dermatitis
  - Seborrheic dermatitis
  - Pompholyx
  - Hyperkeratotic hand and foot dermatitis
- Noneczematous conditions that show a spongiotic pattern
  - Palmoplantar psoriasis
  - Dermatophytosis
  - Pityriasis rosea
  - Erythema annulare centrifugum
  - Pityriasis alba, hypopigmenting dermatitis
  - Other disorders presenting with follicular spongiosis
  - Miliaria

The word "spongiosis" is derived from Latin *spongiōsus* (sponge-like), referring to sponge-like appearance of epidermis. The spongiotic tissue reaction is characterized by intercellular edema in the epidermis which causes the space between keratinocytes to be widened with stretching of intercellular bridges **(Fig. 1)**. The intensity of spongiosis can vary from subtle separation of keratinocytes to formation of spongiotic vesicles **(Fig. 2)**. Focal, cup-shaped collections of Langerhans cells in the upper epidermis are frequently seen.

Spongiosis is often accompanied by the influx of inflammatory cells such as lymphocytes, neutrophils, or eosinophils into the epidermis, a process referred to as exocytosis **(Fig. 3)**. Lymphocytic exocytosis should be differentiated from epidermotropism which refers to presence of lymphocytes in the epidermis with minimal spongiosis, in the context of cutaneous T-cell lymphoma **(Fig. 4)**.

Spongiotic tissue reactions are classified into acute, subacute, and chronic depending on the stage of the process.

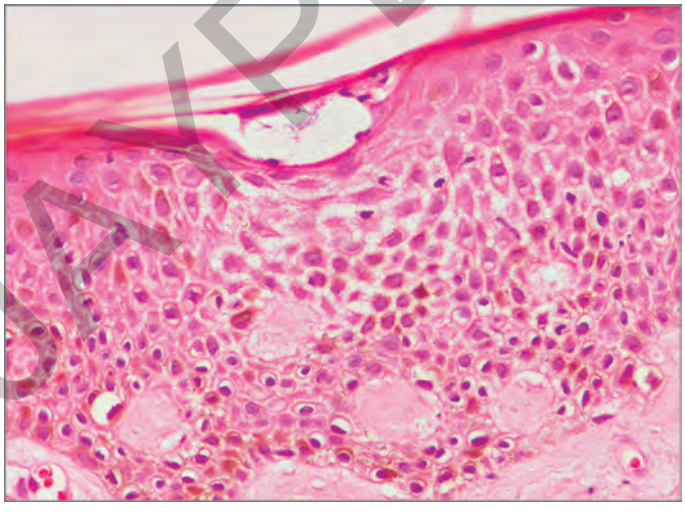

Fig. 1: Spongiosis: Keratinocytes separated from each other by edema, with stretching of intercellular bridges (H&E, ×400).

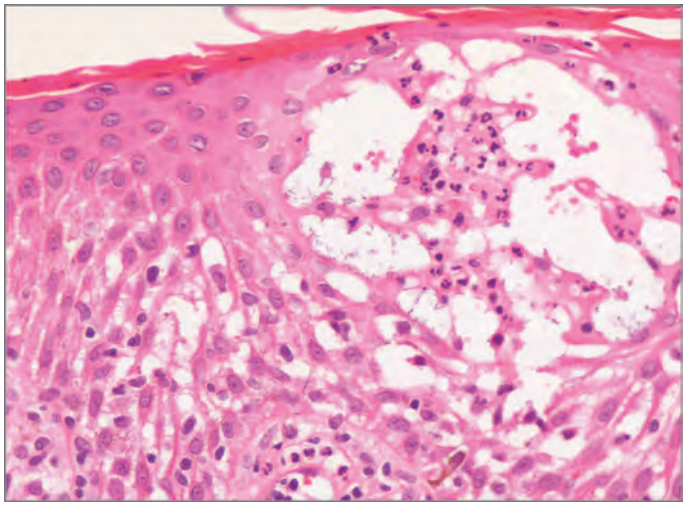

Fig. 2: Spongiotic blister: Large intraepidermal space formed due to wide separation of keratinocytes by marked intercellular edema. Note neutrophils within the blister (H&E, ×400).

JAYPEE BROTHERS

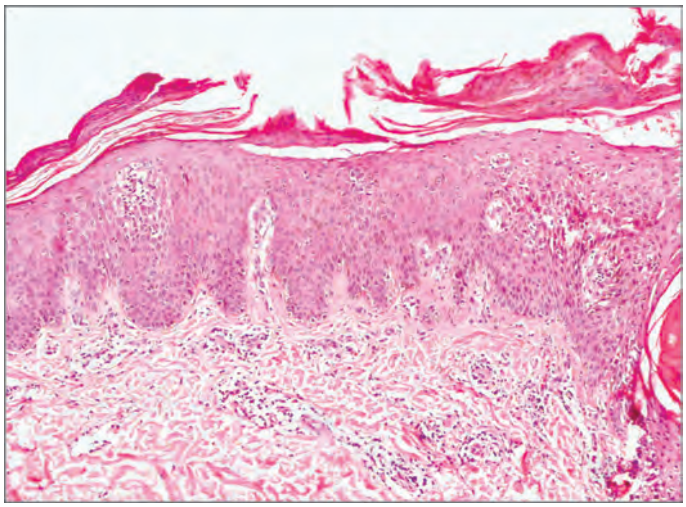

Fig. 3: Lymphocytic exocytosis: Intraepidermal lymphocytes seen in areas of spongiosis (H&E, ×200).

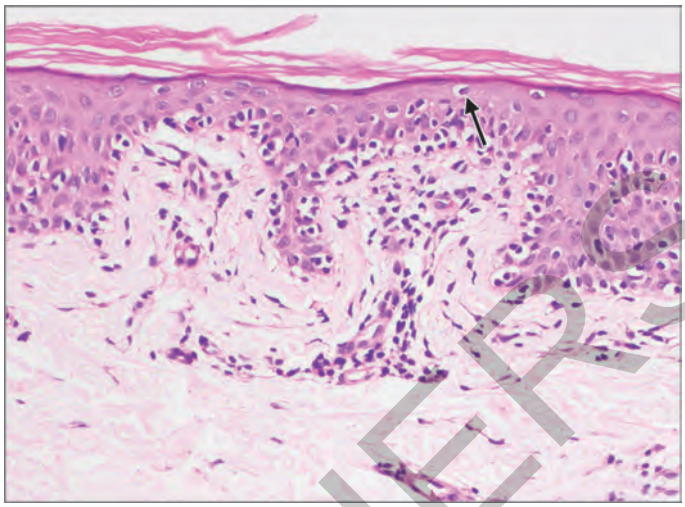

Fig. 4: Epidermotropism: Intraepidermal lymphocytes (arrow) with little or no spongiosis. Note the halo around lymphocytes in the epidermis (H&E, ×200). *Image courtesy*: Dr Sudheer Arava.

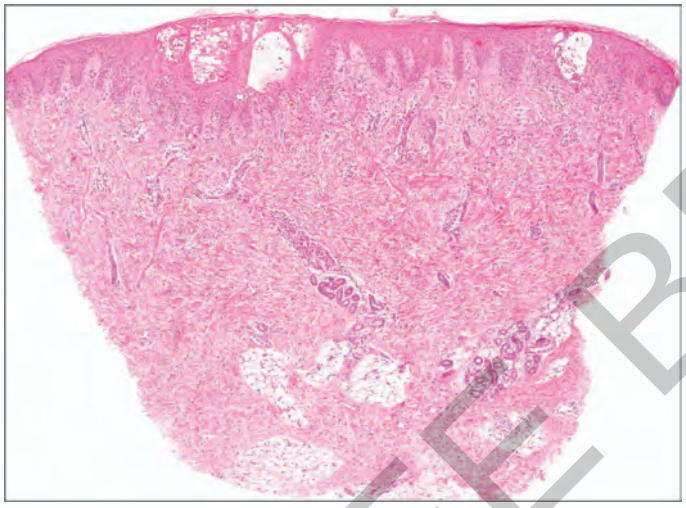

Fig. 5: Acute dermatitis: Spongiotic vesicles, exocytosis, and a mild superficial dermal infiltrate (H&E, ×40).



Fig. 6: Acute dermatitis: Marked edema, erosion, and exudation with many papulo-vesicles in the adjacent skin.

Acute spongiotic reactions show significant edema without much epidermal hyperplasia **(Fig. 5)**. Spongiosis is usually prominent and spongiotic vesicles may be noted. Exocytosis of lymphocytes is seen, along with some neutrophils. There is mild and patchy hyperkeratosis often accompanied by globules of fibrin and plasma within the stratum corneum. Acanthosis is usually minimal or absent. There is marked papillary edema accompanied by some extravasation of red blood cells and a superficial perivascular infiltrate of lymphocytes with an occasional eosinophil.

Clinically, acute dermatitis presents as brightly erythematous, exudative and crusted papules, papulo-vesicles, and plaques with severe burning, discomfort, and itch **(Fig. 6)**.

Subacute spongiotic reactions show patchy parakeratosis overlying focal spongiosis with exocytosis of lymphocytes in a moderately acanthotic epidermis. Papillary edema is mild and there is a moderately dense superficial perivascular infiltrate of lymphocytes, histiocytes and some eosinophils **(Fig. 3)**.

Subacute dermatitis presents clinically as itchy, erythematous papules, and plaques that are relatively dry, with some exudation and crusting **(Fig. 7)**.

Chronic spongiotic reactions show features of skin that is constantly rubbed and scratched, a process known as lichenification. There is a thick and compact stratum corneum with an acanthotic epidermis that may be considerably hyperplastic in some cases **(Fig. 8)**. Spongiosis is mild and is frequently absent. The collagen in the papillary dermis is fibrotic and vertically oriented **(Fig. 9)**. The hairy palm sign refers to the resemblance of lichenified skin to skin of the palms and soles, but for the presence of pilosebaceous units which indicate that the biopsy is actually from a non-acral site **(Fig. 10)**.

JAYPEE BROTHERS

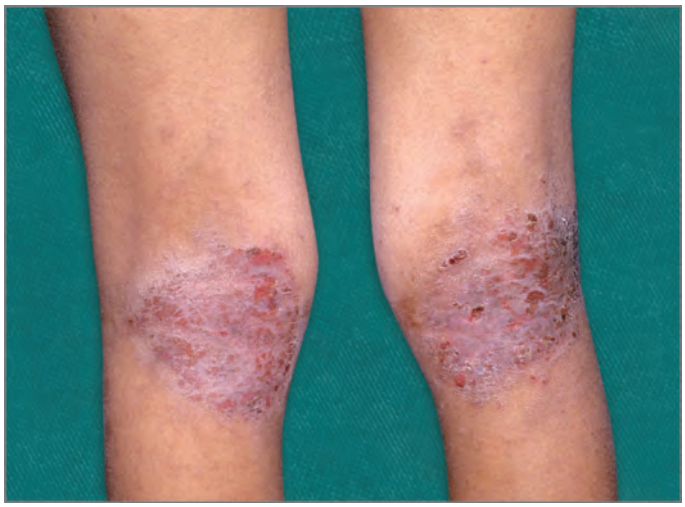

Fig. 7: Subacute dermatitis (atopic dermatitis): Symmetrical, itchy, and exudative plaques with superficial erosions in both popliteal fossae.

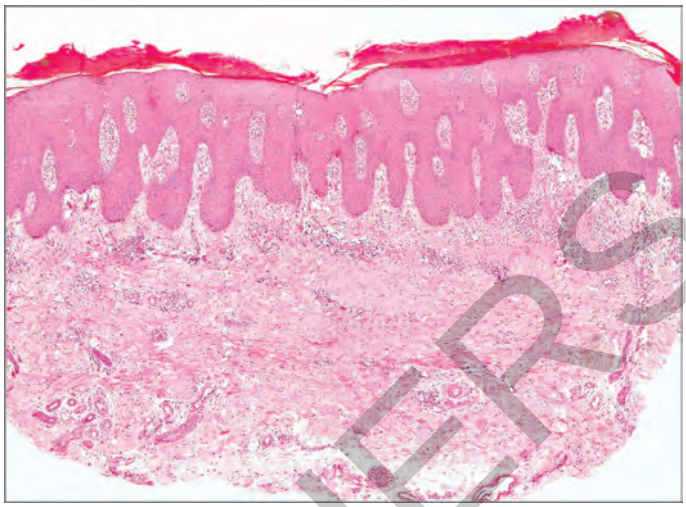

Fig. 8: Chronic spongiotic tissue reaction: Compact hyperkeratosis and acanthosis with minimal spongiosis (H&E, ×40).

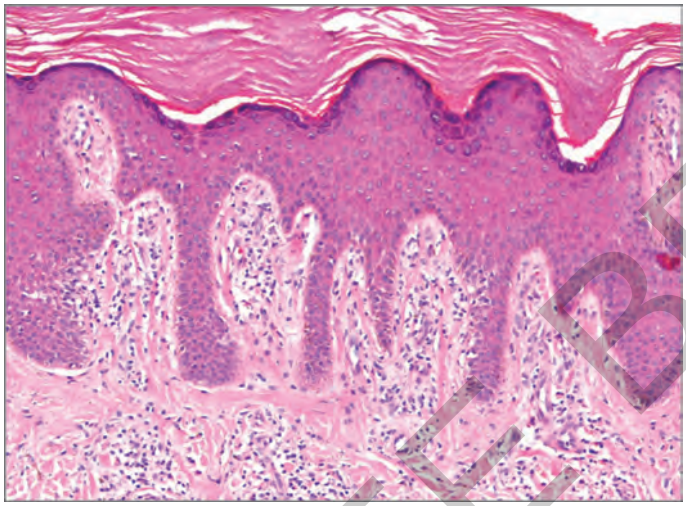

Fig. 9: Chronic spongiotic tissue reaction: Thickened and vertically oriented collagen fibers in papillary dermis (papillary dermal fibrosis) (H&E, ×400).

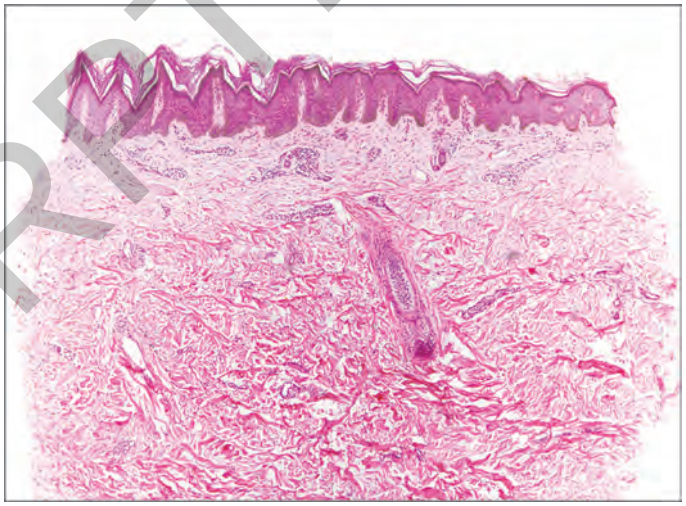

Fig. 10: "Hairy palm" sign: Epidermal features resemble palmar skin but the finding of a hair follicle indicates it is non-acral skin with lichenification (H&E, ×40).

Chronic dermatitis presents as itchy, pigmented, and thickened skin as a result of chronic scratching, referred to as lichen simplex chronicus **(Fig. 11)**. It may develop over preexisting dermatitic plaques or de novo. Prurigo nodularis, which presents as dome-shaped hyperpigmented excoriated nodules on extremities, shows similar histopathological features with prominent involvement of follicular infundibula.

The histopathological features of acute, subacute, and chronic spongiotic reactions are summarized in **Table 1**.

Another way to categorize spongiotic reactions is based on the inflammatory cell infiltrating the epidermis. Usually, this cell is the lymphocyte. In some instances, the predominant inflammatory cell extending into the epidermis is the neutrophil or eosinophil, known as neutrophilic or eosinophilic spongiosis, respectively.

Neutrophilic spongiosis is a feature of pustular psoriasis **(Fig. 12)** and its variants, some variants of pemphigus,



Fig. 11: Lichen simplex chronicus: Itchy, thickened, and hyperpigmented skin with prominent skin markings because of repeated scratching.

JAYPEE BROTHERS

TABLE 1: Histopathological features of acute, subacute, and chronic spongiotic reaction.

	Acute	Subacute	Chronic
Stratum corneum	Normal, may have fibrin crust	Focal parakeratosis, may have fibrin crust	Hyperkeratosis, parakeratosis
Epidermal thickness	Normal epidermis	Moderate acanthosis, can be irregular	Wedge-shaped hypergranulosis, moderate to marked acanthosis
Spongiosis	Variable, can be marked, spongiotic vesicles can be present	Mild-to-moderate	Minimal, focally present; can even be absent
Papillary dermal changes	Variable papillary dermal edema, can be marked, correlates with degree of spongiosis	Mild papillary dermal edema	Papillary dermal fibrosis, vertically oriented collagen bundles, sparse inflammatory infiltrate

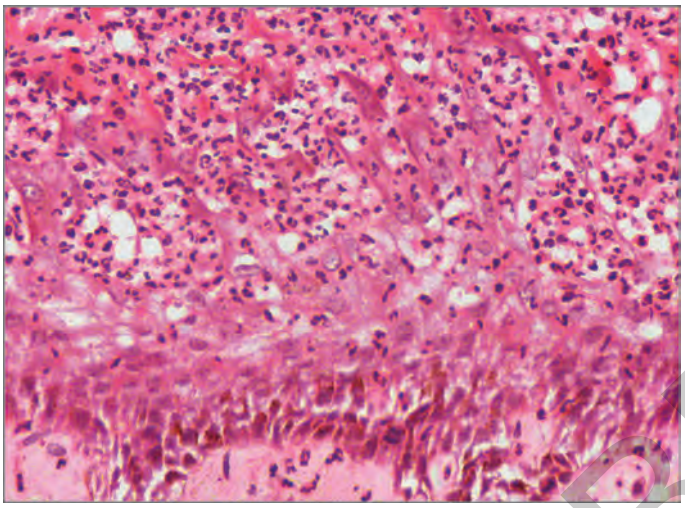

Fig. 12: Neutrophilic spongiosis: Neutrophils in the areas of spongiosis (upper layers of epidermis) in pustular psoriasis (H&E, ×400).

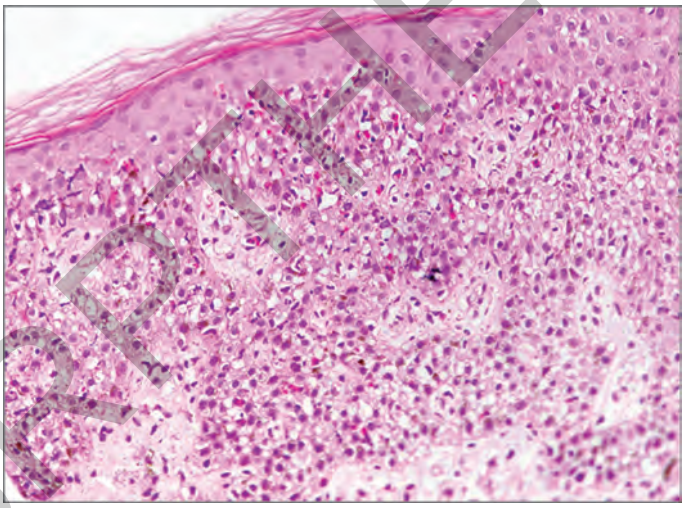

Fig. 13: Eosinophilic spongiosis: Eosinophils and an occasional neutrophil within areas of spongiosis in early pemphigus (H&E, ×400).

bacterial, and fungal infections including dermatophytosis and severe/pustular variants of eczematous dermatitis.

Eosinophilic spongiosis is seen in insect bite reactions, some drug reactions, pemphigus and pemphigoid variants **(Fig. 13)**, and the first stage of incontinentia pigmenti, among others.

Several clinically distinct eczematous disorders or dermatitides show a spongiotic tissue reaction. In addition, some non-eczematous disorders also uniformly show this reaction pattern. Some of the more common and important examples of these two groups of disorders are listed in **Table 2**.

Some clinical variants of eczematous dermatitis and non-eczematous dermatoses show typical or suggestive histopathological findings and these are described here.

TABLE 2: Examples of disorders showing the spongiotic reaction pattern.

Eczematous conditions	Non-eczematous conditions
Atopic dermatitis	Dermatophytosis
Irritant contact dermatitis	Pityriasis rosea
Allergic contact dermatitis	Palmoplantar psoriasis
Nummular dermatitis	Erythroderma
Pompholyx	Micropapular light eruption
Seborrheic dermatitis	Pityriasis alba/hypopigmenting dermatitis
Hyperkeratotic palmoplantar dermatitis	Miliaria
Beetle (*Paederus*) dermatitis	Fox–Fordyce disease
Autoeczematization	Disseminated infundibulofolliculitis
"Unclassified" eczemas	Blaschkitis
Eczematous drug reactions	Grover's disease (spongiotic variant)

ECZEMATOUS DISORDERS

Most eczematous disorders including atopic dermatitis **(Fig. 7)**, nummular dermatitis **(Fig. 14)**, allergic contact

JAYPEE BROTHERS



Fig. 14: Nummular dermatitis: Discoid dermatitic plaques on dorsum of hand.



Fig. 15: Contact dermatitis to nickel: Dermatitic plaque on lower abdomen, adjacent to the site of contact with metallic belt buckle.

dermatitis **(Fig. 15)**, auto eczematization, and eczematous drug reactions largely show the clinical and histopathological features described earlier. Some clinical variants of eczematous dermatitis show typical or suggestive histopathological findings and an account of these conditions follows.

Irritant contact dermatitis

Irritant contact dermatitis presents as a sharply delineated plaque at the site of contact with an irritant/toxic agent. The intensity of the local reaction depends on the irritant potential of the agent and may range from a mild dermatitis to necrosis. Common irritants include detergents, solvents, topical medications, dyes, and acids. Vegetables such as garlic, tomatoes, okra and onions have also been implicated.

Histopathological features vary with the nature of the irritant, including its mode of action and concentration. If the irritant is mild, the histopathological findings are those of spongiotic dermatitis, described earlier. Strong irritants can result in ballooning degeneration of keratinocytes in the upper epidermis, along with variable degrees of keratinocyte necrosis. There is mild spongiosis in the adjacent epidermis, accompanied by neutrophilic exocytosis.

Seborrheic dermatitis

Seborrheic dermatitis presents as erythematous scaly papules and plaques with a greasy yellow appearance, characteristically affecting the scalp, ears, eyebrows, upper eyelid margins, nasolabial folds, central chest, and upper back (*"seborrheic areas"*). It is usually seen during infancy or in the postpubertal period.

In addition to the histopathological features of a spongiotic tissue reaction described above, a characteristic feature of seborrheic dermatitis is the presence of a focal scale-crust centered around the hair follicle, especially in early lesions.



Fig. 16: Pompholyx: Multiple deep-seated vesicles and bullae on palm and fingers in an unusually severe case.

Pompholyx

Pompholyx (*synonym*: acral vesicular dermatitis and dyshidrotic eczema) presents as recurrent itchy deep-seated vesicles on the palms and soles, and on the sides of fingers and toes **(Fig. 16)**. It is believed to be a clinical reaction pattern with several suspected underlying triggers such as atopy, infections, systemic contact sensitivity, smoking, and stress.

Biopsy from a lesion of pompholyx shows large spongiotic blisters in the epidermis. An interesting histopathological finding is the relatively mild spongiosis in the epidermis adjacent to these blisters **(Figs. 17 and 18)**. The overlying stratum corneum is thick, as expected in biopsies from the palms and soles. The dermis shows a perivascular infiltrate of lymphocytes and histiocytes.

JAYPEE BROTHERS

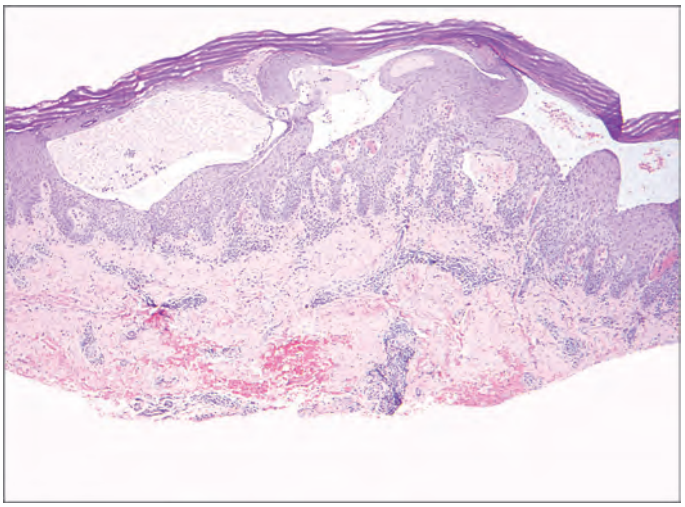

Fig. 17: Pompholyx: Multiple, large, spongiotic vesicles in the epidermis of acral skin (H&E, ×40). *Image courtesy*: Dr Meenakshi Batrani

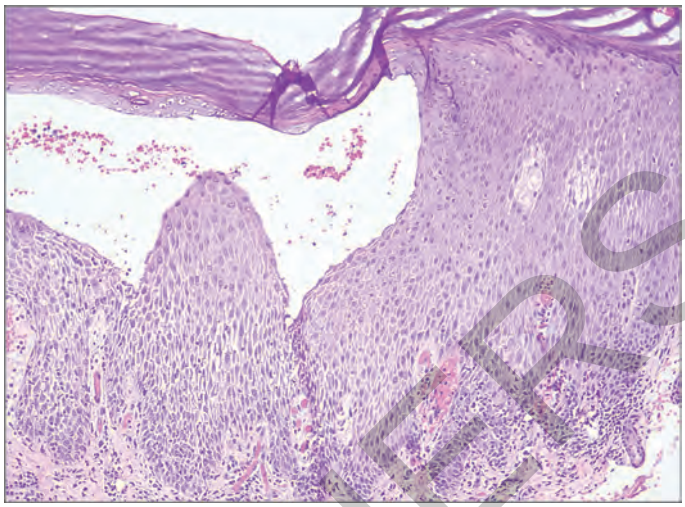

Fig. 18: Pompholyx: Large spongiotic vesicle with relatively mild spongiosis in the underlying and adjacent epidermis (H&E, ×400). *Image courtesy*: Dr Meenakshi Batrani.



Fig. 19: Hyperkeratotic hand dermatitis: Hyperkeratotic, dry, and fissured plaques on palms and fingers.

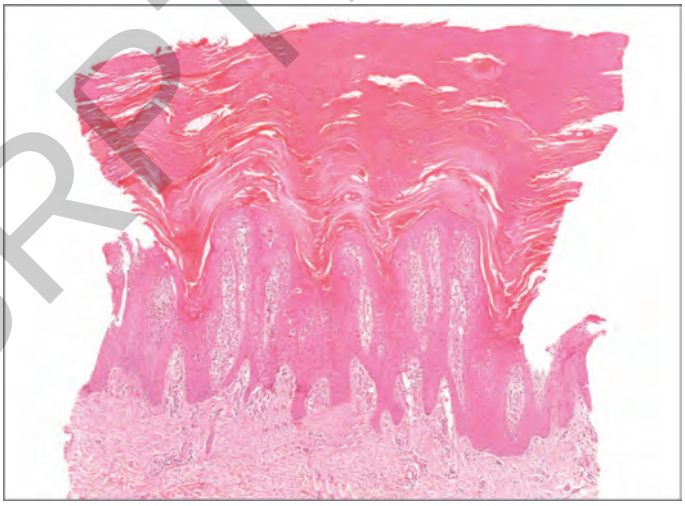

Fig. 20: Hyperkeratotic hand dermatitis: Hyperkeratosis, papillomatosis, spongiosis, papillary dermal edema, and dermal infiltrates on acral skin, features of subacute spongiotic reaction pattern (H&E, ×40).

Hyperkeratotic hand and foot dermatitis

Hyperkeratotic dermatitis of the hand and feet presents as fissured hyperkeratotic plaques on the palms, and less frequently, the soles **(Fig. 19)**. It can often be difficult to distinguish from psoriasis confined to the palms and soles.

Biopsy shows features of a subacute spongiotic dermatitis with hyperkeratosis, parakeratosis, fibrin in the stratum corneum, acanthosis, spongiosis and spongiotic vesicles, exocytosis of lymphocytes and histiocytes, papillary dermal edema, and an upper dermal infiltrate of lymphocytes and histiocytes **(Fig. 20)**.

Biopsy is sometimes taken to distinguish hyperkeratotic dermatitis from psoriasis on the palms or soles. However, the histopathological features of both diseases are nearly identical making this a futile exercise in most cases.

Even though many of the eczematous disorders are clinically distinct, specific histopathological clues to the etiology of the spongiotic dermatitis are usually not found and the final diagnosis requires clinical correlation. In this context, a biopsy report should not overreach and say, e.g., that the histopathological features are those of allergic contact dermatitis because it is not possible to distinguish it from atopic dermatitis or nummular dermatitis on skin biopsy. It is wiser to report it as a spongiotic tissue reaction and state in a note that clinical findings and ancillary investigations may be required to reach a specific diagnosis. Even though this may appear unsatisfactory, it is more accurate. Besides, recognizing a spongiotic tissue reaction can help to exclude other entities.

JAYPEE BROTHERS

NON-ECZEMATOUS CONDITIONS THAT SHOW A SPONGIOTIC PATTERN

Palmoplantar psoriasis

Psoriasis on the palms and soles shows a histopathological picture quite different from psoriasis at other sites. Even in cases where there is no doubt about the diagnosis because of the coexistence of psoriasis at other sites, biopsy from palmar lesions can show a florid spongiotic tissue reaction.

Dermatophytosis

Dermatophytic infections (*synonym*: tinea) classically present as erythematous annular plaques with peripheral papules and scaling.

Histopathology shows epidermal hyperplasia and spongiosis accompanied by neutrophilic exocytosis. The stratum corneum shows fungal hyphae sandwiched between orthokeratotic stratum corneum on top and compact or parakeratotic stratum corneum below *(sandwich sign)*. Apart from the epidermis, neutrophils can be seen within the stratum corneum as well (similar to psoriasis), and this should prompt a search for fungal hyphae both on hematoxylin and eosin (H&E) and periodic acid–Schiff reaction (PAS) stains. The dermis shows a variable inflammatory infiltrate with a perivascular or diffuse mixed infiltrate composed of lymphocytes, histiocytes, and neutrophils.

Pityriasis rosea

Pityriasis rosea is a common, asymptomatic, rapidly evolving eruption characterized by oval, scaly, annular plaques and papules on the trunk and proximal extremities. The eruption usually begins with a single large plaque, the herald patch, followed by multiple lesions about a week later. The eruption resolves spontaneously in 4–8 weeks.

Histopathology shows features of a subacute spongiotic tissue reaction with parakeratosis, mild acanthosis, spongiosis, and exocytosis. There are mounds of parakeratosis adjacent to or overlying the spongiosis. This parakeratotic stratum corneum shows elevation and separation from the rest of the stratum corneum, while being attached on the other side (corresponding to the "collarette" of scale). There is edema of the papillary dermis with some extravasation of RBCs that may extend into the lower dermis. There is a mild-to-moderate superficial perivascular infiltrate of lymphocytes and histiocytes with some eosinophils in the upper dermis.

Erythema annulare centrifugum

Erythema annulare centrifugum (EAC) presents as solitary or multiple erythematous lesions which spread centrifugally. The lesions exhibit a fine scale inner to the advancing edge of the lesion, called a trailing scale.

Biopsy from the advancing edge of the lesion shows focal spongiosis and parakeratosis. There is a well-defined, tight perivascular infiltrate of lymphocytes and histiocytes in the upper dermis in a pattern referred to as coat-sleeving.

Pityriasis alba, hypopigmenting dermatitis

Pityriasis alba presents as hypopigmented, slightly scaly patches of variable size, usually involving the face in children. Biopsy shows prominent spongiosis confined to the follicular epithelium with minimal involvement of the surface epidermis. However, some workers have reported only mild epidermal spongiosis with minimal exocytosis and focal parakeratosis of the epidermis.

Hypopigmenting dermatitis is a recently described entity that presents as hypopigmented macules with overlying follicular prominence/papules and lesional hair loss on the upper extremities and trunk **(Fig. 21)**. The macules are often mistaken for leprosy, hypopigmented mycosis fungoides, early vitiligo, or other disorders of hypopigmentation. Histopathology is characterized by follicular spongiosis and lymphocytic exocytosis **(Fig. 22)**. There may be some



Fig. 21: Hypopigmenting dermatitis: Hypopigmented macule on the chest with loss of hair.

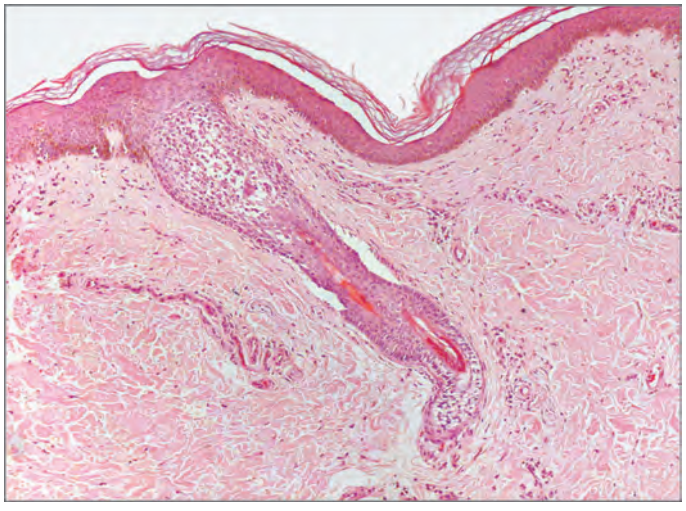

Fig. 22: Follicular spongiosis: Spongiosis and exocytosis of lymphocytes in the follicular epithelium. Note the absence of spongiosis in the adjacent epidermis (H&E, ×100).

JAYPEE BROTHERS

spongiosis of the adjacent epidermis as well. The similarity of both the histopathology and clinical presentation has led to the suggestion that hypopigmenting dermatitis may be a truncal variant of pityriasis alba.

Other disorders presenting with follicular spongiosis

Spongiosis and exocytosis of the follicular epithelium may be noted as an incidental finding in a number of unrelated disorders, but is the typical or main finding in a few diseases including follicular atopic dermatitis, seborrheic dermatitis, eosinophilic folliculitis, disseminated infundibulofolliculitis, and Fox–Fordyce disease.

Infundibulofolliculitis presents as an itchy, recurrent, follicular, papular eruption commonly involving the trunk and proximal parts of the extremities. Some patients may have an atopic tendency. On histopathology, the follicular infundibulum shows spongiosis and exocytosis of lymphocytes, along with a few neutrophils as well. There is widening of the follicular ostium and focal parakeratosis of the adjacent epidermis.

Fox–Fordyce disease, also known as apocrine miliaria, presents at puberty as itchy, skin colored, follicular papules in the axillae, around the areola and in the genitals. It is believed to occur due to obstruction of the apocrine duct due to keratin accumulation in the follicular infundibulum. Histopathology shows follicular spongiosis with a mild lymphocytic infiltrate adjacent to the entry of the apocrine duct into the hair follicle. Perifollicular foamy histiocytes can also be seen occasionally.

Miliaria

Miliaria occurs due to obstruction of sweat flow in the epidermis. In miliaria crystallina, the obstruction is at the level of the stratum corneum; in the most common type, miliaria rubra, the obstruction is at the level of the spinous layer; and in miliaria profunda, at the level of the dermo-epidermal junction.

These conditions are rarely biopsied. Miliaria rubra and profunda show variable spongiosis and spongiotic vesiculation within the sweat duct units and the surrounding epidermis, along with a small number of lymphocytes. An orthokeratotic or parakeratotic plug overlies spongiotic foci. The papillary dermis shows edema and a mild lymphocytic infiltrate around the sweat ducts. Miliaria crystallina shows a vesicle within or directly beneath the stratum corneum and a PAS-positive plug may occlude the distal sweat pore.

SUGGESTED READING

1. Bhatia R, Gupta V, Arava S, Khandpur S, Ramam M. Macular hypopigmentation, hair loss and follicular spongiosis: a distinct clinicopathological entity. Indian J Dermatol Venereol Leprol. 2020;86:386-91.
2. Gru AA, Salavaggione AL. Common spongiotic dermatoses. Semin Diagn Pathol. 2017;34:226-36.
3. Gupta K. Deciphering spongiotic dermatitides. Indian J Dermatol Venereol Leprol. 2008;74:523-6.
4. Rao A, Khandpur S, Kalaivani M. A study of the histopathology of palmo-plantar psoriasis and hyperkeratotic palmo-plantar dermatitis. Indian J Dermatol Venereol Leprol. 2018;84:27-33.

JAYPEE BROTHERS

for detailed information on dermatology books, visit our website www.jaypeebrothers.com, for detailed information on dermatology books, visit our website www.jaypeebroth

IADVL Textbook of Dermatopathology

Easy to read and understand, profusely illustrated with high-quality photomicrographs and clinical images, this new textbook of dermatopathology will change the way you think about a subject that is often considered difficult and dry. The book is comprehensive but a special effort has been made to be comprehensible to trainees in dermatology and pathology and to consultants in both specialties who are unfamiliar with the field.

Written in a refreshingly practical style by authors who have hands-on experience with the clinicopathological problems encountered in daily practice, the book will be of special value to practicing dermatopathologists and pathologists as it addresses commonly encountered challenges and provides many tips and tricks to deal with them.

Professor M Ramam, Professor Sujay Khandpur, Dr Neetu Bhari and **Dr Vishal Gupta**, the editors, are faculty members in the Department of Dermatology and Venereology at the All India Institute of Medical Sciences, New Delhi where they provide dermatopathology services including teaching and research, in addition to their clinical duties.

Professor Ramam and Professor Khandpur undertook external fellowships in dermatopathology and Dr Bhari and Dr Gupta received dermatopathology training in the department. They have all served in the Special Interest Group, Dermatopathology of the Indian Association of Dermatologists, Venereologists and Leprologists (IADVL) in different capacities and have been members and office bearers of the Dermatopathology Society of India.

Printed in India

Available at all medical bookstores or buy online at www.jaypeebrothers.com

JAYPEE BROTHERS
Medical Publishers (P) Ltd.
EMCA House, 23/23-B, Ansari Road,
Daryaganj, New Delhi - 110 002, INDIA
www.jaypeebrothers.com

Join us on facebook.com/JaypeeMedicalPublishers

Shelving Recommendations
DERMATOLOGY, PATHOLOGY

ISBN 978-93-5465-384-1