bsite www.jaypeebrothers.com, for detailed information on neurosurgery books, visit our website www.jaypeebrothers.com, for detailed information on neurosurgery books, visit our website www.jaypeebrothers.com

Operative Manual of N

A St

Volume 2

Editor-in-Chi
Balaji Pai S

Assistant Edit
Asima Banu
Sandesh Kha

Forewords
AS Hegde
S Kalyanarama

bsite www.jaypeebrothers.com, for detailed information on neurosurgery books, visit our website www.jaypeebrothers.com, for detailed information on neurosurgery books, visit our website www.jaypeebrothers.com

Operative Manual of Neurosurgery

A Step by Step Pictorial Atlas

Volume 1

Editor-in-Chief
Balaji Pai S

Assistant Editors
Asima Banu
Sandesh Khandelwal

Forewords
AS Hegde
S Kalyanaraman

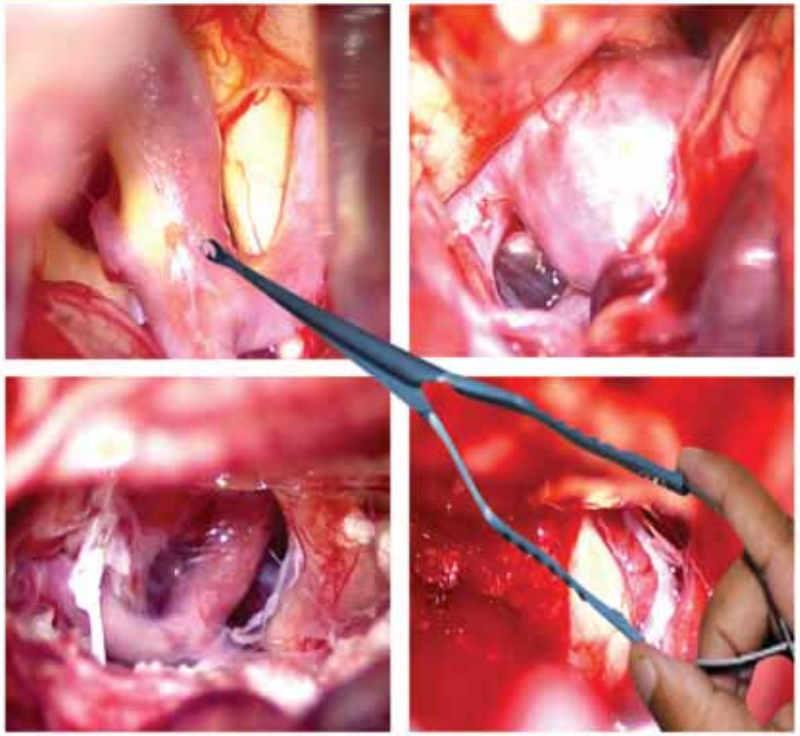

JAYPEE

Contents

Volume 1

Section 1: Preoperative and Intraoperative Consideration

1. **Preoperative Investigations** 3
   Vinay Marulasiddappa
2. **Normal Magnetic Resonance Imaging Anatomy of the Brain and Spine** 9
   Vijay Kumar KR
3. **Anesthesia Techniques** 29
   Vinay Marulasiddappa
4. **Patient Positioning in Neurosurgery** 38
   Murali Mohan, Balaji Pai S
5. **Intraoperative Monitoring** 48
   Vinay Marulasiddappa, Saraswathi N
6. **Awake Craniotomy and Anesthesia** 50
   Raghavendra BS
7. **Trolley and Instrument Preparation** 54
   Sandesh Khandelwal, Shylu Priyadarshini, Balaji Pai S
8. **Instrumentation** 58
   Balaji Pai S, Sandesh Khandelwal
9. **Intraoperative Angiography** 67
   Balaji Pai S

Section 2: Basic Techniques

10. **Burr Hole and Evacuation of Hematoma** 73
    Sandesh Khandelwal, Balaji Pai S, Pratham Bysani
11. **Pterional Craniotomy** 77
    Balaji Pai S, Vikas Naik
12. **Suboccipital Craniectomy** 82
    Balaji Pai S
13. **Decompressive Craniectomy** 95
    Sandesh Khandelwal, Balaji Pai S
14. **Subfrontal Approach** 99
    Balaji Pai S
15. **Supraorbital Craniotomy Approach** 106
    Balaji Pai S, Vishwanath Narayana
16. **Fronto-orbitotomy and Frontotemporo-orbitozygotomy (FTOZ)** 123
    Balaji Pai S, Ravi Gopal Varma
17. **Hemostatic Agents in Neurosurgery** 132
    Sandesh Khandelwal, Nagesh SA, Balaji Pai S

Section 3: Trauma

18. **Depressed Fracture** 143
    Dhaval Shukla, Mohammed Nadeem, Balaji Pai S
19. **Extradural Hematoma** 147
    Balaji Pai S
20. **Acute Subdural Hematoma** 155
    Balaji Pai S, Pratham Bysani
21. **Traumatic Intracerebral Hematoma and Contusion** 161
    Balaji Pai S
22. **Transcranial Repair of Cerebrospinal Fluid Rhinorrhea** 165
    Balaji Pai S
23. **Surgery for Skull Base Cerebrospinal Fluid Rhinorrhea** 174
    Amit Keshri, Vandan Raiyani, Pawan K Verma, Neha Singh, Surendra Singh Baghel, Kuntal Kanti Das
24. **Endoscopic Repair of Cerebrospinal Fluid Rhinorrhea** 184
    Richa Agrawal, Shrikant Phatak, Abhik Sikdar
25. **Posterior Fossa Hematoma** 189
    Pratham Bysani, Balaji Pai S
26. **Endoscopic Optic Nerve Decompression in Traumatic Optic Neuropathy** 192
    Kanika Arora, Aditi Mehta, Ramandeep Singh Virk, Ravi Sankar Manogaran, Raghab Sedai

Section 4: Tumors

27. **Classification of Brain Tumors** 209
    Anitha Mahadevan, Shilpa Rao
28. **Surgery for Intra-axial Brain Tumors (Gliomas)** 222
    Balaji Pai S

JAYPEE BROTHERS

29. Surgery for Convexity Meningioma 231
Balaji Pai S

30. Surgery for Parasagittal and Falx Meningiomas 237
Balaji Pai S

31. Same Side Down Approach 255
Balaji Pai S

32. Transcallosal and Transcortical Approaches for Colloid Cyst 263
Venkatramana NK

33. Surgery for Anterior Third Ventricular Tumors 272
Balaji Pai S

34. Supratentorial Infraoccipital (Transtentorial) Approach 291
Balaji Pai S

35. Infratentorial Supracerebellar Approach 300
Balaji Pai S

36. Peritrigonal High-grade Glioma 307
Priyadarshi Dikshit, Amanjot Singh Boparai, Vikas Dwivedi, Mayank Singh, Ved Prakash Maurya, Kamlesh Singh Bhaisora, Sanjay Behari

37. Transopercular and Trans-Sylvian Approaches for Resection of Giant Insular Gliomas 315
Aliasgar V Moiyadi, Chandrima Biswas, Harshal Agarwal, Kanchi Jain, Parthiban Velayutham

38. Surgery for Cerebellar Tumors 341
Balaji Pai S

39. Surgery for Cerebellopontine Angle Tumors—Retrosigmoid Approach 359
Ravi Mohan Rao, Karthik M, Karthikeyan Y, Shivanna V, Santosh CK, Phanishekar KR, Belliappa MS, Ajith Kumar

40. Surgical Excision of Foramen Magnum Tumors (Far-lateral Approach) 374
Balaji Pai S

41. Surgical Approaches and Excision of an Exophytic Brainstem Glioma 389
Ashutosh Kumar, Kamlesh Singh Bhaisora, Kuntal Kanti Das, Sanjay Behari

42. Excision of Tentorial Meningioma 400
Balaji Pai S

Section 5: Skull Base Surgery

43. Surgical Excision of Olfactory Groove Meningioma 411
Balaji Pai S

44. Craniofacial Resection 420
Balaji Pai S, Sujay Rao, R Deo

45. Excision of Sphenoid Wing Meningiomas 439
Balaji Pai S

46. Surgery of Trigeminal Schwannomas 457
Dwarakanath Srinivas, Jitender Chaturvedi

47. Combined Middle Cranial Fossa and Posterior Cranial Fossa Approach 462
Balaji Pai S

48. Surgery of Cavernous Sinus Lesions 475
Rajneesh Kachhara, Pulak Nigam

49. Transsphenoidal Approach to Sellar and Suprasellar Lesions 495
Balaji Pai S

50. Transcranial Approach to Sellar and Suprasellar Tumors 518
Balaji Pai S

51. Surgical Management of Glomus Jugulare 536
Balaji Pai S

52. Extended Frontobasal Approach 556
Balaji Pai S

53. Nasopharyngeal Angiofibroma 568
Srinath N, Balaji Pai S, Ankita Dahiya

54. Excision of Clinoidal Meningioma 580
Balaji Pai S

55. Tuberculum Sella Meningioma Excision 587
Balaji Pai S

56. Excision of Planum Sphenoidale Meningioma 603
Balaji Pai S

57. Staged Subtotal Excision of Large Skull Base Meningioma via Transfacial Approach 609
Arun K Govind, Ramandeep Singh Virk, Kanika Arora, Gyanaranjan Nayak, Ravi Sankar Manogaran

58. Transfacial Approach for an Extensive Facial Hemangioma with Infraorbital and Infratemporal Fossa Extension 623
Ravi Sankar Manogaran, Govind S Bhuskute, Anant Mehrotra, Arulalan Mathialagan, Abhishek Kumar Dubey, Sanjay Behari

59. Translabyrinthine Approach—A Comprehensive Look into Cerebellopontine Angle Lesions 638
Sampath Chandra Prasad Rao, Sohini Chakrabarti, Ganga Kamath

60. External Auditory Canal Squamous Cell Carcinoma: Piecemeal Lateral Temporal Bone Resection with Submental Flap Reconstruction 653
Ravi Sankar Manogaran, Neha Singh, Surendra Singh Baghel, Amit Keshri, Sanjay Behari

JAYPEE BROTHERS

Section 6: Vascular Surgery

61. **Basic Clipping Techniques** 671
Girish Menon, Aseem Pradhan

62. **Posterior Communicating Artery and Anterior Choroidal Artery (Mid Carotid Area) Aneurysm Clipping** 689
Balaji Pai S

63. **Surgery for Paraclinoid Aneurysms** 697
Balaji Pai S, Nagarjun MN

64. **Internal Carotid Artery Bifurcation Aneurysms** 719
Rajneesh Kachhara, Pulak Nigam

65. **Clipping of Middle Cerebral Artery Aneurysm** 727
Balaji Pai S

66. **Clipping of Anterior Communicating Artery Aneurysm** 737
Balaji Pai S, Chandramouli BA

67. **Clipping of Distal Anterior Cerebral Artery Aneurysm** 749
Balaji Pai S

68. **Posterior Circulation Aneurysms** 759
Maruti Nandan, Yashveer Singh, Ved Prakash Maurya, Kamlesh Singh Bhaisora, Priyadarshi Dikshit, Kuntal Kanti Das, Sanjay Behari

69. **Clipping of Basilar Bifurcation Aneurysms** 771
Girish Menon

70. **Vertebral Artery: Posterior Inferior Cerebellar Artery Aneurysms** 778
Rajneesh Kachhara, Pulak Nigam

71. **Clipping of Vertebral Artery Aneurysm** 785
Balaji Pai S

72. **General Principles in the Surgical Management of a Patient with Multiple Cerebral Aneurysms** 796
Balaji Pai S

73. **Arteriovenous Malformations: General Techniques** 804
Rajneesh Kachhara, Pulak Nigam

74. **Surgical Excision of Large Cerebral Arteriovenous Malformations** 812
Balaji Pai S

75. **Surgery for Spontaneous Intracerebral Hematoma** 830
Balaji Pai S

76. **Carotid Endarterectomy–I** 839
Komal Prasad Chandrachari

77. **Carotid Endarterectomy–II** 843
Sanjay Desai, Balaji Pai S

78. **Superficial Temporal Artery to Middle Cerebral Artery Bypass** 848
Paritosh Pandey

Volume 2

Section 7: Neuroendoscopy

79. **The Neuroendoscope** 857
Anandh Balasubramaniam

80. **Endoscopic Third Ventriculostomy** 866
Anandh Balasubramaniam

81. **Neuroendoscopic Management of Intra- and Paraventricular Cysts** 871
Subhas Konar, Dhaval Shukla

82. **Endoscopic Excision of Colloid Cyst** 880
Venkatramana NK

83. **Endoscopic Pituitary Surgery** 886
Venkatramana NK

84. **Endoscopic Surgical Procedures in Management of Craniopharyngiomas** 894
Chandrashekhar E Deopujari, Salman Shaikh, Krishna Shroff, Vikram Karmarkar, Chandan Mohanty, Nishit Shah

85. **Clival Chordoma Excision via Extended Endonasal Transsphenoidal Approach** 913
Awadhesh Kumar Jaiswal, Arulalan Mathialagan, Ravi Sankar Manogaran, Bhawan Nangarwal, Vandan Raiyani, Kuntal Kanti Das, Anant Mehrotra

86. **Endoscopic Extended Skull Base Approach for Skull Base Lesions** 926
Venkatramana NK, Prahlad NB, Pradeep Hosmani

87. **Endoscope-assisted Microneurosurgery** 935
Chandrashekhar E Deopujari, Anirudha Bhagwat, Krishna Shroff, Vikram Karmarkar, Chandan Mohanty

88. **Role of Visual Evoked Potentials in Anterior Skull Base Lesions during Extended Endonasal Transsphenoidal Tumor Resections** 957
Aditi Mehta, Ramandeep Singh Virk, Rajesh Chhabra, Ravi Sankar Manogaran, Apinderpreet Singh, Kanika Arora

Section 8: Orbital Approaches

89. **Surgical Approaches to the Orbit** 975
Venkatramana NK

90. **Superior and Transcranial Approach to Orbital Lesions** 989
Balaji Pai S

JAYPEE BROTHERS

Section 9: Epilepsy Surgery

91. **Anterior Temporal Lobectomy with Amygdalohippocampectomy and Selective Amygdalohippocampectomy** 1007
Girish Menon, Biji Bahuleyan

92. **Corpus Callosotomy** 1016
Kamlesh Vasant Rangari, Anant Mehrotra, Jayesh Sardhara

93. **Functional Hemispherotomy: Vertical Parasagittal Hemispherotomy (Delalande Procedure)** 1025
Jayesh Sardhara, Anant Mehrotra, Ashutosh Kumar, Vinita Elizabeth Mani, Bhawan Nangarwal

94. **Vagal Nerve Stimulation** 1033
Pratham Bysani

Section 10: Stereotaxy

95. **Stereotactic Instruments and Navigation-guided Biopsy** 1047
Ravi Gopal Varma, Nirmala S

96. **Deep Brain Stimulation** 1056
Ravi Gopal Varma, Nirmala S

Section 11: Pediatric Neurosurgery

97. **Ventriculoperitoneal Shunt** 1073
Balaji Pai S

98. **Encephalocele** 1089
Balaji Pai S

99. **Surgical Management of Craniosynostosis** 1111
Chidambaram B

Section 12: Surgery for Craniovertebral Junction

100. **C1-C2 Posterior Stabilization using the C1 Lateral Mass and C2 Pedicle Screw** 1147
Balaji Pai S

101. **Posterior C1 Lateral Mass-C2 Pars Screw and Rod Fixation** 1161
Rahul Srinivasan, Arun Srivastava, Jayesh Sardhara, Aachal Datta, Amanjot Singh Boparai, Sanjay Behari

102. **Posterior Occipitocervical Stabilization** 1171
Balaji Pai S

103. **Transoral Odontoidectomy** 1180
Balaji Pai S

104. **Transoral Bony Decompression for Craniovertebral Junction Lesions** 1192
Rahul Srinivasan, Sanjay Behari, Amanjot Singh Boparai, Guramritpal Singh, Arun Srivastava, Jayesh Sardhara

105. **Anterior Retropharyngeal Approach to Upper Cervical Spine** 1206
Parthiban JKBC

106. **Anterior Atlantoaxial Stabilization** 1210
Sushil Patkar, Pradnya Patkar

107. **Anterior Odontoid Screw Fixation** 1219
Balaji Pai S

Section 13: Cervical Spine

108. **Anterior Cervical Microdiscectomy** 1233
Balaji Pai S

109. **Anterior Cervical Discectomy and Fusion** 1242
Parthiban JKBC

110. **Cervical Corpectomy and Fusion** 1254
Balaji Pai S

111. **Cervical Arthroplasty** 1266
Balaji Pai S

112. **Cervical Laminectomy** 1277
Sandesh Khandelwal, Balaji Pai S

113. **Cervical Laminoplasty** 1283
Balaji Pai S

114. **Cervical Lateral Mass Fixation** 1293
Balaji Pai S

115. **Posterior Cervical Microdiscectomy** 1304
Balaji Pai S

Section 14: Thoracolumbar Spine

116. **Supraclavicular Transmanubrial Approach to Cervicothoracic Junction** 1313
Balaji Pai S, Srihari BG

117. **Anterolateral Approach to Thoracic Spine (Transthoracic)** 1322
Balaji Pai S, Amresh Bhaganagare S, Patil MD

118. **Transdiaphragmatic Approach to the Thoracolumbar Spine** 1331
Balaji Pai S, Amresh Bhaganagare S, Patil MD

JAYPEE BROTHERS

119. Pedicle Screw Rod Fixation (Posterior) 1338
Balaji Pai S, Parthiban JKBC

120. Posterior Kyphotic Correction 1349
Vikas Naik, Balaji Pai S, Dilip Gopalakrishnan

Section 15: Lumbosacral Spine

121. Microlumbar Discectomy 1361
Balaji Pai S

122. Endoscopic Discectomy 1369
Balaji Pai S

123. Lumbar Laminectomy and Discectomy 1380
Balaji Pai S, Sandesh Khandelwal

124. Transforaminal Lumbar Interbody Fusion 1385
Mahesh Bijwara, Upendra Bidre, Raghavendra Rao D

125. Posterior Lumbar Interbody Fusion 1392
Balaji Pai S

126. Anterior Spine Stabilization of Lumbar Spine 1409
Sundaresh DC, Darshan K Jain

Section 16: Spine: Tumors and Vascular

127. Surgical Excision of Intradural Extramedullary Tumors 1419
Balaji Pai S

128. Surgical Excision of Intramedullary Tumors 1433
Balaji Pai S

129. Surgical Management of Spinal Arteriovenous Malformations 1445
Balaji Pai S

Section 17: Spinal Dysraphism

130. Myelomeningocele 1469
Venkatramana NK

131. Surgery for Release of Tethered Cord 1473
Balaji Pai S

132. Diastematomyelia 1481
Balaji Pai S

133. Surgery for Syringomyelia 1489
Kamlesh Vasant Rangari, Priyadarshi Dikshit, Anant Mehrotra

134. Foramen Magnum Decompression 1496
Balaji Pai S

Section 18: Minimally Invasive Spine Surgery

135. Expanding Horizons of Endoscopic Spine Surgery 1509
Ashutosh Kumar, Jayesh Sardhara, Anant Mehrotra

136. Minimally Invasive "Tube-assisted" Microlumbar Discectomy 1517
Umesh Srikantha, Akshay Hari

137. Full Endoscopic Interlaminar Discectomy 1526
Umesh Srikantha, Yadhu K Lokanath

138. UBF (Unilateral Approach for Bilateral Foraminotomy) ("Over the Top" Decompression for Lumbar Canal Stenosis) 1536
Umesh Srikantha

139. Percutaneous Pedicle Screw Fixation 1549
Umesh Srikantha, Akshay Hari

140. Minimally Invasive Transforaminal Lumbar Interbody Fusion 1558
Umesh Srikantha

141. Oblique Lumbar Interbody Fusion 1570
Umesh Srikantha

142. Minimally Invasive "Tube-assisted" Posterior Cervical Laminoforaminotomy and Discectomy 1579
Umesh Srikantha, Akshay Hari

143. Percutaneous Balloon Kyphoplasty 1586
Umesh Srikantha, Yadhu K Lokanath

144. Minimally Invasive Spine Surgery Transportal Excision of Intradural Extramedullary Spinal Tumors 1592
Ajay Choudhary, Kaviraj Kaushik

Section 19: Peripheral Nerve Surgery

145. General Principles of Peripheral Nerve Surgery 1601
Peddi Manjunath, Astha Sarda, Shankarappa M

146. Nerve Transfers in the Management of Brachial Plexus Injuries 1608
Prem S Bhandari

147. Carpal Tunnel Release 1615
Komal Prasad Chandrachari

Section 20: Miscellaneous

148. Primary Excision of Brain Abscess 1621
Sandesh Khandelwal, Balaji Pai S

149. Microvascular Decompression 1627
Balaji Pai S

JAYPEE BROTHERS

150. **Thecoperitoneal Shunt (Lumbar Peritoneal Shunt)** 1641
Balaji Pai S, Sandesh Khandelwal

151. **Scalp Arteriovenous Malformations** 1650
Lingaraju N, Balaji Pai S

152. **External Ventricular Drain** 1655
Sandesh Khandelwal, Balaji Pai S

153. **Postoperative Neurosurgery Infections** 1658
Asima Banu

Section 21: Postoperative Management

154. **Postoperative Management of Neurosurgical Patients in ICU** 1681
Raghavendra BS

155. **Intracranial Pressure Monitoring** 1684
Balachandar Deivasigamani, Yashveer Singh, Soumen Kanjilal, Ved Prakash Maurya

Index *I-1–I-12*

JAYPEE BROTHERS

CHAPTER

66

Clipping of Anterior Communicating Artery Aneurysm

Balaji Pai S, Chandramouli BA

JAYPEE BROTHERS

INTRODUCTION

Anterior communicating artery (AComA) aneurysm is one of the most common cerebral aneurysms and neurosurgeons are required to address these surgically quite often. Clipping of these aneurysms can be challenging due to the various vital structures surrounding these aneurysms. The complex morphology of these aneurysms too adds to the surgeon's difficulties. The various characteristics of these aneurysms are beyond the purview of this chapter but the operating surgeon should have a thorough working knowledge of the anatomy of this region along with some of the common variations. According to the authors, a clear exposure of this entire area is necessary for effective clipping of an AComA aneurysm. There are various surgical techniques employed by different neurosurgeons for this surgical procedure. The steps described here are those advocated by the authors and by no means are any claims made that they are the best.

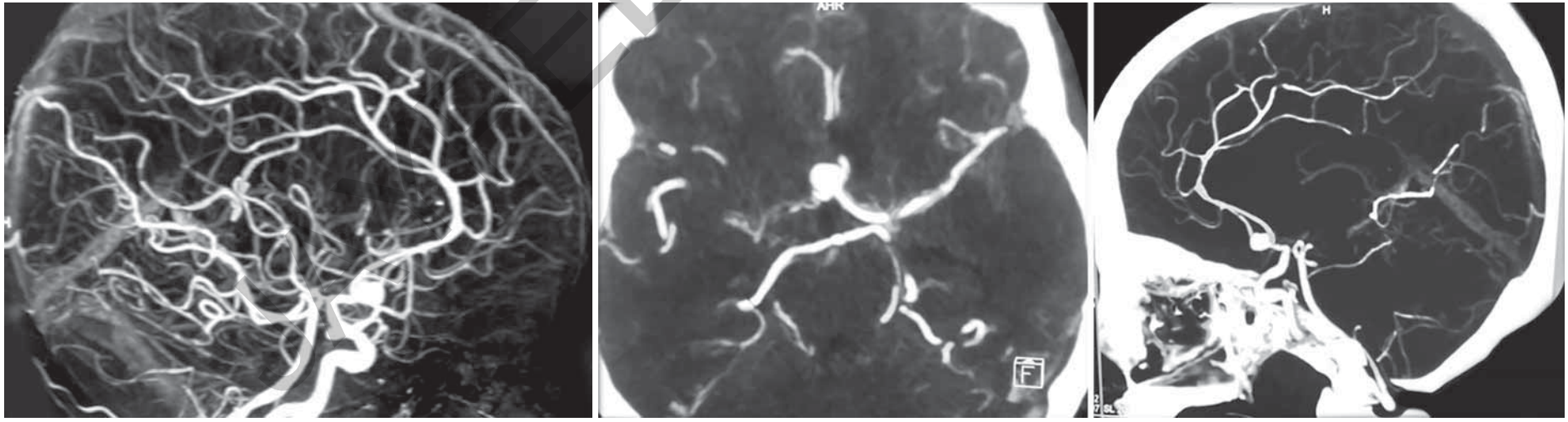

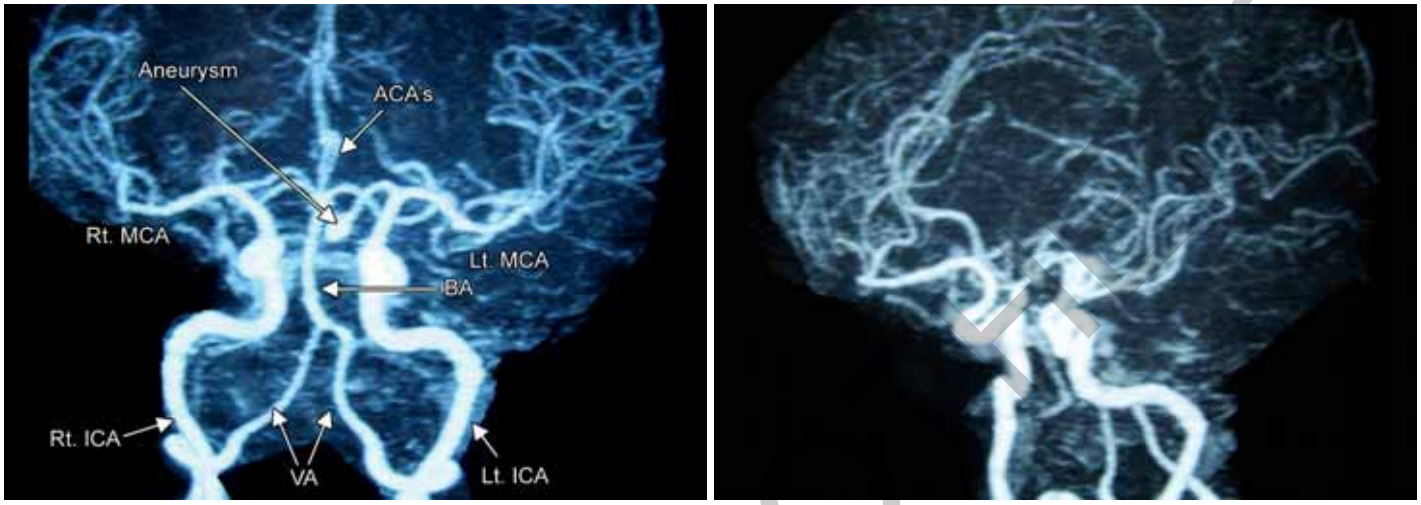

(Rt. MCA: right middle cerebral artery; Lt. MCA: left middle cerebral artery; Rt. ICA: right internal carotid artery; Lt. ICA: left internal carotid artery; BA: basilar artery; VA: vertebral artery, ACAs: anterior cerebral arteries)

POSITION

Anterior communicating artery aneurysms can be clipped through various approaches such as the pterional, interhemispheric, and subfrontal. However, the authors consider the pterional approach as the workhorse approach for most aneurysms and also with the AComA aneurysms. The same position as that for a pterional approach is preferred.

A note needs to be made of the preference of the side of the craniotomy and approach. Some authors advocate predominantly a right-sided approach. However, the authors prefer to approach from the side of the predominant A1 artery and would advise the younger and less experienced neurosurgeons to approach similarly.



SAMPLE PROOF

PROCEDURE



Step 1: A pterional craniotomy is performed with a slightly predominant frontal extension. Dura is opened in a Y fashion.

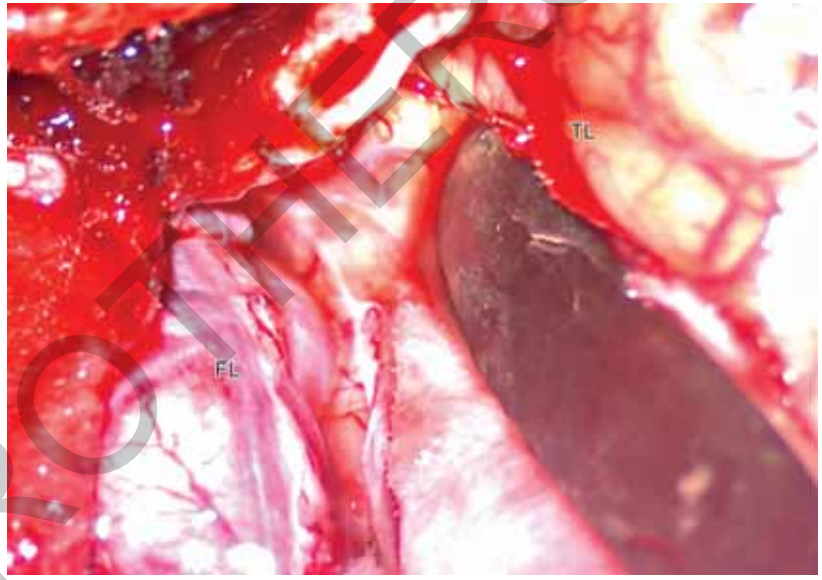

Step 2: The sylvian fissure is opened lateral to medial dissection; the release of CSF relaxes brain. (FL: frontal lobe; TL: temporal lobe)

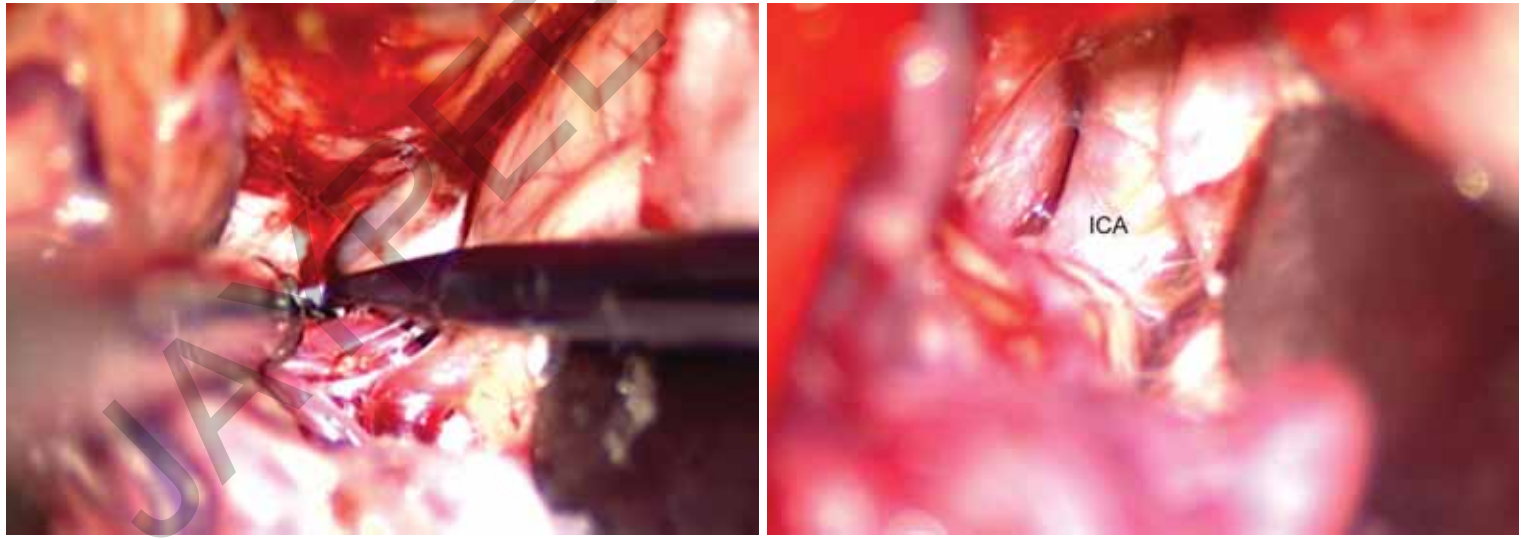

Step 3: The carotid cistern is opened and the proximal internal carotid artery (ICA) dissected.

JAYPEE BROTHERS

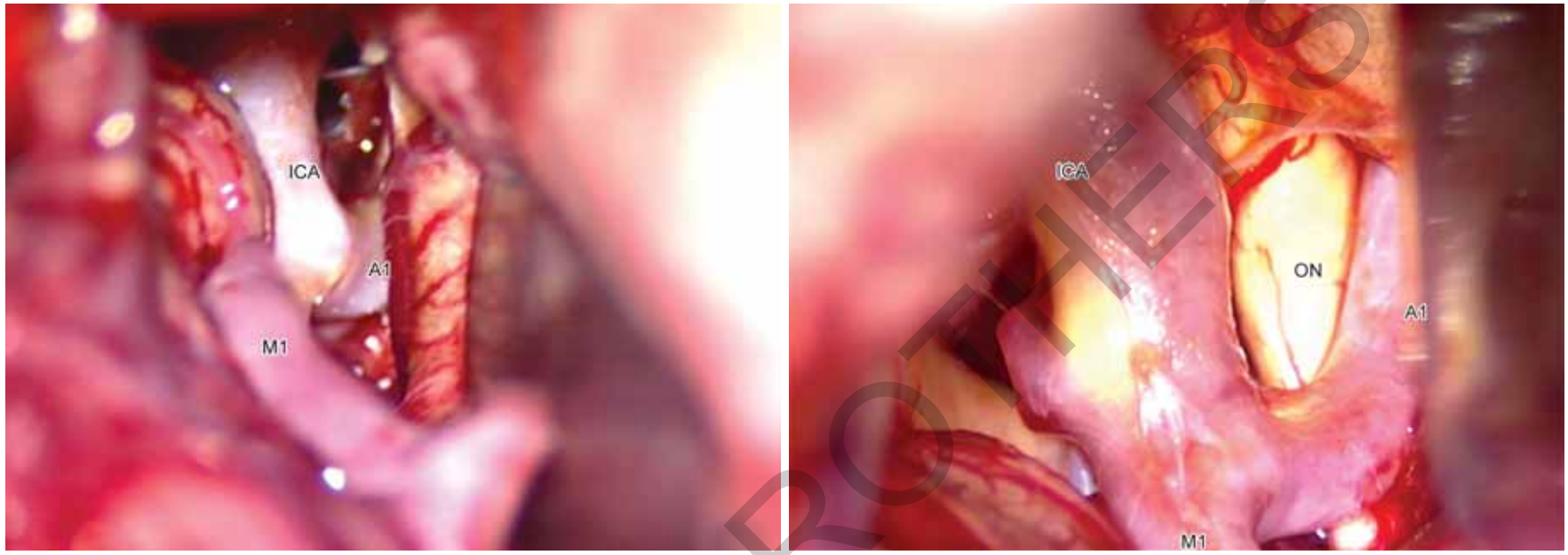

Step 4: The internal carotid artery (ICA) is dissected till its bifurcation. (A1: proximal anterior cerebral artery; M1: proximal middle cerebral artery; ON: optic nerve)

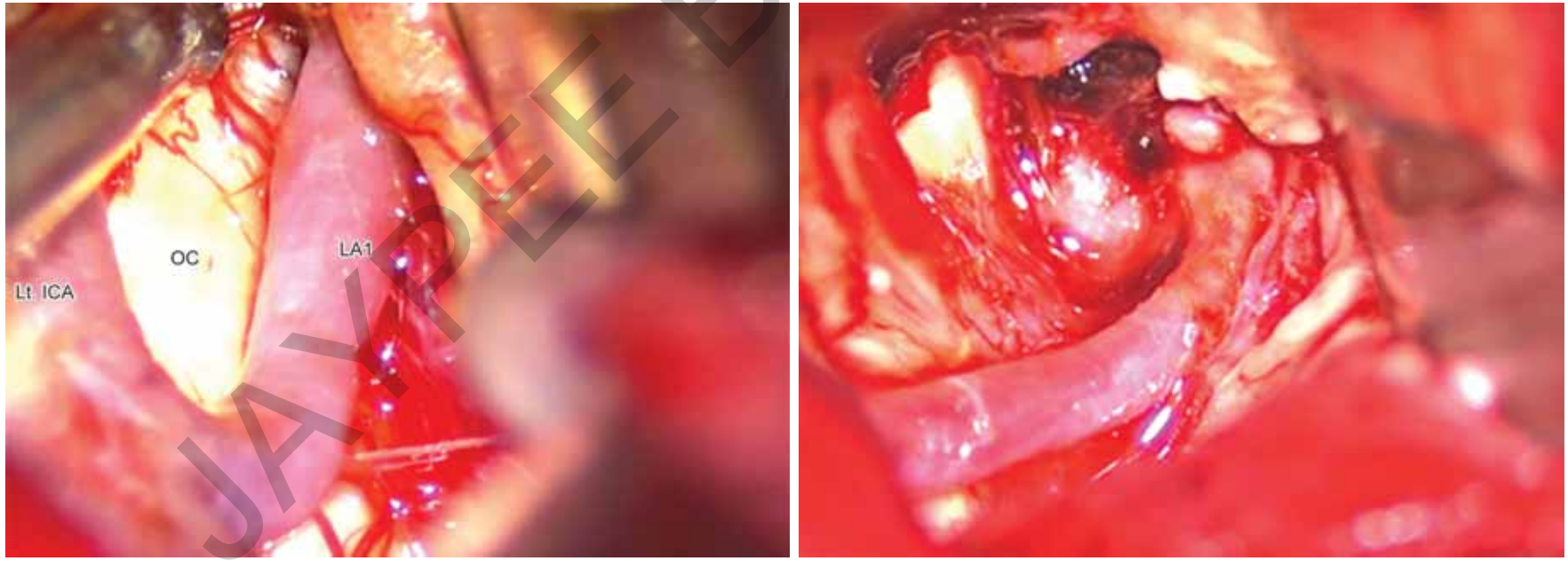

Contd...

JAYPEE BROTHERS

Contd...

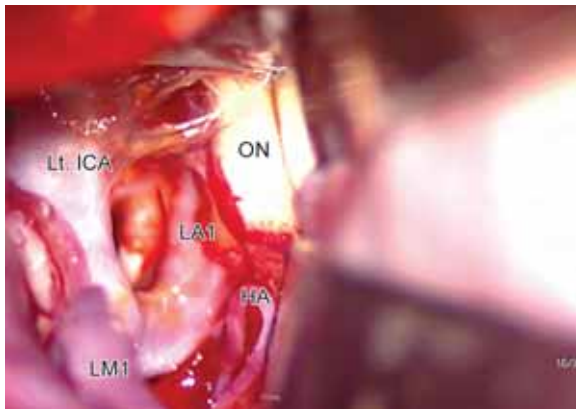

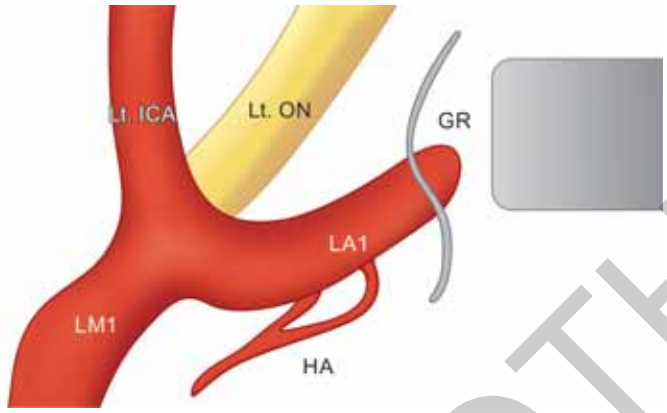

Step 5: Some surgeons advocate a direct approach to the gyrus rectus. However, the authors prefer to dissect the entire A1. The ipsilateral Heubner's artery can be visualized arising from A2 and coursing parallel to the A1. The retractor over frontal lobe has to be placed carefully. We place the retractor parallel to the A1 which is facilitated by the pterional approach. Avoid placing the retractor perpendicular to the A1. Such an action can retract the frontopolar artery and transmit the pressure to the fundus of the aneurysm and its subsequent rupture. The aneurysmal fundus may point in basically two different directions—superiorly or anteriorly. Pure posterior projection of the fundus is uncommon in our experience. Care should also be taken to see that the retractor blade does not slip and inadvertently and compresses the ipsilateral Heubner's artery. (Lt. ICA: left internal carotid artery; ON: optic nerve; LA1: proximal left anterior cerebral artery; LM1: proximal left middle cerebral artery: GR: gyrus rectus; HA: Heubner's artery; Lt. ON: left optic nerve)

Superior

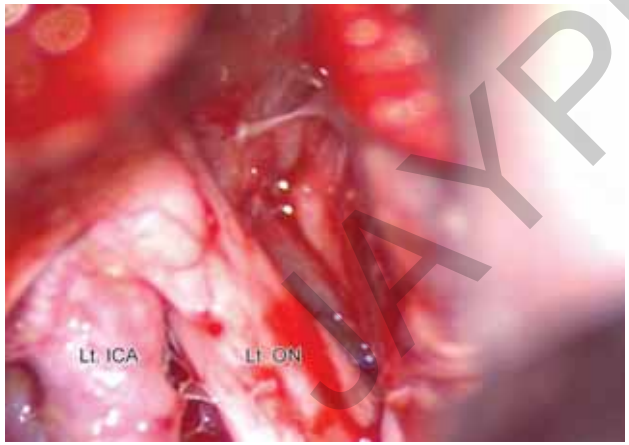

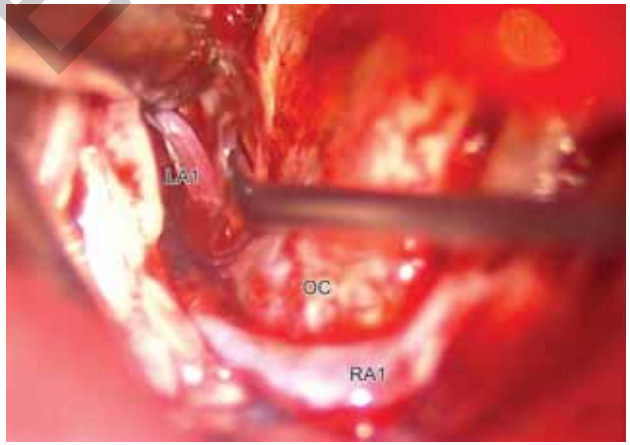

Step 6: Once the ipsilateral A1 is identified and dissected in its entirety, the author now goes across the optic chiasma to the opposite side to identify, dissect, and establish control of the opposite A1 whenever it is essential. (Lt. ICA: left internal carotid artery; Lt. ON: left optic nerve; LA1: proximal left anterior cerebral artery; OC: optic chiasma, RA1: proximal right anterior cerebral artery)

JAYPEE BROTHERS

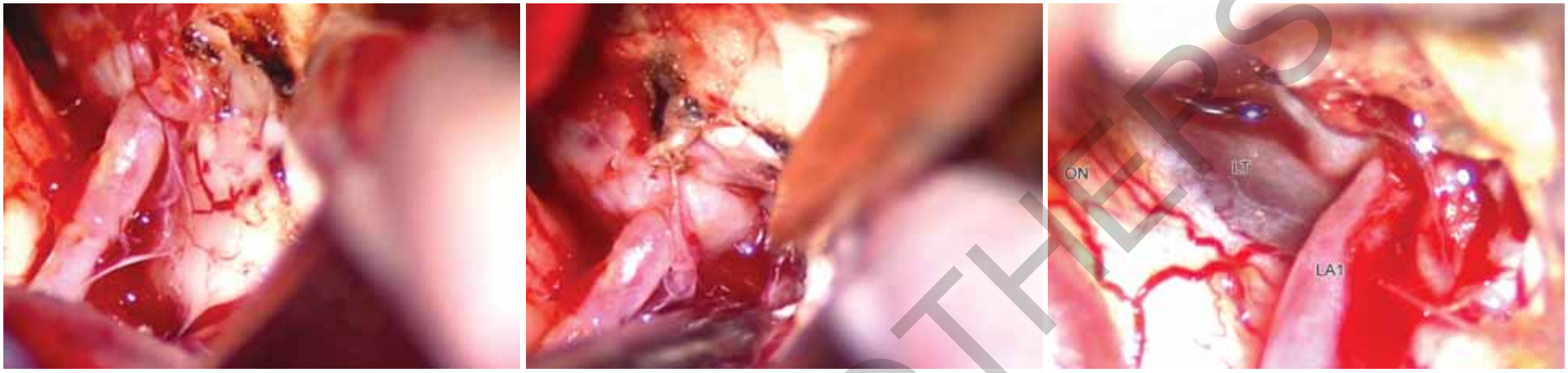

Step 7: The gyrus rectus is identified and a triangular portion of this gyrus is resected using the bipolar cautery and the suction. The triangle consists of the frontopolar artery medially, olfactory tract laterally and the optic nerve brain junction as the base. The gyrus rectus resection is an important and mandatory step according to the authors, this helps in defining the entire arterial complex. It facilitates retraction of frontal lobe without causing traction on the aneurysm, it also helps to identify and to dissect A2 segment especially the opposite A2 which often hidden by the aneurysm. (ON: left optic nerve; LT: lamina terminalis, LA1: proximal left anterior cerebral artery)

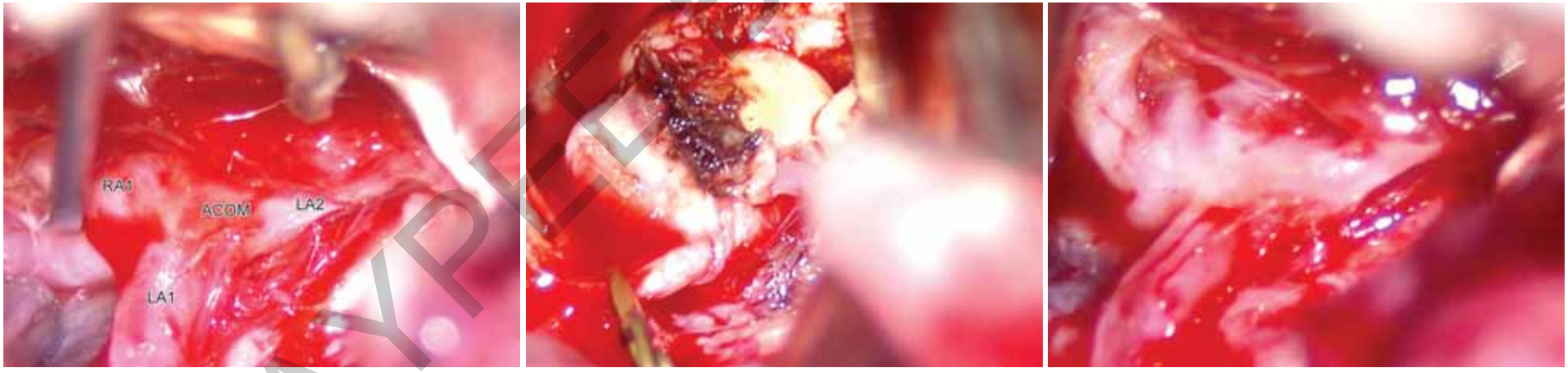

Step 8: The ipsilateral A2 can easily be identified. A sufficient length of this vessel is dissected along with the distal contralateral A2 (i.e., the portion of the A2 distal to the aneurysm) as the proximal contralateral A2 is still hidden by the aneurysm. (RA1: proximal right anterior cerebral artery; ACOM: anterior communicating artery; LA2: distal left anterior cerebral artery; LA1: proximal left anterior cerebral artery)

JAYPEE BROTHERS

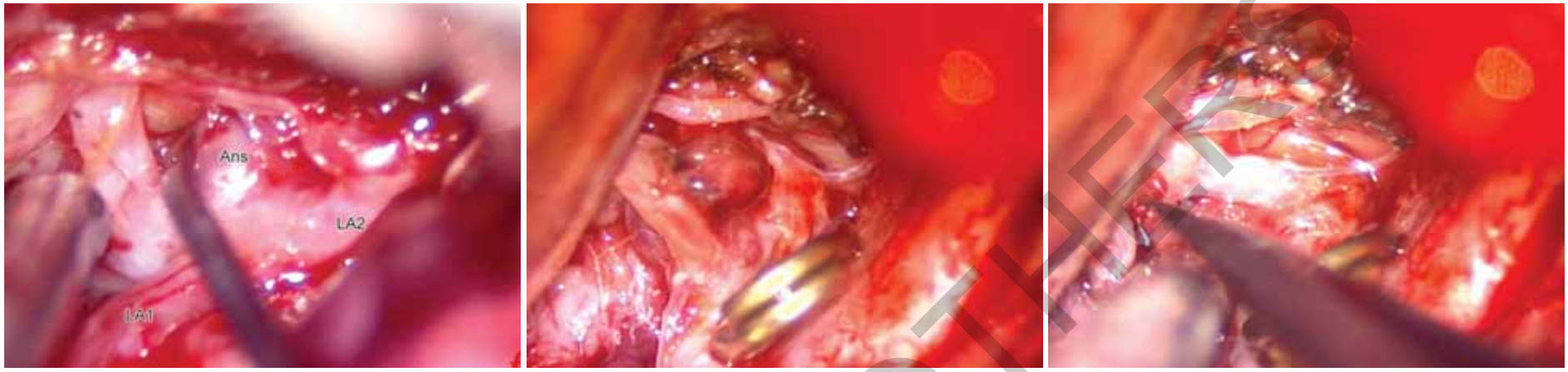

Step 9: The aneurysm is now carefully dissected temporary clip may be applied on one or both the A1's depending on the complexity. The aneurysm neck is shrunk using low setting bipolar coagulation. The ipsilateral A2 is dissected from the neck of the aneurysm, followed by the separation of the neck from the contralateral A2. The perforators from the AComA course posteriorly, hence it is very important to dissect the posterior belly of aneurysm, identify perforators, and preserve them while clipping the aneurysm. The shrinking of belly of the aneurysm creates space for applying the clip. One should be careful not to puncture the posterior belly while application of clip. (Ans: aneurysm; LA2: distal left anterior cerebral artery; LA1: proximal left anterior cerebral artery)

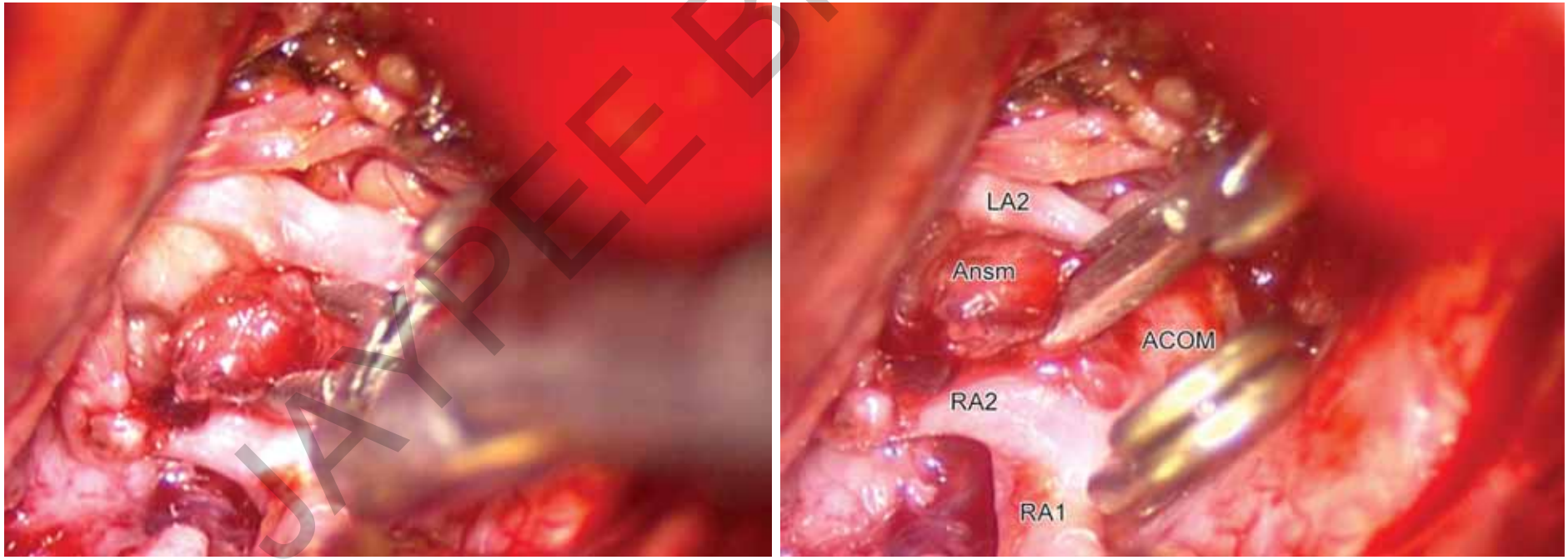

Contd...

JAYPEE BROTHERS

Contd...

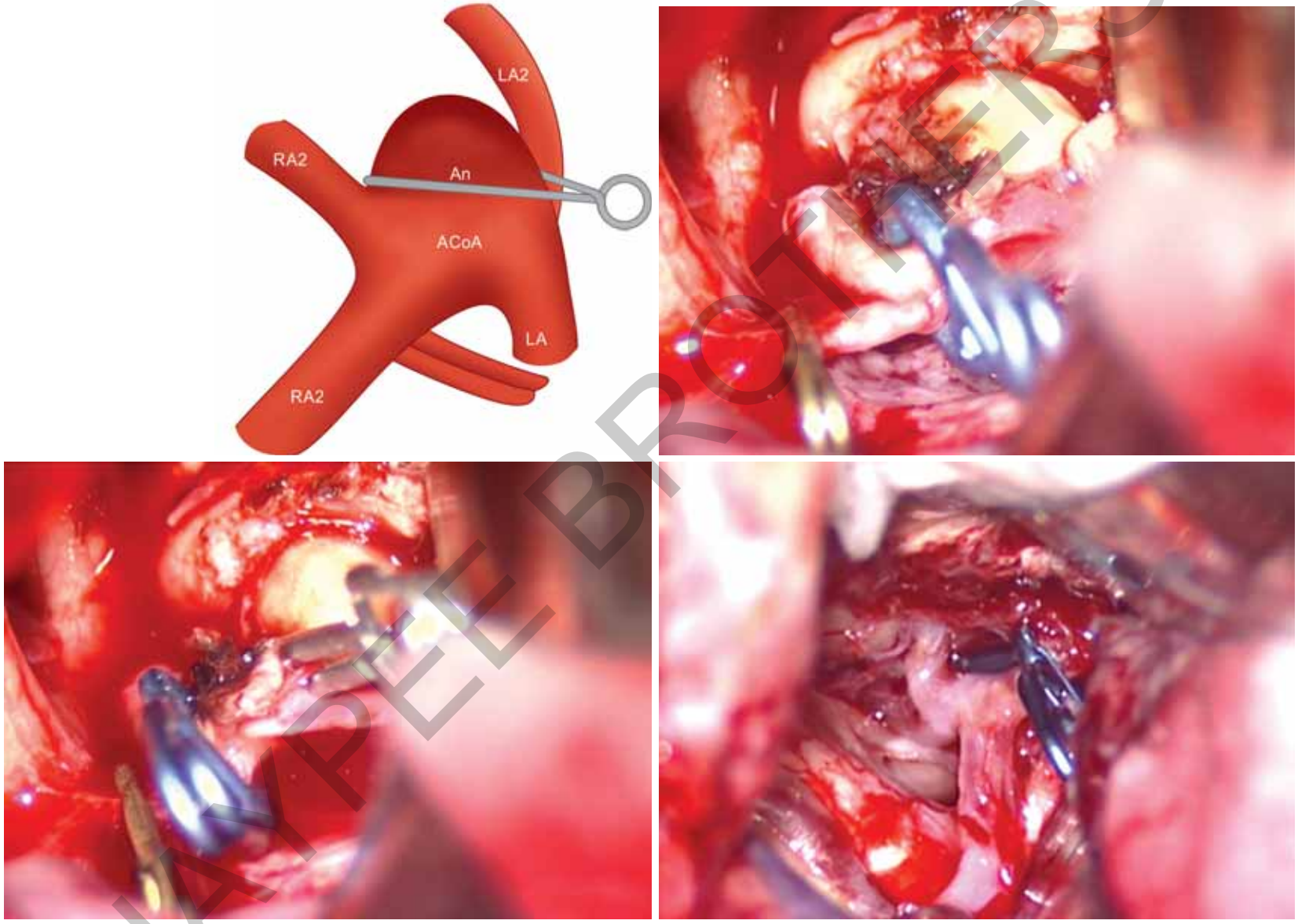

Step 10: The aneurysm is now clipped using an appropriate clip. The clip blades should parallel to the AComA. Majority of the time aneurysms can be clipped with straight clip, however, one should not hesitate to use fenestrated clip. (LA2: distal left anterior cerebral artery; LA: proximal left anterior cerebral artery; RA2: distal right anterior cerebral artery; ACOM: anterior communicating artery; Ansm: aneurysm, RA1: proximal right anterior cerebral artery, ACoA: anterior communicating artery)

JAYPEE BROTHERS

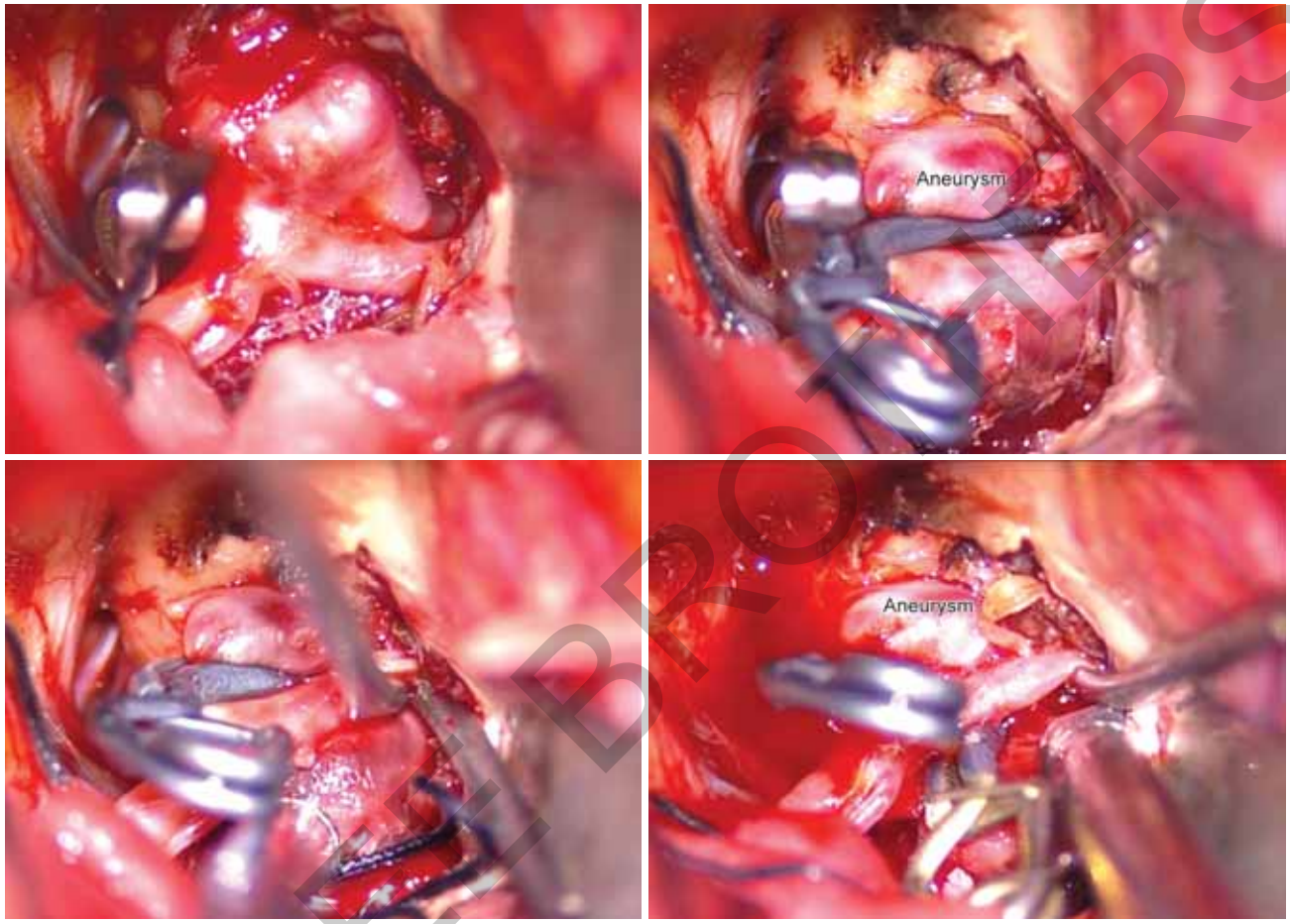



Sometimes, the aneurysm could be multilobulated. It is imperative to make sure that all lobes are obliterated. (An: Aneurysm; LA1: proximal left anterior cerebral artery; LA2: distal left anterior cerebral artery; HA: Heubner's artery)

JAYPEE BROTHERS

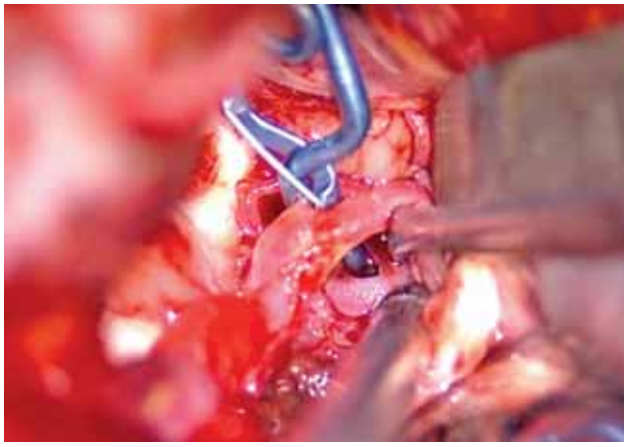
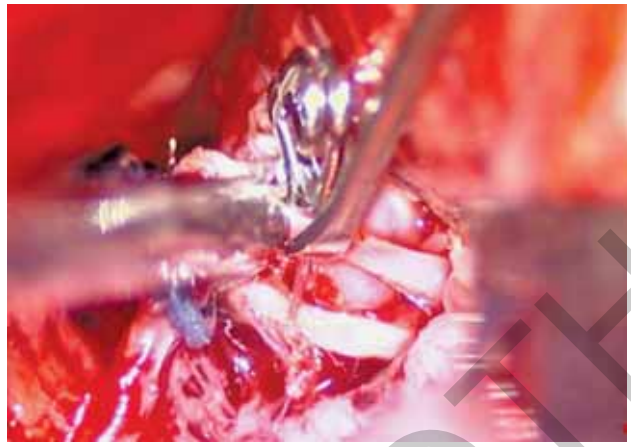
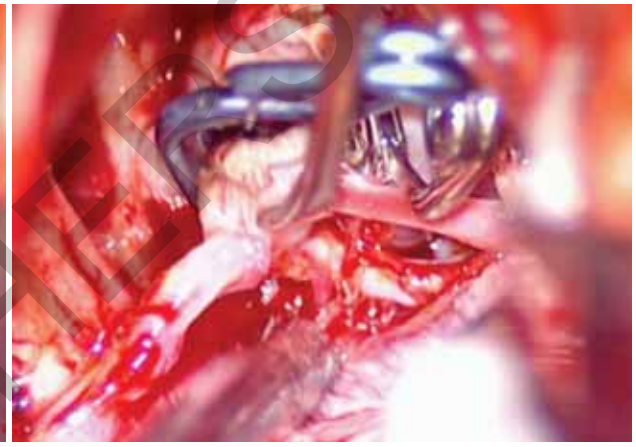

Step 11: After placing the clip, it is important to confirm that the clip has been applied correctly. It is essential to preserve the patency of all the surrounding vessels (both the A1, both the A2 and both the Heubner's arteries, AComA, and its perforators).

Anteriorly

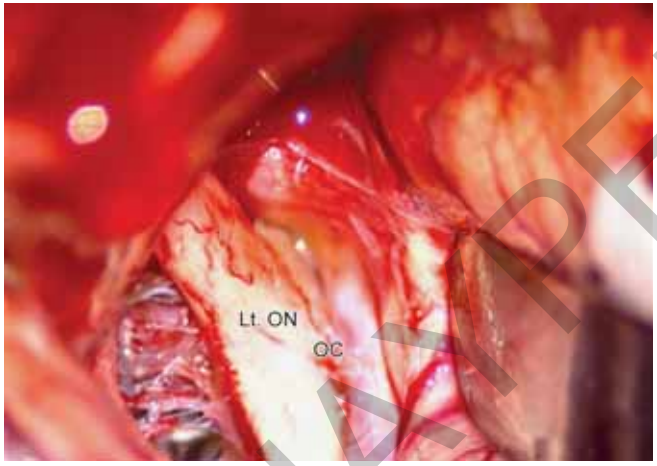

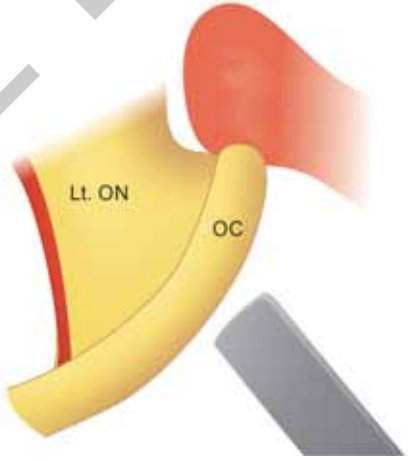

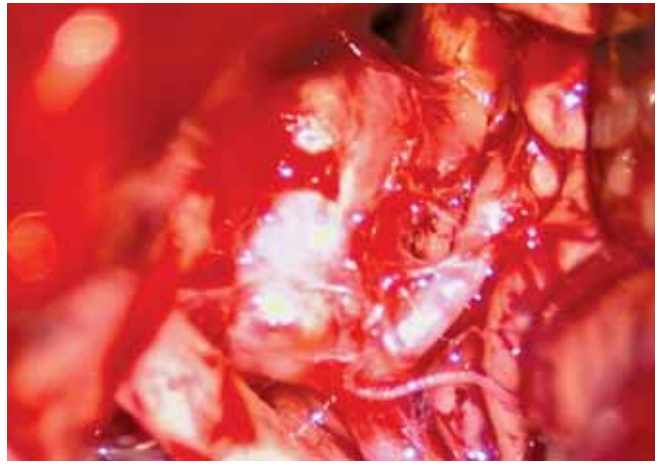

Contd...

JAYPEE BROTHERS

Contd...

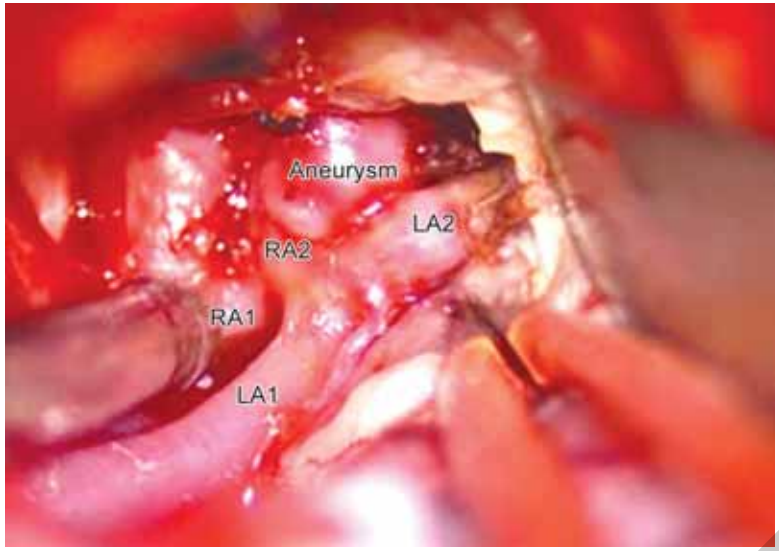

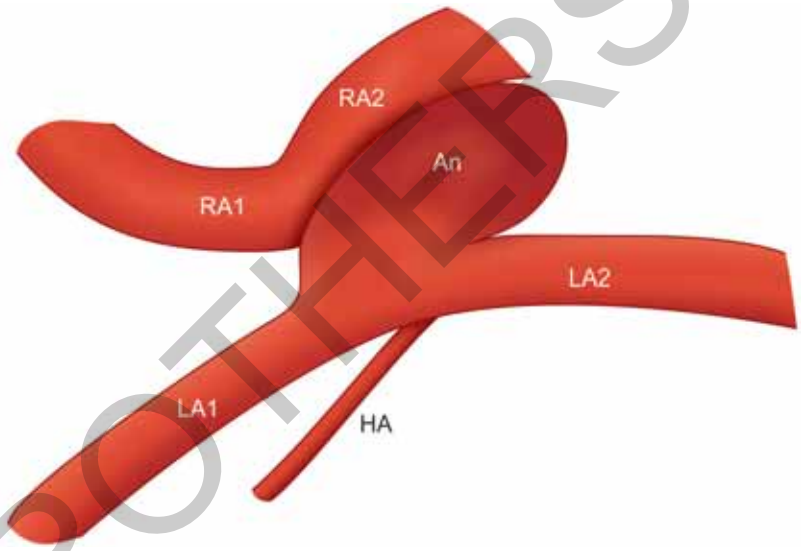

Step 12: Anteriorly placed aneurysms can be both easy and dangerous. The fundus may be adherent to the adjacent anterior cranial fossa floor or to the optic chiasma if it is prefixed. Extreme caution must be exercised during retraction in this case. Frontal lobe retraction must be totally avoided. (Lt. ON: left optic nerve; OC: optic chiasma, RA2: distal right anterior cerebral artery; RA1: proximal right anterior cerebral artery; LA2: distal left anterior cerebral artery, LA1: proximal left anterior cerebral artery, HA: Heubner's artery; An: aneurysm)

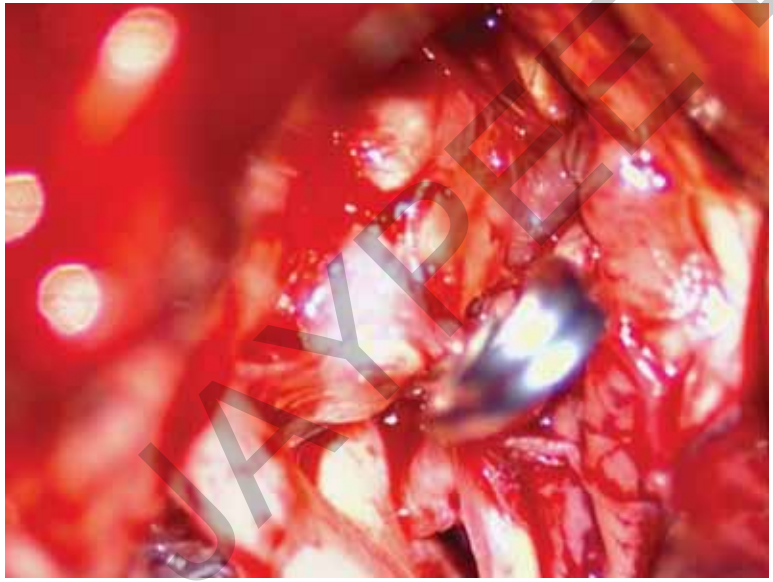

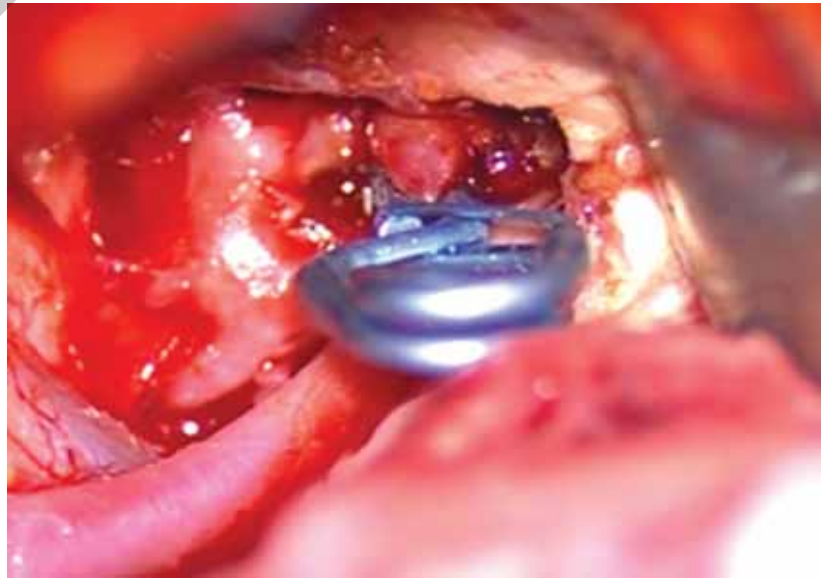

Step 13: The authors advocate the placement of a tentative clip and then dissect the aneurysm.

JAYPEE BROTHERS

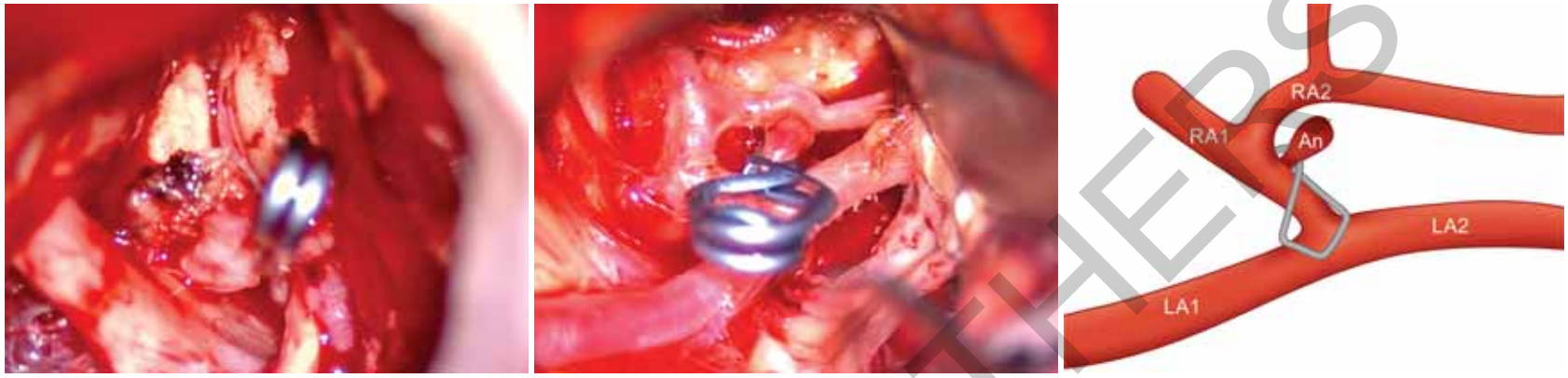

Step 14: Once the entire anatomy is identified a final clip may be placed. (LA1: proximal left anterior cerebral artery, LA2: distal left anterior cerebral artery; RA1: proximal right anterior cerebral artery; RA2: distal right anterior cerebral artery; An: aneurysm)

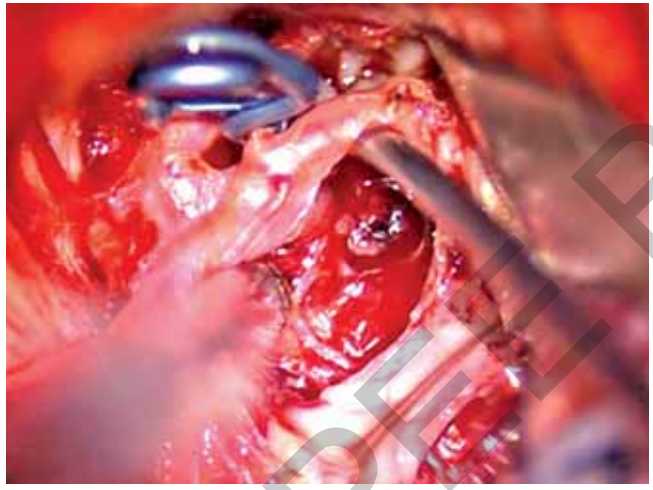

Step 15: All the parent vessels and their branches are then checked for their patency.

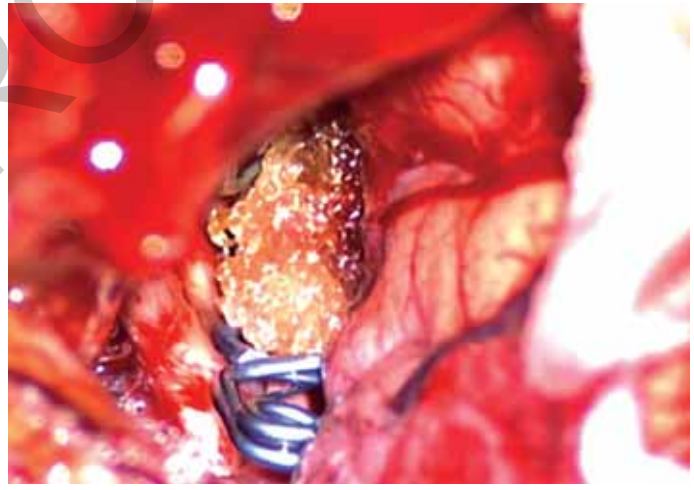

Step 16: Perfect hemostasis is secured and closure done in the usual way.

AUTHOR'S TIPS

- Approach from the side of the dominant A1
- Craniotomy should have more frontal than in other pterional craniotomies.
- Frontal lobe retraction should be careful and nil in case of anteriorly pointing aneurysms.
- Be prepared for intraoperative rupture.
- Gyrus rectus excision is a must for all except anteriorly pointing aneurysms.
- Check patency of all the normal vessels after clipping.

JAYPEE BROTHERS

for detailed information on neurosurgery books, visit our website www.jaypeebrothers.com, for detailed information on neurosurgery books, visit our website www.jaypeebrothers.com, for detailed information on n

Operative Manual of
Neurosurgery
A Step by Step Pictorial Atlas

Salient Features

- A step by step pictorial atlas on most of the neurosurgical procedures performed across the country.
- Comprises 21 sections with around 155 chapters written by various experts in the field and are simple and easily understandable. It includes most of the procedures performed on the brain and spine.
- Each chapter has an introduction (with radiological imaging), position and procedure with systematic steps all corroborated by appropriate photographs and illustrations along with the authors' tips.
- The focus of this atlas are the steps involved in the various surgical procedures through photographs and illustrations rather than on theoretical knowledge of the same.
- Aimed at the neurosurgical residents and junior neurosurgeons just entering practice and not exposed to the wide variety of neurosurgical procedures.

Balaji Pai S MBBS DNB (Neurosurgery) MBA (Hospital Management) is Professor and Head of the Department of Neurosurgery at the Bangalore Medical College and Research Institute (BMCRI), Bengaluru, Karnataka, India. He has been instrumental in setting up a well-equipped and service oriented department at the Pradhan Mantri Swasthya Suraksha Yojana (PMSSY) Superspeciality Hospital at BMCRI, which is now doing yeoman service to the under privileged sections of our society. He is also the first Special Officer of the new Trauma and Emergency Care Centre at the Victoria Hospital, which he was instrumental in commissioning and heading from 2015 to 2020. Conducted more than 5000 brain and spine surgeries of varying complexity in his 27 years of experience. He has more than 35 publications in Indian and International journals and has presented many papers in various fora. He has been a guest faculty at various workshops and has also conducted various cadaveric workshops. His areas of speciality and interest include cerebrovascular surgery, brain tumors, spinal surgeries and instrumentation and endovascular surgery. He has enhanced his knowledge and skill in these areas by undergoing various fellowships.



Printed in India

Available at all medical bookstores
or buy online at www.jaypeebrothers.com

JAYPEE BROTHERS
Medical Publishers (P) Ltd.
EMCA House, 23/23-B, Ansari Road,
Daryaganj, New Delhi - 110 002, INDIA
www.jaypeebrothers.com

Join us on facebook.com/JaypeeMedicalPublishers

Shelving Recommendation
NEUROLOGY

ISBN 978-93-5465-429-9