atology books, visit our website www.jaypeebrothers.com, for detailed information on dermatology book



2nd Edition

Pocket Atlas of Clinical DERMATOLOGY

With Diagnosis and Treatment



Ramesh Bansal

JAYPEE

CONTENTS

Chapter 1	Structure of Skin	1
Chapter 2	Types of Lesions in Dermatology	5
Chapter 3	Skin Diseases Caused by Protozoa, Arthropods, and Parasitic Worms	35
Chapter 4	Cutaneous Infections	51
Chapter 5	Eczemas	115
Chapter 6	Genetics and Genodermatoses	140
Chapter 7	Vesiculobullous Diseases	156
Chapter 8	Papulosquamous Disorders	181
Chapter 9	Disorders of Connective Tissue	196
Chapter 10	Disorders of Skin Appendages	217
Chapter 11	Disorders of Pigmentation	263
Chapter 12	Leg Ulcers and other Disorders of Vascular Insufficiency	281
Chapter 13	Urticaria, Mastocytosis, Pruritus, and other Vascular Responses	293
Chapter 14	Disorders due to Cold, Light, Heat, and Radiation	308
Chapter 15	Drug Reactions	318
Chapter 16	Nevi and Skin Tumors	325
Chapter 17	Cutaneous Manifestations of Internal Diseases	387
Chapter 18	Miscellaneous Cutaneous Diseases	404
Chapter 19	Glucocorticoids	429
Chapter 20	Dermatotherapeutics	438
Chapter 21	Sexually Transmitted Infections	455
Chapter 22	Leprosy	474
Chapter 23	COVID-19 and Mucormycosis	495
Index		503

CHAPTER

4

Cutaneous Infections

IMPETIGO

Impetigo is the contagious superficial bacterial infection of skin which is recognized in two clinical forms, i.e., *nonbullous (impetigo contagious)* and *bullous impetigo* **(Figs. 1A and B and Table 1)**.



Figs. 1A and B: (A) Nonbullous (impetigo contagious) showing thick dirty brown crusts and (B) bullous impetigo on thigh having few bullae.

JAYPEE BROTHERS

NONBULLOUS (IMPETIGO CONTAGIOUS)

Diagnosis

Clinical Diagnosis

- Involvement of face in a child **(Fig. 1A)**
- Honey-colored multiple crusted lesions with surrounding erythema

Investigations

- Gram staining of exudates can reveal *Streptococci* and *Staphylococci* as gram-positive cocci in chins and clusters, respectively.
- *Culture*: Culture and sensitivity to etiological agent can also be performed.

Treatment

- Local treatment is sufficient in mild-to-moderate patients.
- Potassium permanganate should be used to treat infected crust.
- Systemic treatment should be given when involvement is extensive or lymphadenopathy or constitutional symptoms are there.
- For streptococcal impetigo, penicillin is the drug of choice. Benzathine penicillin (0.3–0.6 million for children and 1.2 million for adults) can be given as a single injection.
- Combination of amoxicillin and clavulanic acid (25 mg/kg/day), erythromycin, and cephalexin (50 mg/kg/day) are also suggested.
- Staphylococcal impetigo in adults responds nicely to dicloxacillin.

JAYPEE BROTHERS

BULLOUS IMPETIGO

Difference between bullous impetigo and impetigo contagiosa has been described in **Table 1**.

TABLE 1: Difference between bullous impetigo and impetigo contagiosa.

Bullous impetigo	Impetigo contagiosa
Caused by: Exotoxins produced by *Staphylococcus aureus* group II phage	*S. aureus* or *Staphylococcus pyogenes* or both
Prevalence: Sporadic	Very common
Age: Common in newborn and infants	Preschool and young school children
Epidermal split: Just below the stratum granulosum	Above, within, or below stratum granulosum
Morphology: Bullae are thick-walled, persistent, and usually of small size **(Fig. 1B)**	Thin-walled, transient, and vesicles
Surrounding erythema: Not present	May be present
Crusts: Thin and dark yellow (varnish like)	Thick and yellow or dirty brown (honey colored)
Site: Face and other body parts	Mainly seen on face
Lymphadenopathy: Not a feature	Present in severe cases

JAYPEE BROTHERS

STAPHYLOCOCCAL SCALDED SKIN SYNDROME

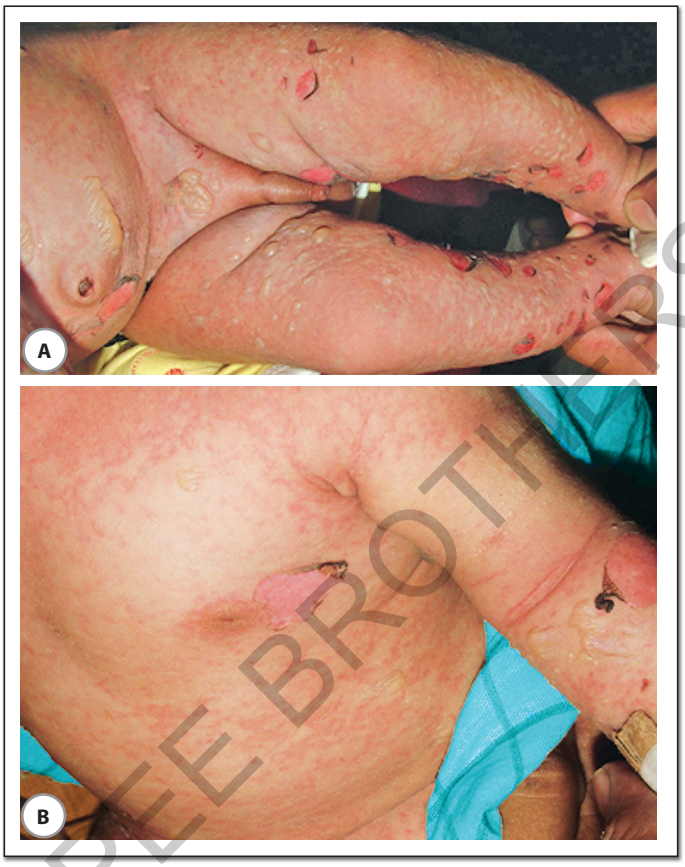

Figs. 2A and B: Staphylococcal scalded skin syndrome. (A) Widespread erythema, blistering, and erosions on lower extremities in a neonate and (B) positive Nikolsky's sign.

JAYPEE BROTHERS

Diagnosis

Clinical Diagnosis

- Patient is usually an infant or a child **(Figs. 2A and B)**.
- Thin-walled vesicles or bullae filled with sterile clear fluid
- Superficial peeling of skin
- Clue of focus of staphylococcal infection
- Absence of mucosal involvement

Investigations

- Gram staining and culture of blister fluid do not reveal any microorganism.

Treatment

- Oral or intravenous suitable antibiotics against *Staphylococcus aureus* should be administered early.
- The nonadherent petroleum-impregnated dressings on widespread raw areas are helpful.
- Fluid and electrolyte imbalance should also be taken care of.

JAYPEE BROTHERS

ERYSIPELAS AND CELLULITIS



Figs. 3A and B: (A) Cellulitis. Around a wound showing erythema and indistinct margins and (B) erysipelas. Superficial red edematous plaque with well-defined edge to normal adjoining skin.

JAYPEE BROTHERS

Diagnosis

Clinical Diagnosis

- Affected part is red, warm, and indurated (firm to hard). Cellulitis is differentiated from erysipelas by indistinct margins between affected and unaffected skin **(Fig. 3A)**.
- Regional lymphadenopathy is frequent. Erysipelas is seen as superficial, painful edematous red plaque with sharp well-defined raised edge to normal tissue **(Fig. 3B)**.
- Lower limbs, less frequently face, and upper limbs

Treatment

- Bed rest, elevation of affected part, applications of moist heat, and nonsteroidal anti-inflammatory drugs (NSAIDs) should be taken as supportive measures.
- For specific measures, mild erysipelas can be treated on outpatient basis with intramuscular (IM) procaine penicillin in the dose of 600,000 units BD.
- Cellulitis should be treated with dicloxacillin (500 mg QID) or oral cephalosporins. Macrolides and clindamycin are alternative drugs for penicillin-allergic patients.
- Extensive infections especially with underlying medical problems need hospitalization and are treated with 1–2 million units of aqueous penicillin every 4–6 hours intravenous (IV) for 10 days.
- *Necrosis and slough formation*: Require early and complete necrotic tissue debridement

JAYPEE BROTHERS

SUPERFICIAL FOLLICULITIS



Figs. 4A and B: Superficial folliculitis. (A) Superficial follicular pustules and (B) chronic superficial folliculitis on leg.

JAYPEE BROTHERS

Diagnosis

Clinical Diagnosis

- It is a profuse eruption of follicular pustules on lower extremities. May be seen in young adults **(Figs. 4A and B)**
- Lower beard area, neck, and jaw area are common sites of involvement.
- Patient complaining of discomfort, papules and pustules on shaved skin are common diagnostic features.

Treatment

- It is often chronic and resistant to treatment.
- *Treatment*: It is unsatisfactory. Patient may be benefited by not shaving for 4–6 weeks.

JAYPEE BROTHERS

DEEP FOLLICULITIS

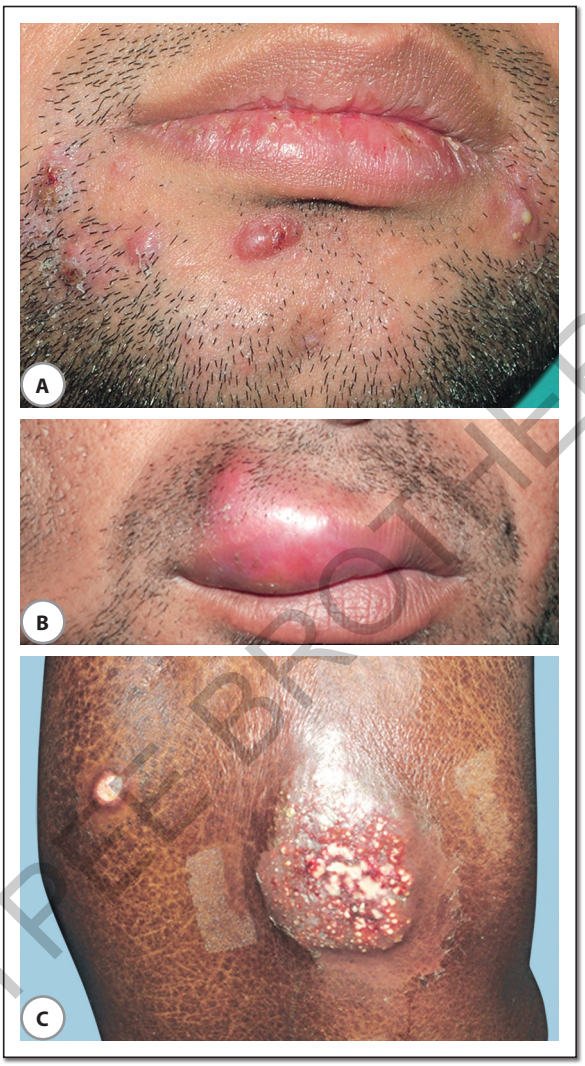

Figs. 5A to C: (A) Sycosis barbae. Deep folliculitis with perifollicular inflammation in the beard area, (B) furuncle (boil) on upper lip, and (C) carbuncle on back in a diabetic patient.

Diagnosis

Clinical Diagnosis

Deep folliculitis includes three clinical diagnostic entities **(Table 2)**.

JAYPEE BROTHERS

TABLE 2: Three different clinical entities of deep folliculitis.

Sycosis* barbae	Furuncle	Carbuncle
• Chronic bacterial infection of whole depth of hair follicles commonly in the beard region or upper lip **(Fig. 5A)** • Red edematous papule or pustule with a hair in the center	• Hard, tender, follicular, and red inflammatory nodule in the hair bearing area of skin • Face, neck, buttocks, anogenital region, arms, and thighs are the most common sites **(Fig. 5B)**	• Presents as painful, smooth, dome-shaped reddish hard, and tender lump. Later followed by suppuration • The back of neck, shoulder, back, and thigh are common sites of involvement **(Fig. 5C)**

*Greek sykosis means figure.

Treatment

Furuncle (Boil)

- It is treated by systemic flucloxacillin or other penicillinase-resistant antibiotic.
- Application of moist heat is helpful.
- When becomes soft, express pus manually or do incision and drainage.

Carbuncle

- Search for underlying predisposing factor
- Moist hot fermentation
- Manipulation of lesions should be avoided because uncommonly it may spread infection via bloodstream and may lead to osteomyelitis or brain abscess.
- Systemic flucloxacillin or other penicillinase-resistant antibiotic should be added.
- Analgesics
- *Incision and drainage*: Of large fluctuant and painful lesions
- *Management of recurrent furunculosis:*
  - In addition to systemic causes, the local predisposing factors such as exposure to chemical, poor hygiene, tight belts, clothing, and obesity should be taken care of.
  - Patient should use loose clothing.
  - In addition to use of soap and water for care of hands and body, use of 4% chlorhexidine solution may help in decreasing cutaneous colonization by staphylococci.
  - Efforts can also be made for elimination of *S. aureus* from nose. Intranasal application of 2% mupirocin ointment for 5 days in a month for 1 year is found to be effective.
  - The use of 600 mg of rifampicin per day for 10 days is also helpful.

JAYPEE BROTHERS

PITTED KERATOLYSIS



Fig. 6: Pitted keratolysis.

Diagnosis

Clinical Diagnosis

- Circular-shaped erosions on the soles **(Fig. 6)**
- The lesions have a punched-out appearance, and may coalesce to form large irregular erosions on pressure-bearing areas.
- Plantar hyperhidrosis and malodorous feet

Treatment

- Hyperhidrosis should be controlled with formalin soaks and feet should be kept as dry as possible.
- Azoles, sodium fusidate, benzoyl peroxide (5%), and erythromycin may be applied topically.

JAYPEE BROTHERS

TUBERCULAR INFECTIONS

TUBERCULOSIS VERRUCOSA CUTIS (TABLE 3)



Figs. 7A to C: (A) Tuberculosis verrucosa cutis, (B) after treatment, and (C) scrofuloderma due to involvement of cervical lymph node.

JAYPEE BROTHERS

for detailed information on dermatology books, visit our website www.jaypeebrothers.com, for detailed

Pocket Atlas of Clinical Dermatology

With Diagnosis and Treatment

Salient Features

- This second edition is after the success of the previous edition which was very well accepted and embraced by the readers
- A reader friendly pocket-sized book has been formatted by keeping the practitioners and doctor's convenience in mind for their easy consult
- Second edition pocket atlas consists of 23 chapters with various excellent photographs for better understanding of dermatological clinical conditions
- Various tables, boxes and flowcharts have been introduced to understand the plethora of clinical advances
- Latest topics on Glucocorticosteroids, COVID-19 and Mucormycosis are covered in this book
- "Dermatology is a visual science" keeping this a root factor every disease is detailed with their relevant clinical photograph
- Every disease with their clinical diagnosis and advance treatment have been introduced for an easy grasp of individual skin disease
- Author's innovative approach has been maintained throughout the book
- Text presented in a lucid form and yet concise manner
- Invaluable resource for dermatologists, physicians and postgraduate students.

Ramesh Bansal MBBS MD (Skin, VD and Leprosy) is a pioneer consultant (Dermatologist) in Rohtak (Since 1990), Haryana, India. He was Registrar in Department of Skin, VD and Leprosy at Pt Bhagwat Dayal Sharma Postgraduate Institute of Medical Sciences, Rohtak, Haryana, India. He had also served the prestigious post of President at IADVL (Indian Association of Dermatologists, Venereologists and Leprologists) Haryana state branch in 1998, IMA Rohtak city branch in 2003-2004, and as Honourable Secretory at IMA Rohtak city branch in 1992-1993, 1997-1998 and 2011-2012. He had been an Executive Committee Member of IASSTD (Indian Association of Study of Sexually Transmitted Diseases) in 1988-1999. He has more than 20 articles in national and international journals to his repute.

Printed in India

Available at all medical bookstores or buy online at www.jaypeebrothers.com



JAYPEE BROTHERS
Medical Publishers (P) Ltd.
EMCA House, 23/23-B, Ansari Road,
Daryaganj, New Delhi - 110 002, INDIA
www.jaypeebrothers.com

Join us on facebook.com/JaypeeMedicalPublishers

Shelving Recommendation
DERMATOLOGY

