ailed information on ophthalmology books, visit our website www.jaypeebrothers.com, for detailed information on ophthalmology books, visit our website www.jaypeebrothers.com

diginerve
A Jaypee Initiative
Your Guide at Every Step
Video Lectures | Notes | Self-Assessment
Scan to Know More



Ophthalmology

Oral and Practical

FIFTH EDITION

25 CELEBRATING 25 YEARS

As per the Competency Based Medical Education Curriculum (NMC)

Samar K Basak
Soham Basak

JAYPEE

Contents

1. History Taking and Examination of an Eye Case 1

- Ocular Symptoms 2
- Ocular Examination 6

2. Practical: Clinical Cases 21

- List of Long and Short Cases 21
- Immature Senile Cataract 21
- Mature Senile Cataract 24
- Hypermature Cataract 24
- Aphakia 26
- Pseudophakia 29
- Posterior Capsular Opacification 31
- Pterygium 33
- Phlyctenular Conjunctivitis 35
- Subconjunctival Hemorrhage 37
- Corneal Ulcer 38
- Leucoma 42
- Adherent Leucoma 45
- Anterior Staphyloma 46
- Phthisis Bulbi 48
- Chalazion 50
- Stye (Hordeolum Externum) 52
- Bitot's Spot and Conjunctival Xerosis 53
- Acute Iridocyclitis (Red Eye) 55
- Chronic Iridocyclitis 56
- Chronic Dacryocystitis 60
- Acute Dacryocystitis 61
- Episcleritis 64
- Trichiasis 65
- Blepharitis 65

3. Brief Theories and Viva 68

- Ocular Anatomy 68
- Layers and Regions of Retina 72
- Ocular Pharmacology 74
- Antiglaucoma Medications 78
- Physiology of Vision 79
- Optics and Refraction of the Eye 80
- Refractive Errors of the Eye 81

- Indications and Principles of Refractive Surgery 84
- Amblyopia 85
- Lid and Adnexal Conditions 86
- How to Give Lacrimal Sac Massage in Congenital Dacryocystitis 89
- Trichiatic Cilia (Eyelash) Removal by Epilation 90
- Orbital Cellulitis 90
- Proptosis and Orbital Tumors 92
- Intraocular Tumors 93
- Red Eye (Conjunctivitis) 94
- Trachoma 97
- Vernal Conjunctivitis 99
- Pterygium 100
- Symblepharon 100
- Technique of Removal of Foreign Body from Eye 101
- Correct Technique of Instillation of Eye Drops 102
- Cornea 103
- Causes of Corneal Blindness 105
- Indications and Types of Keratoplasty 107
- Sclera 110
- Iris and Anterior Chamber 113
- Glaucoma 117
- Investigations of a Patient with Uveitis 121
- Crystalline Lens and Cataract 123
- Etiopathogenesis, Stage of Maturation and Complications of Cataract 124
- Retina and Optic Nerve 128
- Indications of Laser Therapy in Retinal Diseases 129
- Diseases of Optic Nerve and Visual Pathways 133
- Miscellaneous 135
- Strabismus (Squint) and Indications for Referral 136
- Avoidable Blindness, NPCBVI and Vision 2020 139
- Evaluation, Initial Management and Referral in Patient with Ocular Injury 142
- Ocular Manifestations and Associations of COVID-19 143
- Explain Effect of Pituitary Tumors on Visual Pathway 143
- Describe Anatomical Basis of Horner's Syndrome 144
- Explain the Anatomical Basis of Oculomotor, Trochlear and Abducent Nerve Palsies Along with Strabismus 144
- Describe and Demonstrate Parts and Layers of Eyeball 145
- Describe the Position, Nerve Supply and Actions of Intraocular Muscles 145
- Describe and Discuss Functional Anatomy of Eye, Physiology of Image Formation, Physiology of Vision Including Color Vision, Refractive Errors, Color Blindness, Physiology of Pupil and Light Reflex 145
- Describe and Discuss the Physiological Basis of Lesion in Visual Pathway 146
- Describe the Etiology, Genetics, Pathogenesis, Pathology, Presentation, Sequelae and Complications of Retinoblastoma 148
- Describe Drugs used in Ocular Disorders 149
- Visual Loss in the Elderly 149

4. Common Eye Instruments 151

- Eye Speculums 151
- Barraquer's Wire Speculum 152
- Artery Forceps (Hemostat) 152
- Fixation Forceps (Eyeball Fixation Forceps) 152
- Scalpel Handle (Bard Parker Handle) 153
- Blade Breaker 153
- Thermocautery (Heat Cautery) 154
- Corneal Spring Scissors (Universal) 154
- Iris Forceps 155
- De-Wecker's Iris Scissors 156
- Lens Expressor (Lens Hook) 156
- Iris Repositor 156
- Needle Holder (Barraquer's and Castroviejo's) 157
- Colibri Forceps 157
- St. Martin's Forceps 157
- Lim's Sclerocorneal Forceps 157
- Superior Rectus Holding Forceps 157
- Suture Tying Forceps 158
- Cystitome or Capsulotome 158
- Capsulorhexis Forceps (Utarata Forceps) 158
- Irrigating Vectis 159
- Vectis (Wire Vectis) 159
- Irrigation-Aspiration Cannula (Simcoe) 159
- McPherson's Forceps 160
- Vannas' Scissors 160
- IOL Dialer (Sinsky's Hook) 160
- Crescent Knife (Sclerocorneal Splitter) 161
- Angular Keratome 161
- Side-Port Blade 161
- Phaco Chopper 162
- Phaco Handpiece with Connecting Cord 162
- Epilation Forceps (Cilia Forceps) 162
- Strabismus Hook (Muscle or Squint Hook) 163
- Lid Retractor (Desmarre's) 163
- Chalazion Forceps (Clamp) 163
- Chalazion Scoop (Curette) 164
- Punctum Dilator (Nettleship's) 164
- Lacrimal Cannula 165
- Lacrimal Dissector with Scoop (Lang's) 165
- Rougine 165
- Muller's Retractor 166
- Cat's Paw Retractor 166
- Bone Punch 166
- Hammer, Chisel and Bone Gouge 166

- Evisceration Scoop or Spoon 167
- Enucleation Scissors and Spoon 167
- Lacrimal Probe (Bowman's) 168
- Lid Spatula (Plate) 168
- Entropion Forceps 169
- Entropion Clamp 169
- Caliper (Castroveijo's) 169
- Corneal Trephine (Castroveijo's) 170
- Pin-Hole 170
- Stenopaeic Slit 170
- Trial Frame and Ophthalmic Lenses 171
- Retinoscope 172
- Jackson's Cross Cylinder 174
- Maddox Rod 174
- Placido's Disc 175
- Methods of Sterilization of Instruments 175

5. Few Common Eye Surgeries 177

- Cataract Surgery 177
- Intraocular Lens 181
- Dacryocystorhinostomy 183
- Enucleation 183
- Evisceration 184
- Pterygium Operation 184
- Chalazion Operation 185
- Indications and Methods of Tarsorrhaphy 185
- Incision and Drainage of Lacrimal Abscess 186
- Incision and Drainage of Lid Abscess 186

Index *187*

CHAPTER

2

Practical: Clinical Cases

SELF-ASSESSMENT QUESTIONNAIRE

These are representative samples—discussed as long case format. But they are interchangeable as long and short cases.

Long case involves structured case writing—like, any branch of clinical medicine, to be approached, examined (in detail), and documented properly up to provisional diagnosis, investigations and management plan.

For short cases: Chief complaints, positive and relevant negative findings to be written point-wise to establish a provisional diagnosis.

- **In practical**
  - *Long cases:* 2 cases = 20 × 2 = 40
  - *Short cases:* 4 cases = 5 × 4 = 20
  - *Spotter:* 10 = 10 × 1 = 10
- **Viva** = 10 + 10 = 20: One internal and one external in each group
- **Record** = 10
- **Total** = 100

Clinical cases and skill assessment procedures—have been prescribed for the undergraduate students, and published curriculum by the Indian Medical Council in 2018. All have been incorporated under the ocular examination of different cases with code.

LIST OF LONG AND SHORT CASES

- Immature cataract
- Mature/hypermature cataract
- Pseudophakia
- Aphakia
- Subconjunctival hemorrhage
- Phlyctenular conjunctivitis
- Bitot's spot
- Pinguecula
- Pterygium
- Phlyctenular conjunctivitis
- Symblepharon
- Corneal ulcer
- Leucoma
- Adherent leucoma
- Anterior uveitis
- Chalazion
- Blepharitis
- Chronic dacryocystitis
- Anterior staphyloma
- Phthisis bulbi

IMMATURE SENILE CATARACT (ISC) *(OP 7.3 AND OP 9.1)*

A. Patient's particulars:

B. Chief complaints with duration: Painless, progressive loss of vision in RE/LE for 6–12 months.

C. History of present illness: Elaborate the patient's complain. History of colored halos, polyopia, glare at night especially during driving, etc. Negative history—like, blunt trauma, use of systemic or topical steroids, etc.

D. Medical history: Diabetes, hypertension, cardiac problems on anticoagulants (blood thinners), COPD; history of COVID-19 recently (self or among family members).

For male patient, enquire about BHP on alpha-1 antagonist (Tamsulosin), etc.

E. Surgical history: History of any surgery in the same eye or other eye

JAYPEE BROTHERS

F. Personal and allergy history: Allergy to any eye drops, or systemic drug, alcoholism, smoking, etc.

G. General examination: Overall built, obesity, pallor, deep socket.

Look carefully for any lung and heart problem, check BP, pulse and *oxygen saturation* (PO_2), if possible.

H. Ocular examination:

- **Vision:**
  - *Uncorrected vision:* Finger counting—3 mt to 6/12
  - *Vision with glasses:* May improve
  - *Vision with pinhole, if possible:* Usually 6/6 or 6/9
- **Ocular movement:** Full
- **Eyelids:** Normal
- **Conjunctiva:** Normal; pinguecula or early pterygium may be present
- **Cornea:** Arcus senilis may be present. Corneal clear.
- **Anterior chamber:** Normal depth, clear
- **Iris:** Brown or dark brown, normal pattern, no iridodonesis
- **Pupil:** Circular, 3–4 mm.
  - *Direct and consensual light reflex:* Present (brisk).
  - *Pupillary area:* Grayish white appearance
  - *Iris shadow:* Present **(Fig. 2.1A)** [*Pupil may be dilated for examination. Pupillary reaction may be absent in that case.*]
- **Lens:** Grayish white, often radial spoke-like: **(Fig. 2.1B)**.
- **Purkinje's images** (better in a dark room):
  - 3rd image—present.
  - 4th image—may be visible and distorted in early IMSC.
- **Lacrimal sac:** No regurgitation on pressure over the sac region
- **Digital (finger) tension (IOP):** Normal.
- **Any other:** No abnormal head posture or no obvious defect

I. Summary:

J. Provisional diagnosis: Immature senile cataract of RE/LE

Self-assessment Questionnaire *(OP 7.2)*

1. **Define cataract:** (means – 'waterfall'). Any opacity in the lens or its capsule, causing visual impairment is called cataract.
2. **Prevalence of cataract blindness in India:** 66.2% among all blindness—National RAAB (Rapid Assessment of Avoidable Blindness) Survey, 2015–2019
3. **Causes of diplopia or polyopia:** (*see* page 5).
4. **Causes of colored halos:** (*see* page 5 and 19).
5. **Causes of painless progressive loss of vision:** (*see* page 2).
6. **Differential diagnosis:** Age-related macular degeneration (AMD); refractive error; diabetic retinopathy
7. **Points favor of diagnosis:**
   - Colored halos, glare at night, polyopia in early stage followed by painless progressive diminution of vision as symptoms.

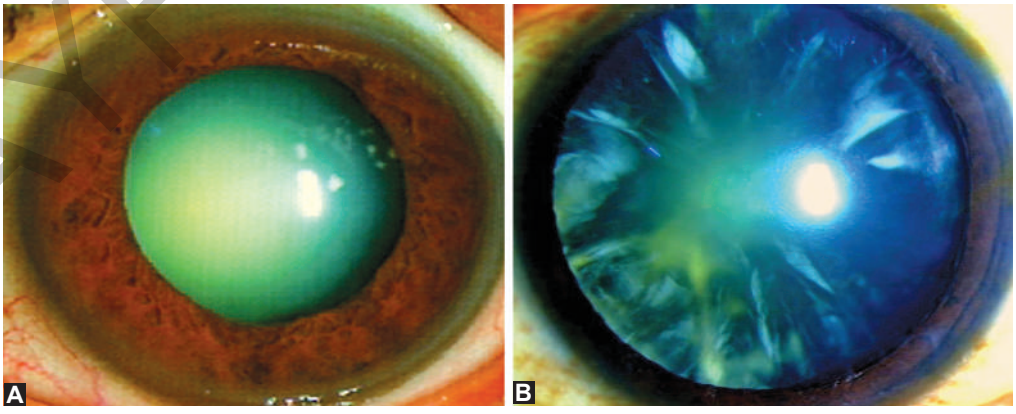

Figs. 2.1A and B: (A) Iris shadow present; (B) Immature senile cataract.

JAYPEE BROTHERS

- On examination—reduced spectacles—corrected vision, grayish white opacity of lens with iris shadow and presence of 4th Purkinje's image

8. **Stages of maturation of cataract:** *See* page 124
9. **Management of immature senile cataract:**
   - Dark room examination and refraction.
   - If the vision improves satisfactorily with glasses—prescribe glasses and ask the patient to come for follow up at a regular interval of 3–6 months.
   - If the vision does not improve satisfactorily—advise for cataract surgery.
10. ***Timing of surgery:*** In spite of spectacles correction when the vision is reduced to such an extent that the patient cannot carry out his day-to-day work efficiently.
11. **Reasons for cataract operation:**
    - For regaining visual loss caused by cataract.
    - To correct the early visual symptoms, and also to correct preoperative high plus or minus power
    - To avoid difficult surgery as in mature stage when the cataract is hard
    - To prevent future complications of hypermature stage, e.g., lens-induced glaucoma, iridocyclitis, and subluxation or dislocation of lens.
12. **Investigations before cataract operation:**
    Details ocular examination:
    - Slit lamp evaluation of the cornea for specular reflection to see endothelial cell status.
    - Dilatation of the pupil to know:
      - Extent of dilatation
      - Presence of synechia
      - Grade of cataract
      - Any subluxation or zonular weakness
      - Presence of pseudo-exfoliation
      - Vitreous and fundus details.
    - Applanation, non-contact or Schiotz tonometry to know exact IOP.
    - *Syringing:* To know the patency of nasolacrimal passage
    - Specular microscopy to study corneal endothelial cell count and morphology.
    - Macular optical coherent tomography (OCT)
    - USG B-scan (if fundus details—not clearly visible)
    - Biometry—to calculate IOL power
    - Conjunctival swab for culture and sensitivity (not a routine).

    Systemic
    - *Blood sugar (PP), HbA1C:* In presence of high blood sugar, there is higher chance of delayed wound healing, wound infection and endophthalmitis. Suboptimal visual outcome in presence of pre-existing diabetic retinopathy. Even, cataract surgery may also aggravate it.
    - *Blood pressure:* more chance of intraoperative bleeding including suprachoroidal hemorrhage, sometimes, cardiovascular accident.
    - *ECG,* and cardiological check-up if necessary
    - *Dental check-up:* To avoid patient with dental/gum infection
    - *Physician's check-up*, if necessary
13. **Important medicine-intake history before surgery:**
    - *Antidiabetic medicines*
    - *Blood thinners:* Like, aspirin; clopidogrel, or similar, etc. It is to be stopped 5 days before cataract surgery, as there is chance of intraoperative bleeding.
    - *Alpha-1 adrenergic blockers:* Tamsulosin, which is used for BHP in male and sometime, for urinary incontinence in female. Poor pupillary dilatation and *intraoperative floppy iris syndrome (IFIS)* are the problems during cataract surgery. IFIS is characterized by progressive miosis, billowing of flaccid iris which tends to prolapse through the wounds during surgery, especially in phaco. Pupil-expand devices (ring or hooks) are used commonly in these cases.
14. **Surgical management in immature cataract:** Phacoemulsification with foldable posterior chamber intraocular lens implantation (phaco with foldable PCIOL), alternately, manual small incision cataract surgery (SICS) with PMMA PCIOL

JAYPEE BROTHERS

Or, conventional extracapsular cataract extraction (ECCE) with PCIOL with 4–5 stitches.

15. **Cataract surgery details with complications:** *See* Page: 177–181

MATURE SENILE CATARACT (MSC) *(OP 7.3)*

A. Patient's particulars:

B. Chief complaints with duration:

- Gradual, painless, complete loss of vision in RE/LE for few weeks to months
- White opacity—noticed for few days/weeks

C. History of present illness: Elaborate the patient's complain. History of gradual, painless loss of vision in RE/LE for few months. Recently, complete loss of vision for few weeks or so. White opacity noticed by patient, or relatives for few days/weeks. The loss of vision is not sudden onset. No history of blunt trauma; or use of systemic or topical steroids, etc.

D. Medical history: Diabetes, hypertension, cardiac problems on anticoagulants (blood thinners), COPD, for male patient, enquire about BHP on alpha-1 antagonist (Tamsulosin), etc.

E. Surgical history: History of any surgery in the same eye or other eye

F. Personal and allergy history: Allergy to any eye drops, or systemic drug, alcohol intake, smoking, etc.

G. General examination: Overall built, obesity, pallor, deep socket.

H. Look carefully for any lung and heart problem, check BP, pulse and oxygen saturation (PO_2), if possible.

I. Ocular examination:

- **Vision:**
  - *Uncorrected vision:* Only perception of light (PL). Projection of rays (PR)—accurate all quadrants
  - *Vision with glasses and pin-hole:* No improvement
- **Ocular movement:** Full
- **Eyelids:** Normal
- **Conjunctiva:** Normal; pinguecula or early pterygium may present
- **Cornea:** Arcus senilis may be present. Corneal clear.
- **Anterior chamber:** Normal depth, clear
- **Iris:** Brown or dark brown, normal pattern, no iridodonesis
- **Pupil:** Circular, 3–4 mm.
  - *Direct and consensual light reflex:* Present (brisk).
  - *Pupillary area:* Milky white appearance
  - *Iris shadow:* Absent **(Fig. 2.2A)**
  - *Pupil may be dilated for examination. Pupillary reaction is absent in that case.*
- **Lens:** White *or* milky white **(Fig. 2.2B)**
- **Purkinje's images** (better in a dark room):
  - 3rd image—present.
  - 4th image—absent
- **Lacrimal sac:** No regurgitation on pressure over the sac region
- **Digital (finger) tension (IOP):** Normal
- **Any other:** No abnormal head posture or no obvious defect

J. Summary:

K. Provisional diagnosis: Mature senile cataract of RE/LE

HYPERMATURE CATARACT (HMSC) *(OP 7.3)*

Almost same as mature senile cataract—*except:*

- **In chief complaints:** Duration of complete loss of vision—more
- **On examination:**
  Color of lens: Pearly white ('mother of pearl' appearance) in Morgagnian cataract.
  Brown-colored lens nucleus may sink at the bottom of the capsular bag **(Fig. 2.3A)**.
  Calcified white spots on the anterior capsule in sclerotic cataract **(Fig. 2.3B)**.

Self-assessment Questionnaire

1. **Differential diagnosis:** Immature cataract
2. **Define mature cataract:** When the entire lens cortex becomes opaque and white, it is called mature cataract. Crystalline lens swells up due to imbibition of water.
   Points favor of mature cataract:
   - *Visual acuity:* Reduced to PL only with accurate PR

JAYPEE BROTHERS

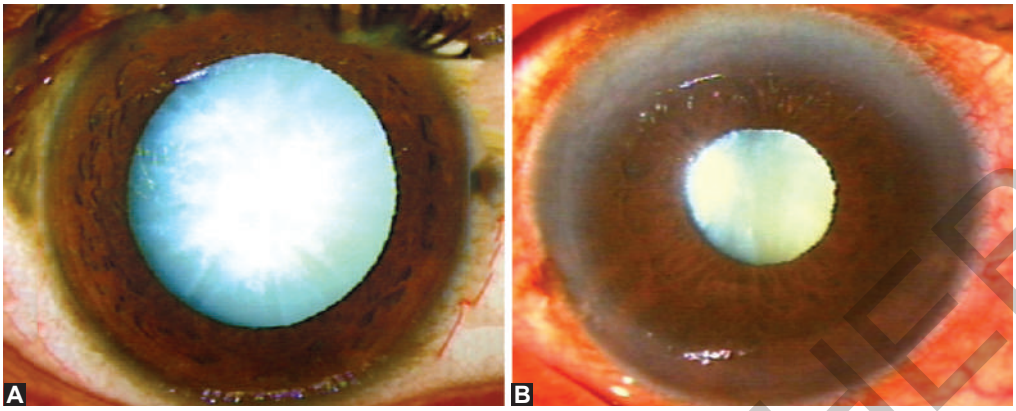

Figs. 2.2A and B: Iris shadow absent; (B) Mature cataract.

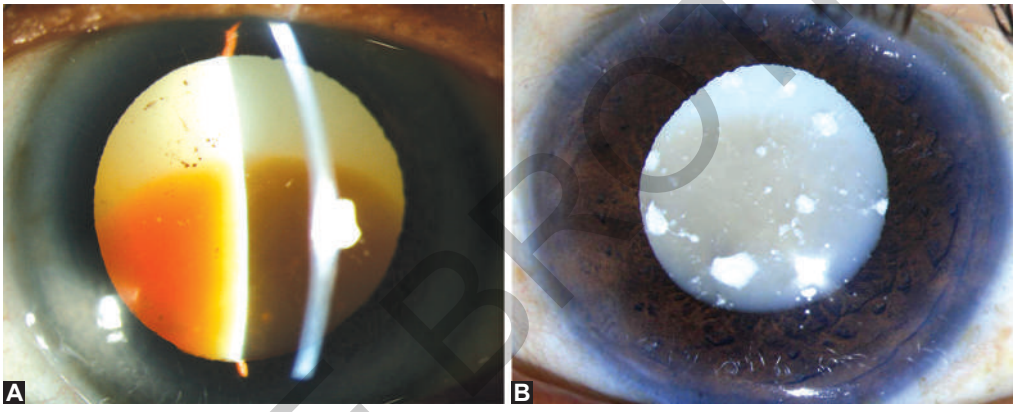

Figs. 2.3A and B: (A) Hypermature Morgagnian cataract; (B) Hypermature sclerotic cataract.

- Absence of iris shadow
- Color of lens—white or milky white
- Absence of 4th Purkinje's image

3. **Management of mature cataract:** Extracapsular cataract extraction with posterior chamber IOL implantation (ECCE with PCIOL) under peribulbar block or topical anesthesia.
   Phacoemulsification with foldable PCIOL is mostly preferred method. Alternately, manual SICS with single-piece PCIOL.
   Very rarely, conventional ECCE with PCIOL with sutures.
4. **Timing of surgery:** As soon as possible after both ocular and systemic investigations.
   If not operated early, the possible complications are: Hypermature cataract, phacolytic glaucoma in morgagnian type, zonular dehiscence with subluxation, dislocation of lens and eventually, patient may present with blind eye with inaccurate PR or with no PL.
   Also, cataract surgery becomes more difficult as the nucleus becomes harder and zonules are weaker with time.
5. **Investigations in this case:** Same as in immature cataract. Additionally, USG B-scan is a must to rule out any posterior segment pathology.
6. **Possible problems encountered during cataract surgery in mature cataracts:** As the lens nucleus is bigger and harder with some degree of zonular weakness—there is more chance of:
   - Corneal endothelial cell damage
   - Posterior capsular rent with vitreous loss

JAYPEE BROTHERS

TABLE 2.1: Differences between immature and mature cataract.

	Immature cataract	*Mature cataract*
A. Symptoms:	• Partial loss of vision • Diplopia/polyopia • Rainbow halos	• Total loss of vision. • White opacity noticed by patients or relatives
B. Sign:		
1. Visual acuity	• Vision reduced to varying degree	• Vision reduced to HM or PL
2. Color of the lens	• Gray/grayish white	• White/pearly white
3. Iris shadow	• Present	• Absent
4. Purkinjie's images	• 3rd image is seen, 4th image may be distorted	• Only 3rd image is seen, 4th image is absent
5. Fundal glow	• Present	• Absent
6. Retinoscopy	• Possible	• Not possible
7. Spectacles correction	• May improve vision	• Does not improve vision

TABLE 2.2: Differences between cortical and nuclear cataract.

Cortical cataract	*Nuclear cataract*
1. Usually starts at late 50s	1. Tends to occur earlier than cortical variety
2. Starts with uniocular diplopia or polyopia and colored halos	2. No such symptoms
3. Gives rise to index hypermetropia	3. Gives rise to index myopia. Neutralizes the 'plus power' of presbyopia (*'Second sight'*)
4. Appears grayish to white to milky white with maturity of the cataract	4. Appears yellow, brown or black with progression of cataract
5. Progress is gradual and ultimately progress into hypermature stage with liquefaction of cortex	5. Progress is very slow and the entire lens functions as a nucleus, but hypermaturity does not occur
6. More chance of lens-induced secondary glaucoma	6. Little chance of lens-induced secondary glaucoma

- Zonular dehiscence
- Nucleus drop into the vitreous cavity
- Wound-related problems (e.g., wound burn in case of phacoemulsification)

7. **Differences between immature and mature cataract (Table 2.1)**
8. **Differences between cortical and nuclear cataract (Table 2.2)**
9. **Current grading system of cataract:** *See* page 125

APHAKIA *(OP 7.4)*

A. Chief complaints with duration: Gross dimness of vision without glasses after cataract extraction for (certain duration).

B. History of present illness: Elaborate the patient's complain. History of loss of vision without glasses in RE/LE for few years or months after cataract surgery. He also gives the distortion of objects after wearing thick-lens spectacles.

C. Medical history: Diabetes, hypertension, cardiac problems on anticoagulants (blood thinners), COPD, etc.

D. Surgical history: History of cataract surgery in the same eye. There may be history of some complications during or after the cataract surgery.

E. Personal and allergy history: Allergy to any eye drops, or systemic drug, alcohol intake, smoking, etc.

F. General examination: Overall built, obesity, pallor, etc.

G. Look carefully for any lung and heart problem, check BP, pulse and oxygen saturation (PO_2), if possible.

JAYPEE BROTHERS

H. Ocular examination:

- **Distant vision:**
  - Unaided—finger counting—1 mt.
  - With glasses (thick plus power lens):
- **Near vision:** Unable to see near objects without glasses.
- **Conjunctiva:** Scar mark may be present.
- **Cornea:** Limbal scar with suture marks 120–180° in the upper half may be present.
- **Anterior chamber:** Deep.
- **Iris:** (a) Iridodonesis or tremulousness of the iris, (b) Peripheral buttonhole iridectomy mark(s) at 11 o'clock and/or 1 o'clock position **(Fig. 2.4)**.
- **Pupil:** Jet-black appearance—3 mm size; direct and consensual light reflexes: present and brisk.
- **Lens:** Absence of 3rd and 4th Purkinje's images.
- **Lacrimal sac:** Normal.
- **Digital (finger) tension:** Normal.

I. Provisional diagnosis: Aphakia—RE/LE

Self-assessment Questionnaire

1. **Define aphakia:**
   - *Anatomically,* aphakia means absence of crystalline lens from the eyeball.
   - *But optically,* aphakia means absence of crystalline lens from its normal position (i.e., from the pupillary area).
2. **Causes of aphakia:**
   - Congenital primary aphakia (very rare).
   - Operative—cataract operation, needling operation and couching (an ancient form of cataract surgery, where cataractous lens was forcibly pushed backward into the vitreous cavity).
   - Traumatic/spontaneous dislocation of the lens into the vitreous.
3. **Differences from posterior dislocation of lens (traumatic or spontaneous):**
   - History of blunt injury to the eye
   - No history of surgery
   - No limbal scar mark
   - No iridectomy mark
   - Vision is poor even with glasses because of other complications.
   - Usually, there is no astigmatism
   - Associated uveitis or secondary glaucoma
4. **Mechanism and causes of iridodonesis:** Normally, iris rests upon the anterior surface of the lens, but in aphakia there is loss of support.
   The causes are:
   - Aphakia
   - Subluxation of the lens
   - Dislocation of the lens
   - Shrunken sclerotic hypermature cataract
   - Buphthalmos
   - Sometimes, in pseudophakia.
5. **Phakia and pseudophakia (definition):**
   - *Phakia* means eyeball with natural crystalline lens. Normal person is phakic and the eye is called *phakic eye.*
   - *Pseudophakia* means eyeball with an artificial lens, i.e., with an IOL. The eye is called *pseudophakic eye.*
6. **Normal dioptric power of eye:**
   Total = + 58 D to + 60 D.
   Lens = + 15 D to + 18 D and cornea = 43 D to + 45 D.
7. **What are the optical defects in aphakia?**
   - High hypermetropia.
   - Astigmatism *"against the rule"*, since cornea is flatter in vertical meridian than the horizontal. This due to fibrosis or contraction of limbal scar.
   - Loss of accommodation.
8. **Treatment of aphakia:**
   - Spectacles correction
   - Contact lens

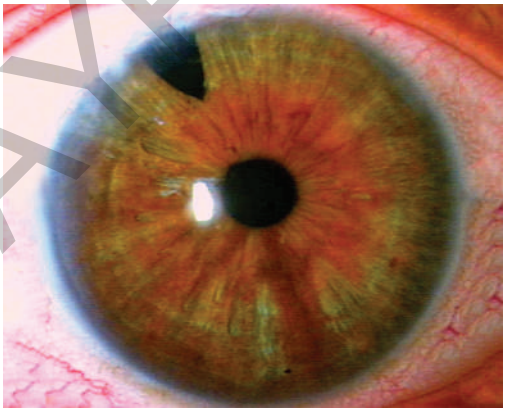

Fig. 2.4: Aphakia.

JAYPEE BROTHERS

- Secondary intraocular lens (IOL) implantation:
  - Anterior chamber IOL (AC IOL)
  - Posterior chamber scleral fixation IOL (SF IOL), also called glued IOL
  - Iris retro-fixated posterior chamber IOL
  - Sulcus-supported posterior chamber IOL, if posterior capsue is intact.

9. **Prescription of aphakic glasses:** If the patient is emmetropic preoperatively—the spectacles power will be approximately for:
   - Distant vision = + 10.0 D Sph with + 2.00 D Cyl × 180°
   - Near vision = + 13.0 D Sph with + 2.00 D Cyl × 180°

   Two glasses are given separately for distant and near vision. Bifocal glasses are usually not prescribed, because the patient cannot tolerate the high plus-power bifocal glasses due to more spherical and prismatic aberrations.

   + 3.00 D Sph is added to near vision as there is loss of accommodation due to absence of lens in aphakia and the comfortable reading distance is 33 cm (i.e., 100/33 = + 3.0 D).

   Glasses are prescribed usually 4 to 6 weeks after the surgery as by this time proper healing of the wound is completed.

   Aphakia glasses are presently required in operated bilateral congenital cataract before 2 years of age. Here, the spectacle power is approx +14 to +18 D Sph determined after refraction.

10. **Disadvantages of aphakic glasses:**
    - An image magnification of about 25–30%.
    - Spherical aberration producing "pincushion effect".
    - Lack of physical coordination in finer movements.
    - Roving ring scotoma or 'Jack-in-the-box' phenomenon due to high prismatic aberration.
    - Reduced peripheral field and poor eccentric visual acuity.
    - *In monocular cases*—there will be high aniseikonia (difference in retinal image sizes between two eyes) resulting in diplopia.
    - High degree of chromatic aberration.
    - Physical inconvenience and cosmetic deficiency due to thick and heavy aphakic spectacle lenses.

11. **Advantages and disadvantages of contact lens in aphakia:**

    Advantages:
    - Image magnification is about 7–8% and can be well tolerated.
    - All the aberrations are less, so there is increase in visual field and improvement of hand-eye coordination and spatial sensation.
    - In monocular cases, diplopia is almost absent.
    - Cosmetically, it is well accepted.
    - Valuable in unilateral operated congenital cataract before in children

    Disadvantages:
    - Lack of dexterity in old patients.
    - Foreign body sensation.
    - Lens spoilage (due to loss, breakage, dislodgement)—leading to high recurrent expenditure.
    - Corneal problems, like erosions, ulceration, vascularization, edema, etc., may be troublesome in future.

12. **Advantages and disadvantages of IOL implantation (pseudophakia):**

    Advantages:
    - Image magnification is virtually nil.
    - No spherical or prismatic aberration.
    - No aniseikonia—so rapid return of binocularity.
    - Normal peripheral visual field and eccentric vision.
    - Freedom from handling the optical devices (e.g., contact lens or heavy spectacles).
    - Good hand-eye coordination and spatial sensation.
    - Cosmetically, best accepted by the patient.

JAYPEE BROTHERS

For detailed information on ophthalmology books, visit our website www.jaypeebrothers.com, for detailed information on ophthalmology books, visit our website www.jaypeebroth

Ophthalmology
Oral and Practical

Key Features

- An ideal book for undergraduate medical students, optometrists, or healthcare professionals who require a comprehensive information on ophthalmology
- According to the new undergraduate curriculum by the National Medical Commission (NMC)
- Competency-based medical education (CBME) in common eye disorders
- Bulleted and easy-to-read format
- Separate chapters on instruments, viva voce and common eye surgeries
- Updated with latest medical and surgical management including latest investigations
- Changes have been done as suggested by the students and teachers.

Samar K Basak MBBS MD (AIIMS) DNB FRCS (Glasgow) is Director and Founder Member of Disha Eye Hospitals, Kolkata, West Bengal, India. He looks after cataract, cornea and external eye diseases, and eye bank services. He is the recipient of 10 gold medals for best paper awards, Dr RP Dhanda, and Dr P Siva Reddy international award from the All India Ophthalmological Society. He has received several awards, including the prestigious Prof LP Agarwal Oration by AIIMS, New Delhi, India. Internationally, he has received several awards for 'Best Video' and 'Best Poster' and 'Best Paper' in American Academy of Ophthalmology, ESCRS, and ASCRS Annual Meetings. He has also been honored with the 'Achievement Award' and the 'International Ophthalmic Education Award' by AAO in 2008. In 2015, he received AAO's 'Senior Achievement Award'. He is an Examiner in FRCS (Glasgow) and DNB in ophthalmology. He has written six other books in ophthalmology and 49 publications in peer-reviewed journals. He is currently serves a reviewer for many prestigious peer-reviewed journals. He is involved in surgery skill transfer in different parts of the country, and internationally, on Manual SICS, Phacoemulsification, DSEK, DMEK, DALK and Boston Keratoprosthesis. He loves to pursue his unique hobby on special stamps collection, 'Ophtha-Philately', which has been recognized by the International Philatelic Society. He has also written a book on Ophtha-Philately.

Soham Basak MBBS MS DNB FRCS (Glasgow) is a young Consultant of Cataract, Cornea and External Disease, Disha Eye Hospitals, Kolkata, West Bengal, India. He is also trained in corneal diseases from the Massachusetts Eye and Ear Infirmary, Boston, USA. He is the recipient of 'Dr G Venkataswamy Gold Medal' from Aravind Eye Care System, Madurai, Tamil Nadu, India, for Best Postgraduate Resident. He is involved in postgraduate teaching. Internationally, he has received 'Achievement Award' from the AAO in 2019 and Best Paper Award in Cornea in AAO 2020. He has 12 publications in peer-reviewed journals, and he is a reviewer of Indian Journal of Ophthalmology and Cornea.

Printed in India

Available at all medical bookstores
or buy online at www.jaypeebrothers.com



JAYPEE BROTHERS
Medical Publishers (P) Ltd.
EMCA House, 23/23-B, Ansari Road,
Daryaganj, New Delhi - 110 002, INDIA
www.jaypeebrothers.com

Join us on facebook.com/JaypeeMedicalPublishers

Shelving Recommendation
OPHTHALMOLOGY

