osite www.jaypeebrothers.com, for detailed information of radiology books, visit our website www.jaypeebrothers.com

A Teaching Atlas of Case Studies in Diagnostic Imaging

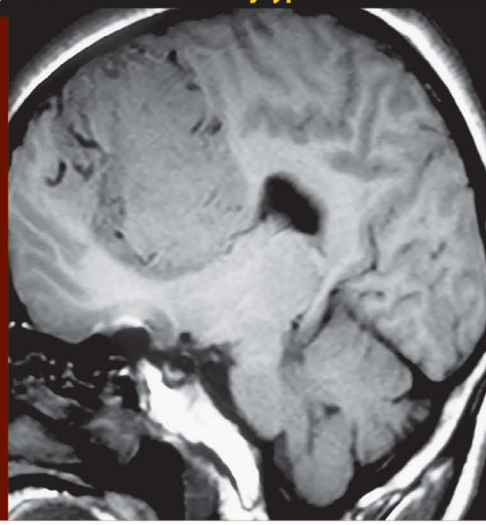

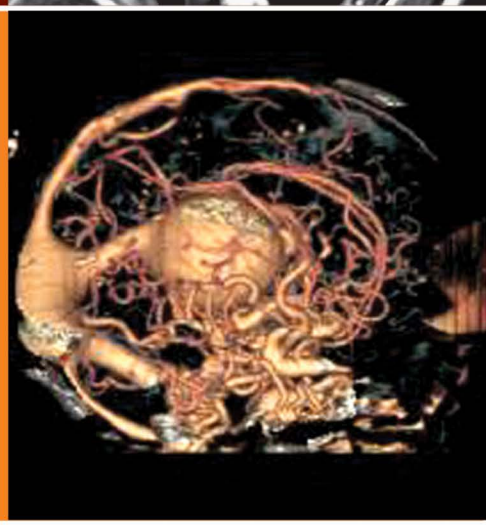

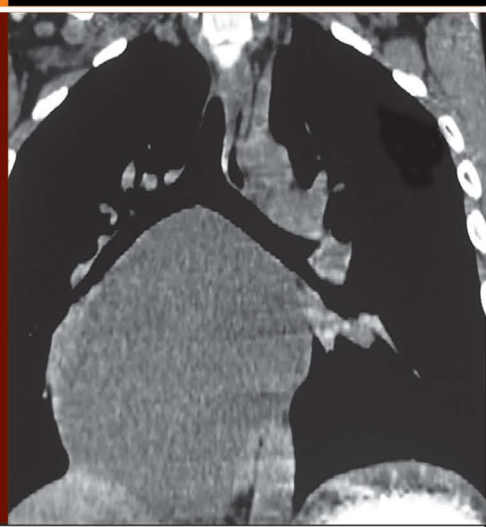

Funsho Komolafe
M Haroun Dahniya

Foreword
SB Lagundoye

2nd Edition

JAYPEE

CONTENTS

1. Chest and Respiratory Tract Imaging **1**

2. Musculoskeletal System Imaging **91**

3. Urogenital System Imaging **196**

4. Gastrointestinal System Imaging **297**

5. Neurological System Imaging **399**

6. Small-parts Imaging **508**

Index **551**

CHAPTER

4 Gastrointestinal System Imaging

CASE 1

A 2-day-old male baby presented with progressive abdominal distension and nonpassage of meconium. A plain lateral shoot through abdominal radiograph was done.



FIGURE 1

There is gaseous distension of the sigmoid colon and rectum, extending almost to the anal verge. The marked distension of the rectum without filling the urinary tract suggests the absence of rectourinary fistula. Note the absence of the caudal segment of the sacrum.

DISCUSSION

See discussion given under Case 2, page 299.

FURTHER READING

See further reading given under Case 2, page 300.

JAYPEE BROTHERS

CASE 2

A male baby presented at 3 days of age with progressive abdominal distension, fecaluria, and nonpassage of meconium. A colostomy was performed on him, followed by a pressured colostography at the age of 6 months, prior to definitive corrective surgery.

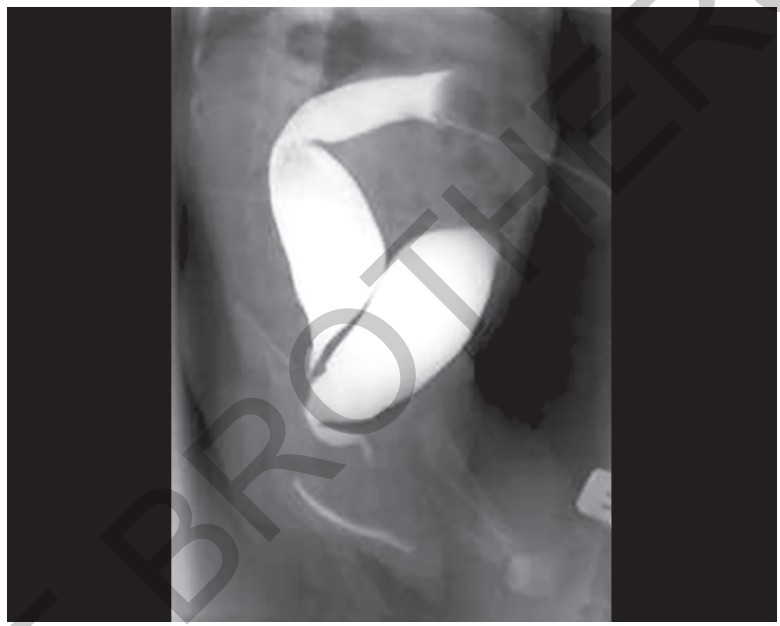

FIGURE 1

A distal colostogram showing contrast-filled sigmoid and rectum. Note the termination of rectal contrast column above the mid-pelvic cavity and the filling of the urinary bladder with contrast via a rectourethral fistula.

Courtesy: Dr Adekunle Abdulkadir.

DISCUSSION

Anorectal malformation (ARM) is a common congenital anomaly with an incidence of 1 in 5,000 live births. Fecaluria and obstructive gastrointestinal symptoms are the earliest diagnostic pointers, while imperforate anus is the hallmark clinical sign. When associated with genitourinary fistula, it permits an outlet for fecal matter, and ARM may therefore go unnoticed in the child for years. The roles of radiological imaging in ARM are to determine the level of obstruction, identify the presence and location of any associated fistula, and diagnose any associated anomalies. ARM is classified as high or low depending on whether or not the rectal pouch lies above or below the level of the puborectalis sling. This level is the M-line and it correlates on the radiograph to the line joining the ischial spines. Available imaging methods to classify ARM include prone cross-table lateral abdominal radiograph and transperineal ultrasound (US) to determine the colon pouch-perineal distance. Fistulae may be demonstrated by distal colostography, or by retrograde or micturating cystourethrography. However, MRI has proven to be the single-stop modality to answer all the crucial questions such as level and type of malformation, type of fistula, developmental state of the sphincter muscle complex, and the presence of associated anomalies.

JAYPEE BROTHERS

FURTHER READING

1. Abdulkadir AY, Abdur-Rahman LO, Adesiyun OM. Nonfluoroscopic pressure colostography in the evaluation of genitourinary fistula of anorectal malformations: Experience in a resource poor environment. Pediatr Radiol. 2009;39(2):132-6.
2. Alamo L, Meyrat BJ, Meuwly JY, Meuli RA, Gudinchet F. Anorectal Malformations: Finding the Pathway out of the Labyrinth. Radiographics. 2013;33(2):491-512.
3. Endo M, Hayashi A, Ishihara M, Maie M, Nagasaki A, Nishi T, et al. Analysis of 1,992 patients with anorectal malformations over the past two decades in Japan. Steering Committee of Japanese Study Group of Anorectal Anomalies. J Pediatr Surg. 1999;34:435-41.
4. McHugh K. The role of radiology in children with anorectal anomalies with particular emphasis on MRI. Eur J Radiol. 1998;26(2):194-9.

JAYPEE BROTHERS

CASE 3

A 1-week-old male presented with lumbar mass and features of partial intestinal obstruction.

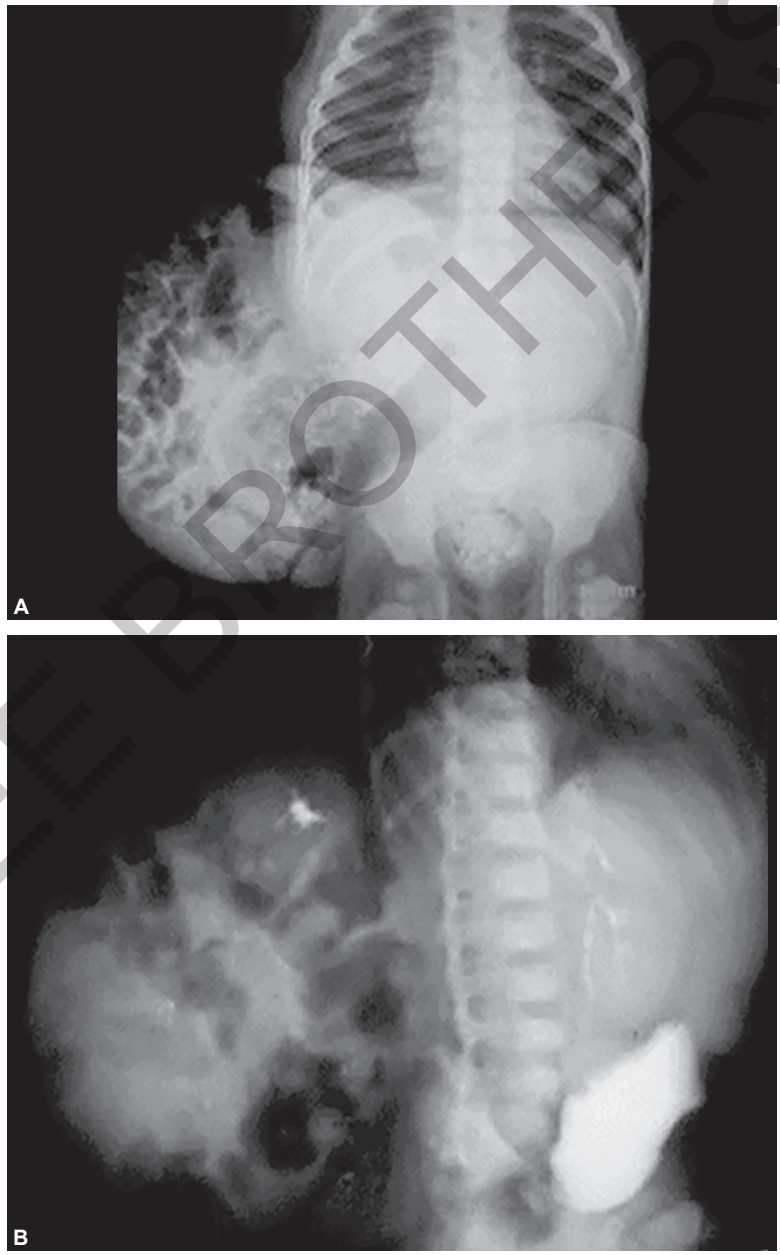

FIGURES 1A AND B

Plain abdominal radiograph and intravenous urogram. Note the right kidney among the hernial contents.

JAYPEE BROTHERS

DISCUSSION

See discussion given under Case 4, page 304.

FURTHER READING

See further reading given under Case 4, page 304.

JAYPEE BROTHERS

CASE 4

A male baby presented few days after birth with a congenital right lumbar swelling.



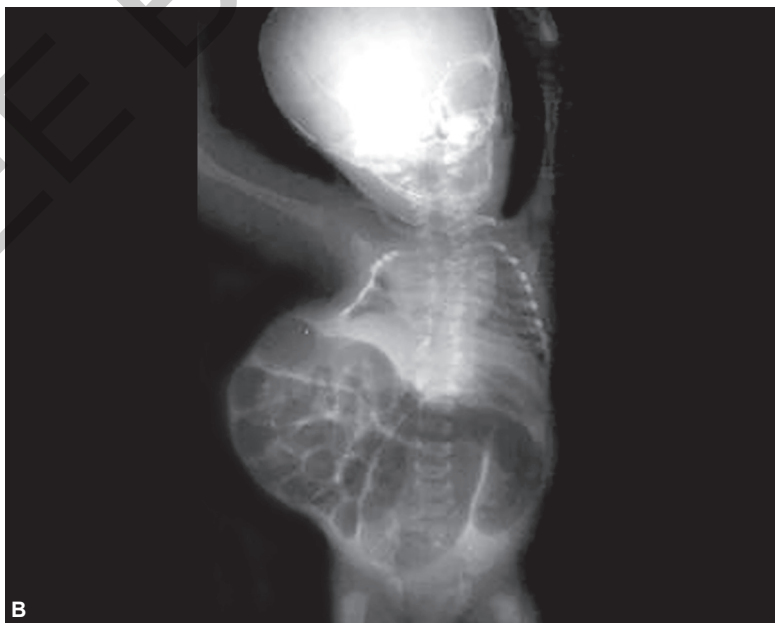

FIGURES 1A AND B

Photograph showing the right lumbar mass and a plain radiograph showing gas-filled herniated bowel. Note costovertebral anomalies with absent right 7–12th ribs ***(For color version, see Plate 2).***

Courtesy: Dr Adekunle Abdulkadir, Dr Luqman Abdur-Rahman, and Dr Anas Ismail.

JAYPEE BROTHERS

DISCUSSION

Hernias such as inguinal, femoral, and umbilical varieties constitute up to 98.5% of external abdominal hernias. Lumbar and gluteal hernias account for the remaining 1.5%. Lumbar hernia has a male-to-female prevalence of 3:1 and left-to-right ratio of 2:1. It is acquired in about 80% of cases. Congenital lumbar hernia is often reported in association with costovertebral anomalies thought to be due to somatic defects occurring between the 3rd and 5th weeks of embryogenesis. Other reported associated anomalies include anorectal malformations, sacral dysgenesis, and genitourinary anomalies. Although the diagnosis can be made clinically, imaging is required to define associated anomalies, guide management, and evaluate treatment and assess complications.

FURTHER READING

1. Aguirre DA, Santosa AC, Casola G, Sirlin CB. Abdominal wall hernias: Imaging features, complications, and diagnostic pitfalls at multi-detector row CT. Radiographics. 2005;25(6):1501-20.
2. Akçora B, Temiz A, Babayi it C. A different type of congenital lumbar hernia associated with the lumbocostovertebral syndrome. J Pediatr Surg. 2008;43(1):21-3.
3. Cornier AS, Ramirez N, Carlo S, Reiss A. Controversies surrounding Jarcho-Levin syndrome. Curr Opin Pediatr. 2003;15(6):614-20.
4. Miller PA, Mezwa DG, Feczko PJ, Jafri ZH, Madrazo BL. Imaging of abdominal hernias. Radiographics. 1995;15(2):333-47.

JAYPEE BROTHERS

CASE 5

A 7-day-old premature male infant admitted in the intensive care unit was noted to have progressive abdominal distension and bloody stool. Abdominal ultrasonography showed free peritoneal fluid. A kidney, ureter, and bladder (KUB) was done 6 hours later.

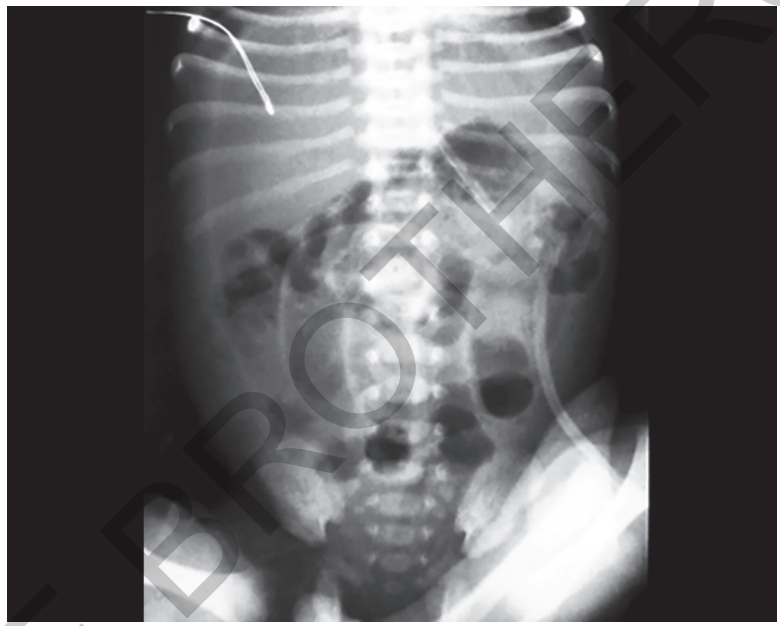

FIGURE 1

Supine kidney, ureter, and bladder (KUB) shows a large pneumoperitoneum with dilated loops of small and large bowel.



FIGURE 2

Lateral decubitus radiograph shows a long air–fluid level, confirming the massive pneumoperitoneum. Features are those of necrotizing enterocolitis (NEC).

JAYPEE BROTHERS

DISCUSSION

Necrotizing enterocolitis (NEC) is a condition of idiopathic etiology affecting premature neonates, usually presenting with feeding intolerance, abdominal distension, and bloody stool. It may progress to bowel perforation and peritonitis. The role of imaging is to establish the diagnosis. Abdominal ultrasonography may demonstrate intramural gas as well as free peritoneal fluid. Abdominal radiograph may also show pneumatosis intestinalis, bowel distension, or frank pneumoperitoneum.

FURTHER READING

1. Coursey CA, Hollingsworth CL, Wriston C, Beam C, Rice H, Bisset G. Radiographic Predictors of Disease Severity in Neonates and Infants With Necrotizing Enterocolitis. Am J Roentgenol. 2009;193:1408-13.
2. Epelman M, Daneman A, Navarro OM, Morag I, Moore AM, Kim JH, et al. Necrotizing enterocolitis: Review of state-of-the-art imaging findings with pathologic correlation. Radiographics. 2007;27(2): 285-305.
3. Kosloske AM, Musemeche CA, Ball WS Jr, Ablin DS, Bhattacharyya N. Necrotizing enterocolitis: value of radiographic findings to predict outcome. AJR Am J Roentgenol. 1988;151(4):771-4.

JAYPEE BROTHERS

CASE 6

A 2-year-old girl presented with abdominal pain. Abdominal ultrasound was first performed, followed by CT, MRI, and MRCP.

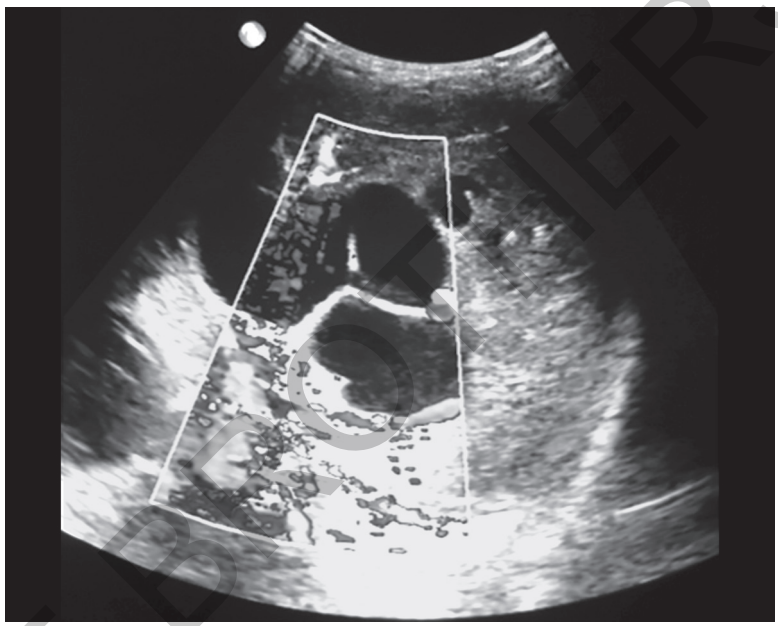

FIGURE 1

Abdominal ultrasound with Doppler showing multiple, cystic nonvascular structures in the liver.

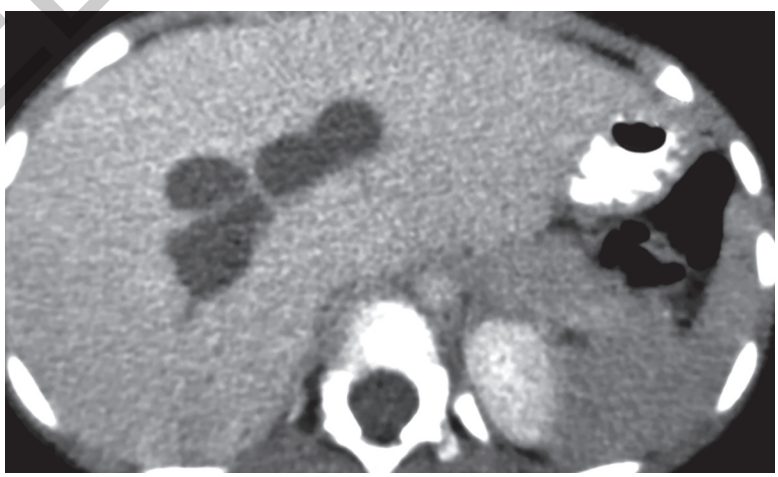

FIGURE 2

Axial contrast CT image showing the nonenhancing cysts.

JAYPEE BROTHERS

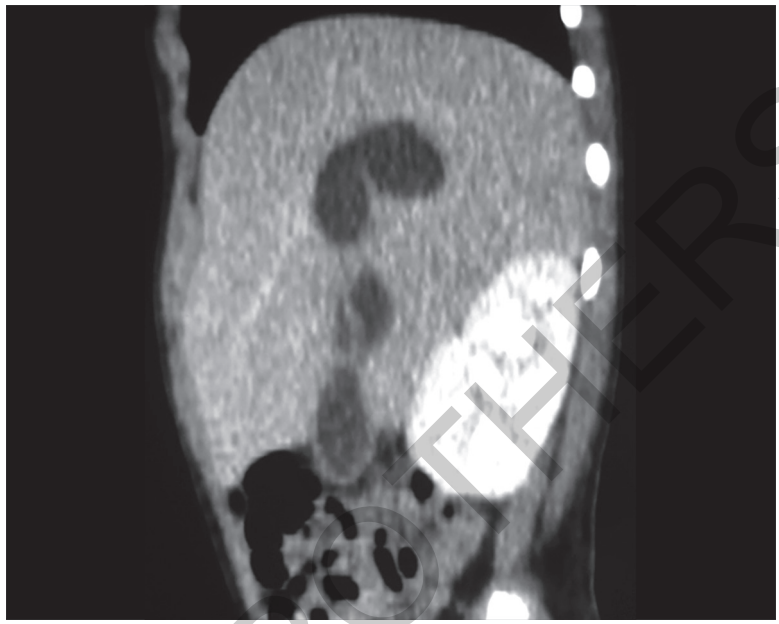

FIGURE 3

Sagittal reformatted contrast-enhanced CT image shows several of the cystic structures to be communicating.

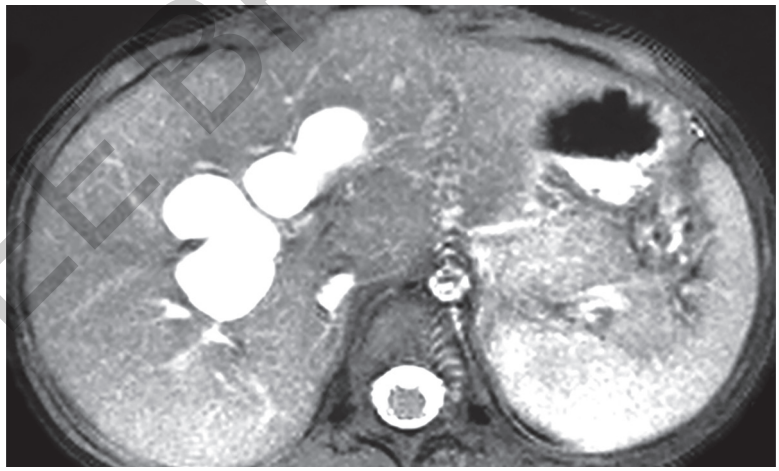

FIGURE 4

T2-weighted axial MRI confirms the communicating cysts.

JAYPEE BROTHERS

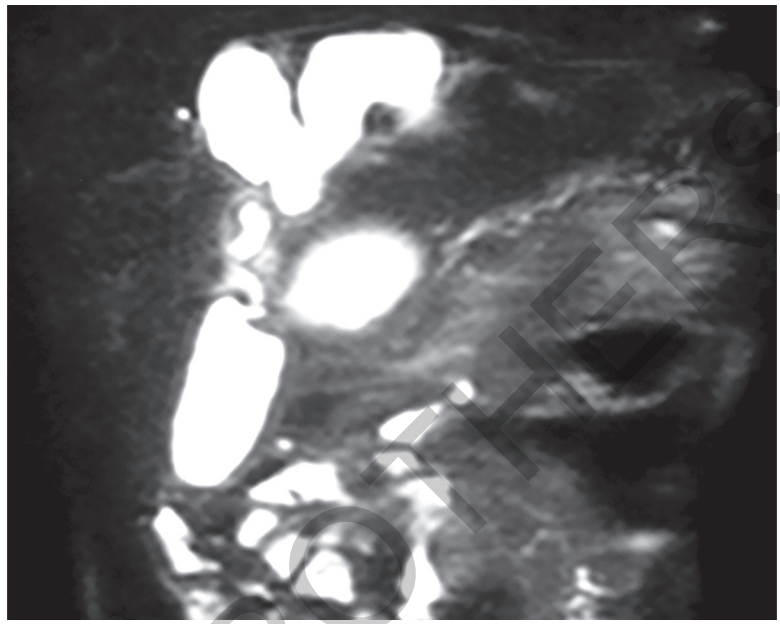

FIGURE 5

In magnetic resonance cholangiopancreatography (MRCP) the gallbladder and cystic duct are demonstrated. At least one of the cysts is extrahepatic.

Diagnosis: Choledochal cyst, probably Todani Type IV.

DISCUSSION

A choledochal cyst is a congenital anomaly with cystic dilatation of the biliary ductal system, with involvement of the intra- or extrahepatic system or both. Five major types have been described by Todani et al. Ultrasonography is the usual initial preferred examination, but it may be impossible to differentiate a choledochal cyst from a hepatic cyst or a pancreatic pseudocyst. As in this case, CT and MRI will be required for a more definitive diagnosis.

FURTHER READING

1. Irie H, Honda H, Jimi M, Yokohata K, Chijiiwa K, Kuroiwa T, et al. Value of MR cholangiopancreatography in evaluating choledochal cysts. AJR Am J Roentgenol. 1998;171(5):1381-5.
2. Kim SH, Lim JH, Yoon HK, Han BK, Lee SK, Kim YI. Choledochal cyst: Comparison of MR and conventional cholangiography. Clin Radiol. 2000;55(5):378-83.
3. Todani T, Watanabe T, Narusue M, Tabuchi K, Okajima K. Congenital bile duct cysts: Classification, operative procedures, and review of thirty seven cases including cancer arising from choledochal cyst. Am J Surg. 1977;134(2):263-9.

JAYPEE BROTHERS

or detailed information of radiology books, visit our website **www.jaypeebrothers.com**, for detailed information of radiolo

A Teaching Atlas of
Case Studies in Diagnostic Imaging

Salient Features

- The book is designed for radiology residents preparing for their Fellowship or Board examinations.
- It is written in clear, lucid language and well laid out, and easy to follow and understand.
- Conventional procedures and applications have been incorporated.
- Each case is preceded by a short clinical history, the major radiological features of the images, the diagnosis, a short discussion, and suggestions for further reading.
- Readers are advised to make their own assessment of the images before referring to the description and the diagnoses.
- Practicing radiologists will also find the book useful as well as clinicians in areas relevant to their specialties.

Funsho Komolafe MBBS FMCR FWACS FICA FRCR graduated from University of Ibadan, Nigeria, and trained in Radiology at University College Hospital, Ibadan, Sacramento Medical Center of University of California, Davis, USA and Tokyo Metropolitan Cancer Detection Center, Japan. He has served as a Professor and Head of Radiology at University of Ilorin, Nigeria, Professor and Chairman of Radiology at King Faisal University, Dammam, Saudi Arabia, and adjunct Professor of Radiology, Ras Al-Khaimah Medical and Health Sciences University, United Arab Emirates (UAE). He was also a Senior Consultant Radiologist and Head of Radiology at Fujairah Hospital, UAE. He served on the Editorial Boards of several International Radiology Journals, and was for many years an Examiner in Radiology for the Nigerian and West African Postgraduate Medical Colleges. He also served for two consecutive terms as Dean of the University of Ilorin Medical School, Ilorin, Nigeria.

(Late) M Haroun Dahniya MBBS (Durham) DMRD FRCR FWACS graduated from the University of Durham, England. He was a Commonwealth Scholar, and had his Radiology training at the Royal Victoria Infirmary, Newcastle upon Tyne, obtaining the FRCR Fellowship in 1970. He served as Consultant Radiologist and Head of Radiological Services in his country of Sierra Leone between 1971 and 1982. He also served for almost 1 year as Consultant Radiologist, Bolton Group of Hospitals, Manchester, UK. In 1982, he was appointed as the pioneer Professor and Head of Radiology at the University of Maiduguri, Nigeria. He was at various times an examiner in Radiology for the Nigerian and West African Postgraduate Medical Colleges. He was appointed as Senior Consultant Radiologist at Al-Sabah Hospital, Kuwait in 1987, and was the Director of Kuwait Ministry of Health FRCR and FFR (RCSI) Radiology training programs. He subsequently served as Senior Consultant Radiologist at Fujairah Hospital, UAE.

Printed in India

Available at all medical bookstores
or buy online at www.jaypeebrothers.com



JAYPEE BROTHERS
Medical Publishers (P) Ltd.
EMCA House, 23/23-B, Ansari Road,
Daryaganj, New Delhi - 110 002, INDIA
www.jaypeebrothers.com

Join us on facebook.com/JaypeeMedicalPublishers

Shelving Recommendation
RADIOLOGY

