peebrothers.com, for detailed information on medicine books, visit our website www.jaypeebrothers.com, for detailed information on medicine books



ABC of ECG

Your guide for clinical and practice to quickly, accurately identify ECG abnormalities

From Basics to Bedside
A Manual for Students and Practitioners

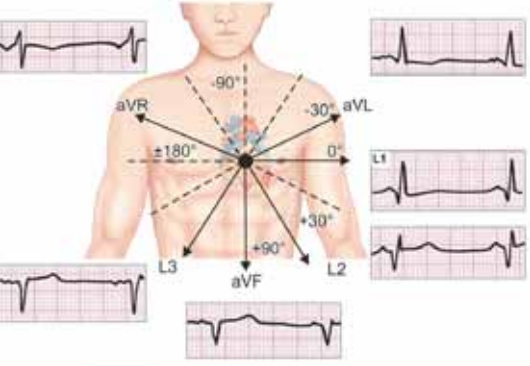

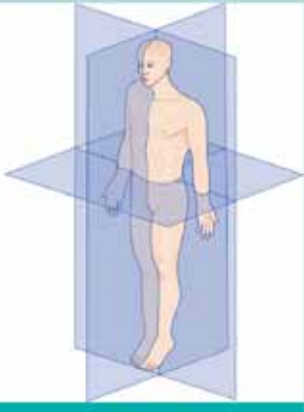

Archith Boloor

Foreword
Ramanath L Kamath

JAYPEE

Contents

1. **Introduction, Anatomical and Physiological Consideration** 1
   - ♦ **The Cardiac Conduction System: The Wiring System of the Heart 1**
     - Origin and Spread of Cardiac Excitation 1
     - Impulse Conduction through the Heart 3
     - SA Node of Keith and Flack 4
     - Internodal Conduction Pathways 4
     - The AV Node 5
     - The Bundle of His and the Bundle Branches 5
     - Purkinje Fibers or Purkinje Cardiomyocytes 6
   - ♦ **The Cardiac Cell Action Potential 7**
     - Action Potential in Cardiomyocytes 7
     - Refractory Period 10
   - ♦ **ECG Waveforms 12**
     - J Wave and U Wave 14
2. **Technical Aspects of ECG** 16
   - ♦ **What is an ECG? 16**
     - Utility of ECG: With ECGs We Can Identify 17
   - ♦ **ECG Paper and Timing 17**
     - ECG Leads 19
     - Placement of Electrodes 21
     - Standard Sites Unavailable 21
     - Precordial Leads 24
     - Color Codes Given by AHA 24
     - Limb Leads Electrodes 26
     - Ambulatory ECG Monitoring 33
3. **Rate, Rhythm, and Axis** 40
   - ♦ **Reading 12-Lead ECG 40**
   - ♦ **Rate 40**
     - Rule of 300 40

JAYPEE BROTHERS

- 6-Second Rule 42
- For Irregular Rhythms 42

♦ **Rhythm 43**
- Determine Regularity 43
- Normal Sinus Rhythm 44
- Sinus Bradycardia 44
- Sinus Tachycardia 45
- Sinus Pause 45
- Atrial Fibrillation 45
- Atrial Flutter 46
- Ventricular Fibrillation 46
- Ventricular Tachycardia 46
- Torsades de Pointes 47
- Supraventricular Tachycardia 47
- Types 47

♦ **Axis 48**
- The QRS Axis 48
- Cardiac Axis 48
- Genesis of QRS 48
- Determining the Axis 51

4. Waves, Segments, and Intervals 62

♦ **Understanding ECG Waveform 62**

♦ **P Waves 63**
- Assess the P Waves 63
- Abnormalities of P Wave 63
- Other P Wave Abnormalities 65

♦ **PR Interval 65**
- Atrioventricular Block 66
- Short PR Interval 67

♦ **PR Segment 69**

♦ **QRS Complex 70**
- Glassglow Scoring System 79
- Bundle Branch Blocks 80
- QRS Complex 82

♦ **J Point 86**

♦ **ST Segment 86**

♦ **T Wave 87**

♦ **QT-Interval 93**

JAYPEE BROTHERS

- **U-Wave 97**
  - Normal Variants 98
  - Electrocardiogram Rules of Normal ECG 98

5. ECG in Myocardial Infarction 103

- **Acute Coronary Syndrome 103**
- **Myocardial Infarction 103**
  - ECG Changes: Ischemia 104
  - ECG Changes: Injury 105
  - ECG Changes: Infarct 107
  - Evolving MI and Hallmarks of AMI 107
  - Reciprocal Changes 107
- **Use of ECG in a Setting of MI 107**
- **Localization of MI Based on ECG 109**
- **Blood Supply of the Heart 110**
- **Anterior Wall Myocardial Infarction 111**
  - Left Main Coronary Artery Stenosis 115
- **Wellens' Syndrome 115**
  - De Winter's T Waves 116
- **Inferior Infarction 117**
  - Complications of Inferior Infarction: The Big Three 119
- **Right Ventricular Infarction 119**
- **Posterior Myocardial Infarction 120**
- **Lateral STEMI 121**
- **Diagnosis of STEMI in a Setting of LBBB 121**
- **Non-ST Elevation Myocardial Infarction 123**
  - ECG Manifestation 123
- **Complications of Acute Coronary Syndrome 124**

6. Tachyarrhythmia 126

- Narrow QRS Complex 127
- Wide QRS Complex 127
- **Narrow Complex Tachydysrhythmias 128**
  - Sinus Rhythm 128
  - Sinus Tachycardia 128
  - Sinus Arrhythmia 129
  - Atrial Flutter 130
  - Supraventricular Tachycardia 131

JAYPEE BROTHERS

- AV Nodal Re-entrant Tachycardia 132
- Atrioventricular Reciprocating Tachycardia 134

♦ **Wolff-Parkinson-White Syndrome 135**
- Treatment of SVT 140
- Junctional Rhythm 141
- Atrial Fibrillation 141
- Atrial Flutter with Variable Block 144
- Multifocal Atrial Tachycardia 146

♦ **Wide Complex Tachycardia 148**
- Causes 148
- Ventricular Tachycardia 148
- Torsades de Pointes 158
- Ventricular Fibrillation 159

7. Bradyarrhythmias 164

♦ **Sinus Bradycardia 164**

♦ **Heart Block 164**
- AV Block 164
- Sinus Node Dysfunction/Sick Sinus Syndrome 167
- Sinoatrial Nodal Exit Block (SA Exit Block) 167

♦ **Cardiac Arrest Rhythms 169**
- Pulseless Electrical Activity 170
- Cardiopulmonary Resuscitation 170
- Asystole 171

8. Electrolytes and ECG 172

♦ **Potassium Disorders 172**
- ECG Features of Hyperkalemia 172
- ECG Features of Hypokalemia 176

♦ **Calcium Disorders 177**
- ECG Features of Hypocalcemia 177
- ECG Features of Hypercalcemia 177

♦ **Magnesium Disorders 178**
- ECG Features of Hypomagnesemia 178
- ECG Features of Hypermagnesemia 180

9. Drugs and Miscellaneous 182

♦ **Drugs and ECG 182**
- Rhythm and Rate 182

JAYPEE BROTHERS

- **Digoxin Effect 186**
  - Digoxin Toxicity 186
  - Tricyclic Antidepressant Overdose 187

Miscellaneous 188

- **Pericarditis 188**
- **Myocarditis 190**
- **Hypertrophic Obstructive Cardiomyopathy 190**
- **Pulmonary Embolism 191**
- **Brugada Pattern 192**
- **Arrhythmogenic Right Ventricular Dysplasia 193**
- **Benign Early Repolarization 193**
  - Benign Early Repolarization versus Pericarditis 194
- **Hypothermia 194**
- **Congenital Long QT Syndromes 195**
- **Pacing 196**
  - Ventricular Pacing 196
- **Atrial and Ventricular Ectopics 199**
  - Classification of PVCs 200

10. Review—Multiple Choice Questions 204

11. Practice ECGs 224

Index 257

JAYPEE BROTHERS

CHAPTER 6

Tachyarrhythmia

INTRODUCTION

Tachydysrhythmias are defined as any abnormal cardiac rhythm with a rate greater than 100 beats per minute.

A systematic approach can be useful in the rapid assessment and treatment of the patient presenting with tachydysrhythmia.

It is important to recognize the hemodynamic consequences of the rhythm. General approach to tachyarrhythmias are shown in **Flowchart 1**.

Flowchart 1: General approach to tachyarrhythmias.

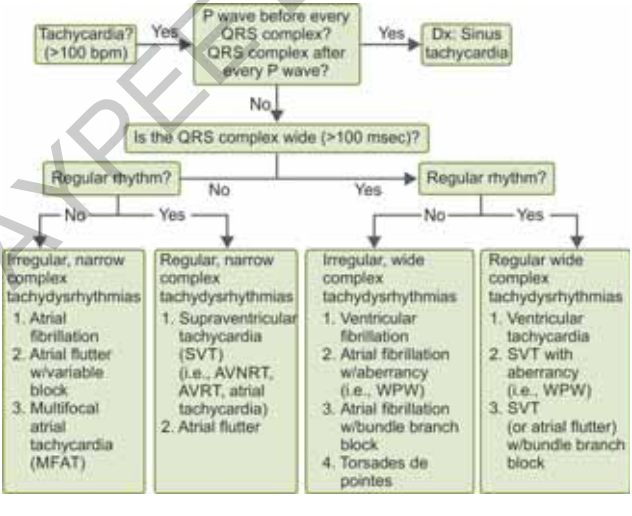

JAYPEE BROTHERS

Narrow QRS Complex

Regular

- Supraventricular tachycardia (SVT)
- Sinus tachycardia
- Atrial flutter
- Junctional rhythm

Irregular

- Atrial fibrillation
- Atrial flutter with variable block
- Multifocal atrial tachycardia

Wide QRS Complex

Regular

- Ventricular tachycardia
- SVT with aberrancy

Irregular

- Atrial fibrillation with pre-excitation
- AF with aberrancy
- Ventricular fibrillation
- Torsades de pointes

Causes of narrow and wide complex tachyarrythmias is shown in **Table 1**.

Table 1: Comparison between narrow and wide complex.

	Regular narrow	*Irregular narrow*	*Regular wide*	*Irregular wide*
100–120	Sinus tachycardia (ST)	Airtal fibrillation	Sinus tachycardia with preexisting LBBB/RBBB	AF with LBBB/RBBB
120–150	ST	A-Fib ST	Most VTs	
Around 150	Atrial flutter AT with 2:1 AV conduction	A-fib	Any SVT with rate dependent Aberrancy	
150–180	ST AVNRT Orthodromic AVRT Fascicular/septal VT	A-RB AT with intermittent AV block		Unusual form of VT (post shock/amiodarone effect)

Contd...

JAYPEE BROTHERS

Contd...

	Regular Narrow	*Irregular Narrow*	*Regular Wide*	*Irregular Wide*
180–120 (Most tachycardias)	Typical AVNRT Ortho AVRT Sinus tachycardia PJRT (always consider ST)	A-fib Atrial flutter AT/MAT With varying blocks		* VTs are largely regular. Minor irregularity can be observed during onset/offset Or if there is too much of AV dissociation
220–250	Orthodromic AVRT Atypical AVNRT PJRT Incessant JT SNRT	A-Fib A-flutter AT (with AV blocks hypoxic/toxic states)	VT Orthodromic AVRT	Antidromic AVRT Polymorphic VT
250–280	Orthodromic AVRT Postoperative Automatic JT	Antidromic-AVRT	Fast ischemic myocardial VT	Polymorphic VT Antidromic AVRT
>280	Uncommon (possible in infants/children)		Very unstable polymorphic VT/loss of baseline/V-flutter/V-fib	

NARROW COMPLEX TACHYDYSRHYTHMIAS

Sinus Rhythm

Sinus rhythm is shown in **Figure 1**.



Fig. 1: Electrocardiogram showing sinus rhythm.

Sinus Tachycardia

Sinus tachycardia (ST) is the most common narrow complex regular tachycardia. ST is characterized by sinus P waves, normal PR interval (<200 msec), 1:1 AV conduction, and an atrial rate

JAYPEE BROTHERS

usually 100–160 beats/min. It is typically an appropriate response to physiologic stimuli. Common causes include: hypovolemia, sepsis, pain, alcohol withdrawal, sympathomimetic intoxication, thyroid storm, etc. **(Figs. 2 and 3)**.

Defining criteria and ECG features:	• **Rate:** >100 beats/min • **Rhythm:** Sinus • **PR:** ≤0.20 sec • **QRS complex:** Normal



Fig. 2: Electrocardiogram showing sinus tachycardia.

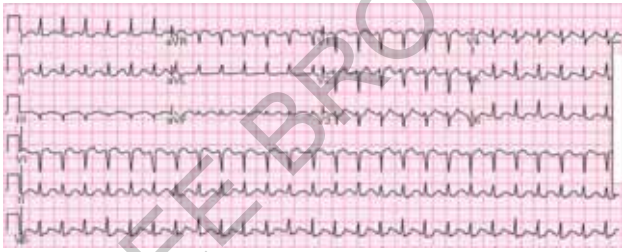

Fig. 3: Electrocardiogram showing sinus tachycardia with different features.

Sinus Arrhythmia (Fig. 4)

Impulses originate at SA node at varying rate.

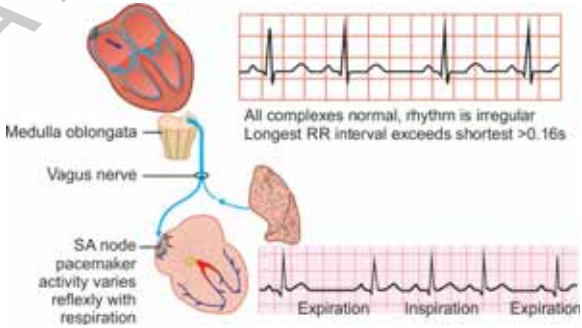

Fig. 4: Electrocardiogram showing sinus arrhythmia.

JAYPEE BROTHERS

It is a normal phenomenon that occurs with changes in intrathoracic pressure. The heart rate increase with inspiration (RR interval shorten) and decreases with expiration (RR interval lengthen), so the rhythm is irregular **(Fig. 4)**.

Loss of sinus arrhythmia is seen in seen in cardiac failure and autonomic neuropathy.

Atrial Flutter



Fig. 5: Atrial flutter.

- Narrow complex tachycardia
- Regular atrial activity at approximately 300 bpm
- Flutter waves ("saw-tooth" pattern) best seen in leads II, III, aVF—may be more easily spotted by turning the ECG upside down **(Fig. 5)**
- Flutter waves in V1 may resemble P waves
- Loss of the isoelectric baseline

Types of atrial flutter are described in **Table 2**.

Table 2: Types of atrial flutter.

Typical Atrial flutter (common, or type I atrial flutter) Involves the IVC and tricuspid isthmus in the reentry circuit	
• Anticlockwise re-entry: Most common form of atrial flutter (90% of cases). Retrograde atrial conduction produces: ➢ Inverted flutter waves in leads II, III, and aVF ➢ Positive flutter waves in V1—may resemble upright P waves	• Clockwise re-entry: This uncommon variant produces the opposite pattern: ➢ Positive flutter waves in leads II, III, and aVF ➢ Broad, inverted flutter waves in V1
Atypical atrial flutter (uncommon, or type II atrial flutter) • Does not fulfill criteria for typical atrial flutter • Often associated with higher atrial rates and rhythm instability • Less amenable to treatment with ablation	

JAYPEE BROTHERS

Supraventricular Tachycardia

- Refer to any tachydysrhythmia arising from above the level of the bundle of His.
- Paroxysmal SVT (pSVT) describes an SVT with abrupt onset and offset—characteristically seen with re-entrant tachycardias involving the AV node such as AVNRT or atrioventricular re-entry tachycardia (AVRT) **(Figs. 6 and 7).**

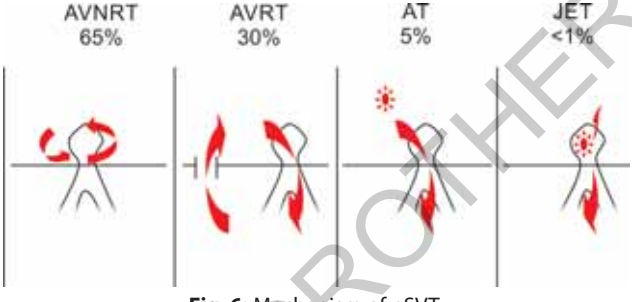

Fig. 6: Mechanism of pSVT.

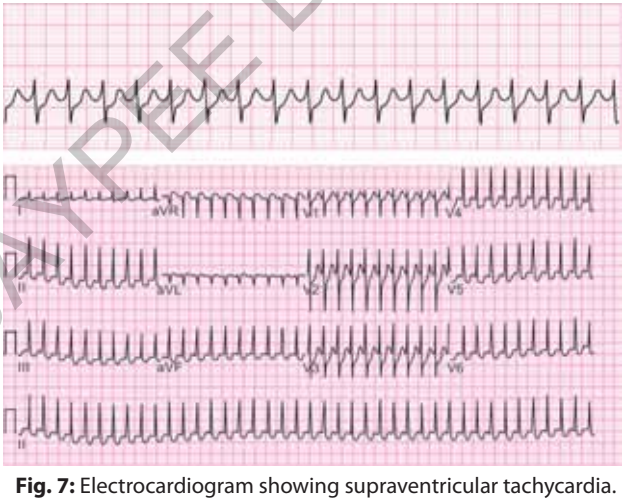

Fig. 7: Electrocardiogram showing supraventricular tachycardia.

JAYPEE BROTHERS

Classification of SVT by site of origin and regularity (Tables 3 and 4)

Table 3: Classification of SVT.

Regular atrial	*Irregular atrial*	*Regular atrioventricular*
• Sinus tachycardia • Atrial tachycardia • Atrial flutter • Inappropriate sinus tachycardia • SNRT	• Atrial fibrillation • Atrial flutter (variable block) • MAT	• AVRT • AVNRT • Automatic junctional tachycardia

Table 4: Short and long RP tachycardia.

Short RP tachycardia	*Long RP tachycardia*
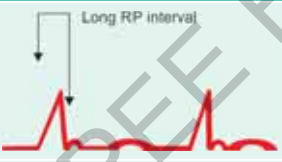	
• AV nodal re-entrant tachycardia • Orthodromic reciprocating tachycardia (ORT) • Atrial tachycardia when associated with slow AV nodal conduction (rare)	• Atrial tachycardia • Sinus node re-entry • Sinus tachycardia • Atypical AV nodal re-entrant tachycardia

JAYPEE BROTHERS

AV Nodal Re-entrant Tachycardia (AVNRT)

- Most common re-entrant SVT
- May achieve rates >200 bpm
- Look for the pseudo-R' in V1 or No P wave at all.

Slow-Fast AVNRT (Common Type)

- Accounts for 80–90% of AVNRT
- Associated with slow AV nodal pathway for anterograde conduction and fast AV nodal pathway for retrograde conduction.
- The retrograde P wave is obscured in the corresponding QRS or occurs at the end of the QRS complex as pseudo r' or S waves **(Fig. 8)**.



Fig. 8: Atrioventricular nodal re-entrant tachycardia.

Fast-Slow AVNRT (Uncommon AVNRT)

- Accounts for 10% of AVNRT
- Due to the relatively long ventriculo-atrial interval, the retrograde P wave is more likely to be visible after the corresponding QRS.
- ECG features:
  - QRS-P-T complexes.
  - Retrograde P waves are visible between the QRS and T wave **(Fig. 9)**.

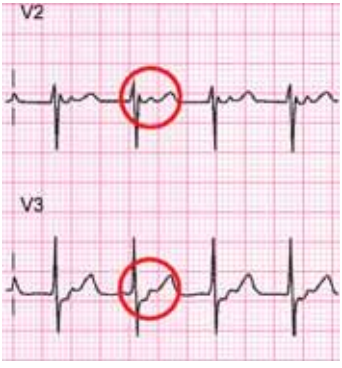

Fig. 9: Fast-slow AVNRT.

JAYPEE BROTHERS

for detailed information on medicine books, visit our website www.jaypeebrothers.com, for detailed information on medicine books, visit our website

ABC *of* ECG

Salient Features

- Comprehensive
- Easy to read
- Systematic approach to ECG interpretation
- Abundance of illustrations
- Clinical scenarios and assessment included
- Covers arrhythmology with evidence-based management

Archith Boloor MBBS MD (Internal Medicine) is an Additional Professor, Department of Medicine, Kasturba Medical College, Mangalore, Manipal Academy of Higher Education, Karnataka, India. He is a distinguished alumnus from the Manipal Academy of Higher Education. As the "Best Outgoing Student in Internal Medicine" during his MD in 2008, he has distinguished himself as an enthusiastic teacher and a skilled clinician with awards in Best Audio-visual Teaching Methods and more than 50 research publications in high impact journals such as Nature and Lancet. He has earned the 'Best Teacher Award' five times in a short teaching career. He has years of experience shining through multiple books such as *Exam Preparatory Manual of Medicine, An Insider's Guide to Clinical Medicine, Mastering Medicine—MRCP Made Easy, Comprehensive Medicine for dental students, Antibiotics Basics to Clinicians* (South Asian Edition), and *The Washington Manual of Medical Therapeutics* (South Asian Edition).

Printed in India

Available at all medical bookstores
or buy online at www.jaypeebrothers.com



JAYPEE BROTHERS
Medical Publishers (P) Ltd.
EMCA House, 23/23-B, Ansari Road,
Daryaganj, New Delhi - 110 002, INDIA
www.jaypeebrothers.com

Join us on facebook.com/JaypeeMedicalPublishers

Shelving Recommendation
MEDICINE

