nation on dermatology books, visit our website www.jaypeebrothers.com, for detailed information on dermatology books, visit our website www.jaypeebrothers.com

Illustrated Dermatology

Including Skin of Color





4th Edition

Yasaman Mansouri
Howard Maibach

JAYPEE

Contents

1. Scalp 1
- Seborrheic Dermatitis *1*
- Psoriasis *3*
- Tinea Capitis *5*
- Head Lice *8*
- Hair Loss (Alopecia) *9*

2. Face and Neck 15
- Seborrheic Dermatitis *15*
- Pityriasis Alba *17*
- Contact Dermatitis *19*
- Photodermatitis *21*
- Tinea Faciei *23*
- Acne *27*
- Rosacea *33*
- Perioral Dermatitis *37*
- Pseudofolliculitis Barbae ("Beard Bumps") *40*
- Warts *42*
- Herpes Simplex *44*
- Erysipelas *47*
- Melasma (Chloasma) *49*
- Lichen Simplex Chronicus *51*

3. Genitals, Groin, and Axillae 54
- Herpes Simplex *54*
- Anogenital Warts (Condylomata Acuminata) *57*
- Syphilis *59*
- Pubic Lice (Crabs) *63*
- Erythrasma *65*
- Tinea Cruris (Jock Itch) *68*
- Candidiasis *70*
- Diaper Dermatitis (Diaper Rash, Nappy Rash) *72*
- Lichen Simplex Chronicus *74*

4. Extremities 77
- Hand Dermatitis *77*
- Tinea Pedis *82*
- Onychomycosis *86*
- Paronychia *89*
- Periungual Warts *91*
- Plantar Warts *94*
- Stasis Dermatitis *97*
- Lichen Simplex Chronicus *99*
- Nummular Eczema *101*

5. Trunk and Generalized 103
- Atopic Dermatitis *103*
- Dry Skin (Xerosis, Asteatosis, and Winter Itch) *109*
- Contact Dermatitis *112*
- Psoriasis *117*
- Pityriasis Rosea *125*
- Lichen Planus *129*
- Urticaria (Hives) *134*
- Erythema Multiforme *137*
- Miliaria (Heat Rash) *140*
- Secondary Syphilis *143*
- Scabies *149*
- Tinea Versicolor (Pityriasis Versicolor) *154*
- Tinea Corporis *156*
- Impetigo and Bacterial Pyoderma *159*
- Herpes Zoster (Shingles) *162*
- Molluscum Contagiosum *165*
- Vitiligo *168*
- Skin Findings in HIV Infection *171*

6. Tumors, Lumps, and Marks 178
- Moles (Melanocytic Nevi) *178*
- Dermatosis Papulosa *182*
- Seborrheic Keratoses *185*
- Dermatofibroma (Histiocytoma) *188*
- Skin Tags (Acrochordons) *190*
- Pyogenic Granuloma *192*
- Cysts *194*
- Warts (Verrucae) *199*
- Actinic Damage and Sun Protection *201*
- Telangiectasia and Spider Angiomata *205*
- Solar Lentigo *206*
- Actinic Keratoses *207*
- Keratoacanthoma *210*
- Basal Cell Carcinoma and Squamous Cell Carcinoma *213*
- Melanoma *220*

7. Diagnostic Procedures 226
- The Potassium Hydroxide (KOH) Examination and Culture for Fungi *226*
- Scabies Preparation *229*
- Anesthesia *231*
- Skin Biopsy *231*

8. Formulary 233
- Principles of Topical Therapy *233*
- Acne Medications *234*
- Some Topical Antibacterials *235*
- Treatment of Fungal Infections *235*
- Topical Corticosteroid/Antifungal Combinations *237*

- Pediculocides and Scabicides *237*
- Antiviral Agents *237*
- Corticosteroids *237*
- Agents that Affect Pigmentation *241*
- Soaks, Baths, Dressings, Astringents, and Oils *241*
- Soaps and Shampoos *242*
- Antihistamines *243*
- Keratolytics, Tars, and Destructive Agents *244*

9. Patient Guides 245

- Seborrheic Dermatitis *245*
- Acne *246*
- Herpes Simplex *248*
- Pubic Lice ("Crabs") *248*
- Head Lice *249*
- Hand Dermatitis *249*
- Atopic Dermatitis ("Eczema") *250*
- Dry Skin *251*
- Pityriasis Rosea *251*
- Tinea Versicolor *252*
- Scabies *252*
- Sun Protection *253*
- Psoriasis *254*
- All about Warts *255*
- Moles and Melanoma *255*

Index 257

CHAPTER 4

Extremities

Hand Dermatitis



Typical "dishpan hands." Low-grade irritant dermatitis from water and cleansers. Skin is dry, tight, glazed, and cracked.

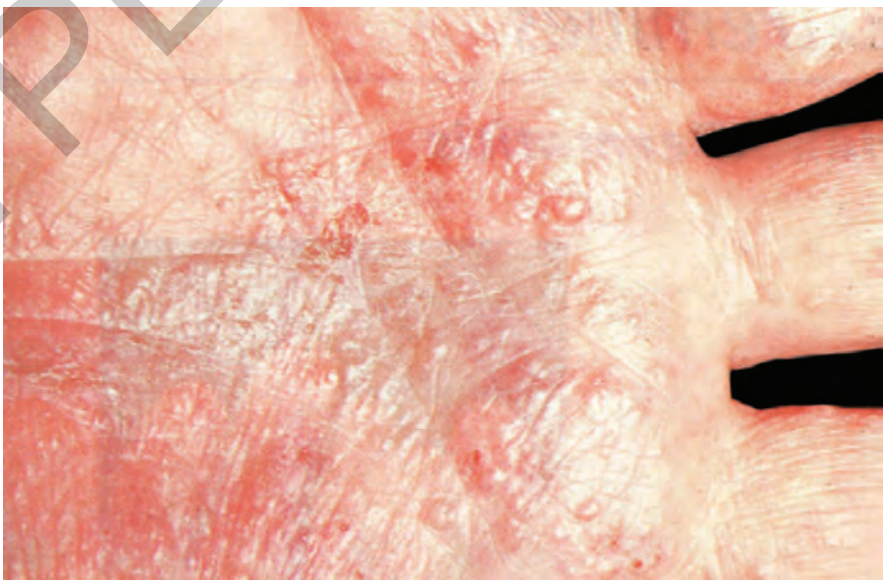

Severe dyshidrotic eczema of the fingers and palms leads to considerable fissuring and peeling.

JAYPEE BROTHERS



Mild dyshidrotic eczema (pompholyx) appears predominantly on the sides of the fingers.



A patch of vesicles suddenly erupting on the sole in an 8-year-old with pompholyx.

JAYPEE BROTHERS



Stasis dermatitis of the ankle was followed shortly by a vesicular pompholyx-like id eruption on the palms.



A fractured ankle led to a stasis dermatitis, then palmar id eruption.

JAYPEE BROTHERS



Chronic scaly psoriasis of the palms.



Acute pustular psoriasis of the palms. Typical psoriasis was present elsewhere. In contrast to dyshidrotic eczema, the patches are well-circumscribed and the vesicopustules are larger.

Because of the similarities in their appearance and management, these hand eruptions are discussed together:
- Irritant dermatitis
- Pompholyx (dyshidrotic eczema)
- Id eruptions
- Psoriasis

JAYPEE BROTHERS

CLINICAL

- Irritant dermatitis
  - Typically, dry, glazed, cracked skin is seen on the pads, palms, webs, and dorsa of fingers.
  - Condition is induced by exposure to water, detergents, and chemicals, which alter the keratin layer, causing cracking, peeling, and inflammation.
    - Seen in "wet workers": Restaurant workers, healthcare workers, bartenders, beauticians, and the like
- Pompholyx (dyshidrotic eczema)
  - Typically, tiny vesicles erupt along the sides of the fingers and on pads and, less commonly, on palms and soles (except in children), followed by a healing, peeling phase that resembles irritant contact dermatitis.
  - This condition is idiopathic and recurrent.
    - Onset in young adults most common but may continue for decades
    - Often occurs during stress
    - Often involves history of childhood atopic dermatitis and may be a form of atopic dermatitis of the adult
- Id (autosensitization) dermatitis
  - Sudden eruption of tiny vesicles on palms, indistinguishable from pompholyx
  - A sympathetic, possibly autoimmune, reaction to a sudden inflammatory eruption of the ankle or foot:
    - Stasis dermatitis, most commonly
    - Sudden inflammatory flare of tinea pedis (*See* page 82)
- Psoriasis:
  - Psoriasis may present as a chronic hand and/or foot rash, in one of two forms:
    1. Well-circumscribed area of redness, scaling, and/or deep desquamation on palm
    2. Chronic or recurrent 1- to 3-mm vesicopustules with desquamation
- Look for typical nail changes (*See* page 120) and rash elsewhere.

When examining a patient with a hand dermatitis, always take a complete history for water exposure and past or present dermatologic disease, and perform a complete examination for evidence of atopic dermatitis, psoriasis, and rashes of the ankles and feet.

TREATMENT

- General measures:
  - Stop all lotions, moisturizers, and so on, as they often contain irritants.
  - Decrease exposure to water, cleansers, and irritants.

Protective gloves induce sweating (which macerates the skin); accumulate moisture, soap, and dirt; and may themselves be allergic sensitizers (if rubber). They should be used when handling strong irritants (e.g., oven cleaner, silver polish). Vinyl gloves are the least-irritating protection if worn over a thin cotton glove that can be changed periodically as it becomes soaked with sweat, but this is so awkward and inconvenient as to be impractical for many uses.

  - Treat inflammatory disease of the ankles, feet, and legs to control the id eruption.
- Acute vesicular eruption (pompholyx, id, pustular psoriasis)
  - Tap water or mild astringent soaks (*See* page 241) three times daily for 10–15 minutes, followed by a potent topical corticosteroid, should be administered.
  - Individual tense vesicles and bullae should be punctured, if they cause significant discomfort. A hypodermic needle or pointed scalpel blade is ideal, and patients can do it, carefully, themselves. Follow with soaking and application of topical corticosteroid.
  - Antihistamine should be given as a sedative (*See* page 243), especially at bedtime or if pompholyx attack is related to stress.
- Chronic inflammation, cracking, and desquamation
  - Topical corticosteroids are the mainstay of therapy.
    - Potent forms (*See* page 237) are needed initially and often chronically. Use less potent ones when possible.
    - Ointment form is often indicated to lubricate dry, cracked skin.
    - Apply two or three times daily, but plain lubricant may also be used several times a day.
    - Vinyl gloves (*See* page 238) can be worn over corticosteroid for a few hours a day, or overnight, in stubborn cases. Monitor closely for signs of skin atrophy, then reduce potency of corticosteroid or discontinue vinyl glove occlusion.

Tip: If only the palm is involved, cut off glove fingers for comfort.

  - Moisturization:
    - Emphasize that the patient should cease using cosmetic moisturizers, as they may contain irritants or allergens.

JAYPEE BROTHERS

- If topical corticosteroids are not required (because of absence of inflammation and itching), emphasize frequent use of a thick, bland moisturizer. Lotions are too thin (mostly water) and may be drying. Use heavy creams or ointments
- Vinyl gloves worn over the emollient enhance lubrication.
  - After vinyl glove occlusion, rinse hands and immediately reapply lubricant to prevent drying.

For chronic cases, patients may need to make permanent changes in their habits and may need constantly or periodically to use lubricants or corticosteroids. Use the Patient Guides (*See* page 254) and repeatedly urge compliance.

Tinea Pedis

Tinea pedis can occur in anyone but may be more frequent or more severe in people with moist feet (excessive sweating, occlusive shoes), especially after friction and trauma (athletes). The three clinical forms are chronic plantar scaling, acute vesicular tinea pedis, and interdigital tinea pedis.



Typical "two-foot-one-hand" pattern in chronic tinea manuum. The other palm was unaffected.



Chronic tinea of palm, sometimes described as "painter's palm," with white scale building up in skin creases, like paint after cleaning painting hand.



Moderately severe chronic tinea pedis with redness and scaling in "moccasin" distribution.

JAYPEE BROTHERS



CHRONIC PLANTAR SCALING

Clinical

- "Moccasin" distribution on plantar surface and around sides of feet
  - Redness generally mild or absent
  - Scaling mild to profuse:
    - Often accentuated in normal fold lines, appearing as a white powder
    - May build up as hyperkeratosis on weight-bearing surfaces, especially around the edges of the heel
- One or more toenails often involved (*See* page 86)
- Itching usually absent
- Difficult to find organism on potassium hydroxide (KOH) examination (*See* page 226)

Treatment

In 10–20% of individuals, there is a constitutional incapability of mounting an immune response to the organism *Trichophyton rubrum,* so it exists peaceably on the foot and usually recurs (from environmental contamination or persistent skin spores) even after adequate treatment. Emphasize to the patient that no cure is expected only suppression of symptoms. Treatment is for amelioration of symptoms or to improve appearance and is not a medical necessity.

- Keratolytics (*See* page 244):
  - Chronic application minimizes or abolishes scale, thus reducing organism population.
  - These agents are a useful adjunct to topical antifungal agents.
  - Keratolytics are rarely curative.
  - Apply ointment or gel thinly once or twice daily or as necessary.
    - Salicylic acid 6% in propylene glycol gel
  - These products may be irritating, especially on nonplantar skin.
- Topical antifungal agents (*See* page 235):
  - Chronic applications minimize or suppress eruption.
  - These agents are sometimes curative.
  - Apply cream or solution twice daily; powder form is not very active.
  - There is occasional development of resistance to these agents.

JAYPEE BROTHERS



Acute vesicular tinea pedis. Close inspection of vesicles shows that they are multilocular, unlike unilocular friction blisters.

- Systemic antifungal agents are suppressive but rarely curative. Possible side effects make use rarely justified.
  - Fluconazole 150 mg daily for 2–6 weeks
  - Itraconazole 200 mg twice daily for 1 week
  - Griseofulvin microsize 1 g daily or ultramicrosize 750 mg daily for 4–8 weeks:
    - Griseofulvin may be less effective than other oral antifungals

ACUTE VESICULAR TINEA PEDIS

Clinical

- Sudden eruption of pruritic or painful blisters:
  - Often occurs abruptly in teenagers, which may induce immunity from further infections
  - Sometimes occurs on background of chronic scaling tinea

JAYPEE BROTHERS

- Small individual vesicles or, characteristically, multilocular bullae
- Often follows, by 1–2 days, sweating and friction to soles (athletes)

- Positive KOH examination result is difficult to obtain (*See* page 226) because inflammation kills organisms.
  - Roof of blister is removed, soaked in KOH several minutes, and examined.
  - Blister fluid is serum, which does not contain organisms.

Treatment

Acute tissue reaction (blisters) kills fungi, so treatment is aimed at treating the inflammatory reaction itself.

- Decrease sweating by minimizing occlusive footwear and friction
- Soaks or baths should be used two or three times a day for a few days to dry up blisters.
  - Tap water
  - Astringents (*See* page 241)
  - Dry thoroughly after soaks
- If tense blisters are painful, carefully puncture and drain blisters with a clean needle.
  - Blister top settles onto eroded base and serves as dressing. **Do not remove blister tops,** as they promote healing.
  - Continue soaks until blisters are dry to reduce chance of secondary infection.
- A potent topical corticosteroid helps to relieve itching.
- Specific antifungal therapy is usually not necessary because inflammation kills organisms. If chronic scaling remains, treat as described in the preceding section.

INTERDIGITAL TINEA PEDIS

Clinical

- Erosion, scaling, and fissuring in toe webs:
  - Fourth web is most common
- Usually itchy, burning, or painful
- More common in people with sweaty feet or occlusive footwear
- Marked malodor often noticeable
- Represents maceration with colonization by fungi and gram-negative bacteria
  - Often occurs in absence of tinea of sole



Itchy, eroded, and malodorous interdigital tinea.

- KOH examination result (*See* page 226) often negative on first attempt but usually positive after repeated attempts
- Gram-negative bacteria may cause burning and offensive odor

JAYPEE BROTHERS

Treatment

Because the primary contributing problem is superhydration and maceration, the cure can be effected by drying, without specific therapy aimed at the fungi or bacteria.

- General measures:
  - Light, loose, and nonocclusive footwear:
    - Sandals
    - Absorbent cotton socks (any color)
  - Thorough drying after bathing
  - Reduction of sweating with topical sweat inhibitors:
    - Aluminum chloride solution 20%
    - Tannic acid powder
- Drying agents:
  - Soak feet twice daily for 10 minutes, then dry well
    - Water
    - Astringent solution (*See* page 241)
  - Drying paints may be applied twice daily with cotton-tipped applicator
    - Aluminum chloride 6–20%
- Antimicrobial agents
  - Antifungal solution (*See* page 235) (drying vehicle) applied twice daily
  - Econazole cream—an antifungal agent with some antibacterial properties, which may be more effective than other topical antifungals
  - Combined antifungal and antibacterial therapy:
    - Antifungal agent and mupirocin
  - Oral antifungals—often not beneficial

Onychomycosis



Nails of patient shown on page 83 are thickened and have accumulated crumbly subungual debris.

JAYPEE BROTHERS

CLINICAL

- Infection of the nail and/or the nail bed with dermatophyte (ringworm) fungi:
  - Many species can cause infection.
  - Secondary colonization with nonpathogenic fungi is common.
  - KOH examination and fungal culture results are often negative, even with excellent technique.
  - Histology and Periodic acid–Schiff (PAS) staining are predominantly used for diagnosis
- Clinical characteristics:
  - Distal nail edge onycholysis (separation of nail plate from nail bed) with yellowish thickening of nail plate and accumulation of tan crumbly debris beneath separated portion of nail
    - Distal edge of nail may split and crumble and eventually shorten considerably through "erosion."
    - Nail may thicken, become elevated and grossly distorted, and be painful from pressure of shoes.



This diabetic patient had particularly marked nail and skin involvement with dermatophytes.



Chronic indolent onychomycosis caused only slight thickening and longitudinal striation of these fingernails.

    - Black or greenish subungual color may occur from secondary colonization by nonpathogenic fungi (e.g., *Aspergillus*).
  - Condition is often seen in association with tinea pedis or tinea manuum.
  - Toenail involvement is much more common than fingernail involvement.
    - May occur in single nail (often great toenail) or in multiple nails
    - If isolated and skin is unaffected, may be secondary to traumatic damage to nail, which is a portal for infection
  - Usually lasts a lifetime; rarely heals spontaneously:
    - More nails may become involved with passage of time, especially if skin of soles and palms is affected.

JAYPEE BROTHERS

TREATMENT

- General:
  - Continuous treatment of chronic palm or sole tinea (*See* page 82) possibly decreases the likelihood of nail infection.
  - Well-established onychomycosis, especially of the toenails, is difficult to cure, and it is best to warn the patient of the poor prognosis and the possibility of relapse.
  - After discussion, the patient might decide to forgo treatment.
    - Keep the nail neatly clipped and buffed flat (with file or pumice stone) for cosmetic appearance and to prevent painful pressure by shoes.
- Topical therapy:
  - Most topical agents are of little benefit.
    - Efinaconazole 10% solution (Jublia) once daily for 48 weeks
    - Gently spread the solution completely around the toenail (toenail bed, folds, hyponychium, and undersurface of the toenail plate) with the attached applicator brush and let dry thoroughly.
- Systemic antifungal agents (*See* page 235):
  - These agents are associated with a high likelihood of response (85%), but some nails may not respond.
  - Relapse rate for toenails is very high (80%) within a few years after therapy is stopped.
    - Relapse rate lower (50%) for fingernails
  - Course of therapy is prolonged with the use of some agents (until nails clear).
    - About 12 months for toenails
    - About 6 months for fingernails
  - Side effects are possible (*See* page 236).
  - All agents are expensive.
  - Because of long duration of therapy, possible side effects, and high relapse rate, oral agents are used with reluctance for onychomycosis of the toenails (which is essentially a cosmetic problem) but are worth a try for onychomycosis of the fingernails (where not only is cosmesis more important, but intact nails are necessary for picking up small objects).
    - Itraconazole: In the United States, the approved course is 200 mg daily for 6 weeks for fingernails, 12 weeks for toenails. More commonly suggested is 200 mg twice daily for 1 week; repeat every 4 weeks for 2 months (fingernail) or 3 months (toenail).
    - Fluconazole: The course for this drug is 150 mg weekly until clear (an unapproved use in the United States). Its success and cost are comparable to those of itraconazole.
- Nail avulsion: Removal of a single involved nail sometimes allows a normal nail to grow again in its place.
  - The relapse rate is high, especially if more than one nail is involved or if the sole is involved and not treated.
  - Treat with topical antifungal solution or oral antifungal agent during regrowth.
  - Surgical avulsion is standard but should be performed only by a trained practitioner.
    - To do this, use ring block anesthesia (without epinephrine), apply a tourniquet, use a periosteal elevator to separate the entire nail plate from the nail bed and cuticle, pull the nail out of the matrix with hemostat or pliers, then gently curette the bed to remove infected debris. Lightly cauterize bleeding points, but do not curette or cauterize matrix, as that may permanently prevent nail growth. Remove tourniquet and have the patient soak the digit two or three times daily in warm water or astringent for 2–4 days (until oozing stops).

Note: See page 89 for *Candida* paronychia, which may be confused with onychomycosis.

JAYPEE BROTHERS

r detailed information on dermatology books, visit our website www.jaypeebrothers.com, for detailed information on dermatology books, visit our website www.jaype

Illustrated Dermatology

Including Skin of Color

Salient Features

- Full-color guide to the most common dermatologic conditions
- Common skin conditions are easy to diagnose and treat
- Organized by anatomic region, the authors provide an in-depth discussion of 75 skin conditions and growths
- Each monograph contains Clinical and Treatment sections as well as full-color photographs.

Yasaman Mansouri MD MRCP (UK) Dermatology Attending, Department of Dermatology, NYC Health + Hospitals/Woodhull, Icahn School of Medicine at Mount Sinai, New York, New York, USA. She is board-certified in dermatology in both the United Kingdom and the United States and has published several peer-reviewed articles and textbook chapters.

Howard Maibach MD Professor, Department of Dermatology, University of California School of Medicine, San Francisco, California, USA. He has extensive bibliography (including journal articles and books) with a long-term interest in reducing the complexities of clinical dermatology to a wide medical audience.

Printed in India

Available at all medical bookstores or buy online at www.jaypeebrothers.com

JAYPEE BROTHERS
Medical Publishers (P) Ltd.
EMCA House, 23/23-B, Ansari Road,
Daryaganj, New Delhi - 110 002, INDIA
www.jaypeebrothers.com

Join us on facebook.com/JaypeeMedicalPublishers

Shelving Recommendation
DERMATOLOGY

ISBN 978-93-5465-757-3