ur website www.jaypeebrothers.com, for detailed information on obstetrics & gynecology books, visit our website www.jaypeebrothers.com



Inter-University School of Medical Ultrasound
Ian Donald

Donald School
Atlas of Fetal Anomalies

Editors
Asim Kurjak
Ritsuko K Pooh
Frank A Chervenak

2nd Edition

JAYPEE

Contents

1. **Ultrasound and Fetal Anomalies** 1
   Frank A Chervenak, Asim Kurjak, Jose Maria Carrera

2. **Three-dimensional Sonography in the Evaluation of Normal and Abnormal Fetal Face** 25
   Asim Kurjak, Guillermo Azumendi Pérez

3. **Fetal Echocardiography** 56
   Badreldeen Ahmed, Milan Stanojević

4. **Prenatal Diagnostics of Fetal Abnormalities by Ultrasound and Color Doppler** 67
   Zehra Nese Kavak, Ertan Ozen, Alin Basgül Yigiter

5. **The Advantages of Three-dimensional Sonography in the Diagnosis and Assessment of Fetal Abnormalities** 94
   Zehra Nese Kavak, Ertan Ozen, Alin Basgül Yigiter, Alexandra Shera Lieb

6. **Prenatal Ultrasound Diagnosis in Turner Syndrome and Triploidy** 120
   Radu Vladareanu, Alina Veduta, Simona Vladareanu

7. **Bioethical Standards of Ultrasonographic and Invasive Prenatal Diagnosis: Practical Aspects** 131
   Jose Maria Carrera, Bernat Serra Zantop

8. **3D and 4D Ultrasound for Congenital Fetal Anomalies** 136
   Sonal Panchal

9. **Fetal Face Malformations in Ultrasound** 163
   Marek Pietryga, Kinga Toboła-Wróbel, Rafał Iciek, Jacek Brązert

10. **Three-dimensional Reconstruction of Normal Fetal Heart and Congenital Heart Disease** 181
    Toshiyuki Hata, Aya Koyanagi, Riko Takayoshi, Takahito Miyake, Kenji Kanenishi

11. **Microvasculature of Normal and Abnormal Placentas** 191
    Toshiyuki Hata, Aya Koyanagi, Riko Takayoshi, Takahito Miyake, Kenji Kanenishi

12. **Skeletal Dysplasias** 206
    Pamela Grant, Kenneth Ward

13. **Placenta** 211
    M Lisa Bartholomew, Ivica Zalud

14. **Congenital Cardiac Tumors** 227
    Aleksandar Ljubić, Ida Jovanović, Dušan Damnjanović, Milica Đurđić, Andjela Perović, Milena Srbinović, Dušica Petrović, Tatjana Božanović

15. Congenital Lung Anomalies 235
Aleksandar Ljubić, Ida Jovanović, Dušan Damnjanović, Milica Đurđić, Andjela Perović, Milena Srbinović, Dušica Petrović, Tatjana Božanović

16. Prenatal Diagnosis of Conjoined Fetuses 248
Apostolos Athanasiadis, Panayiota Papasozomenou, Themistoklis Mikos, Menelaos Zafrakas

17. Fetal Brain Structure and Central Nervous System Anomalies 258
Ritsuko K Pooh

18. Embryonal/Fetal Anomalies in the First Half of Pregnancy 280
Ritsuko K Pooh

19. Gastrointestinal Tract and Internal Abdominal Wall 298
Fernando Bonilla-Musoles, Luiz Eduardo Machado

Index 323

CHAPTER

4

Prenatal Diagnostics of Fetal Abnormalities by Ultrasound and Color Doppler

Zehra Nese Kavak, Ertan Ozen, Alin Basgül Yigiter

JAYPEE BROTHERS

INTRODUCTION

During the last 25 years, the development of increasingly sophisticated equipment [digital techniques, gray scales, color Doppler, and three-dimensional (3D) and four-dimensional (4D) sonography] enabled the diagnosis of a growing number of malformations so that it is now possible to diagnose about 80% of congenital abnormalities with reliable structural images.[1–4]

There is no doubt that ultrasound provides many clinical advantages. The Cochrane database confirms that ultrasound enables the earlier detection of fetal malformations.[2,5]

Professionals expect from routine ultrasound objective information that cannot usually be obtained by clinical procedures.[6] Parents seek reassurance about the absence of fetal congenital anomalies and overall fetal health. Therefore, people view routine ultrasound as a part of obstetrical care, capable of filling important gaps by delivering much key information for improving obstetrical practice.[7] Fetal anomalies screening (FAS) requires higher education and qualifications than obstetrical ultrasound.[8] In most European countries, approximately 98% of pregnant women are examined by ultrasound, frequently 2–3 times (usually once per trimester). Detection rate of congenital anomalies is about 28% in private practice and hospitals, 60–80% in obstetrics and gynecology ultrasound laboratories.[9-11]

While congenital defects constitute 3% of all births, monogenic disorders and chromosomal syndromes constitute 1.4 and 0.6% of all births, respectively.[12]

Progressive improvements in ultrasound equipment within the field of prenatal diagnosis of structural fetal anomalies have permitted to obtain a sensitivity range of 90–95% and specificity range of 95–100%, with utilization of high definition equipment and an expert ultrasonographist in fetal dysmorphology.[13–15]

EVALUATION OF ABNORMALITIES OF FETAL CENTRAL NERVOUS SYSTEM

Advanced sonography combined with methodology of approaching the fetal brain has improved the assessment of fetal intracranial structure and diagnosis of the prenatal brain abnormalities.[16,17]

Prenatal assessment of the fetal central nervous system (CNS) is very important as anomalies in this region often determine survival, physical appearance, and function in society.[2,17]

Many malformations of the CNS and fetal neural axis can be detected easily and reliably.[18–22] Such as agenesis of corpus callosum, anencephaly, arachnoid cyst, cranial tumors, craniosynostosis, Dandy–Walker malformations, ventriculomegaly, hydrocephalus, diastematomyelia, encephalocele, holoprosencephaly, hydranencephaly, iniencephaly, intracranial hemorrhage, microcephaly, vein of Galen malformation, spina bifida, meningomyelocele, Arnold–Chiari malformation, and teratomas.

Recent remarkable development of 3D and 4D ultrasound will produce more accurate evaluation of the brain morphology.[3,16]

EVALUATION OF FACE AND NECK ABNORMALITIES

It is now possible to make prenatal identification of fetal face and neck malformation with great precision by means of different ultrasonographic proceedings; 2D, 3D, or 4D.[2,3,16,22] Some examples are: cleft lip and palate, ocular abnormalities, nose malformations, ear malformations, micrognathia, facial asymmetry, retrognathia, nuchal translucency and nuchal fold, and various types of cystic lesions and tumors in the neck. The most frequents are: cystic hygroma septated and nonseptated, teratomas, hemangiomas, fetal goiter, and thyroid enlargement.

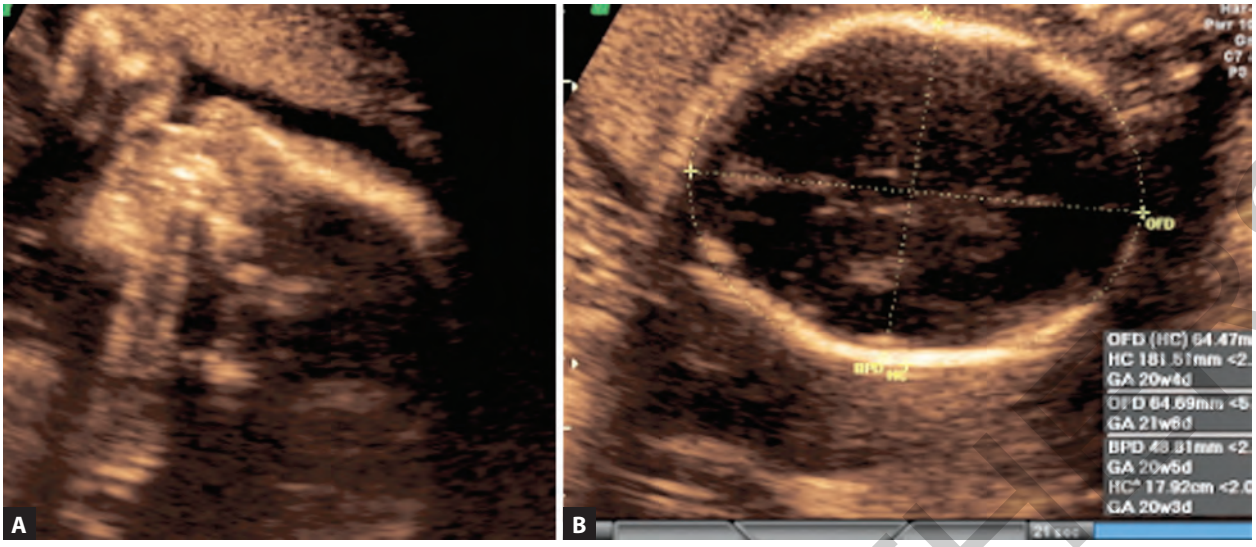

Figs. 1A and B: Microcephaly at 24th gestational weeks. Abnormal fetal profile with small forehead (A) and transverse section of the head (B). Biparietal diameter and head circumference are well below the third percentile. The abdominal circumference was compatible with 24 weeks whereas BPD and HC are measured as 20 weeks. (The abdominal circumference measurement normally about the same size as the head circumference at term is much larger). The head circumference needs to be at least below the fifth percentile before microcephaly is considered, unless there is no ventriculomegaly.



Figs. 2A to C: Communicant hydrocephalus in 28 weeks (A), 30 weeks (B), and 32 weeks fetuses (C).

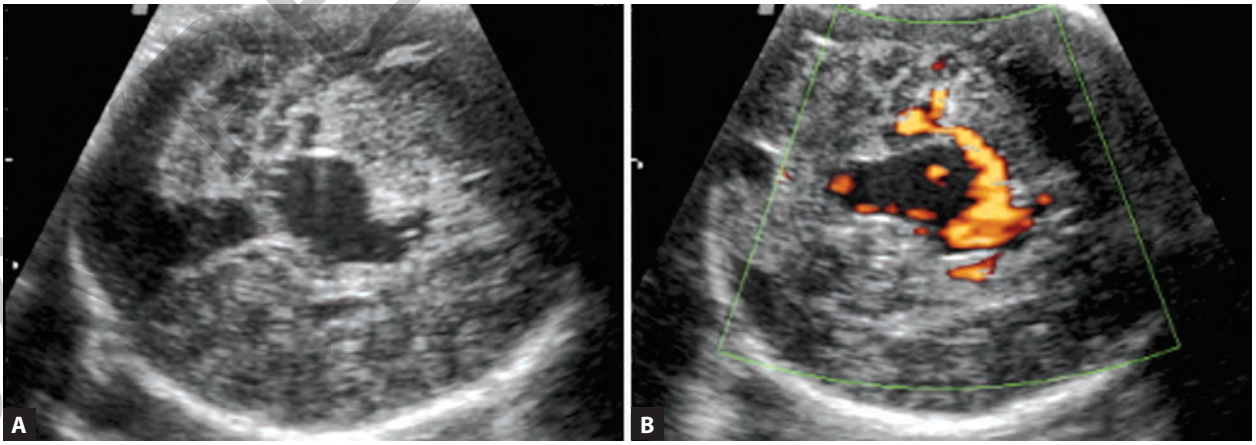

Figs. 3A and B: Vein of Galen aneurysm in a 39 weeks' fetus. Axial view at the level of the third ventricle. The large black area is the vein of Galen aneurysm. The small cystic areas adjacent to the big cystic area represent the feeding arteries [two-dimensional ultrasound (2D-US) in A, power Doppler evaluation in B].

JAYPEE BROTHERS

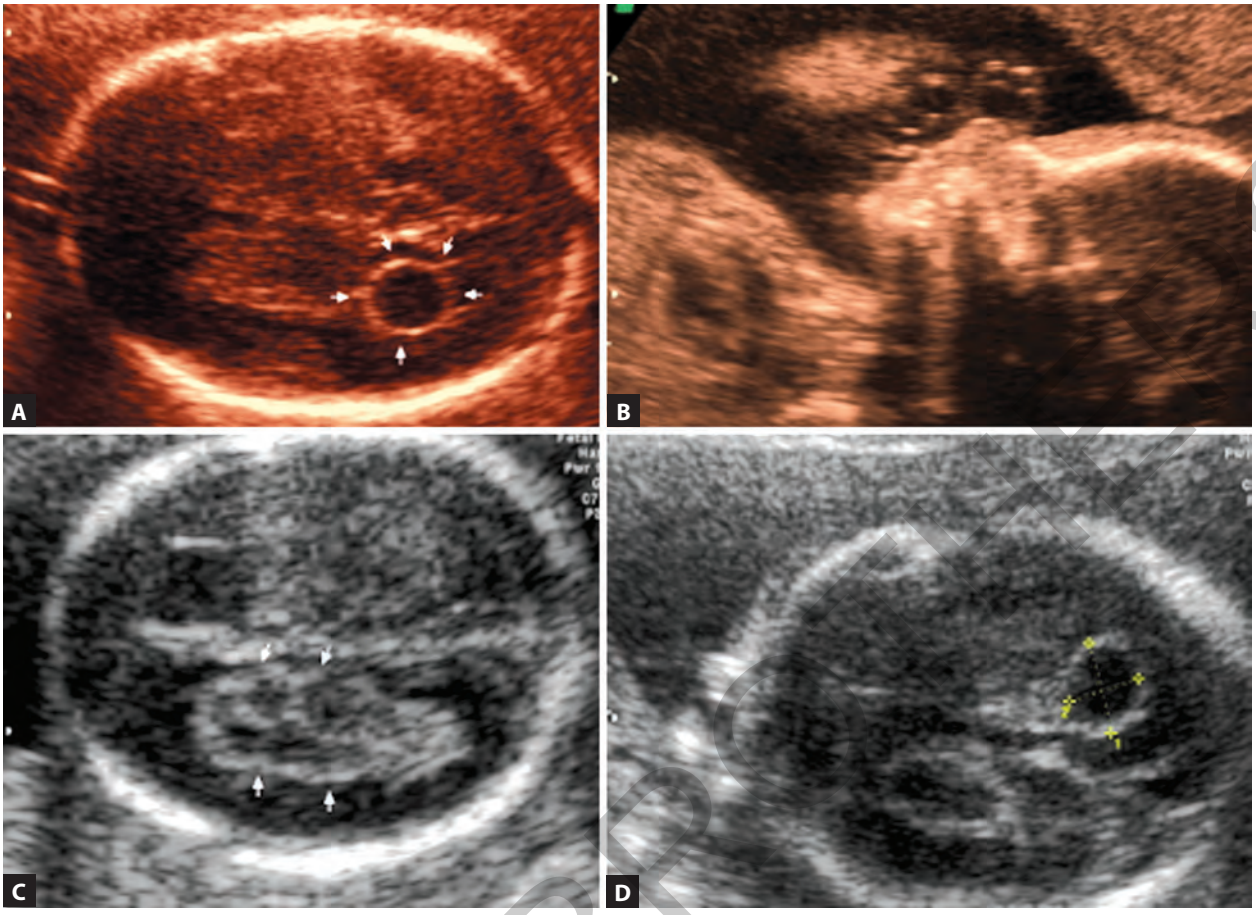

Figs. 4A to D: Choroid plexus cyst. Isolated choroid plexus cyst was found in a fetus at 22 weeks' fetus (A) and normal fetal profile of the fetus (B). Spongy choroid plexuses in a fetus at 16th gestational weeks (C) and choroid plexus cyst in a fetus at 20 weeks of gestation (D).

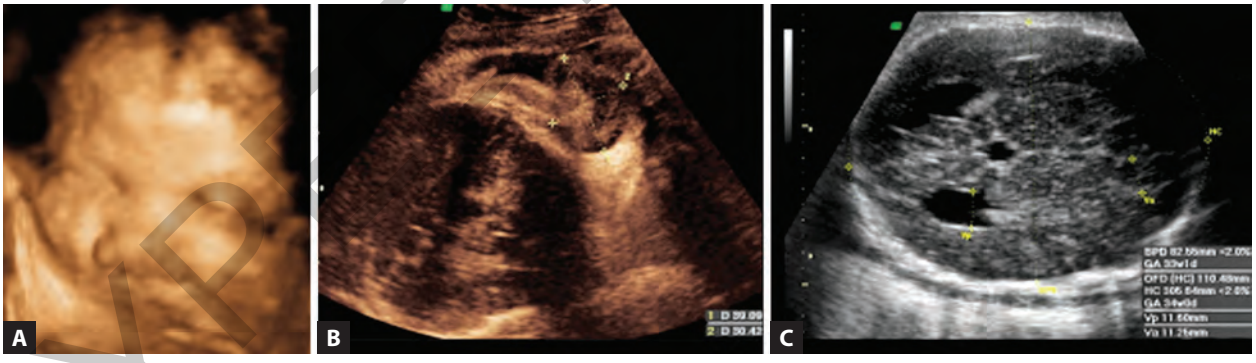

Figs. 5A to C: Cervical myelomeningocele in a 39 weeks' fetus. Three-dimensional (3D) view of fetal face (A), longitudinal view of large myelomeningocele (B), and transverse section of the skull showing mild ventriculomegaly. The head circumference was smaller than his gestational age (C).

FETAL THORACIC ABNORMALITIES

The most frequent thoracic anomalies (excluding cardiac malformations) are: the congenital diaphragmatic hernia, congenital cystic adenoid malformation, pleural effusions and sequestration of the lungs, esophageal atresia, tracheal atresia, and tracheoesophageal fistula.[2,23,24]

THE GASTROINTESTINAL SYSTEM MALFORMATIONS

The most frequent anomalies that can be detected by ultrasound are: duodenal atresia gastrointestinal atresia or stenosis, gastroschisis, omphalocele, hepatatic tumors, meconium cyst, and meconium ileus.[2,25]

JAYPEE BROTHERS



Figs. 6A to C: Alobar holoprosencephaly in a 33-week fetus. The most severe form of holoprosencephaly. Transverse section of the head (A), sagittal section of the fetal profile and the head (B), and three-dimensional (3D) view of the fetal face (C).

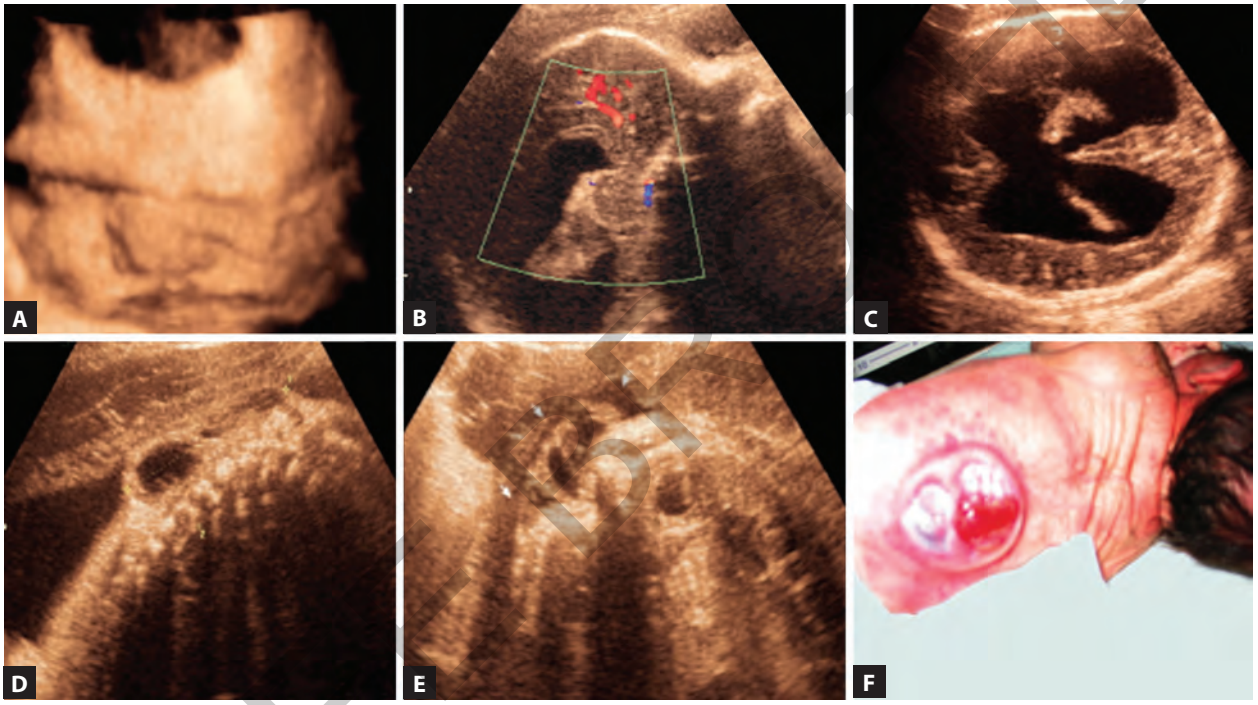

Figs. 7A to F: Labor holoprosencephaly associated with lumbar meningomyelocele in a fetus at 39 weeks. Three-dimensional ultrasound (3D-US) of the fetal face (A), the baby is grimacing. Sagittal view shows the corpus callosum as a hypoechoic semicircular image. Color Doppler shows the pericallosal artery (B), transverse section of the head showing lobar holoprosencephaly with interrupted septum (C), and longitudinal (D) and transverse (E) section of the lumbar myelomeningocele. The newborn (F).

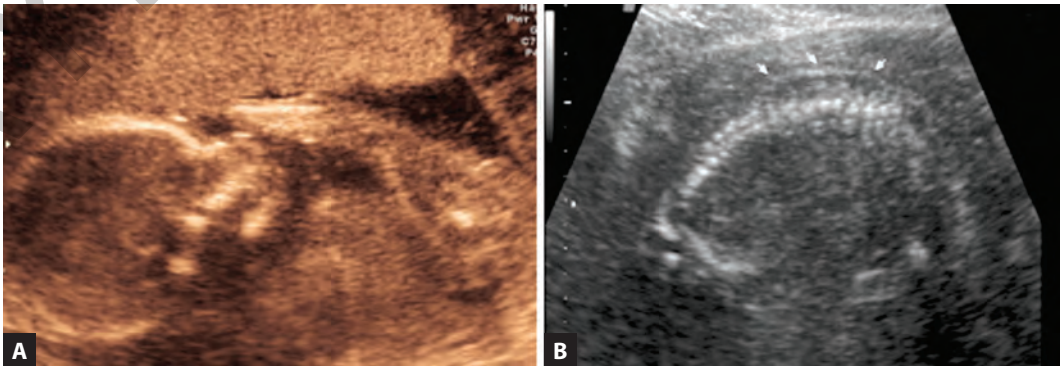

Figs. 8A and B: Arnold–Chiari malformation in a fetus with thoracolumbar meningomyelocele at 19 weeks of gestation. The fetal profile (A), myelomeningocele; the septated cystic mass can be seen in the thoracolumbar area (B).

JAYPEE BROTHERS

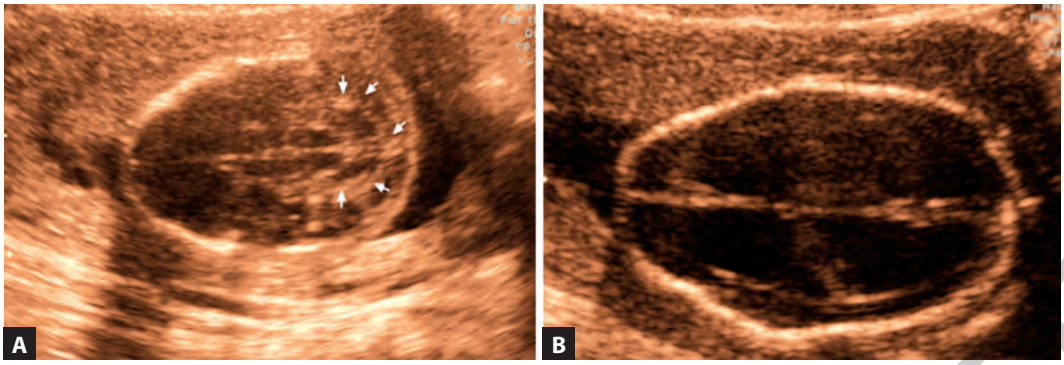

Figs. 9A and B: Arnold–Chiari malformation in a fetus with thoracolumbar meningomyelocele at 19 weeks of gestation. The cerebellum forms a "banana" shape and there is no visible cisterna manga (A). The anterior aspect of the skull is flattened, so the skull assumes a lemon shape (B).

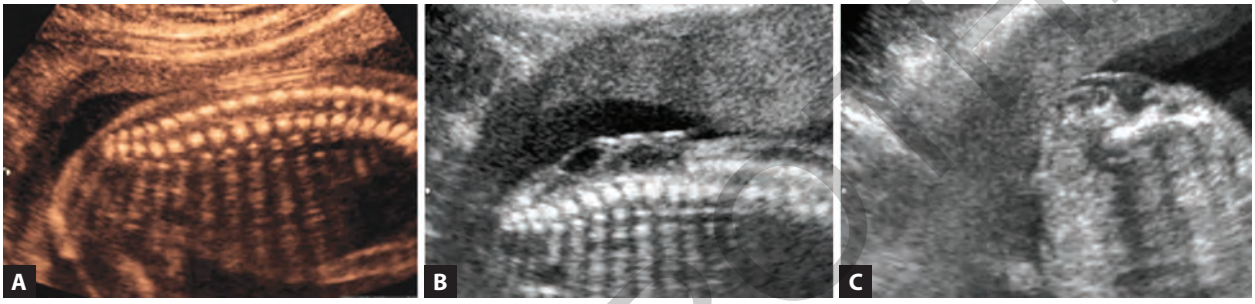

Figs. 10A to C: Lumbosacral spina bifida at 22 weeks. Longitudinal section of a normal spine at 22 weeks (A). Longitudinal (B) and sagittal (C) planes are demonstrating a full-thickness defect of soft tissue overlying the spine in a 22-week fetus with spina bifida.

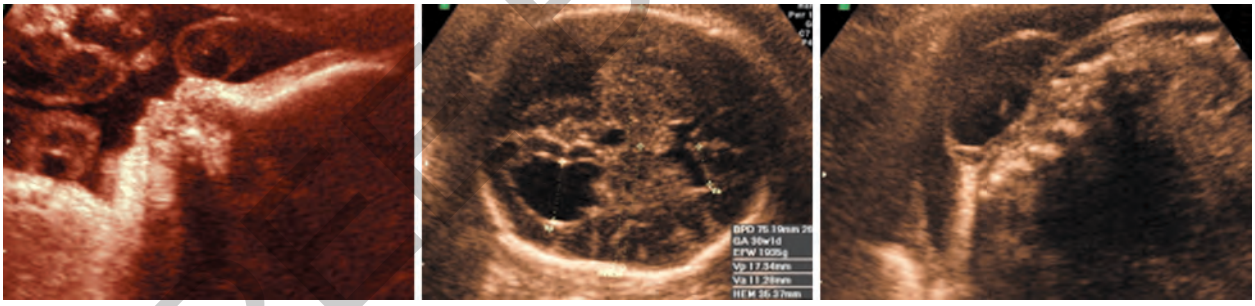

Fig. 11: Moderate ventriculomegaly with lumbosacral meningocele at 30 weeks.

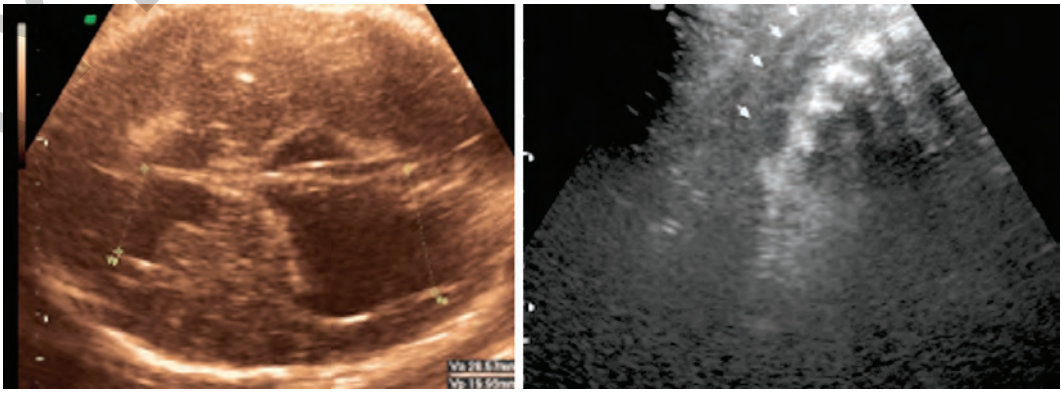

Fig. 12: Moderate to severe ventriculomegaly with lumbar meningocele at 40 weeks.

JAYPEE BROTHERS

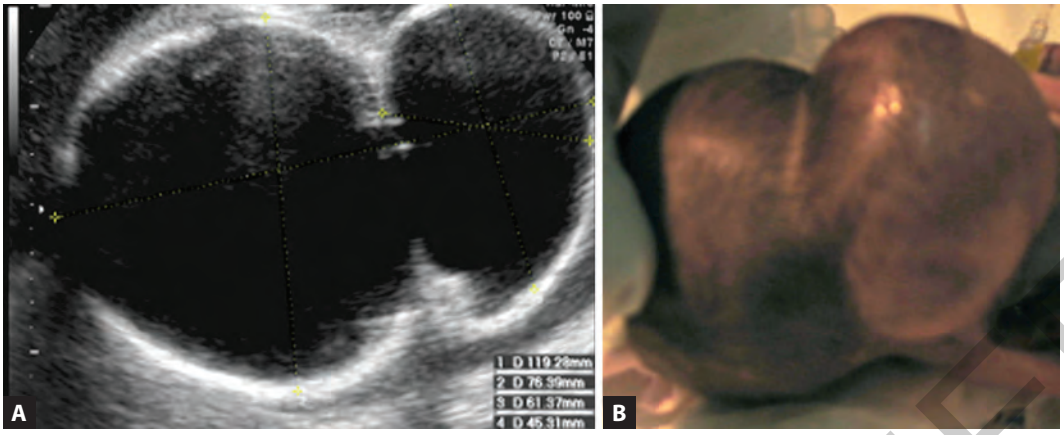

Figs. 13A and B: Large occipital communicating encephalocele in a fetus with a lobar holoprosencephaly at 36 weeks. The transverse view shows the defect of posterior calvaria with protrusion of the brain (A). The baby after birth (B).

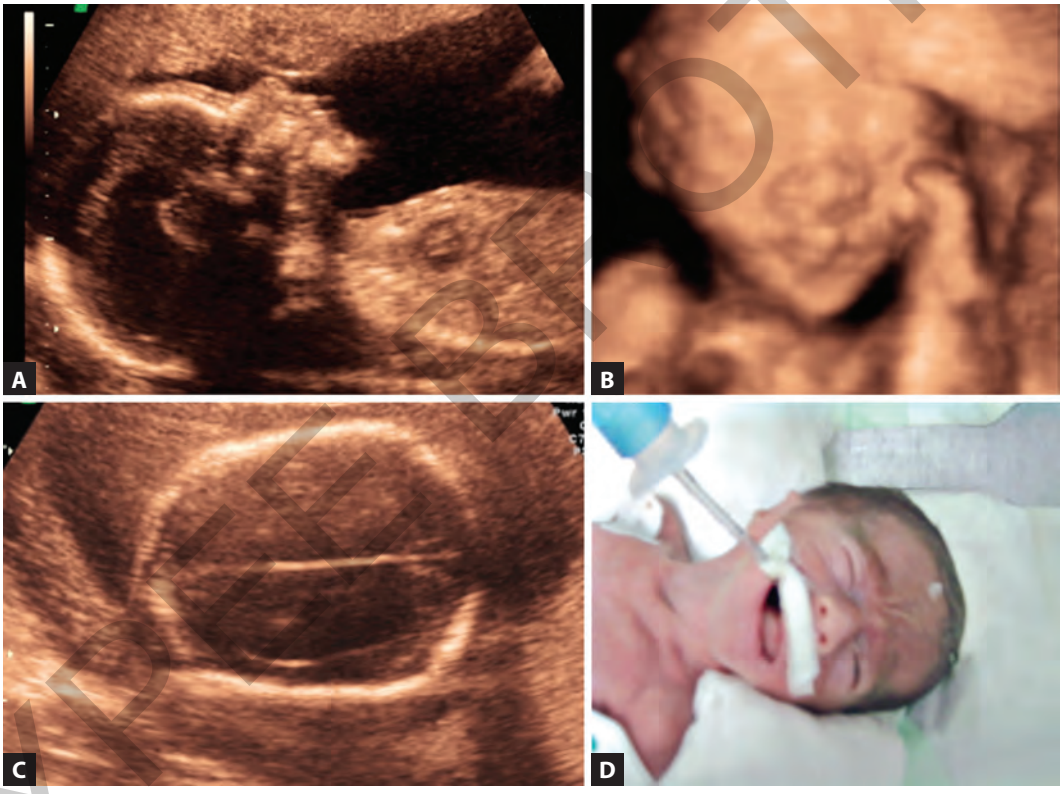

Figs. 14A to D: Severe ventriculomegaly in a fetus with intrauterine growth restriction (IUGR) at 23 weeks. The fetal profile by two-dimensional ultrasound (2D-US) (A), and three-dimensional (3D) view of the fetal face (B). Transverse section of the head (C) showing severe bilateral ventriculomegaly). The baby in the neonatal intensive care unit (D), he died 1 week after birth.

GENITOURINARY SYSTEM MALFORMATIONS

Evaluation of the fetal bladder and kidneys is routine practice in obstetric sonography.[26]

Fetal genitalia are also evaluated routinely as the parents frequently ask the fetal gender. Urinary malformations are relatively uncommon.[2,27] The incidence of urinary malformations is found to be 0.65% in a prospective antenatal ultrasound study.[2,28]

The fetal kidney can be visualized ultrasonically as early as 9.5 weeks in optimal circumstances. Kidneys are readily seen at 12th gestational week by abdominal sonography and a week early by transvaginal sonography.[26]

The urinary tract abnormalities are easily recognized as they are invariably accompanied by fluid-filled masses in fetal abdomen. Urinary malformations are suspected if there are following features: decreased amniotic fluid,

JAYPEE BROTHERS



Fig. 15: Some examples of fetal face by three-dimensional ultrasound (3D-US). Especially after 3D and 4D ultrasound imaging has been settled, the images of fetal face are very realistic and impressive.

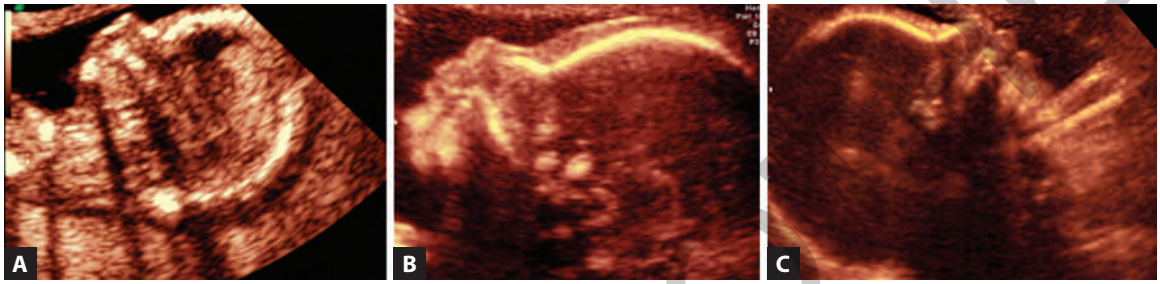

Figs. 16A to C: Normal fetal profile two-dimensional ultrasound (2D-US) at first trimester (A), at second trimester (B), and at third trimester (C).

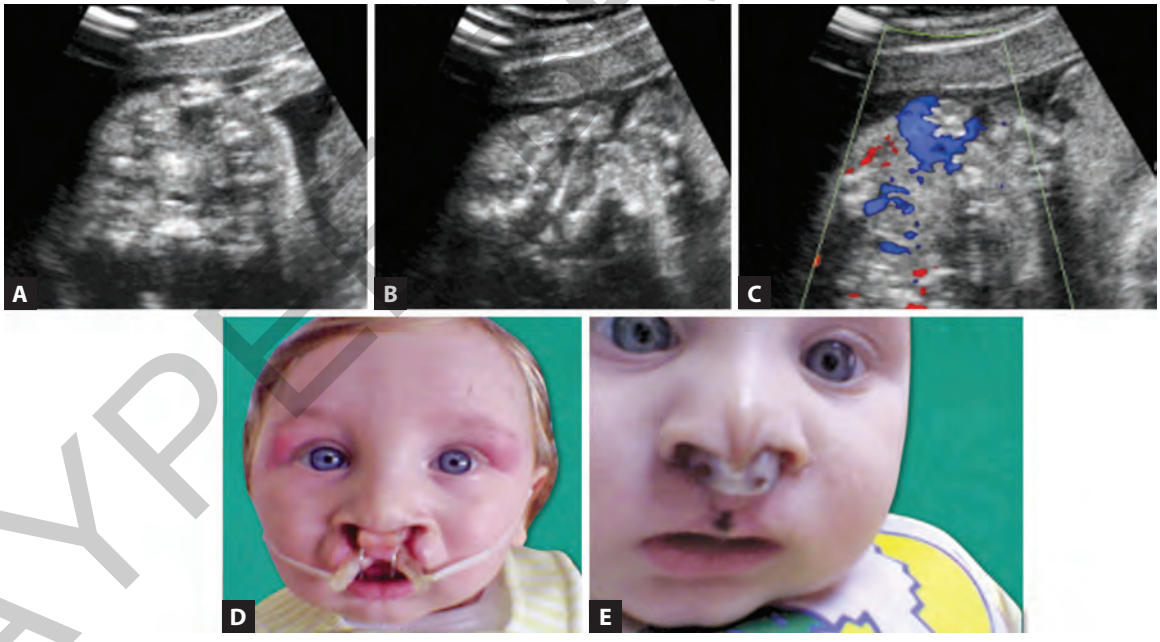

Figs. 17A to E: Cleft lip and palate in a fetus at 27 weeks of gestation. Transverse section of the palate is clearly seen to have a defect in the middle bilaterally (A and B). Color shows in the transverse section of the palate, the amniotic fluid is entering inside the mouth through a full-thickness bilateral defect in the lips and palate (C). The baby is seen at 6 months of age. The palate is repaired and artificial palate replaced (D). The final appearance at 8 months of age with the cleft lip and palate having been repaired (E).

dilatation of the urinary tract (renal pelvicalyceal dilatation, ureteral, or urethral dilatation), presence of a renal cyst, and change in the size, shape, and echogenicity of the kidney, absence or failure to visualize the fetal bladder and any other fetal malformation detected.

The most frequent genitourinary malformations that can be recognized by ultrasound are: renal agenesis, renal dysgenesis infantile polycystic kidney disease; Potter type I, multicystic dysplastic kidney disease (MDKD)—Potter type II, adult polycystic kidney disease (APKD)—Potter type III,

JAYPEE BROTHERS

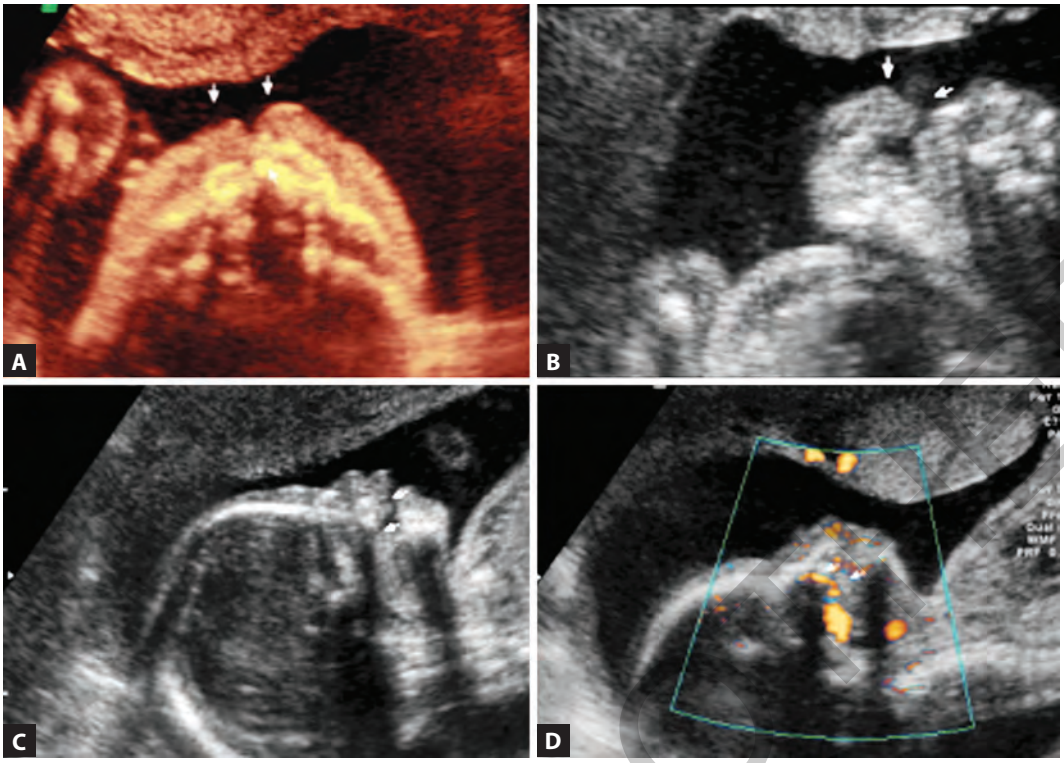

Figs. 18A to D: Unilateral cleft lip and palate at 22 weeks of gestation. Transverse section (A) is showing full thickness, unilateral cleft lip, and palate. Coronal plane (B) showing unilateral cleft lip. The cleft is clear in sagittal section of the fetal profile as well (C). Power Doppler imaging shows with fetal inspiration the amniotic fluid goes up inside the mouth of the fetus through the defect in the palate (D).

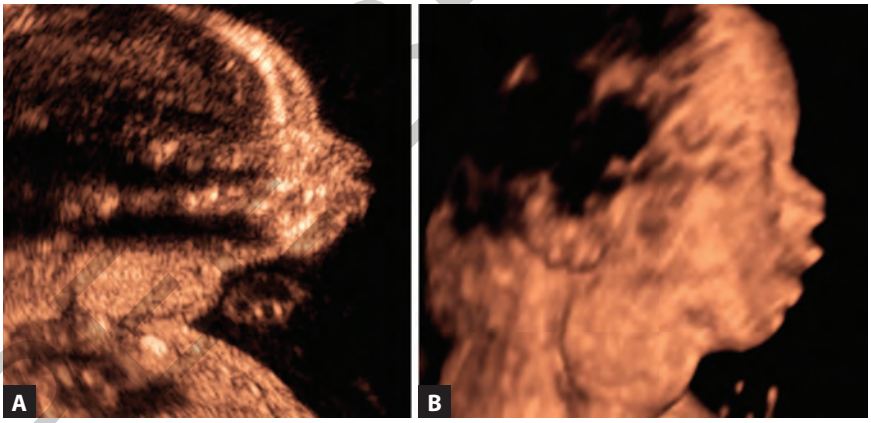

Figs. 19A and B: Fetal goiter at 24 weeks by two-dimensional (2D) (A) and three-dimensional (3D) (B) ultrasound imaging.

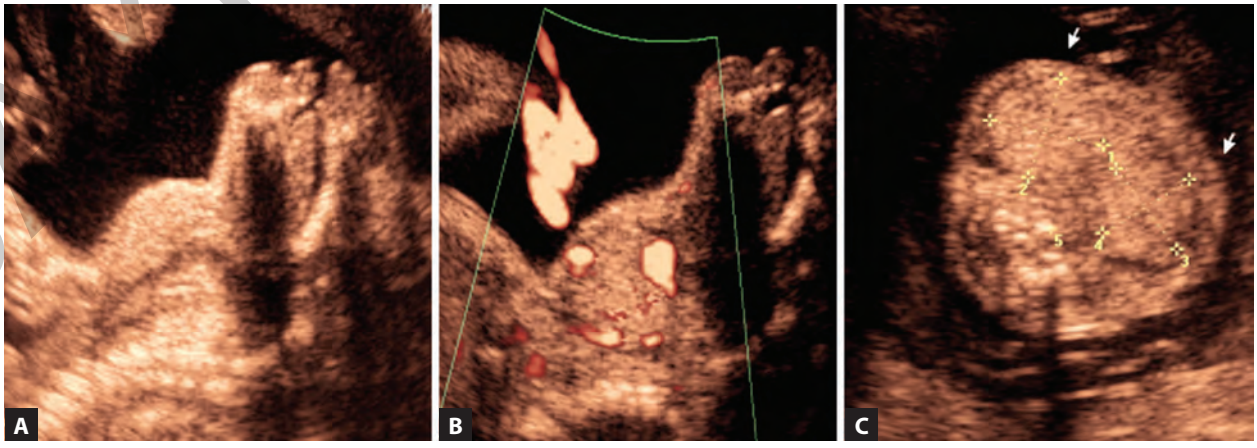

Figs. 20A to C: Fetal goiter at 25 weeks. The fetus is in extension on the sagittal plane, the mass in the neck is clearer (A). Power Doppler sonography shows the presence of blood vessels (B). Transverse section of the fetal neck confirms the bilobed enlarged fetal goiter (C).

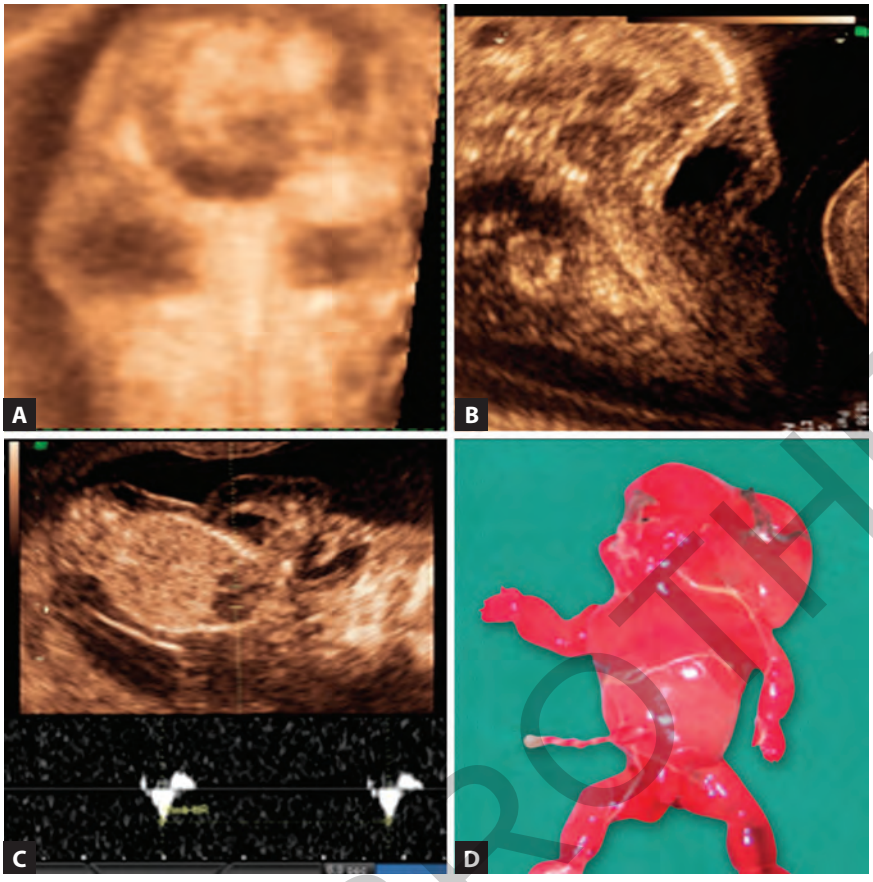

Figs. 21A to D: Bilateral cystic hygromata with diffuse edema in a fetus at 13 weeks of gestation by three-dimensional (3D) scan (A) and two-dimensional (2D) scan (B). The bilateral cystic masses by the neck are the cystic hygroma (A and B) and karyotyping revealed this baby as Turner syndrome. There is skin thickening around the body (C). The fetus had severe bradycardia during the scan (C) and died shortly afterward. The fetus after abortion, note the diffuse edema (D).

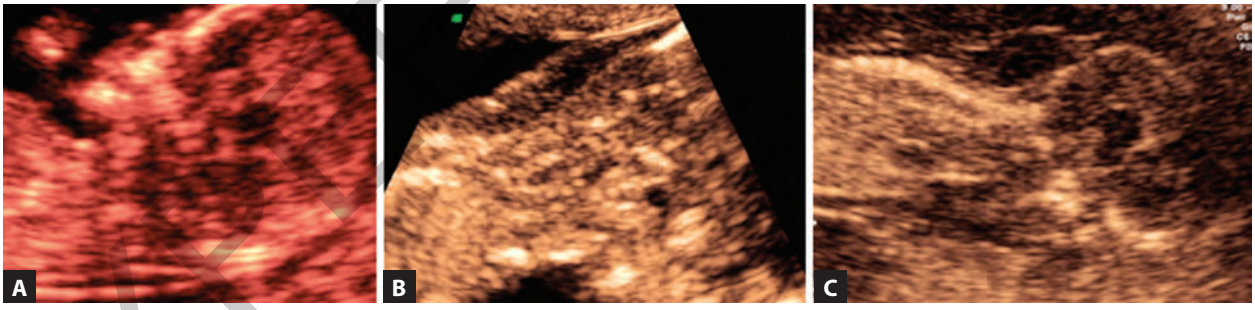

Figs. 22A to C: Increased nuchal translucency in the first trimester. Normal nuchal translucency at 12 weeks (A), moderately increased nuchal translucency (B) and severely increased nuchal translucency at 12 weeks of gestation (C).

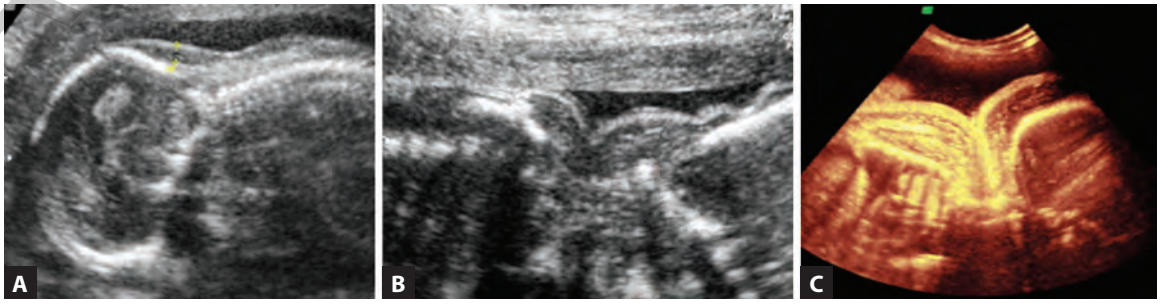

Figs. 23A to C: Increased nuchal fold. Normal nuchal fold at 23rd weeks (A). Increased nuchal fold in a baby with Down's syndrome at 26 weeks (B) and severely increased nuchal edema and hydrops in the last trimester (C).

JAYPEE BROTHERS

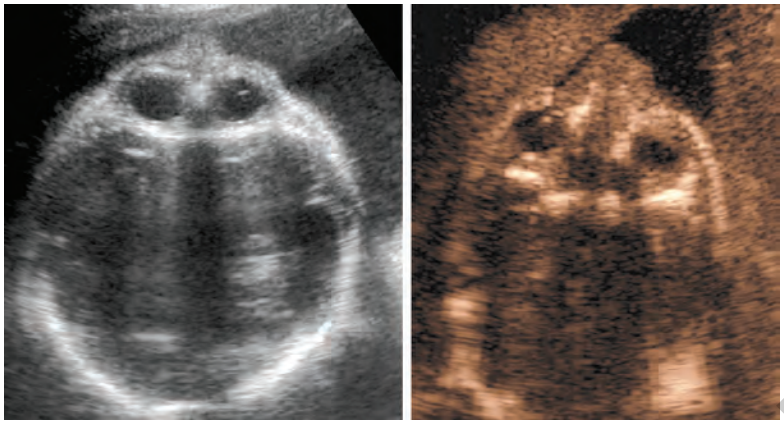

Fig. 24: Hypotelorism.

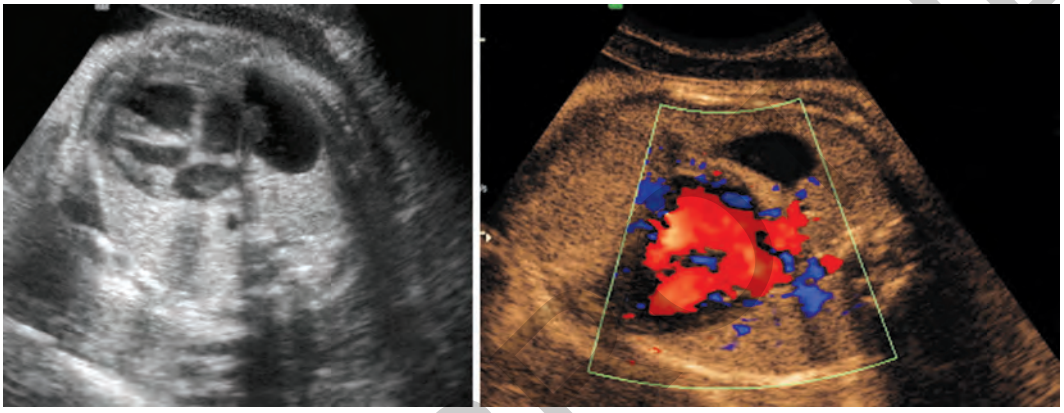

Fig. 25: Congenital cystic adenoid malformation. Transverse view: This is a case of unilateral cystic adenoid malformation of the lungs, macrocyst type.

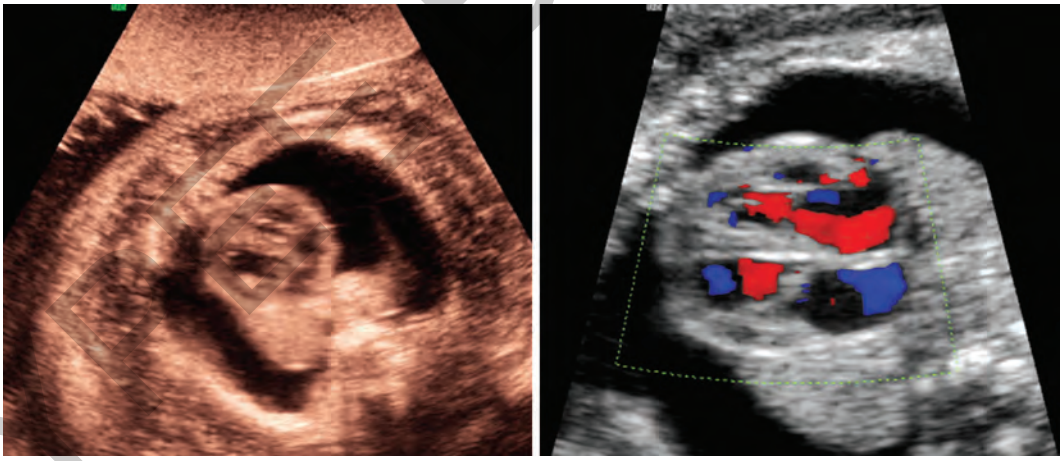

Fig. 26: Pleural effusion. Transverse images of the fetal thorax. Bilateral effusion and hydrops.

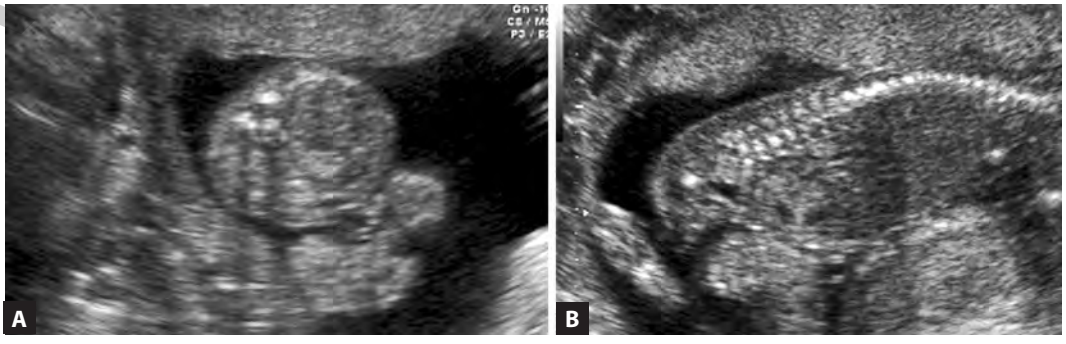

Figs. 27A and B: Gastroschisis at 19th gestational weeks. Transverse (A) and longitudinal (B) scan shows the loops of bowel protruding through a defect in the abdominal wall, not covered by a membrane.

JAYPEE BROTHERS

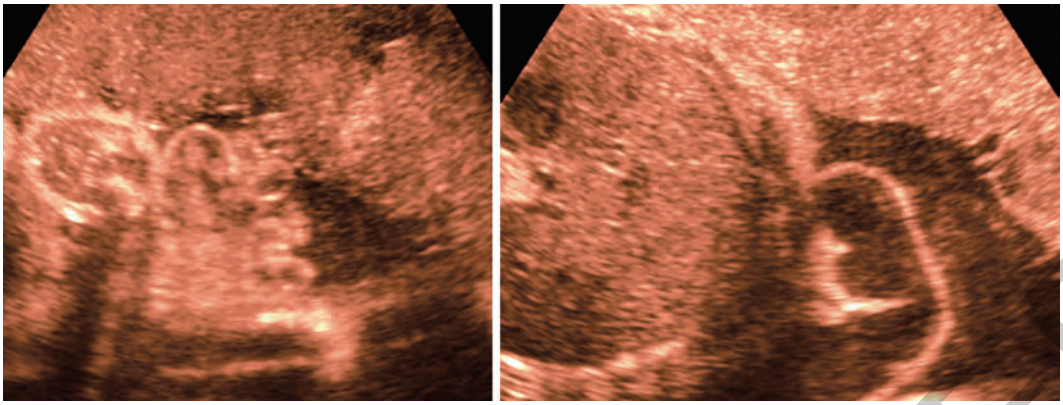

Fig. 28: Gastroschisis at 32nd gestational weeks. Freely floating fluid-filled bowel loops can be seen in the third trimester in a fetus with gastroschisis. Gastroschisis loops can be mistaken for cord loops.[2]

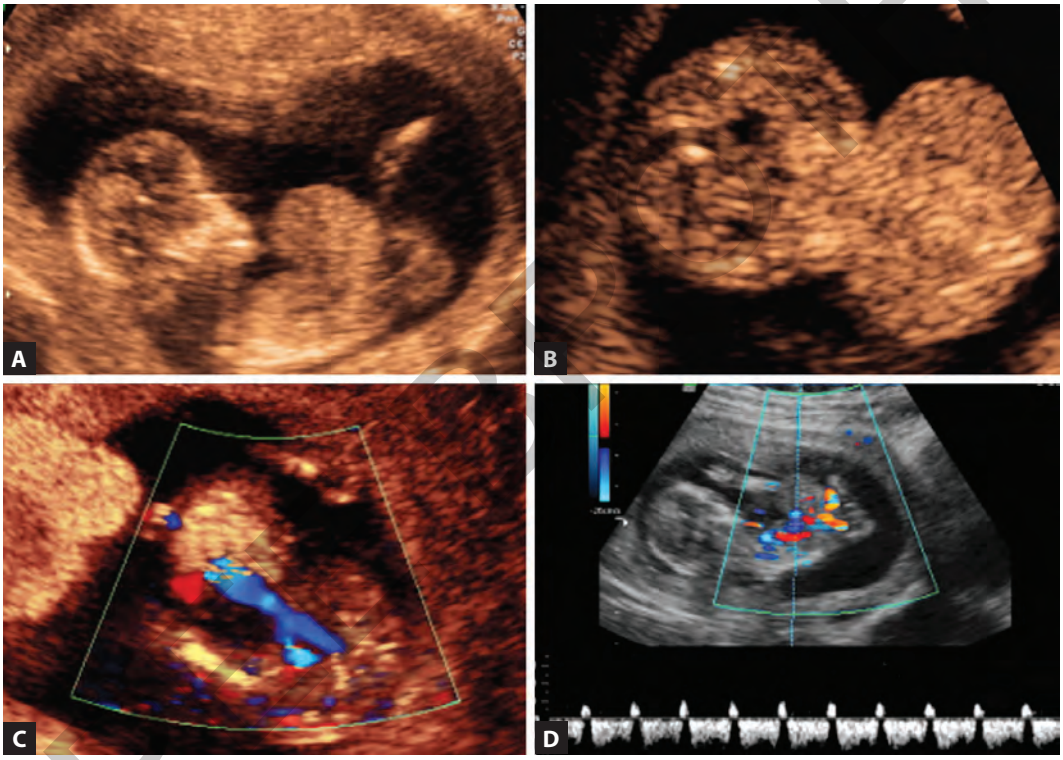

Figs. 29A to D: Omphalocele at 12th gestational weeks. Longitudinal section (A) through the fetal body shows a solid mass protruding from the fetal abdomen. Transverse section (B) shows the omphalocele containing liver with bilateral mild hydronephrosis in the same fetus. Color Doppler examination shows the blood supply (C). Reversed flow in the ductus venosus (D), because of the possible kinking of the ductus as most of the fetal liver is almost outside the abdomen.

cystic renal dysplasia (CRD)—Potter type IV, abnormally distended fetal bladder (megacystis) due to posterior urethral valve, urethral agenesis or stricture, persistence of cloaca and megacystis-microcolon-hypoperistalsis syndrome, bladder extrophy, ureteropelvic junction obstruction, pyelectasis, megaureter, vesicoureteral reflux, horseshoe kidney and empty renal fossa, renal duplication anomalies, tumors of the kidney, adrenal gland tumor, congenital adrenal neuroblastoma, and sacrococcygeal teratoma.[1,2,13,27,28]

Genital anomalies that are recognizable by ultrasound are: fetal ovarian cysts, hydrocolpos and hydrometrocolpos in the case of female fetus, fetal hydrocele, ambiguous genitalia, and hypospadias in the case of male genitals.[27,28]

SKELETAL ABNORMALITIES

The fetal skeleton can be visualized by ultrasound very early however, only a small proportion of skeletal malformations can be identified in the early second trimester.[2]

During the scan, it is very important to focus; biometry of the long bone, grade of bone density, fractures or bowing of the bones, fetal spine, appearance and number of digits, and fetal movements.[29]

JAYPEE BROTHERS

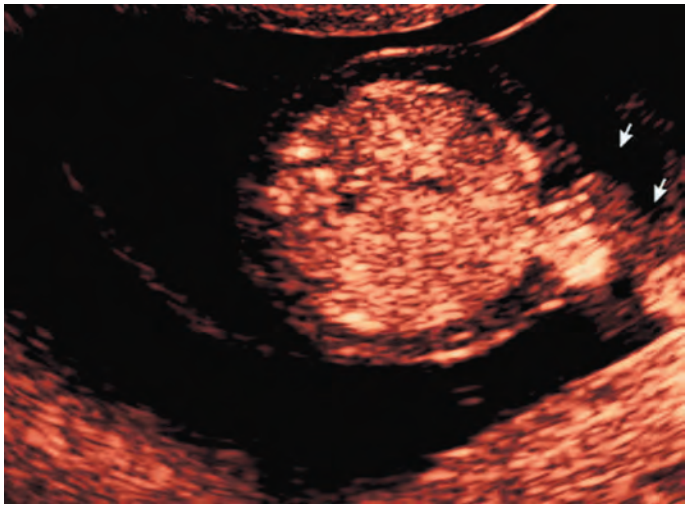

Fig. 30: Omphalocele at 16 weeks. Transverse section shows the extracorporeal bowel surrounded by a membrane.

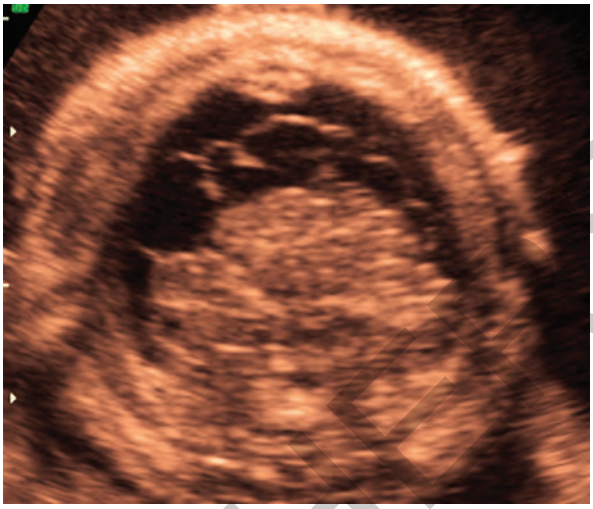

Fig. 33: Abdominal ascites at third trimester.



Fig. 31: Large liver—filled omphalocele at 38 weeks.

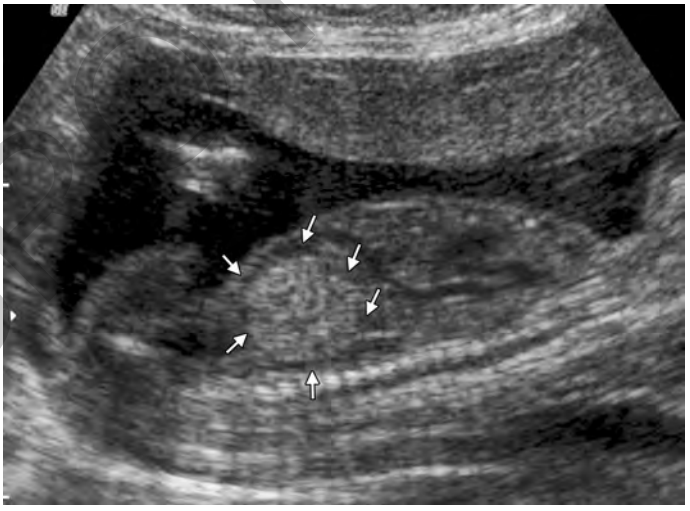

Fig. 34: Hyperechogenic bowel.

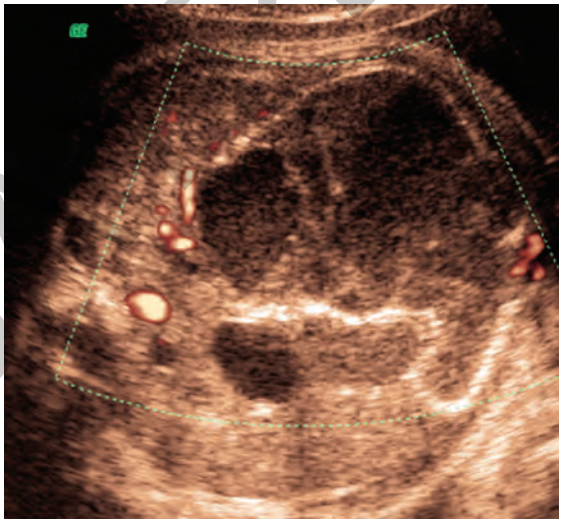

Fig. 32: Intestinal obstruction at third trimester. Dilated loops of the bowel can be seen. The baby had bowel resection after birth.

Numerous abnormalities of skeleton can be detected by ultrasound, some of which are: achondrogenesis, achondroplasia, limb deficiencies, alternations of the hands and feet, thanatophoric dysplasia, osteogenesis imperfecta, arthrogryposis, and campomelic dysplasia.[2,29,30]

CARDIAC MALFORMATIONS

Major congenital heart defects (CHDs) account for one-third of all congenital anomalies are the most common severe congenital malformations with an incidence of about 5 in 1,000 live births.[31]

Congenital heart defects are responsible for nearly half of all neonatal and infant deaths due to congenital anomalies.[2] Their incidence is six times greater than chromosomal abnormalities and four times greater than neural tube defects. The majority of the fetuses with CHD occur in the pregnancies with no identifiable risk factors. Therefore,

JAYPEE THE

detailed information on obstetrics & gynecology books, visit our website www.jaypeebrothers.com, for detailed information on obstetrics & gy

Donald School
Atlas of Fetal Anomalies

The 2nd Edition of the *Donald School Atlas of Fetal Anomalies* presents a comprehensive overview of the most common and most serious fetal anomalies encountered by sonologists and sonographers throughout the world. An international group of authorities have been brought together to address this topic with a clear text and illustrative images that will enhance perinatal care for all.



Asim Kurjak MD PhD is Professor of Obstetrics and Gynecology at Medical School Universities of Zagreb and Sarajevo, and Professor Emeritus at University Sarajevo School of Science and Technology. He received his medical degree from Medical School University of Zagreb in 1966. From 1971 to 1972, as a British scholar, he was a Research Assistant, Institute of Obstetrics and Gynecology, University of London, UK. In 1974, he became a specialist in Obstetrics and Gynecology and in 1977 he got his PhD degree. In 1980, he was awarded the position of a Professor. From 1985 to 2002, Dr Kurjak served as Head of the Department of Obstetrics and Gynecology, Medical School University of Zagreb, Sveti Duh Hospital. Dr Kurjak has published 1,160 papers which have been cited more than 15,300 times (Google Scholar). Authored, co-authored or co-edited 121 books. He is a regular fellow of World Academy of Art and Science, European Academy of Sciences and Arts, International Academy for Human Reproduction, Italian Academy of Science and Art of Reggio Puglia, Academy of Medical Sciences of Catalonia. Honorary member of American Institute of Ultrasound in Medicine and Biology, and foreign member of Russian Academy of Medical Sciences. He is the President of International Academy of Perinatal Medicine, the Director of Ian Donald Inter-University School of Medical Ultrasound and President of International Academy of Art and Science in Bosnia and Herzegovina. He received a doctor honoris causa from the Universities in Banja Luka, Budapest, Barcelona, Bucharest, Athens, Montevideo, Tomsk, Buenos Aires, St Petersburg, Moscow, Tirana and Khartoum.



Ritsuko K Pooh MD MSc PhD LLB has combined detailed transvaginal 3D sonograms with cytogenetics and molecular genetics to advance the field of fetal medical science, as the President of the Fetal Diagnostic Center/Fetal Brain Center of CRIFM Prenatal Medical Clinic (*https://fetal-medicine-pooh.jp/en/*), as well as the CEO and founder of the Ritz Medical Clinical Genetic Laboratory in Osaka, Japan. Dr Pooh is also an Affiliate Professor at Juntendo University School of Medicine in Tokyo, Japan, an Adjunct Professor at Wayne State University School of Medicine in Detroit, USA, a Professor within the Department of Health Science at Dubrovnik International University in Croatia, and an Honorary Professor at Pirogov Russian National Research Medical University in Moscow, Russia. She has been included in the editorial board of several international medical journals and received international awards for her work in fetal medicine. She is an international executive in the field of perinatology who is focused on clinical research and education. She has published more than 70 original scientific papers, 150 review articles and 4 books to date.



Frank A Chervenak MD currently serves as Chair of Obstetrics and Gynecology, Lenox Hill Hospital; Chair of Obstetrics and Gynecology and Associate Dean of International Medicine, Zucker School of Medicine at Hofstra/Northwell, New York, New York, USA. Dr Chervenak was appointed Associate Professor of Obstetrics and Gynecology and Director of Obstetric Ultrasound and Ethics at New York Hospital-Cornell Medical Center in 1987. In 1991 he was named Director of Maternal Fetal Medicine and Director of Obstetrics. In 1992 he was made Full Professor with tenure, in 1998, he was named Vice Chairman of the Department of Obstetrics and Gynecology, and in 1999 was named Acting Chairman of that department. Dr Chervenak was named Chairman and Obstetrician and Gynecologist-in-Chief in 2000. He received his Master in Medical Management degree from Carnegie Mellon University in 2001 and earned fellowship status from the American College of Physician Executives in 2008. Dr Chervenak has published over 300 papers in peer review literature and has co-authored or co-edited 36 textbooks. Research interests include ultrasound and ethics in obstetrics and gynecology and physician leadership. He has been named a member of The National Academy of Medicine of the National Academies. Currently, Dr Chervenak serves as President of the International Society of the Fetus as a Patient, Vice-president of the International Academy of Perinatal Medicine, and Co-director of The Ian Donald Inter-University School of Medicine and Ultrasound. He serves on the March of Dimes Bioethics Committee and is Chairman of the Ethics Committee of FIGO. He has been awarded doctor honoris causa from Medical Universities throughout the world. He has been admitted as a fellow ad eundem of the Royal College of Obstetricians and Gynaecologists of Great Britain and as a Foreign Member of the Russian Academy of Sciences.

Printed in India

Available at all medical bookstores
or buy online at www.jaypeebrothers.com

JAYPEE BROTHERS
Medical Publishers (P) Ltd.
EMCA House, 23/23-B, Ansari Road,
Daryaganj, New Delhi - 110 002, INDIA
www.jaypeebrothers.com

Join us on facebook.com/JaypeeMedicalPublishers

Shelving Recommendation
OBSTETRICS & GYNECOLOGY

ISBN 978-93-5465-851-8