ebrothers.com, for detailed information on otolaryngology books, visit our website www.jaypeebrothers.com, for detailed information on otolaryngology books

Surgical Atlas of Transcanal Endoscopic Ear Surgery

A Step by Step Guide

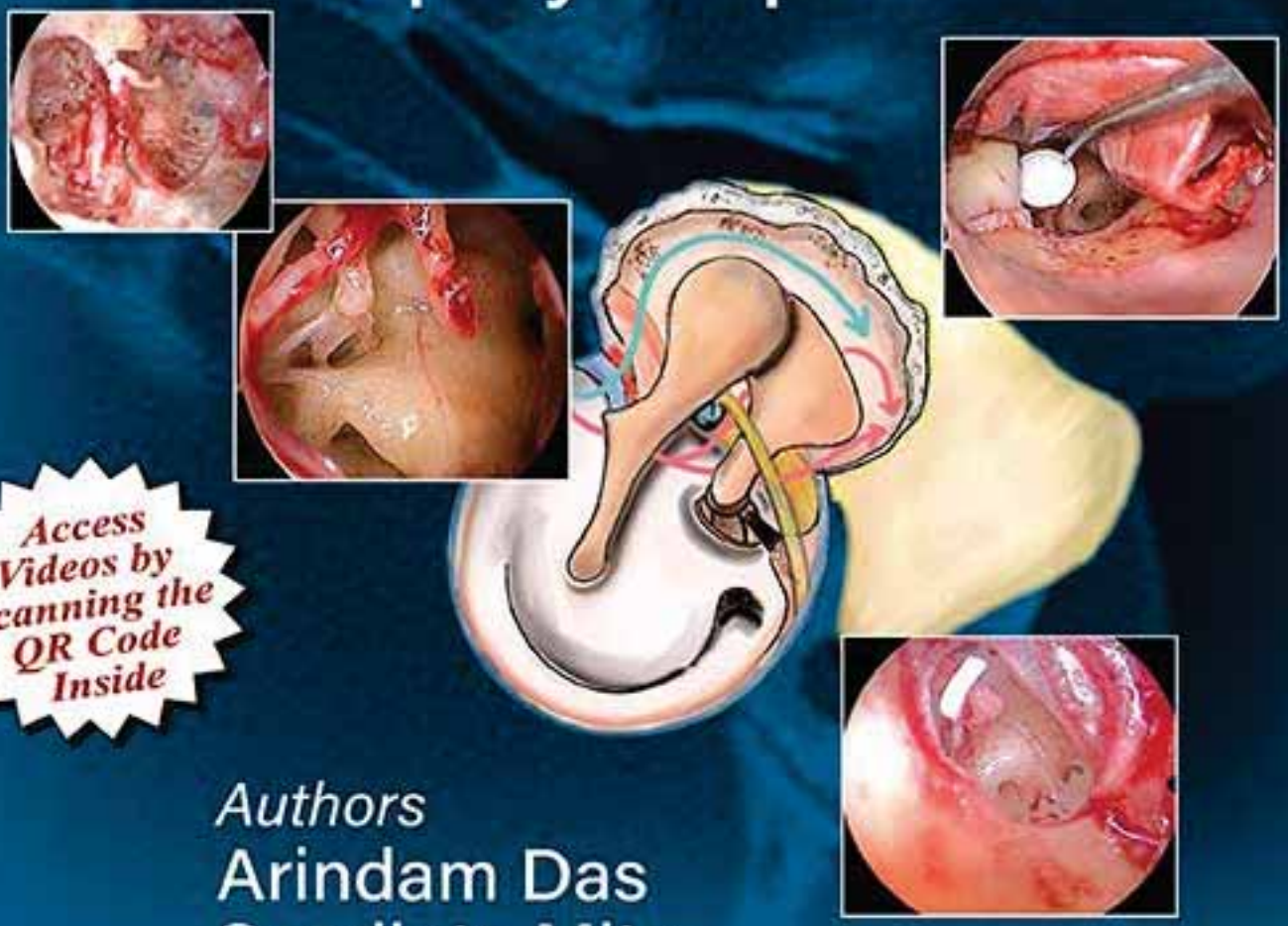

Access Videos by Scanning the QR Code Inside

Authors
Arindam Das
Sandipta Mitra
Sayan Hazra

Forewords
Mohamed MK Badr-El-Dine
Nirmal Patel

JAYPEE

Contents

1. History of Endoscopic Ear Surgery 1
Arindam Das, Sayan Hazra
- Early Days of Endoscopic Ear Surgery *2*

2. Principles of Endoscopic Ear Surgery 5
Arindam Das, Sandipta Mitra
- Clinicopathological Basis *6*
- Microscopic to Endoscopic Ear Surgery: A Paradigm Shift *6*
- Instrumentation in Endoscopic Ear Surgery *7*
- Role of Preoperative Otoendoscopy in Endoscopic Ear Surgery *9*
- Anatomical Considerations in Endoscopic Ear Surgery *9*
- Safety Concerns in Endoscopic Ear Surgery *9*
- Hemostasis in Endoscopic Ear Surgery *10*
- Role of Endoscope Holder in Endoscopic Ear Surgery *12*
- Endoscopic Bone Drilling: The Art *12*
- Exposure in Endoscopic Ear Surgery *13*
- Endoscopic Ear Surgery as a Teaching Tool *13*
- Endoscopic Ear Surgery: The Shortcomings *13*

3. Endoscopic Anatomy of Middle Ear: A Surgeon's Perspective 15
Arindam Das, Sandipta Mitra
- Surgical Anatomy of Retrotympanum *17*
- Surgical Anatomy of Epitympanum *24*
- Surgical Anatomy of Protympanum *32*
- Surgical Anatomy of Hypotympanum *36*
- Surgical Anatomy of Chorda Tympani *37*
- Endoscopic Anatomy of Cochlea *39*

4. Operation Theater Setup and Instruments 45
Arindam Das, Sayan Hazra
- Endoscope *46*
- Camera and Monitor *47*
- Operation Theater Setup *54*
- Instrument Sets *54*
- Patient Preparation *63*
- Surgeon and Patient Position *66*
- Table Arrangement *68*
- Postoperative Care *68*

5. Imaging for Endoscopic Ear Surgery 69
Arindam Das, Sayan Hazra
- Preimaging Preparation: Its Role and Importance *70*
- Role of Preoperative Computed Tomography Scan *70*
- How to Read the Computed Tomography Scan? *70*
- Case-based Study of Preoperative CT Scan *80*
- Intensity Projection in 3D-MPR Mode *81*
- Magnetic Resonance Imaging Fundamentals *87*
- Role of Preoperative Magnetic Resonance Imaging *88*

6. Endoscopic Myringotomy 89
Arindam Das, Sayan Hazra
- Indications *90*
- Preoperative Preparation *90*
- Types of Grommets Used *90*
- Surgical Steps *90*

JAYPEE BROTHERS

7. Endoscopic Myringoplasty/Tympanoplasty 100
Arindam Das, Sandipta Mitra
- Important Definitions *101*
- Indications of Endoscopic Tympanoplasty *101*
- Surgical Rationale and Its Physiological Basis *101*
- Freshening of Margins of Perforation *105*
- Incision *108*
- Flap Elevation *111*
- Middle Ear Inspection *121*
- Palpation of Ossicular Chain *123*
- Preparation of Graft Bed *124*
- Preparation of Temporalis Fascia *126*
- Preparation of Cartilage-Perichondrium *130*
- Graft Placement *132*
- Closing Steps *138*

8. Endoscopic Ossiculoplasty 139
Arindam Das, Sandipta Mitra
- Austin Classification of Ossicular Chain Defects with Absent Incus *140*
- Kartush Modification of Austin Classification of Ossicular Chain Defects *140*
- Materials Used for Ossiculoplasty *140*
- General Principles of Ossiculoplasty *140*
- Prognostication in Ossiculoplasty *140*
- Principles of Endoscopic Ossiculoplasty *140*
- Steps of Endoscopic Ossiculoplasty *141*
- Clinical Scenario: Stapes Superstructure Present (S+); Reconstruction with Partial Ossicular Replacement Prosthesis *142*
- Clinical Scenario: Stapes Superstructure Absent (S–); Reconstruction with Total Ossicular Reconstruction Prosthesis *157*

9. Endoscopic Epitympanic Exploration 161
Arindam Das, Sandipta Mitra
- Indications of Endoscopic Epitympanic Exploration *162*
- Surgical Rationale and Its Physiological Basis *162*

10. Endoscopic Transcanal Atticotomy 183
Arindam Das, Sandipta Mitra
- Principle of Endoscopic Transcanal Atticotomy and its Difference with Microscopic Atticotomy *184*
- Steps of Surgery *185*

11. Minimally Invasive Endoscopic Mastoid Surgery 208
Arindam Das, Sandipta Mitra
- Indications of Minimally Invasive Endoscopic Mastoid Surgery *209*
- Contraindications of Minimally Invasive Endoscopic Mastoid Surgery *209*
- Rationale of Minimally Invasive Endoscopic Mastoid Surgery *209*

12. Endoscopic Management of Tympanosclerosis 234
Arindam Das, Sayan Hazra
- Etiopathogenesis *235*
- Sites of Involvement and Its Effects *235*
- Management Protocols *237*

13. Endoscopic Stapes Surgery 258
Arindam Das, Sandipta Mitra
- Special Preoperative Considerations *259*
- Special Instruments for Endoscopic Stapes Surgery *259*
- Endoscopic Stapedotomy *262*
- Endoscopic Stapedectomy *304*

14. Endoscopic Transcanal Facial Nerve Decompression 312
Arindam Das, Sandipta Mitra
- Endoscopic Facial Nerve Decompression: Concept of Segmental Decompression *313*

JAYPEE BROTHERS

- Rationale of Endoscopic Transcanal Facial Nerve Decompression *315*
- Indications of Endoscopic Transcanal Facial Nerve Decompression *315*
- Contraindications of Endoscopic Transcanal Facial Nerve Decompression *315*
- Preoperative Considerations *315*
- Steps of Surgery *317*
- Specific Points Related Segmental Decompression *350*

15. Recent Advances and Future of Transcanal Endoscopic Ear Surgery 352

Arindam Das, Sayan Hazra

- Three-dimensional High-definition System *353*
- Laser *355*
- 4K Technology and Narrow-band Imaging in TEES *358*

Index *367*

JAYPEE BROTHERS

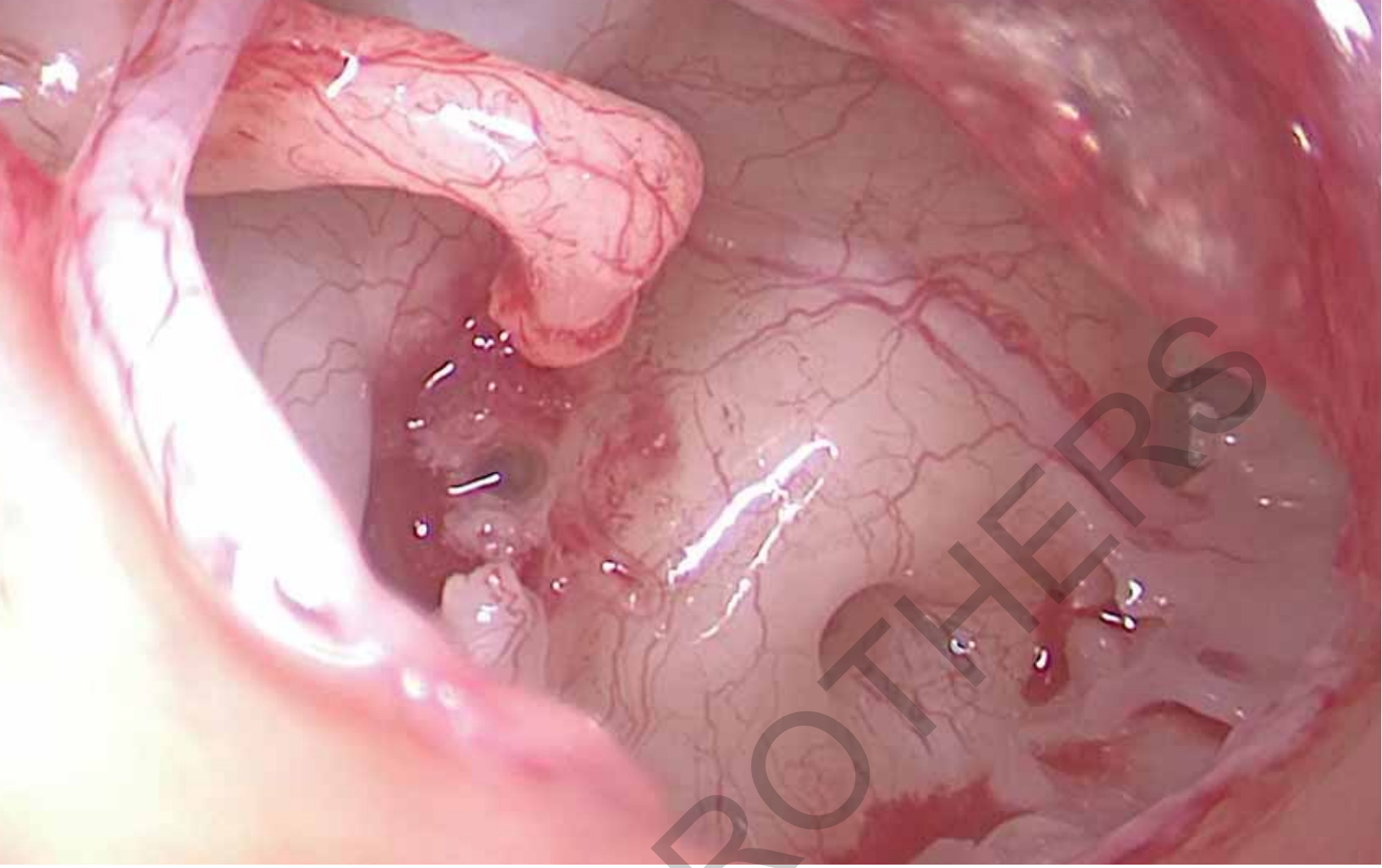

CHAPTER 13

Endoscopic Stapes Surgery

Arindam Das, Sandipta Mitra

Chapter Outline

- Introduction 259
- Special Preoperative Considerations 259
- Special Instruments for Endoscopic Stapes Surgery 259
- Endoscopic Stapedotomy 262
- Endoscopic Stapedectomy 304
- References 311

JAYPEE BROTHERS

INTRODUCTION

Otosclerosis has been defined as a localized hereditary disorder of metabolism of otic capsule enchondral bone that is characterized by disordered resorption and deposition of bone.[1]

A number of surgical approaches for treatment of otosclerosis have been described in literature, of which the most noteworthy are stapedotomy and stapedectomy. Stapedotomy is the creation of an opening in the footplate of stapes followed by placement of a stapes prosthesis. Shea performed the first stapedectomy in the year 1956. He is regarded as the pioneer of the modern surgical treatment of otosclerosis.[2]

Endoscopes offer a wider panoramic and magnified view of the working area without sacrifice of any soft tissue lying ahead. In contrast, in microscopic stapedotomy, it is often required to curette the posterosuperior canal wall in order to visualize the incudostapedial complex with considerable amount of chorda tympani manipulation.

It has been found that endoscopic stapedotomy entails lesser bone removal, chorda tympani handling, better visibility of the footplate area, lesser operating time, less postoperative pain, and minimal postoperative taste alteration when compared to microscopic stapedotomy.[3]

SPECIAL PREOPERATIVE CONSIDERATIONS

- *Preoperative diagnostic otoendoscopy*: This can be useful to know the gross anatomical dimension and slant of the external auditory canal, presence of any major canal humps, etc. These factors, especially for beginners have significant impact as it enables careful planning before surgery
- *Preoperative imaging*: In clinically suspicious or revision cases, imaging can give valuable clues regarding anatomical variations such as wide vestibular aqueduct which may give rise to an intraoperative gusher. In such cases, sole endoscopic approach may not turn out to be successful and that a back-up microscope should be kept at hand.

SPECIAL INSTRUMENTS FOR ENDOSCOPIC STAPES SURGERY

- Annulus elevator
- 2 mm angled pick
- Angled curette
- Curved microscissors
- Angled measuring rod (Fisch)
- Perforators of different sizes
- Hand burrs
- Skeeter drill



Fig. 1: Round knife and annulus elevator.

JAYPEE BROTHERS



Fig. 2: 2 mm angled pick.



Fig. 3: Perforators of different sizes.



Fig. 4: 0.8 and 0.9 mm hand burrs.

JAYPEE BROTHERS

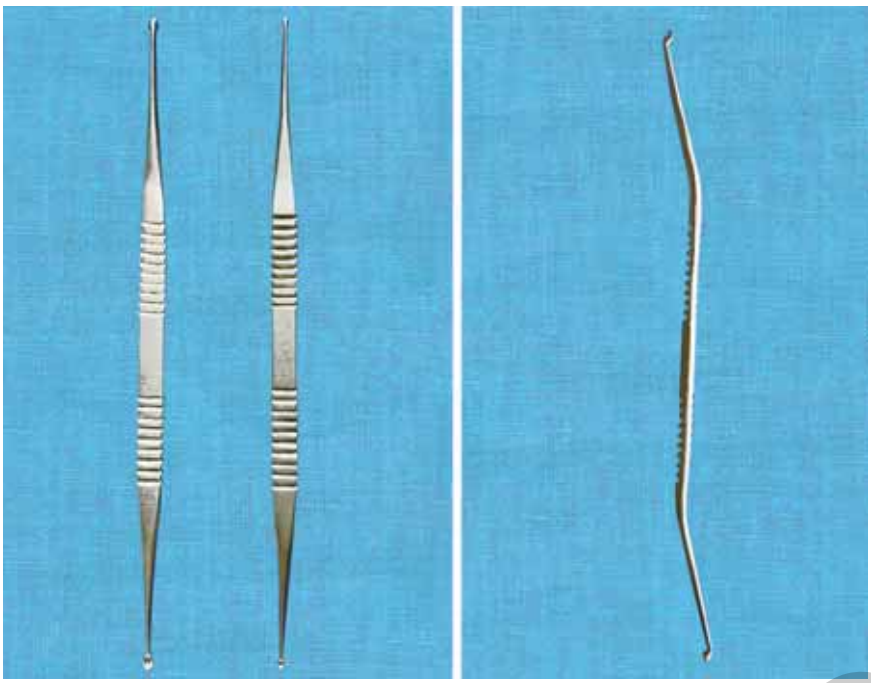

Fig. 5: Angled curette of different sizes.



Fig. 6: Angled measuring rod (Fisch).

JAYPEE BROTHERS



Fig. 7: Skeeter drill.



Fig. 8: Burrs for skeeter drill; single color—cutting burr, dual colored—diamond burr.

ENDOSCOPIC STAPEDOTOMY

Endoscopic stapedotomy	*Microscopic stapedotomy*
• Chorda tympani nerve is identified • The nerve is dissected minimally to obtain a ledge of bone to engage the curette • Minimal bone curettage • Nerve transposed back into its neocanal superiorly • Better visualization of incudostapedial complex	• Greater volume of bone has to be removed in order to attain a similar view of incudostapedial complex

JAYPEE BROTHERS

- *Anesthesia:* Four quadrant infiltration with 2% Lidocaine with Adrenaline (1:1 00,000).

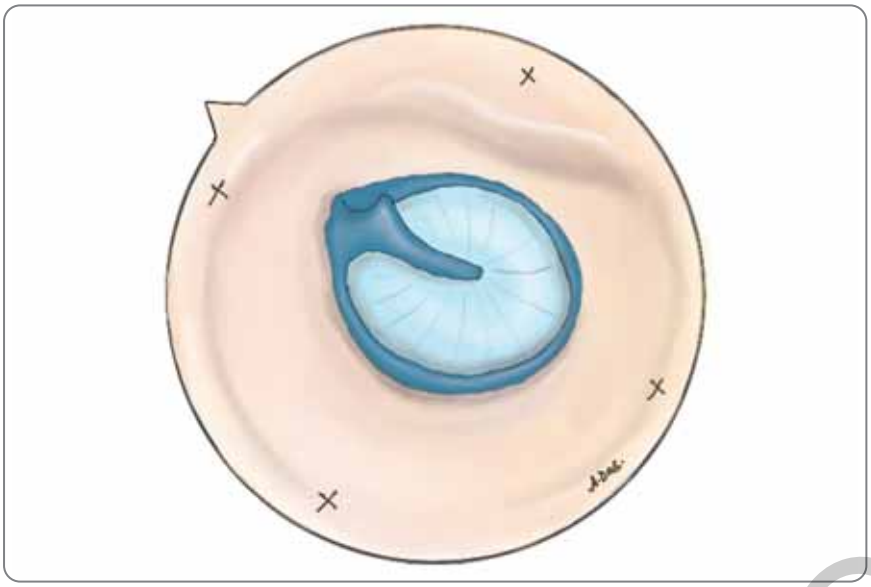

Fig. 9: Sites of four quadrant infiltration of local anesthesia (marked with x).

TIP

For anesthesia, needle of a finer gauge is of choice, to minimize trauma. Insulin syringe of 1cc capacity is the most appropriate for four quadrant infiltration.

PEARL

Lower gauge needles may cause trauma to canal skin and lead to bleb or hematoma formation. This again may impede visualization and pose difficulty during surgery. In case of such a situation, the bleb or hematoma may be punctured with a fine tipped angled pick followed by application of pressure with cotton ball soaked in adrenaline.

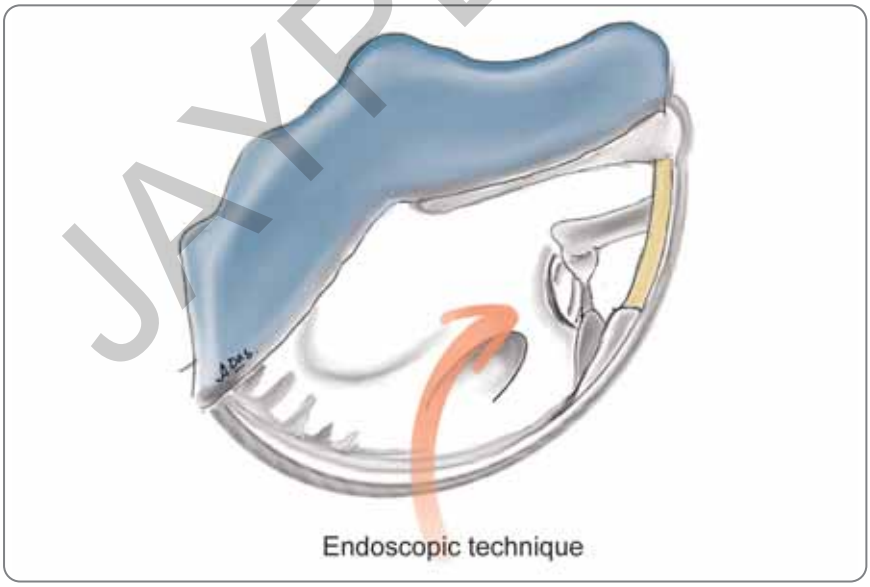

Fig. 10A: Working window of endoscopic stapedotomy. Schematic depiction.

JAYPEE BROTHERS

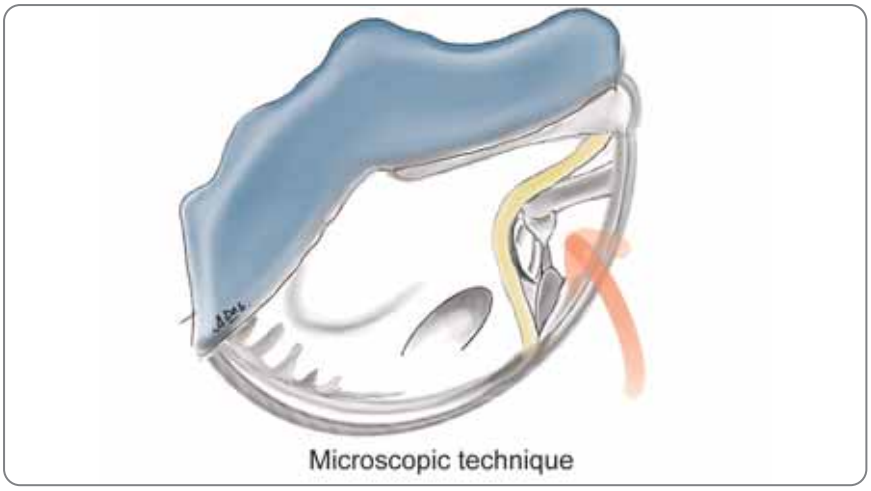

Fig. 10B: Working window of microscopic stapedotomy. Schematic depiction.

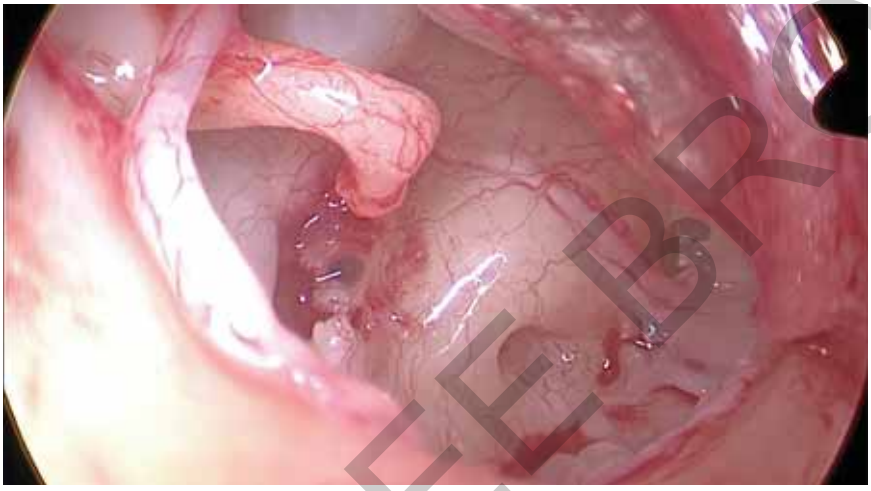

Fig. 10C: Working window of endoscopic stapedotomy.

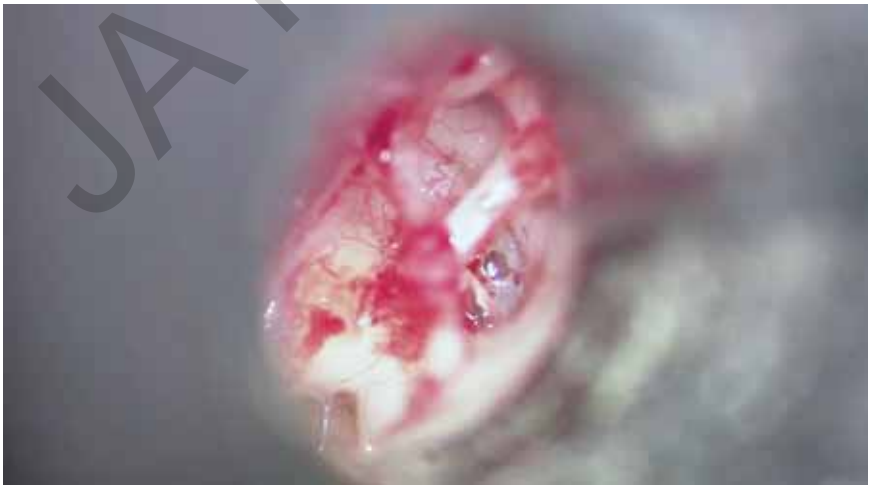

Fig. 10D: Working window of microscopic stapedotomy (transcanal technique using aural speculum).

JAYPEE BROTHERS

Incision

- Incision is made 4–6 mm lateral to the annulus and curved superiorly just anterior to the lateral process of malleus.



Fig. 11: Palpation of annulus with the help of round knife to correctly identify the site of incision.

TIP

Always palpate the position of the annulus prior to fashioning of the incision. The incision is then fashioned with respect to the position of the annulus.

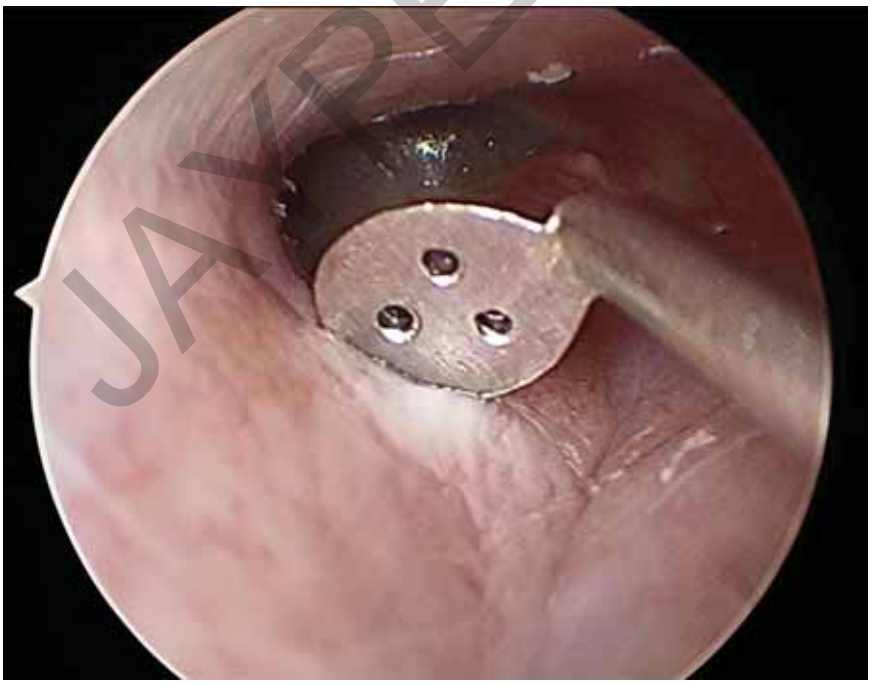

Fig. 12A: Horizontal limb of incision being placed 4–6 mm lateral to the annulus (left ear).

JAYPEE BROTHERS

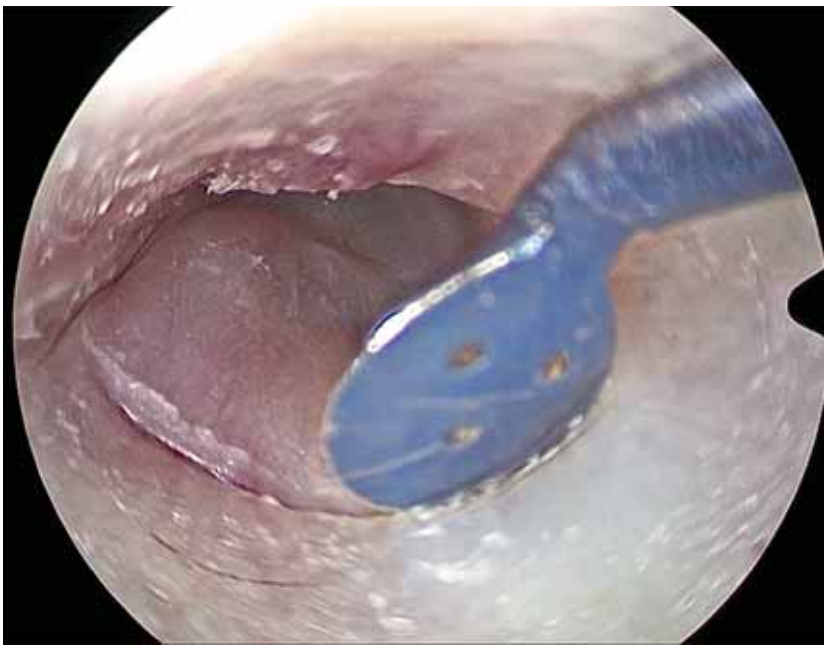

Fig. 12B: Horizontal limb of incision being placed 4–6 mm lateral to the annulus (right ear).

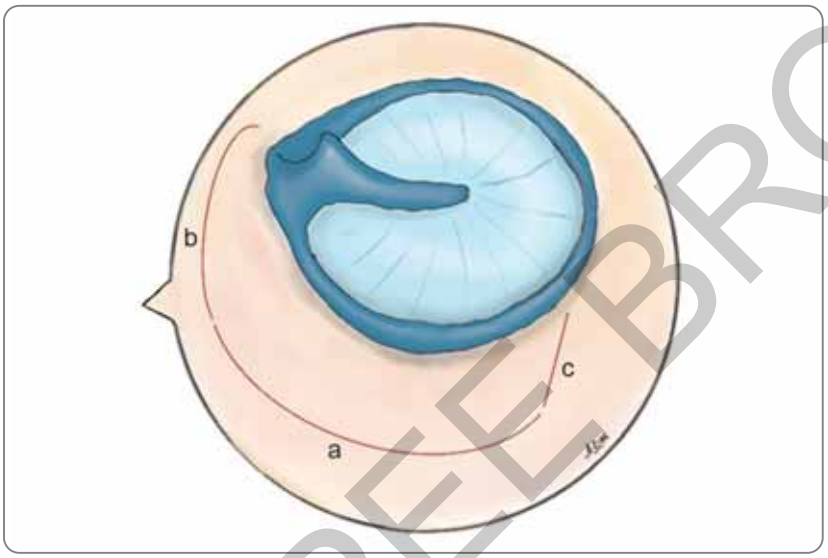

Fig. 13A: Schematic depiction of the three limbs of incision in right ear marked as a—horizontal limb, b—superior limb, c—inferior limb.

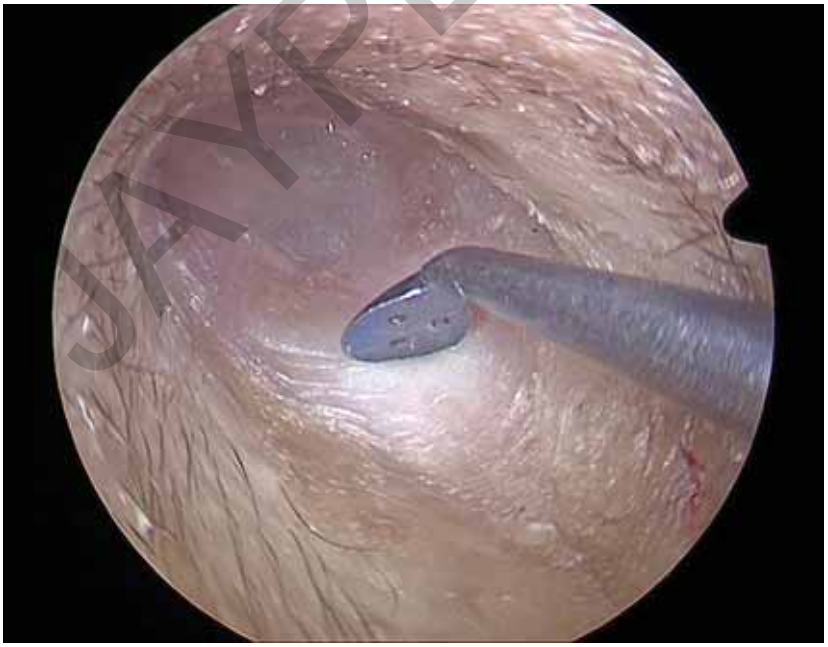

Fig. 13B: Horizontal limb of incision being placed with a sharp circular knife.

JAYPEE BROTHERS

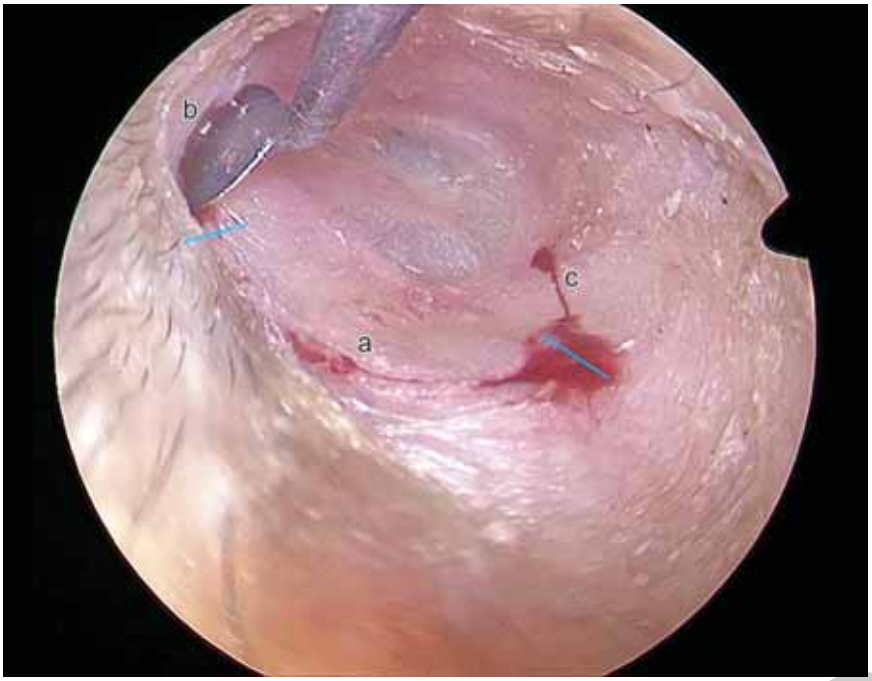

Fig. 13C: Superior limb of the incision being placed with circular knife.
(a—horizontal limb, b—superior limb, c—inferior limb)



Fig. 13D: Inferior limb of incision being placed a side knife.

- The incision is extended inferiorly up to 6-O' clock position.
- Superiorly, the incision is extended just anterior to the lateral process of the malleus.

TIP

Anterior edge of the superior incision is cut sharply with angled micro or spring scissors

JAYPEE BROTHERS

for detailed information on otolaryngology books, visit our website www.jaypeebrothers.com, for detailed information on otolaryngology books, visit our website

Surgical Atlas of Transcanal Endoscopic Ear Surgery

A Step by Step Guide

Salient Features

- Concise surgical manual of transcanal endoscopic ear surgery
- Covers basic to advanced endoscopic ear surgeries
- Each step of surgery discussed in points with possible preoperative and intraoperative considerations and their management
- Full HD snapshots demonstrating each step of surgery
- Accompanying high-quality hand-drawn illustrations for better understanding
- Provides Tips and Pearls for readers
- Atlas of instruments required for endoscopic ear surgery set-up
- Explains principles and radiological insights needed to perform endoscopic ear surgery
- Includes 140 hand-drawn images and more than 400 high-definition figures have been added for easy understanding
- Includes step-by-step approach to Endoscopic Stapes Surgery and Endoscopic Transcanal Facial Nerve Decompression Surgery.



Arindam Das MS (ENT) did his postgraduation from Institute of Postgraduate Medical Education and Research (IPGMER) and SSKM Hospital, Kolkata, West Bengal, India. At present, he is working as an Assistant Professor in the Institute of Otorhinolaryngology & Head and Neck Surgery (IORL & HNS), Kolkata. Being a versatile Otologist, he is doing Endoscopic and Microscopic Ear Surgery, Cochlear Implantation, Facial Nerve Surgery and Lateral Skull-Base Surgery regularly. He has mentored many temporal bone dissection workshops and trained endoscopic ear surgery skills to aspiring ENT surgeons. He has published many original articles in world renowned, Pubmed-indexed international journals. He has pioneered various novel techniques and scoring systems in the field of Endoscopic Ear Surgery. He is an active member of International Working Group on Endoscopic Ear Surgery (IWGEES). He bagged Best Paper Prize-2020 by *Journal of Laryngology and Otology* for his original research work entitled *Prolonged intraoperative thermal exposure in endoscopic ear surgery: is it really safe?*. He was awarded First prize in oral presentation in 18th National conference of Cochlear Implant Group of India (CIGICON-2021). Beside his academic and research achievements, he has keen interest in medical and scientific illustration.



Sandipta Mitra MBBS MS MRCS (London) DNB graduated from the Institute of Postgraduate Medical Education and Research (IPGMER) and SSKM Hospital, Kolkata, West Bengal, India. She completed her Master in Surgery in Otorhinolaryngology from her parent institute. She is Senior Resident (Academic), All India Institute of Medical Sciences, New Delhi. She is a recipient of the Membership of Royal College of Surgeons (MRCS) from the prestigious Royal College of Surgeons (RCS), England. She has also obtained the degree of Diplomate of National Board of Examinations. Recipient of the *Journal of Laryngology and Otology (JLO)*, UK Best Paper Award 2020, she has published her research work in many internationally acclaimed journals. She has been invited as Reviewer in a number of world-renowned journals. Fascinated by the diversity of the branch, she holds a keen interest in the fields of Endoscopic Ear Surgery and Head and Neck Oncology. She is currently pursuing her Master of Chirurgiae (MCh) in Head and Neck Surgery and Oncology from All India Institute of Medical Sciences (AIIMS), New Delhi.



Sayan Hazra MBBS MS-ENT (Gold Medal) DNB is a young dynamic ENT Surgeon with special interest in Otology and Cochlear implant surgery. He did his undergraduation from NRS Medical College in 2014 and MS in ENT and Head-Neck Surgery from Institute of Postgraduate Medical Education and Research (IPGMER), Kolkata, West Bengal, India in 2018 where he was awarded Gold Medal for being the university topper. In 2019, he passed DNB examination, New Delhi. He has many original articles published in indexed national and international journals to his credit. He won many prizes in State level and National level temporal bone dissection competitions. He has mentored many temporal bone dissection workshops and continues to train endoscopic and microscopic ear surgery skills to aspiring ENT surgeons of the state. He is an active member of the prestigious International Working Group on Endoscopic Ear Surgery (IWGEES). Currently, he is Senior Resident (ENT), Institute of Otorhinolaryngology & Head and Neck Surgery (IORL & HNS), at IPGMER, and SSKM Hospital, Kolkata and Visiting Consultant at Narayana Hospital, Kolkata.

Printed in India

Available at all medical bookstores or buy online at www.jaypeebrothers.com

JAYPEE BROTHERS
Medical Publishers (P) Ltd.
EMCA House, 23/23-B, Ansari Road,
Daryaganj, New Delhi - 110 002, INDIA
www.jaypeebrothers.com

Join us on facebook.com/JaypeeMedicalPublishers

Shelving Recommendation
OTORHINOLARYNGOLOGY

ISBN 978-93-5465-888-4