eebrothers.com, for detailed information on nephrology books, visit our website www.jaypeebrothers.com, for detailed information on nephrology book



Cases in Nephrology

Muhammad Rafiqul Alam

Forewords
Md Sharfuddin Ahmed
Harun-Ur-Rashid

JAYPEE

CONTENTS

Chapter 1:	**Diabetic Nephropathy with Chronic Kidney Disease**	**1**
Chapter 2:	**Lupus Nephritis**	**6**
Chapter 3:	**Antineutrophil Cytoplasmic Antibody-positive Glomerulonephritis**	**13**
Chapter 4:	**Post-transplant Thrombotic Microangiopathy**	**18**
Chapter 5:	**Transplantation in a Patient with Lower Urinary Tract Abnormality**	**21**
Chapter 6:	**Preemptive Renal Transplantation**	**26**
Chapter 7:	**Acute Kidney Injury**	**31**
Chapter 8:	**Gitelman Syndrome**	**35**
Chapter 9:	**Renal Amyloidosis**	**38**
Chapter 10:	**Down's Syndrome with Chronic Kidney Disease**	**43**
Chapter 11:	**Continuous Ambulatory Peritoneal Dialysis Peritonitis**	**46**
Chapter 12:	**Wilson's Disease with Focal Segmental Glomerulosclerosis**	**49**
Chapter 13:	**Immunoglobulin M Nephropathy**	**53**
Chapter 14:	**Membranoproliferative Glomerulonephritis**	**56**
Chapter 15:	**Membranous Nephropathy**	**61**
Chapter 16:	**Henoch–Schönlein Purpura Nephritis**	**66**
Chapter 17:	**Alport Syndrome**	**72**
Chapter 18:	**Lipomyelomeningocele with Tethered Cord Syndrome, Neurogenic Bladder, CKD, and Disseminated Tuberculosis**	**75**
Chapter 19:	**Systemic Lupus Erythematous, Lupus Nephritis, and Avascular Necrosis of Femoral Head**	**81**

Chapter 20: Membranous Nephropathy: Remission with Supportive Treatment 85

Chapter 21: Collagenofibrotic Glomerulopathy 88

Chapter 22: Cytomegalovirus Pneumonia in Kidney Transplant Patient 93

Chapter 23: Cellular Rejection in Renal Allograft Recipient 97

Chapter 24: Vascular Complication after Renal Transplantation 105

Chapter 25: Sepsis in a Renal Allograft Recipient 112

Chapter 26: Chronic Pyelonephritis due to Vesicoureteric Reflux, Secondary FSGS, Renal Abscess, and CKD 115

Chapter 27: Refractory Lupus Nephritis 120

Chapter 28: Systemic Amyloidosis Involving Kidney and Heart 124

Chapter 29: Myelodysplastic Syndrome and Nephrotic Syndrome 127

Chapter 30: Minimal Change Disease or Focal Segmental Glomerulosclerosis 131

Index 135

2
CHAPTER

Lupus Nephritis

INTRODUCTION

Mrs SK, 20 years old, Muslim, homemaker, was admitted to our hospital with the complaints of pain in multiple joints for 4 months, generalized swelling of the whole body for 2 months and fever for last 1 month. According to the patient's statement, she was reasonably well about 4 months back, then she noticed pain in multiple joints which was insidious in onset and involving small and large joints of upper and lower limbs, predominantly upper limbs, moderate in intensity, symmetrical, inflammatory in nature with morning stiffness >1 hour, not relieved by rest but reduced by pain killers. She also complained of excessive hair fall and multiple painless oral ulcers for same duration. Then she developed swelling all over the body 2 months back, initially appeared in face, then gradually involved rest of the body. The swelling was associated with breathlessness, cough, and productive sputum, which was white and frothy, no hemoptysis was noted. She has no history of reduction in urine output, no history of passage of dark-colored urine, but patient mentioned about passing of frothy urine. She had no history of chest pain, paroxysmal nocturnal dyspnea, and orthopnea. In addition to that she complained of fever for last 1 month which was continued in nature, not associated with chills and rigor, relieved partially by antipyretics, highest recorded temperature was 102°F. With these complaints, she was admitted in our hospital and during hospital stay on, she developed generalized tonic-clonic seizure which persisted for 5 minutes, associated with visual aura, headache, and postictal confusion. There was no history of tongue bite or urinary or fecal incontinence. She was managed with intramuscular (IM) diazepam and intravenous (IV) phenytoin. There was no history of previous seizure prior to this episode.

JAYPEE BROTHERS

This lady has no significant history of past illness. She is nonsmoker, nonalcoholic, she has no history of contact with any tuberculosis patient. She has one son who is in good health. Her parents are alive and well. Her all other family members are healthy. She comes from a middle class family, her husband works at a textile industry, earning 20,000 per month. They live in tin-shed house and drink tube well water. She is immunized according to Expanded Programme on Immunization (EPI) schedule. Pneumococcal and influenza vaccine was given during the hospital course. She is a normally menstruating woman. She has no history of abortion.

On examination, her appearance was ill-looking, puffy face, she was mildly anemic, her pulse was 76 bpm, her blood pressure (BP) was 140/80 mm Hg, temperature 99°F, moderately edematous, painless oral ulcers present and bedside urine dipstick showed +++ proteinuria. Jaundice, cyanosis, clubbing, koilonychias, leukonychia, and lymphadenopathy. Mild tenderness present in the small joint of hands, wrist, elbow, and knee joint. There was no swelling of joints and no deformity.

Respiratory and cardiovascular system examination revealed no abnormality. Fundoscopy is normal.

INVESTIGATIONS

Urine R/M/E showed albumin +++, red blood cell (RBC): 8–10/high power field (HPF), white blood cell (WBC): 6–10/HFP, cast: granular 4–8/HPF, 24 hours urinary total protein: 4.02 g/day, hemoglobin: 10.1 g/dL, erythrocyte sedimentation rate (ESR) (in 1st hour) 105 mm, WBC count: 9,000, N—88%, L—11%, platelet count: 270,000, serum albumin: 21 g/L, serum creatinine: 1.45 mg/dL, serum electrolytes: Na—130 mmol/L, K—4.4 mmol/L, Cl—103.8 mmol/L, TCO_2—27.1 mmol/L, serum calcium: 1.7 mmol/L corrected Ca (1.2 mmol/L), serum iron: 13 mcg/dL (normal range: 60–170 mcg/dL), serum ferritin: 716 ng/mL (normal range: 24–336 ng/mL), total iron-binding capacity (TIBC) 194 mcg/dL (normal range: 240–450 mcg/dL), transferrin saturation (TSAT): 6.70%, anti-hepatitis C virus (HCV), HBsAg, anti-HBc: negative, prothrombin time: control 12.00 seconds patient 30 seconds, international normalized ratio (INR): 1.13, activated partial thromboplastin time (APTT): Control 26 seconds patient 30 seconds, bleeding time (BT): 3 minutes, clotting time (CT): 6 minutes, echocardiography showed: Moderate pericardial effusion (14 mm), and ejection fraction (EF)—58%.

Ultrasonography of Whole Abdomen

- Both kidneys are normal in size, shape, and position.
- Normal corticomedullary differentiation
- Moderate ascites present

JAYPEE BROTHERS

Noncontrast Computed Tomography Scan of Chest

- Inflammatory lesion with subsegmental consolidation in right lung, more marked in middle and lower lobes
- Right-sided mild pleural effusion and mild pericardial effusion

Magnetic Resonance Imaging of Brain

- Acute infarcts **(Fig. 1)**

Renal Biopsy

Light microscopic examination **(Figs. 2A to D)**:

- *Glomerulus*: Number-18, size-enlarged, cellularity-proliferation of endocapillary cells, matrix-increased (++), glomerular basement membrane (GBM)—thick
- *Tubules*: Tubular atrophy—mild, epithelium-features of protein reabsorption, tubular basement membrane (TBM), thick in atrophic tubules, cast—hyaline, RBC, and granular
- *Interstitium*: Inflammation—chronic, mild

Direct immune fluorescence finding:

- Immunoglobulin G (IgG)—GBM, mesangial deposition, granular, and intensity is (++++)
- IgA—GBM, mesangial deposition, granular, and intensity is (+)
- C3—GBM, mesangial deposition, granular, and intensity is (++)
- C1q—GBM, mesangial deposition, granular, and intensity is (++)
- Kappa—GBM, mesangial deposition, granular, and intensity is (++)
- Lamda—GBM, mesangial deposition, granular, and intensity is (++)

Comment: Diffuse proliferative lupus nephritis (LN) (class IV)

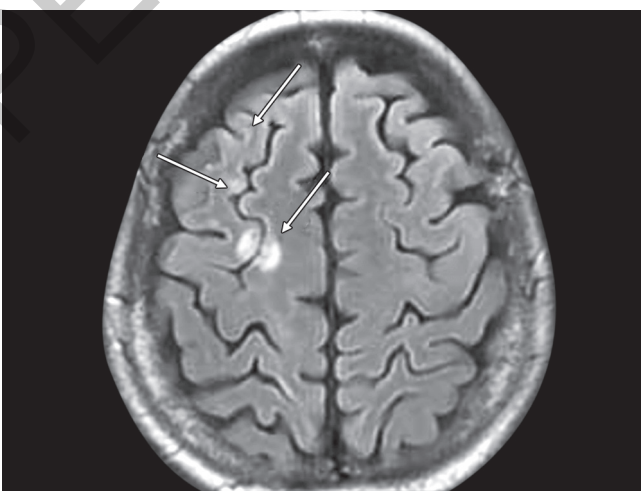

FIG. 1: Magnetic resonance imaging (MRI) of brain showing infarct (arrows).

JAYPEE BROTHERS

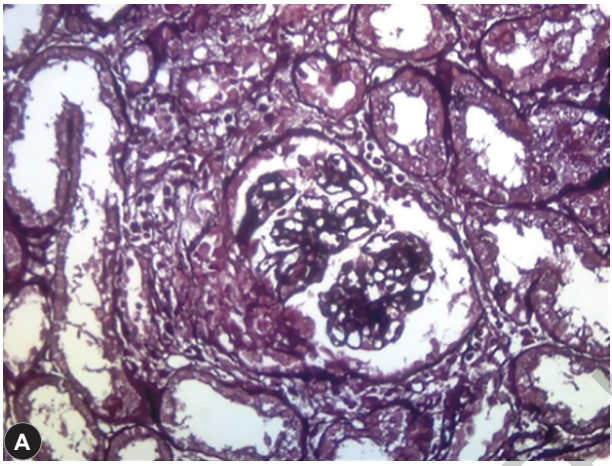

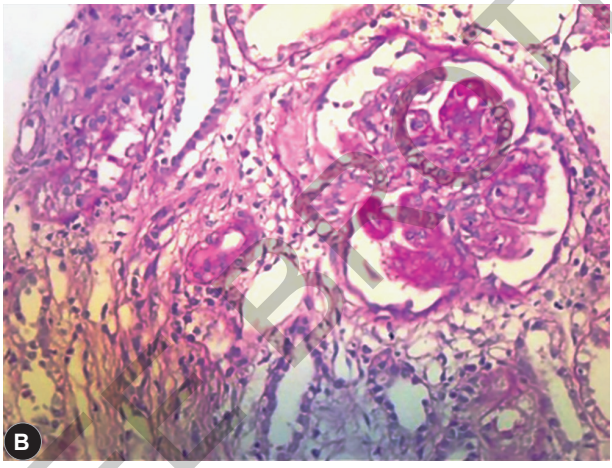

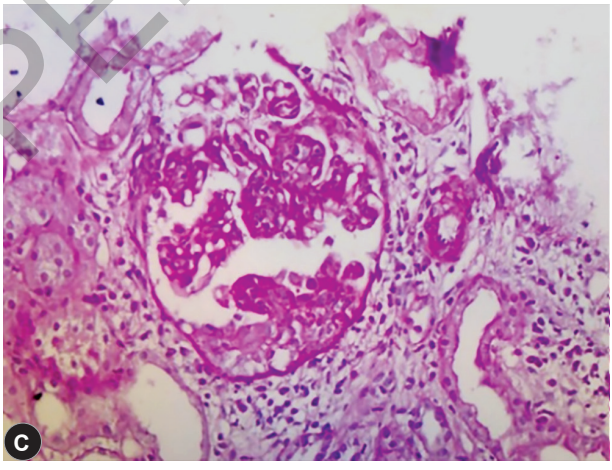

FIGS. 2A TO D: *Continued*

JAYPEE BROTHERS

Continued

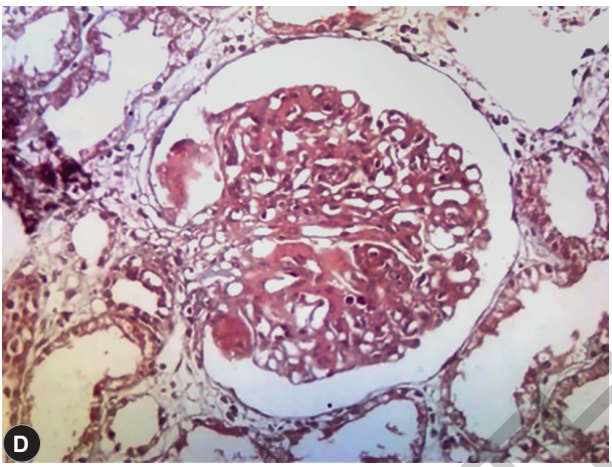

FIGS. 2A TO D: Lupus nephritis class IV (histopathology slides).

TREATMENT

The patient got several medications after admission in our hospital. Those were: Injection methylprednisolone 1 g IV daily for 3 days followed oral prednisolone 1 mg/kg/day. Injection lasix (20 mg)—1 amp IV 12 hourly, injection phenytoin 750 mg diluted in 200 mL normal saline @30 d/min, followed by injection phenytoin (150 mg)—1 amp IM tds for 7 days, tablet levetiracetam 250 mg bd, tablet paracetamol (500)—per oral (po) sos, after renal biopsy, she was given treatment according to KDIGO guidelines for class 4 LN with IV cyclophosphamide 750 mg/m^2 1st dose and was advised to follow-up for further treatment.

DISCUSSION

Systemic lupus erythematosus (SLE) can affect any organ of the body. But renal and neurological involvement is prognostically bad. Although SLE is female preponderant disease, LN affects both gender equally. However, it is more severe in men and children. Renal involvement occurs in about 60% adult lupus patients. Some patients may present with renal involvement (membranous LN) at the beginning without other systemic features. Renal involvement is characterized by active urinary sediment proteinuria (hematuria and RBC cast) and hypertension. Some other glomerular diseases mimic SLE. These are Henoch–Schönlein purpura nephritis (immunoglobulin A deposition in HSP and full house deposition in SLE).

Pauci immune rapidly progressive glomerulonephritis (RPGN) with positive antineutrophil cytoplasmic antibody (ANCA) may be confused with LN (serology and renal biopsy). Patients positive for both ANCA and antinuclear antibody (ANA) or anti-ds DNA but having no immune

JAYPEE BROTHERS

deposits on renal biopsy be treated as pauci immune glomerulonephritis (GN).

Antineutrophil cytoplasmic antibody positivity has got no significance in an established case of SLE. Bacterial endocarditis and cryoglobulinemia can also mimic SLE.

Neurological involvement usually presents with headache, psychosis, seizure, and coma.

Patients with severe proliferative LN and patients with neurological involvement need aggressive treatment as has been done in the present case. In most cases, acute renal condition improves in 3 months of treatment and by 6 months almost all responding patients show improvement in glomerular filtration rate (GFR), decline in proteinuria and serologic markers such as anti-ds DNA antibody titers and complement levels also improve during this time period.

Relapse rate varies from 35 to 60%. Elevation of anti-ds DNA antibody titer and decrease in complement level may herald a relapse. Monitoring during remission includes BP measurement, estimation of GFR, proteinuria, and urinary sediment.

To stop treatment is often possible after 5 years or more when there is no proteinuria, normal serological tests, and stable renal function.

FREQUENTLY ASKED QUESTIONS

Q1. What is SLICC criteria for diagnosis of LN?

Ans. SLICC criteria require at 4 of 17 criteria including 1 of the 11 clinical criteria and 1 of 6 immunologic criteria or that the patient has biopsy-proven nephritis compatible with SLE in the presence of ANA or anti-ds DNA positivity.

Q2. What are the types of flares in LN?

Ans. Two types of flares:

1. *Proteinuria flare*: An isolated increase in proteinuria typically at least doubling and above 1 g/24 hours
2. *Nephritic flare*: Appearance of glomerular hematuria or red cell casts with proteinuria, with or without hypertension and a decline in GFR

Q3. What are the indications of repeat renal biopsy?

Ans.

- At the time of flare
- Rapidly declining GFR
- To detect class transformation and activity and chronicity index

Q4. Treatment of class IV lupus.

Ans. *Induction*: Injection methylprednisolone 1 g IV daily for 3 days or oral prednisolone 1 mg/kg/day

JAYPEE BROTHERS

Plus

Oral mycophenolate mofetil (MMF) 1.0–1.5 g bid for 6 months

Or

Replace MMF with IV cyclophosphamide

Or

Replace MMF with oral cyclophosphamide 1–3 mg/kg/day for 3–6 months

Maintenance:

Low-dose prednisolone 5–10 mg/day or alternate day plus oral MMF 0.5–1 g bid

Or

Replace MMF with oral azathioprine 1–2 mg/kg/day

Q5. What is Eurolupus regimen?

Ans. Cyclophosphamide 500 mg IV every 2 weeks for six doses (total dose 3 g), then switching to azathioprine maintenance therapy (2 mg/kg/day). Less toxicity and less infection complication.

Q6. Treatment of type V c/d.

Ans. Treatment is same as class IV.

Q7. Transplantation in lupus patients.

Ans.

- Wait until 6–12 months on dialysis (lupus is not active).
- Many patients have burnt out disease by the time they reach end-stage renal disease (ESRD).
- Some patients rapidly develop irreversible renal failure and needs renal replacement therapy as well as aggressive treatment for active disease, but need to wait for 6–12 months before transplantation.
- Some patients with antiphospholipid syndrome require anticoagulation to prevent arteriovenous fistula or graft clotting.
- Cross matching of donors with lupus patients may be difficult because the sera may contain antilymphocyte antibody (false positive cross match).

Q8. What is the background drug in the treatment of LN?

Ans. Hydroxychloroquine.

Q9. What is remission in LN?

Ans. Reduction in proteinuria below 0.5 g/24 hours or urine protein creatinine ratio below 0.5 mg/mmol, absence of glomerular hematuria or red cell casts and normalization or stabilization of GFR.

JAYPEE BROTHERS

for detailed information on nephrology books, visit our website www.jaypeebrothers.com, for detailed information on nephrology books, visit our website

Cases in Nephrology

This book has been compiled for MD residents in Nephrology, fellowship examinees in Nephrology and internal medicine, postgraduate trainees in nephrology. Long cases are collected from grand rounds, long cases presented in different clinical meetings in the Department of Nephrology, Bangabandhu Shiekdh Mujib Medical University. About thirty cases have been presented, some are common cases and some are less common. There are limitations in investigations obviously due to resource and expertise limitations and poor compliance on behalf of the patients. Even then, I hope this book will be of some help for the postgraduate trainees in preparing themselves for their summative examination.



Muhammad Rafiqul Alam, born in 1958 in Chattogram district of Bangladesh; currently serving as professor of Nephrology, Bangabandhu Sheikh Mujib Medical University (BSMMU). He was the former chairmen of department of Nephrology and former Pro vice chancellor, Bangabandhu Sheikh Mujib Medical University. He obtained MBBS degree from Chittagong Medical College in 1982, FCPS (Medicine) under the auspicious of Bangladesh College of Physician and Surgeons in 1992 and MD (Nephrology) from Dhaka University in 1995.

He is the third son of Late Syedul Hoque and Late Rabeya Begum.

Dr Muhammad Rafiqul Alam is married with Ms Shahin Alam and they are blessed with two daughters, Dr Fariba Tabassum and Dr Parisa Tarannum.

Dr Muhammad Rafiqul Alam is the president of Bangladesh Renal Association, Vice President of Society of Organ Transplantation, Bangladesh, and President of Association of Physicians of Bangladesh. He is a fellow of the American Society of Nephrology. He is a member of ISN South Asia regional board. Dr Muhammad Rafiqul Alam is one of the editor of Bangladesh Renal Journal. He is the writer of the book "Kidney Niye Joto Kotha (Facts about Kidney)", "Manual of clinical Nephrology", "Synopsis of Nephrology" and contributors of chapters in different books. He has about 55 publications in reputed national and international journals. He attended many international congress, CME program, expert committee meeting and workshops.

He loves Tagore's song and enjoy reading books and travelling.

Printed in India

Available at all medical bookstores
or buy online at www.jaypeebrothers.com



JAYPEE BROTHERS
Medical Publishers (P) Ltd.
EMCA House, 23/23-B, Ansari Road,
Daryaganj, New Delhi - 110 002, INDIA
www.jaypeebrothers.com

Join us on facebook.com/JaypeeMedicalPublishers

Shelving Recommendation
NEPHROLOGY

ISBN 978-93-5465-957-7

