for detailed information on PGMEE books, visit our website www.jaypeebrothers.com, for detailed information on PGMEE books, visit our website www.jaypeebrothers.com, for detailed information on PGMEE books

Gold Standard Book for NEET PG Preparation

Includes full color image-based questions

3rd Edition

NEET/NEXT ESSENCE

A Must-buy Book for NEET-PG, INI-CET & FMG Exams

Updated from Harrison, Bailey and Love, Sabiston, Schwartz, Gray's, Ganong, Guyton, Goodman Gillman, Harper, Robbins, Katzung, Park, Nelson and latest editions of Premium Textbooks

COVID-19 Updates added

Authentic Questions with Finest Explanations Verified by Leading National Faculties

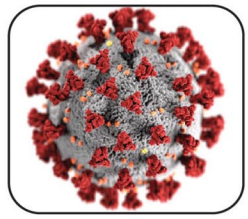

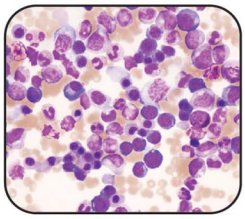



Pritesh Singh

JAYPEE

Contents

Coronavirus *xiii-xix*

1. NEET PG 2022 QUESTIONS **1-20**

Explanations *21-170*

2. NEET PG 2021 QUESTIONS **171-190**

Explanations *191-415*

3. NEET PG 2020 QUESTIONS **417-440**

Explanations *441-700*

4. NEET PG 2019 QUESTIONS **701-724**

Explanations *725-1010*

5. NEET PG 2018 QUESTIONS **1011-1034**

Explanations *1035-1317*

NEET PG 2022

Multiple Choice Questions

ANATOMY

1. Identify the structure in the given microscopic picture:

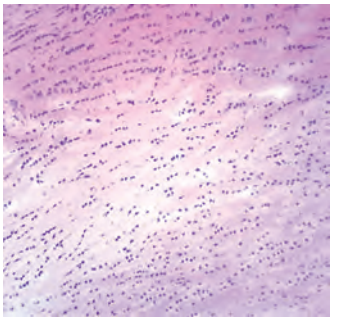

a. Articular cartilage
b. Non-articular hyaline cartilage
c. Fibrocartilage
d. Elastic cartilage

2. Identify the arrow marked structure in the given microscopic picture:

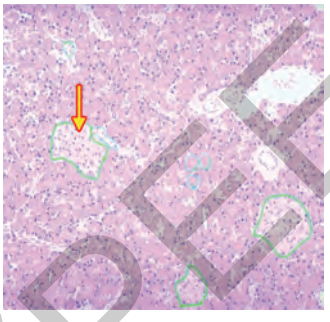

a. Glomerulus
b. Lymphatic nodule
c. Demilunes
d. Islet of Langerhans

3. Identify the image shown in the picture:

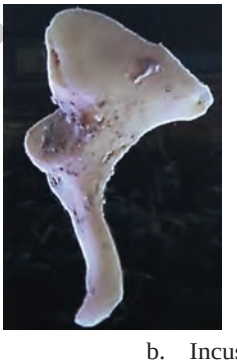

a. Malleus
b. Incus
c. Stapes
d. Vomer

4. A patient has presented with unilateral retro-orbital headache, photophobia and excessive tears. He also complains of hemifacial pain on clenching of teeth. On examination pupillary reaction is normal, light reflex and accommodation reflexes are present and normal. Which of the following marked structure is involved?

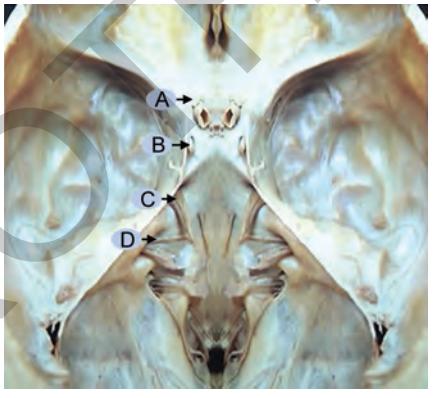

a. A
b. B
c. C
d. D

5. Which of the following ligament develop in the arrow marked structure?

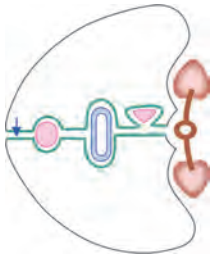

a. Falciform ligament
b. Gastrophrenic ligament
c. Gastrosplenic ligament
d. Lienorenal ligament

6. Which of the following is most common site for intraperitoneal abscess?

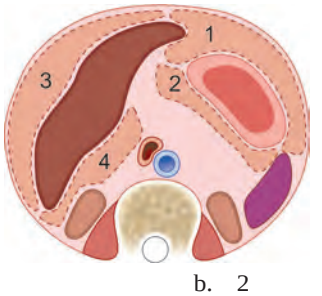

a. 1
b. 2
c. 3
d. 4

JAYPEE BROTHERS

7. Which of the following is most common site for intraperitoneal abscess in relation to liver?

a. Right subphrenic space b. Left subphrenic space
c. Right subhepatic space d. Left subhepatic space

PHYSIOLOGY

8. Which type of signalling is shown in the figure?

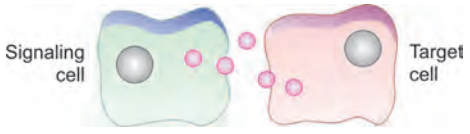

a. Autocrine b. Paracrine
c. Merocrine d. Endocrine

9. Which of the following will cause a decrease in extracellular K^+?

a. Lactic acid b. Epinephrine
c. Glucagon d. Atropine

10. Which of the following will be involved in baro-receptor reflex? *(NEETPG 2022, AIIMS May 2018)*

a. Negative feedback b. Positive feedback
c. Adaptive control d. Feed forward

11. Which of the following is true regarding the following diagram?

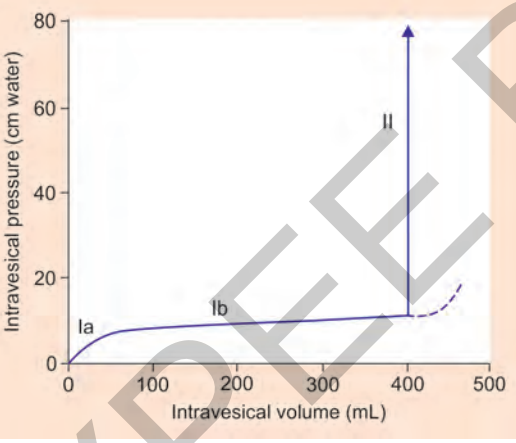

a. Dotted line indicates micturition has occurred
b. Segment 1a is a manifestation of Laplace law
c. Segment 1b is a manifestation of Laplace law
d. Micturition reflex is inhibited in phase II

12. A 35-years-old female was watching TV for long hours with hands under the head. She complaints of tingling sensation over the arm. Which type of nerve fibre is most likely to be affected? *(NEETPG 2022, 2020)*

a. Type A nerve fibers are more susceptible to pressure than type C nerve fibers
b. Type B nerve fibers are more susceptible to pressure than type A fibers
c. Type C fibers ore more susceptible to hypoxia than type A fibers
d. Type C fibers are more susceptible to pressure than type A fibers

13. The following diagram shows changes in hypothalamic set point and body temperature. What changes will be seen at point A as compared to point B?

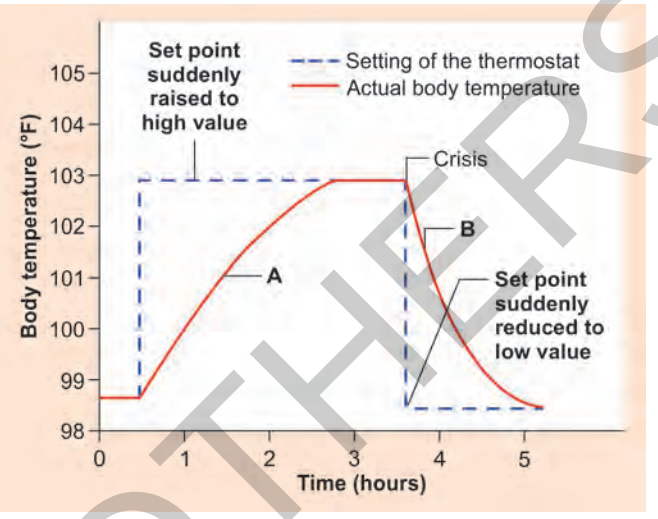

a. Shivering
b. Sweating
c. Shutdown of chemical thermoregulator
d. Cutaneous vasodilation

14. Which nucleus is involved in hemiballismus?

a. Globus pallidus b. Caudate nucleus
c. Substantia nigra d. Subthalamic nucleus

BIOCHEMISTRY

15. DNA packing is done by:

a. Histone b. Glycoprotein
c. Nucleic acid d. Helicases

16. A paint factory worker working since 20 years complains of joint pain, insomnia, fatigue, constipation and headache. He is found to have anemia. Enzyme affected is:

a. Uroporphyrinogen III synthase
b. Uroporphyrinogen I synthase
c. ALA synthase
d. Ferrochelatase

17. Complex IV inhibitor:

a. Cyanide b. Carbon dioxide
c. Oligomycin d. Antimycin

18. An alcoholic patient on anti-tubercular drugs for the past 3 months complains of numbness, tingling and burning sensation in all the extremities. What could be the vitamin deficiency?

a. Vitamin A b. Vitamin B_{12}
c. Vitamin B_1 d. Vitamin D

19. A woman on anti-depressants presents with bleeding. She gives a history of bulky stools which stick to the pan. Which of the following vitamin deficiency can cause bleeding in this condition?

a. Vitamin A b. Vitamin D
c. Vitamin E d. Vitamin K

JAYPEE BROTHERS

20. FAD status in body is determined by:
a. Thiamine
b. Glutathione reductase
c. Hexokinase
d. Transketolase

21. True about Warburg effect:
a. Makes cancer cells immortal
b. Aerobic glycolysis with lactate formation
c. Produces more ATP
d. Decrease glucose uptake

22. A Mediterranean person didn't receive primaquine. Which pathway is affected by G-6-PD enzyme deficiency?
a. HMP pathway
b. Glycolysis
c. Gluconeogenesis
d. Kreb's cycle

23. True about telomeres and telomerase is:
a. Increased telomere length with ageing
b. Gradually decreasing length of telomeres with ageing
c. Telomeres have coding sequences
d. Telomerase is found in somatic cells

24. When a codon is changed to a stop codon, then it is:
a. Stop codon mutation
b. Non-sense mutation
c. Missense mutation
d. Silent mutation

25. Fatty acid transport through mitochondrial membrane occurs via:
a. Carnitine
b. Acyl carrier protein
c. Cholesterol transporter
d. LCAT

PATHOLOGY

26. Which of the following will increase the life span?
a. Regular exercise (walking for 30 minutes)
b. Decreasing stress
c. Decrease calorie by 30%
d. Increase food intake

27. Which of the following has autosomal recessive pattern of inheritance?
a. Achondroplasia
b. Huntington's disease
c. Cystic fibrosis
d. Familial hypercholesterolemia

28. True about neutrophil extracellular trap (NET) are all *except*:
a. Seen in sepsis
b. Involves interaction between neutrophil and bacteria
c. Mitochondrial DNA is involved in the process
d. Chromatin concentrates antimicrobial enzymes

29. A case of microcytic hypochromic anemia was investigated. His red blood cell parameters include hemoglobin 9 g/dL, MCV 60 fL and RBC count of 5.2 million/mm^3. What will be your next step of investigation?
a. HbA_2
b. Serum ferritin
c. Serum folate
d. Red cell distribution width

30. An elderly male with dragging sensation in abdomen presents to the OPD. On laboratory investigation, total leucocyte count and platelet count was raised. His peripheral smear shows metamyelocytes, myelocytes, eosinophilia and basophilia. Which of the following is the likely genetic anomaly present in this individual?
a. t(9;22)
b. t(15;17)
c. t(8;14)
d. t(8;21)

31. A 40-year-old female presented with arthralgia, oral ulcer, skin rash and urinary complaints. Urine analysis revealed presence of red blood cells. What will be the probable diagnosis?
a. Post-streptococcal glomerulonephritis
b. Membranous glomerulopathy
c. Lupus nephritis
d. Minimal change disease

32. In a patient with raised LDH, elevated bilirubin and hemoglobinuria. Peripheral smear shows schistocytes. What would be likely diagnosis?

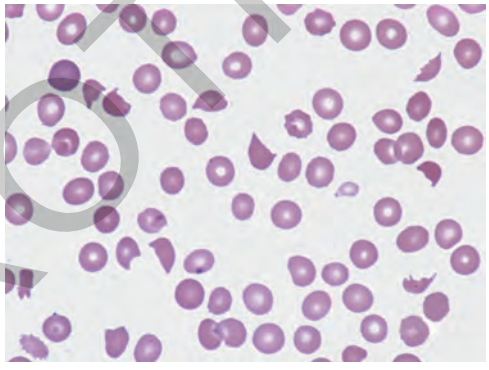

a. RBC enzyme defects
b. Hypersplenism
c. Mechanical heart valves
d. Thyroid dysfunction

33. The following histological image is seen in the patient who is complaining of growth failure and abdominal distension. Signs found were anemia. thrombocytopenia and bony pain. Which enzyme is deficient in this patient?
(NEETPG 2022, AIIMS May 2013)

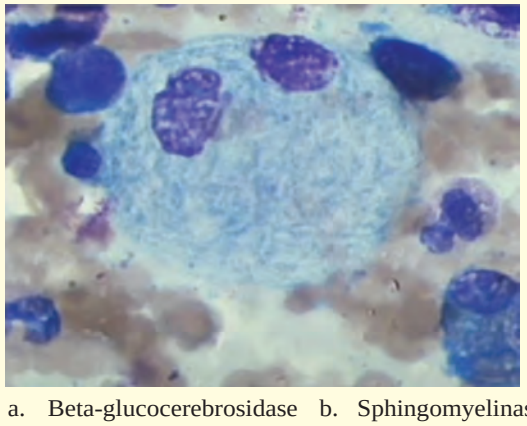

a. Beta-glucocerebrosidase
b. Sphingomyelinase
c. Hexosaminidase
d. Glu-6-phosphatase

34. Familial HNPCC is due to a defect in:
a. Nucleotide excision repair
b. Base excision repair
c. Point mutation
d. Mismatch repair

JAYPEE BROTHERS

35. A trauma patient was supposed to undergo emergency laparotomy. They wanted to monitor the coagulation studies. Which of the following is the investigation of choice?

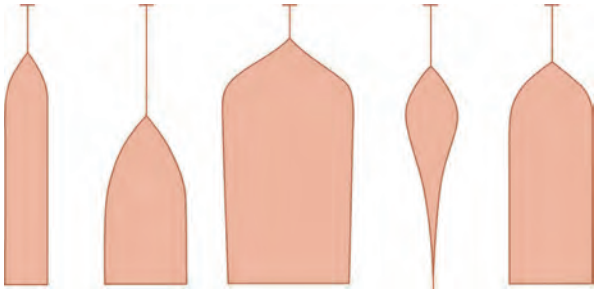

a. Elastography
b. Thromboelastography
c. Bleeding time
d. Clotting time

PHARMACOLOGY

36. Drug of choice in paracetamol overdose is:
a. N-acetylcysteine
b. Dopamine
c. Hydralazine
d. Furosemide

37. A young female presented with left sided severe throbbing headache associated with nausea, vomiting, photophobia and phonophobia. Which of the following drug can provide immediate relief to this patient?
a. Propranolol
b. Sumatriptan
c. Topiramate
d. Flunarizine

38. A patient on digoxin therapy accidently consumed 8 tablets of digoxin 0.25 mg. Two hours later, he presented to emergency with heart rate of 54 bpm and ECG evidence of third-degree AV block. What is the immediate management of this patient?
a. Digoxin immune Fab
b. Lignocaine
c. Phenytoin
d. DC cardioversion

39. An 82-year-old patient presented with acute episode of breathlessness. Chest X-ray shows pulmonary edema. History reveals that the patient has uncontrolled hypertension and is not taking the medication regularly. Which should be the management of this patient?
a. Intravenous nitroglycerine
b. Salbutamol nebulization
c. Intravenous salbutamol
d. Intravenous antibiotics plus oxygen

40. Which of the following hypolipidemic drug acts by inhibition of PCSK-9?
a. Atorvastatin
b. Evolocumab
c. Ezetimibe
d. Lomitapide

41. A patient with opioid poisoning presents with severe respiratory depression. What is the most effective drug for treatment of this patient?
a. Fomepizole
b. Naltrexone
c. Flumazenil
d. Naloxone

42. A patient presents with tremors, rigidity and bradykinesia. Which of the following drugs can be used for the treatment of this patient?
a. Selegiline
b. Donepezil
c. Fluoxetine
d. Haloperidol

43. An 11-year-old boy presented to emergency with vomiting. Parents gave history of consuming 10–15 tablets of ferrous sulphate a day before. What is the antidote of iron for treatment of this patient?
a. Dimercaprol
b. Desferrioxamine
c. d-Penicillamine
d. Activated charcoal

44. A deep vein thrombosis patient was started on an anticoagulant therapy. Next day, the patient presented with the features shown in the diagram below. Likely drug implicated for this adverse effect is:



a. Heparin
b. Rivaroxaban
c. Warfarin
d. Dabigatran

45. A patient with COPD was given intravenous aminophylline therapy following which the patient developed diuresis. This is due to action on which effector?
a. Adenosine receptors
b. Beta 2 adrenergic receptors
c. IL-10
d. Histone deacetylase

46. A female with ovarian cancer was on cisplatin therapy. He presented to hospital with several episodes of vomiting. After giving an antiemetic drug, the patient developed dystonia. The anti-emetic drug most likely to be responsible for these features is:
(NEETPG 2022, AIIMS May 2018)
a. Metoclopramide
b. Meclizine
c. Ondansetron
d. Scopolamine

47. A pregnant female with urinary tract infection took antimicrobials for the same. The baby of this female developed tendon rupture and arthropathy. What is the likely mechanism of action of the antimicrobial consumed by the pregnant female?
a. Folic acid synthesis inhibitor
b. Mycolic acid synthesis inhibitor
c. DNA gyrase inhibitor
d. DNA inhibitor

48. A known patient of Tuberculosis, on ATT for the past 3 months complains of numbness, tingling and burning sensation in all the extremities. What could be the vitamin deficiency?
(NEETPG 2022, AIIMS November 2017)
a. Vitamin B_3
b. Vitamin B_6
c. Vitamin B_1
d. Vitamin B_{12}

JAYPEE BROTHERS

49. In MDR tuberculosis, which of following drug combinations show resistance?
a. Rifampicin and Fluoroquinolones
b. Isoniazid and rifampicin
c. Isoniazid and Pyrazinamide
d. Rifampicin and kanamycin

50. Which of the following drugs have the least adverse effect on pleura?
a. Bromocriptine b. Metformin
c. Nitrofurantoin d. Methysergide

MICROBIOLOGY

51. A female patient presented with complaints of thick curdy white vaginal discharge. Microscopy of vaginal scrapings showed budding yeasts with pseudo hyphae. Which medium is used to identify the likely species?
a. Bird seed agar b. CHROMagar
c. SDA d. Brain heart infusion agar

52. A truck driver presents with sudden onset breathlessness. On examination, cervical lymphadenopathy and disseminated maculopapules were present. He was investigated and found to be HIV reactive. Biopsy of skin lesions was cultured at 28°C and showed a red velvety growth with red diffusible pigment on the under surface as shown in the image. Which of the following is the likely dimorphic fungus the patient is infected with?

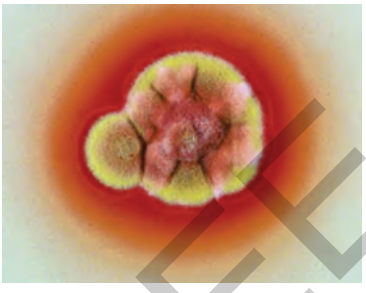

a. Pneumocystis carinii b. Talaromyces marneffei
c. Blastomyces d. Aspergillus versicolor

53. A woodworker from Himachal Pradesh presented with chronic localized infection of the skin on lower legs and feet which were irregular, rough, cauliflower-like lesions, microscopy of biopsy shows copper penny or medlar bodies. What is the etiological agent? *(NEETPG 2022; AIIMS November 2017)*

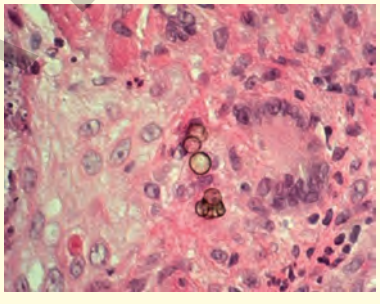

a. Chromoblastomycosis b. Pheohyphomycosis
c. Blastomycosis d. Sporotrichosis

54. A teacher recently joined a school in the village and few days later developed rice watery diarrhea. The causative agent acts on which of the following receptors to produce the actions?
a. GM-1 ganglioside
b. GM-2 ganglioside
c. GM-3 ganglioside receptor
d. GD-1 alpha ganglioside receptor

55. A patient was given intravenous botulinum toxin and the patient died. Mechanism of botulinum toxin overdose is:
a. Inhibits release of acetylcholine
b. Inhibit reuptake of nor-epinephrine
c. Blockade of post-synaptic nicotinic cholinergic receptors
d. Inhibit entry of acetylcholine in vesicle

56. A person with sepsis was admitted to the hospital and administered antibiotics for 10 days. He has now developed watery diarrhea and dehydration. Which of the following is the best investigation to diagnose *Clostridium difficile* infection?
a. Aerobic culture of stool
b. GDH and toxin assay of stool
c. GDH assay of stool
d. Stool microscopy

57. A woman with clinical history of diarrhea is on broad-spectrum antibiotic therapy. Which of the following is not true regarding *Clostridium difficile* infection?
a. It is toxin mediated
b. Oral fidaxomicin is used for the treatment
c. Can be confirmed by using IgM assay
d. Pseudomembranes consist of leukocytes, fibrin and cellular debris

58. A young boy presented with fever, sore throat, malaise and abdominal pain, conjunctival suffusion and calf tenderness. No history of cough, vomiting, hemorrhage and travel. What is the diagnosis?
a. Chikungunya
b. Leptospira
c. Dengue hemorrhagic fever
d. Hepatic encephalopathy with hepatitis A

59. A 26-year-old lady came to OPD with a case of anogenital warts. With the help of genetic study, it has come to their knowledge that she's having high risk of CA cervix. Which will be the most responsible?
a. HPV 5 b. HPV 18
c. HPV 11 d. HPV 1

60. A military soldier presents with fever, rash and myalgia. There is an absence of rash in palms and soles. History of louse infestation present in the same battalion. Causative organism is:
a. R. prowazekii
b. R. akari
c. R. typhi
d. R. conorii

JAYPEE BROTHERS

61. A patient presents with itchy macule on the axilla for the last few days. On taking skin scrapings, culture showed colonies that had red non-diffusible pigment on the under surface. LPCB stain showed septate branching hyphae with pencil shaped macroconidia and a few microconidia. Which of the following is the etiologic agent?

a. Trichophyton rubrum
b. Trichophyton violaceum
c. Trichophyton tonsurans
d. Trichophyton schoenleinii

62. A truck driver presents with cough and breathlessness. Chest X-ray showed right lower lobe pneumonia. Further investigation showed severe neutropenia. All bacterial cultures of sputum were negative. Lung biopsy histopathology showed dichotomous branching septate hyphae as shown in the image. What is the causative agent for the consolidation?

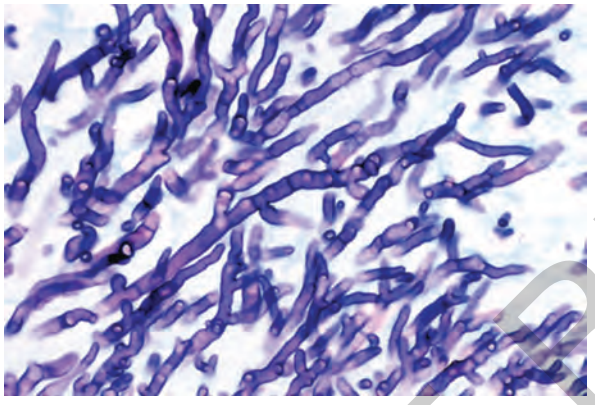

a. Rhizopus
b. Penicillium
c. Mucor
d. Aspergillus

63. A previously well 35-year-old man presented with high-grade fever, severe body aches, headaches, rigors and chills of 4 days duration. Dengue (IgM & NS1 antigen), malaria and blood cultures were negative. A chance peripheral blood smear examination showed larvae with 2 nuclei in the tail tip. What is the etiologic agents?

a. Wuchereria bancrofti
b. Brugia malayi
c. Loa Loa
d. Onchocerca volvulus

FORENSIC MEDICINE

64. A female has come to gynaecologist for hysterectomy. The doctor explains the benefits & risks of the procedure & obtained consent. The type of consent is:

a. Implied consent
b. Informed consent
c. Blanket consent
d. Emergency consent

65. A doctor who is drunk, while performing the surgery, injured a major vessel leading to the death of the patient. This is:

a. Civil negligence
b. Criminal negligence
c. Therapeutic misadventure
d. Dichotomy

66. A 45-year-old male came with acute loss of hair in head & madarosis. The wife had given history of behavioural changes. The doctor examined the nails & made the diagnosis. The condition is:

a. Arsenic poisoning
b. Thallium poisoning
c. Mercury poisoning
d. Lead poisoning

67. What type of hymen it is?

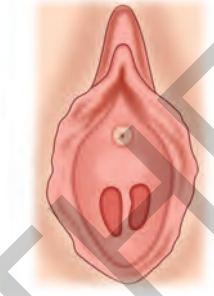

a. Septate
b. Fimbriate
c. Annular
d. Semilunar

68. The injury is suggestive of:



a. Postmortem wound
b. Self-inflicted cuts
c. Defense cuts
d. Hesitation cuts

69. A dead body is brought with ligature mark over neck, which is encircling the neck, transverse, below the thyroid cartilage. No salivary dribbling was noted. This condition is:

a. Throttling
b. Mugging
c. Ligature strangulation
d. Hanging

70. Identify the range:



a. Pistol near range
b. Rifle close range
c. Pistol close range
d. Shot gun intermediate range

71. In a court trial, leading questions are not permitted in all the following, *except*:

a. Re-examination
b. Cross examination
c. Dying declaration
d. Direct examination

JAYPEE BROTHERS

PSM

72. At an urban PHC, you are given 1 vial of pentavalent vaccine, and 2 vials of MR vaccine. Both were already open from before. Provided that all the cold chain requirements are still intact, will you use them or discard. Mark accordingly:

a. Use both pentavalent & MR open vials
b. Discard both pentavalent & MR open vials
c. Use pentavalent vial & discard MR vial
d. Use MR vial & discard pentavalent vial

73. Many children from a particular community coming to a hospital were detected as having ALL. The hospital said that it is due to a chemical in the water of that community. If a case control study has to be done to find whether that chemical and ALL are associated, children introduced to chemicals having ALL are taken as cases. Then what will be taken as controls?

a. Children in same community with ALL getting exposed to chemicals
b. Children in same community without ALL not getting exposed to chemicals
c. Children from hospital with ALL getting exposed to chemicals
d. Children from hospital without ALL not getting exposed to chemicals

74. For applied nutrition program, seeds and manure supply under School health services has been done by:

a. WHO b. UNICEF
c. CARE d. UNDP

75. For an Institutional delivery, ASHA worker motivated a woman in an Urban area of Madhya Pradesh. The ASHA worker and the Second gravida mother are given what amount (₹) under JSSK?

a. 1400 to mother and 1000 to ASHA
b. 1000 to mother and 400 to ASHA
c. 1400 to mother and 600 to ASHA
d. 700 to mother and 400 to ASHA

76. Broken glass vaccine vials at the vaccination center are supposed to be disposed in which container?

a. Yellow bag b. Red bag
c. Sharps container
d. Blue puncture proof container

77. Copper-T insertion is contraindicated in:

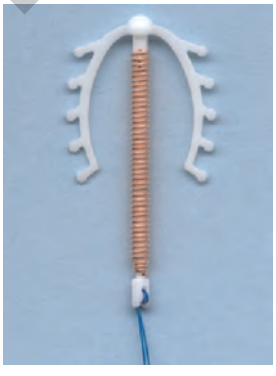

a. Menstruation
b. Broken condom
c. Trophoblastic disease
d. Post-partum immediately after delivery

78. Criteria for establishing Urban CHC to ensure facilities:

a. Where subdistrict or district hospital are not present
b. Referral centre for 2–3 urban primary health centers
c. For city with 1–1.5 lac population
d. 100 bedded in Metro cities

79. A Cohort study is undertaken to study association between Green tea intake and diabetes mellitus. Relative risk was found to be '0.85'. Which of the following is correct regarding association between green tea and DM?

a. Green tea consumption increases the risk of DM
b. Green tea consumption decreases the risk of DM
c. Green tea consumption has no effect on the risk of DM
d. Cannot be determined

80. Correct about additional nutritional caloric in pregnancy is:

a. 300 kcal throughout pregnancy
b. 400 kcal in second trimester
c. 400 kcal in third trimester
d. 200 kcal in second trimester

81. WHO STEP wise approach include all, *except*:

a. Physical b. Psychological
c. Behavioural d. Therapeutic

82. A photographer who recently returned from Egypt, presents with abdominal pain, hepatomegaly, hemorrhagic manifestations and renal dysfunction. He was given treatment, however, he deteriorated. On autopsy, hepatocytes shows intranuclear Torres bodies. Which of the following vaccines could have prevented his death?

a. 17D vaccine
b. Nakayama strain
c. Ra 27/3 strain
d. Jeryl Lynn strain

83. A child presented with manifestations of Streptococcal infection but no carditis. What will you suggest for secondary prevention?

a. Single dose of Inj. benzathine penicillin
b. Lifelong benzathine penicillin 3 weekly once
c. 3 weekly benzathine penicillin injection for 5 years or till 18 years whichever is later
d. 3 weekly benzathine penicillin injection for 5 years or till 25 years whichever is later

84. A patient having cough 3 weeks was started on ATT under NTEP. Intensive phase and continuation phase were completed and then he tested smear negative for AFB on two samples. What is the status of patient?

a. Treatment completed b. Cured
c. Improper follow-up d. Failure

JAYPEE BROTHERS

85. Most logical and cost effective approach of controlling rabies in urban population:

a. Test all the dogs for rabies
b. Remove stray dogs and vaccinate the dog population
c. Administer rabies vaccine to the entire human populations
d. Health education of people

86. A 24-year-old female with 18 months baby on breast feeding has heavy irregular bleeding on mensuration. What is best contraception advisable?

a. Mala N
b. Progestasert
c. CuT 380A
d. Depot formulation

87. Things you will not do as a medical officer of PHC when posted in seismic areas:

a. Ensure funds and resources are available and can be mobilized at the time of disaster for quick evacuation
b. Preparedness to handle emergency
c. Disaster simulation practices and then check the response
d. Follow the announcements given on loudspeakers

88. Life span of Japanese women is 84.3 years. As Japanese have longest life expectancy, their life expectancy statistics are used as a standard for measuring premature death in:

a. HALE
b. QALY
c. DFLE
d. DALY

MEDICINE

89. A 35-year-old patient reported suffering with malaise and fatigue since last 2 months. On laboratory examination, his serum parameters depicted HBsAg+ with IgM core antibody +. Diagnosis is:

a. Chronic hepatitis B
b. Chronic hepatitis C
c. Acute hepatitis B
d. Acute hepatitis C

90. A person manifested with fever, headache, vomiting and neck rigidity. CSF specimen of patient is shown below. Report shows mononuclear cytosis with moderately low sugar with elevated protein values. Which of the following is the likely etiology?

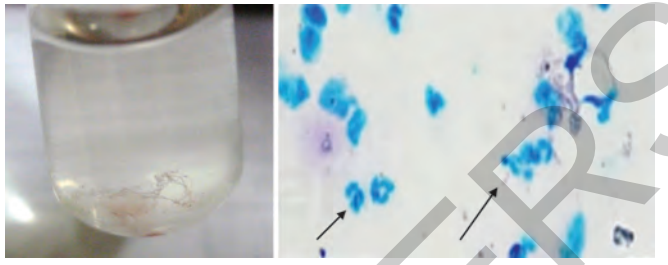

a. Pyogenic meningitis
b. Aseptic meningitis
c. Viral meningitis
d. Tubercular meningitis

91. A 50-year-old male, known case of chronic liver disease with ascites presents with abdominal pain and tenderness. Ascitic tap shows presence of 600 PMN cells/mm^3. Which of the following is the likely etiology?



a. Tubercular ascites
b. Malignant ascites
c. Spontaneous bacterial peritonitis
d. Chylous ascites

92. An adult patient complains of palpitations and presents with irregularly irregular pulse. Pulse deficit is 20, HR = 120/min, BP = 110/70 mm Hg. Which of the following will be found in the patient?

a. Absent 'a' wave
b. Canon 'a' wave
c. Absent 'y' wave
d. Prominent 'v' wave

93. A 74-year-old patient with CAD presents with palpitations. ECG is shown below. BP = 120/84 mm Hg. Which of the following shall be the best treatment for this patient?



a. Oral metoprolol
b. IV metoprolol
c. IV amiodarone
d. Oral amiodarone

JAYPEE BROTHERS

94. A 25-year-old patient with dental caries is undergoing dental extraction. Which of the following does not need prophylaxis for endocarditis?
a. Previous history of endocarditis
b. Artificial heart valve
c. Untreated cyanotic heart disease
d. ASD

95. A 40-year-old diabetic female presented to emergency with abdominal pain, vomiting and recent onset confusion. On examination, she had irregular breathing and dehydration. Her blood sugar is 539 mg/dL and there was presence of ketone bodies in the urine. Blood pressure of the patient is 80/50 mm Hg. What is the next best step in the management of this patient?
a. Regular insulin
b. Intravenous fluids
c. Intravenous fluids with regular insulin
d. Long acting insulin

96. A female patient with poorly controlled diabetes is brought to the emergency with complains of fever, cough and difficulty in breathing. She is diagnosed to be suffering with severe COVID-19 infection. Due to persistently low oxygen saturation, she was started on high-dose steroids. She started complaining of facial pain and loosening of teeth 5 days later. Which of the following tests need to be done on priority basis?
a. HBA1C
b. Ferritin
c. Nasal swab for mucor
d. MRI head

97. A patient presents with pituitary tumor that overproduces growth hormone. Surgical removal of the tumor was incomplete. What is the first line of treatment?
a. Nafarelin
b. Octreotide
c. Leuprolide
d. Goserelin

98. A 40-year-old male presents with protrusion of chin, excessive sweating, impaired glucose tolerance and enlargement of hands and feet? Which of the following drugs is a growth hormone receptor antagonist used to treat this condition?
a. Pegvisomant
b. Octreotide
c. Cabergoline
d. Olcegepant

99. A 45-year-old female presented with galactorrhea. Her urine pregnancy test was negative. MRI brain revealed a large pituitary tumor. Patient refused to undergo surgery for the tumor. Which of the following is the best drug for the treatment of this patient?
a. Bromocriptine
b. Leuprolide
c. Degarelix
d. Cetrorelix

100. An old age smoker presents with respiratory difficulty. ABG report: Ph = 7.2, pO_2 = 75 mm Hg, pCO_2 = 84 mm Hg, HCO_3 = 35 mEq. Diagnosis:
a. Respiratory acidosis
b. Respiratory alkalosis
c. Metabolic acidosis
d. Metabolic alkalosis

101. Which of the following electrolyte imbalance will produce ECG findings of ST depression and U waves?
a. Hyperkalemia
b. Hypokalemia
c. Hypocalcemia
d. Hypercalcemia

102. A patient on anti-depressant therapy presents with elevated body temperature, dilated pupil, palpitations and low blood pressure. ECG shows tachycardia, broad QRS complex and right axis deviation. Which of the following interventions must be done immediately? *(NEETPG 2022, AIIMS November 2015)*
a. Hemodialysis
b. Intravenous sodium bicarbonate
c. Intravenous esmolol
d. DC cardioversion

103. A 10-year-old child had abdominal pain with melena. On examination, palpable purpura is found on calves and buttocks. Which drug will be used?
a. Azathioprine
b. Methotrexate
c. Corticosteroids
d. Cyclosporine

104. An obese woman came to OPD with dark patches on the neck. What could be the diagnosis?



a. Metabolic syndrome
b. Hypothyroidism
c. Hypoparathyroidism
d. Addison disease

105. Which fluid is shown below?

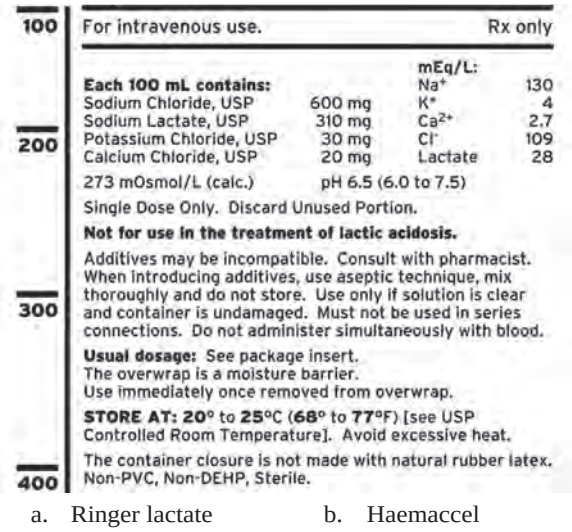

a. Ringer lactate
b. Haemaccel
c. Isolyte – P
d. Isolyte – M

JAYPEE BROTHERS

106. A child presents with epigastric pain, vomiting for past 10 days with oliguria and features of dehydration. Peripheral smear shows presence of lymphoblasts. On laboratory investigations, serum creatinine and K+ levels were elevated. What will be immediate management?

a. Hydration
b. Send for USG
c. Probenecid
d. Urgent chemotherapy

107. Laboratory investigations of a patient being evaluated for jaundice show elevated bilirubin and alkaline phosphatase levels. Levels of the remaining liver enzymes are normal. What is the likely diagnosis?

a. Obstructive jaundice
b. Hemolytic jaundice
c. Hepatic jaundice
d. Prehepatic jaundice

SURGERY

108. A 35-year-old female presented to OPD. Physical examination findings are given in the image. Which structure is affected in this condition? *(NEETPG 2022; AIIMS November 2015)*



a. Involvement of chest wall
b. Involvement of subdermal lymphatics
c. Involvement of Cooper's ligaments
d. Involvement of connective tissue

109. A young male presented with slow growing midline swelling in anterior part of neck. After 6 months, bilateral cervical lymphadenopathy developed. Histopathology slide is given below. All of the following are correct about this condition, *except*:

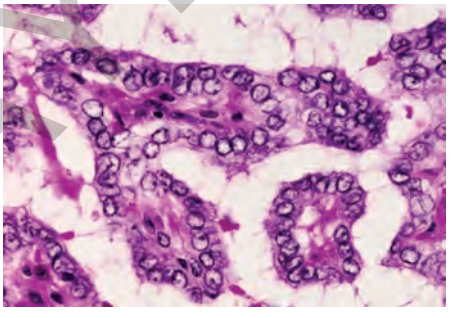

a. Lymphatic spread is seen
b. Specific nuclear pattern on histology
c. Has excellent prognosis
d. FNAC is not diagnostic

110. A 45-year-old female underwent thyroidectomy. On 3rd day, she developed peri-oral numbness. Further investigation involves:

a. Free T3, T4
b. Calcium, phosphate and PTH levels
c. RAI scan
d. T3, T4, TSH

111. All of the following are the components of MEN-2b, *except*:

a. Parathyroid adenoma
b. Megacolon
c. Marfanoid habitus
d. Mucosal neuroma

112. A 35-year-old patient presented with severe abdominal pain and vomiting. His vitals are stable. The radiograph is given below. What is the most effective way to treat this patient? *(NEETPG 2022, 2019)*

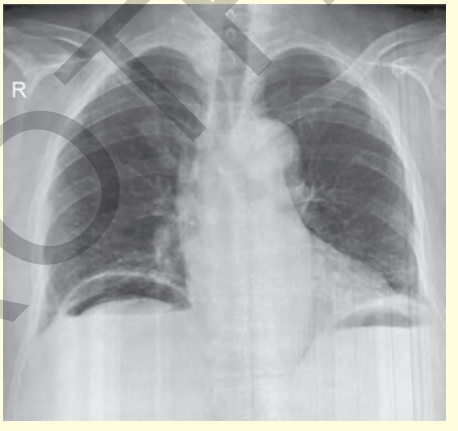

a. Gastric lavage with cold saline
b. Tracheostomy
c. Chest tube insertion
d. Resuscitation and laparotomy

113. An 11-month-old boy was brought to emergency with pain abdomen and multiple episodes of vomiting. On examination, mass was palpable in right lumbar region. Barium enema image is given below. What is the diagnosis?



a. Intussusception
b. Volvulus
c. Malrotation
d. Duodenal atresia

JAYPEE BROTHERS

114. A patient with long standing hemorrhoids came to the hospital for the routine check-up. On blood investigations, Hb was 7 g/dL. On peripheral blood smear following findings are seen. What is the most likely diagnosis?

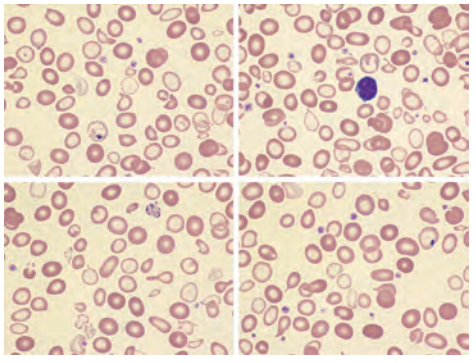

a. Iron deficiency anemia
b. Sideroblastic anemia
c. Megaloblastic anemia
d. Hemolytic anemia

115. A 30-year-old male presented with recurrent painful perianal nodules on buttocks with serous discharge. The image is given below. What is the most probable diagnosis?



a. Perianal boils
b. Carbuncle
c. Fistula-in-ano
d. Pilonidal sinus

116. A delayed intravenous urogram of the patient is shown below. What is the most likely diagnosis?



a. Putty kidney
b. Staghorn calculus
c. Pelviureteric junction obstruction
d. Renal cyst

117. A 6-year-old child presented with recurrent UTI. Micturating cystourethrogram image of the patient is given below. What is the most likely diagnosis?

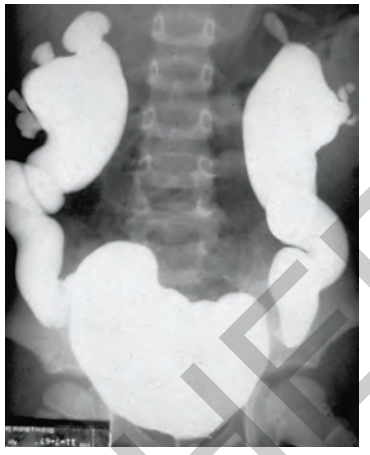

a. Vesicoureteric reflux
b. Vesicocolic fistula
c. Urinary bladder hernia
d. Urinary bladder diverticula

118. Identify the congenital anomaly shown in the newborn baby: *(NEETPG 2022, AIIMS May 2018)*



a. Omphalocele
b. Gastroschisis
c. Persistent vitellointestinal duct
d. Bladder exstrophy

119. A middle aged patient presented with fever and repeated episodes of cystitis. Patient underwent cystoscopy, which showed multiple yellow white plaque in the bladder. The histopathological examination shows infiltrated lamina propria layer as shown below. What is the diagnosis?

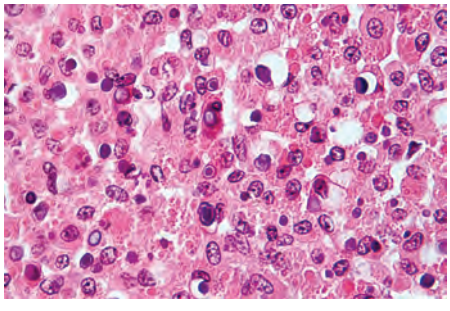

a. Malakoplakia
b. Interstitial cystitis
c. Acute cystitis
d. Chronic cystitis

JAYPEE BROTHERS

120. Route of metastasis of prostate cancer to lumbar vertebrae:

a. Transcoelomic spread b. Lymphatics
c. Prostatic venous plexus d. Inferior vesical vein

121. A 30-year-old patient with motor vehicle accident presented to the causality. His vitals are stable but he is unable to pass urine. He has blood at the tip of meatus. An RGU was performed as shown below. What is the most likely site of urethral injury?



a. Membranous urethra b. Penile urethra
c. Bulbar urethra d. Spongy urethra

122. A 55-year-old patient presented to emergency with scrotal swelling, ecchymosis, fever and serous discharge. Image is given below. What is the most probable diagnosis?



a. Fournier's gangrene b. Epididymo-orchitis
c. Torsion testis d. Carcinoma testis

123. A 30-year-old male was being investigated for infertility. Semen analysis shows azoospermia. Biopsy image is given below. What is the most probable diagnosis?

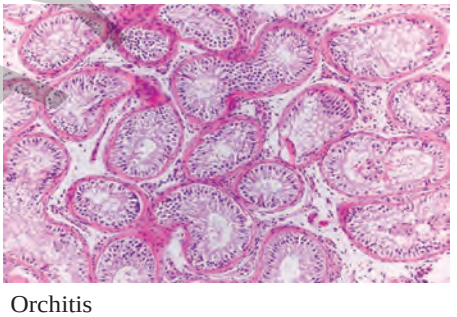

a. Orchitis
b. Sertoli cell only syndrome
c. Testicular tumor
d. Non-seminomatous germ cell tumor

124. A patient presented to emergency with claudication of calf muscles, numbness in thigh with impotence. Image showing gangrene of foot is given below. Which artery is involved?



a. Aortic-iliac bifurcation
b. Internal iliac artery
c. Bilateral popliteal artery
d. Femoral artery

125. Following surgery for varicose veins, patient started complaining of numbness along the medial aspect of leg. Which nerve is most commonly affected?

a. Superficial peroneal b. Deep peroneal
c. Saphenous nerve d. Sural nerve

126. A 25-year-old patient presents with multiple injuries due to RTA. 2 days later in the hospital he developed dyspnea with petechial rash and altered sensorium. Which of the following is the cause? *(NEETPG 2022, 2020, AIIMS May 2017)*

a. Massive hemorrhage b. Fat embolism
c. Thromboembolism d. Air embolism

127. A 30-year-old patient presented to the casualty after a motor vehicle accident. He has bruises on the chest. His pulse is 120 beats per minute. BP is 90/60 mm Hg and respiratory rate is 40/minute. A chest X-ray was performed and shown below. What is the next most appropriate step in the management of this patient?

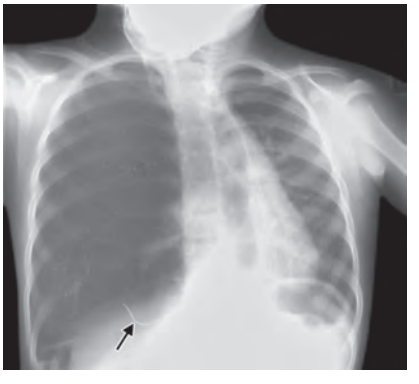

a. Immediate thoracotomy
b. Pericardiocentesis
c. Pleurodesis
d. Chest drain insertion and drainage

JAYPEE BROTHERS

128. **A 9-year-old child was brought to the hospital after burns. There was involvement of half of chest wall and abdomen towards left side, posterior arm and thigh. Calculate the burnt surface area:**

a. 5–10%
b. 15–20%
c. 25–30%
d. 35–40%

129. **A 65-year-old patient presented with gradually increasing growth besides the nose near the medial canthus with ulceration. Histopathology image is shown below. What is the most likely diagnosis?**

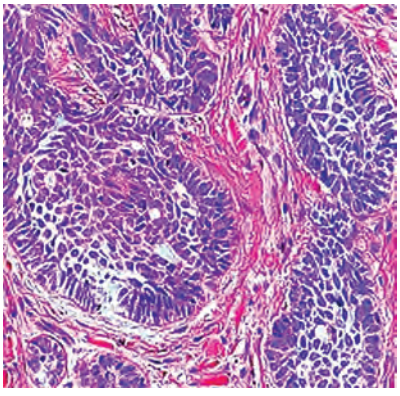

a. BCC
b. SCC
c. Melanoma
d. Nevus

130. **A 73-year-old male was bed ridden for 15 years. The image of bed sore is given below. What is the grade of bed sore?** *(NEETPG 2022, AIIMS November 2019)*



a. Grade I
b. Grade II
c. Grade III
d. Grade IV

131. **A patient with history of chronic alcoholism presented to OPD with whitish patch, whose image is given below. What is the most probable diagnosis?**

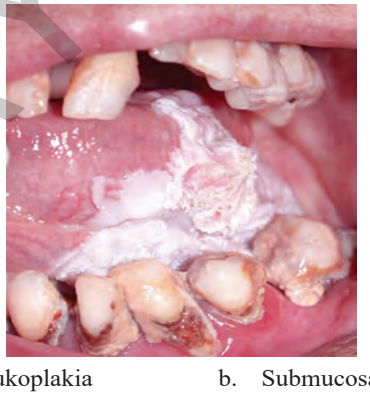

a. Leukoplakia
b. Submucosal fibrosis
c. Erythroplakia
d. Malakoplakia

132. **A 45-year-old patient complaints of recurrent swelling in one side of the neck. She is afraid of eating food as it worsens the swelling. Imaging was performed and shown below. What is the most likely diagnosis?**



a. Sialolithiasis
b. Penetrating irregular foreign body
c. Isolated osteoma of floor of mouth
d. Submandibular duct abscess

133. **A patient came with swelling under the ear lobe as shown below in the image. The swelling was non-tender & firm. What is the most likely diagnosis?** *(NEETPG 2022, 2019)*



a. Bezold abscess
b. Parotid gland swelling
c. Osteoid osteoma
d. Deep cervical lymph node enlargement

134. **A Patient came to OPD with erythematous (red) neck swelling near clavicle as shown below, which is tender and pulsatile. What will be the next best step?**



a. Needle biopsy
b. USG doppler neck
c. CT angiography with percutaneous intervention
d. Oral antibiotics for 7 days

JAYPEE BROTHERS

135. Which of the following is most likely to be seen due to rupture of saccular aneurysm in brain?

a. Subdural hemorrhage b. Subarachnoid hemorrhage
c. Hydrocephalus d. Intracerebral hemorrhage

136. A patient with stab injury was brought to the emergency. Vitals were stable. Image is given below. What is next best step of management?



a. Further investigation
b. IV fluids
c. Wait and watch after dressing
d. Exploratory laparotomy

137. Green color in triage signifies:

a. Dead patients b. High priority patients
c. Ambulatory patients d. Moderate priority patients

OBSTETRICS & GYNAECOLOGY

138. A 30-year-old woman comes with history of primary infertility of 2 years, hysterosalpingography is done and the findings are as shown in the image. The cause of her infertility is which of the following?

(NEETPG 2022, 2018)



a. Unicornuate uterus b. Arcuate uterus
c. Septate uterus d. Uterus didelphys

139. A primigravida is brought home by her relatives just after 1 hour of a vaginal delivery of a full-term healthy infant. The baby is doing well. On examination, the patient is hypotensive, hypoxic, and has disseminated intravascular coagulation. Which of the following is the most likely cause?

a. Postpartum hemorrhage
b. Postpartum cardiomyopathy
c. Rupture of uterus
d. Amniotic fluid embolism

140. Identify the area marked in green:

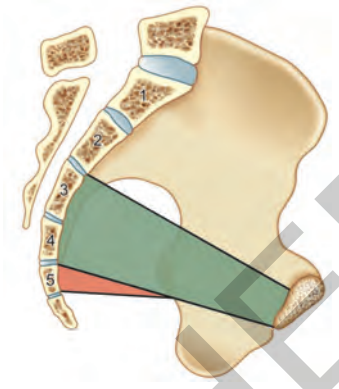

a. Pelvic outlet b. Anatomical outlet
c. Midpelvis d. Obstetric outlet

141. A pregnant patient, with a history of classical cesarean section in view of fetal growth retardation in the previous pregnancy presents to you. She is currently at 35 weeks of gestation with breech presentation. What is the next step in management?

a. External cephalic version at 36 weeks
b. Plan cesarean section at 37 weeks
c. Repeat USG after a week and decide
d. Internal podalic version followed by vaginal delivery

142. A primigravida presented to the emergency room in the early stage of labor with adequate uterine contractions. On per vaginal examination, a gynecoid pelvis is felt, the membranes are ruptured and the vertex is felt in the right occipitoposterior position. How will you manage this patient?

a. Vacuum assisted delivery b. Cesarean section
c. Normal vaginal delivery d. Forceps delivery

143. While conducting a delivery, you perform the maneuver shown below. Following this, there is incomplete separation of the placenta and massive hemorrhage. What is the nest best step in management?



a. Uterine massage b. Injection oxytocin
c. Manual removal
d. Arrange blood and remove placenta via Crede's method

144. A woman with an obstetric score of G2P1 comes to the clinic at 14 weeks of gestation for her antenatal check-up. A uterine artery doppler was suggested by the doctor. What would it detect?

a. Late onset preeclampsia
b. Early onset preeclampsia
c. IUGR d. Placenta accreta

JAYPEE BROTHERS

145. A 25-year-old female with history of 2 weeks amenorrhea came in emergency department with complaints of scanty vaginal bleeding. On examination, no adnexal mass noted. On lab investigation, hCG was 1,400 mIU/mL. On USG, uterus was bulky, trilaminar endometrium was seen. Patient vitals were stable. What is the next step to do?
a. Repeat hCG after 48 hours
b. Measurement of progesterone
c. Laparoscopy
d. Repeat ultrasound after 3 days

146. What will be the level of the uterus on postpartum day 2?
a. Two fingers below umbilicus
b. Four fingers below umbilicus
c. Just above symphysis pubis
d. At the level of umbilicus

147. A primigravida at 22 weeks of gestation presents to you with profuse vaginal bleeding. Her blood pressure and glucose levels are within normal limits. Placental implantation at which of the following site can cause this?
a. Internal os
b. Ovary
c. Tube
d. Abdominal

148. You are examining a multigravida in the second stage of labor for the past 2 hours. On examination, contractions are adequate, the cervix is dilated with the head at station 0 with moulding 2+ and caput 2+. The sagittal suture is in the right occipitotransverse position. The fetal heart rate is 140/minute. Which of the following is carried out for the management of this patient?
a. Vacuum assisted delivery
b. Midpelvic forceps
c. Lower segment cesarean section
d. Wait for an hour for spontaneous labour

149. A type 1 diabetic mother is on magnesium sulfate infusion post-cesarean section for preeclampsia. She develops delirium and is drowsy. She has a respiratory rate of 10/min, random blood glucose level of 240 mg/dL, oliguria and bilaterally absent patellar reflex. What is the cause of her condition?
a. Diabetic ketoacidosis
b. Diabetes insipidus
c. $MgSO_4$ toxicity
d. Eclampsia

150. A 40-year-old G2P1 woman with 18 weeks of amenorrhea comes with a dilated cervix. The cervical length is 15 mm. In spite of explaining the risks, she insisted on cerclage. Which of the following is a contraindication for cerclage operation?
a. Rupture of membrane
b. Prolapse of membrane into vagina
c. Fetal fibronectin positive
d. Advanced maternal age

151. A pregnant lady at 32 weeks of gestation with no other comorbid conditions developed eclampsia. She enquires about the cause of her condition. Doctor explained that it is due to the failure of invasion of:
a. Spiral artery by villous trophoblast
b. Radial artery by cytotrophoblast
c. Spiral artery by extravillous trophoblast
d. Arcuate artery by extravillous trophoblast

152. A pregnant lady with 34 weeks of amenorrhea has the following findings: LDH: 700 IU/L, platelets: 75,000/mm^3, serum bilirubin: 1.5 mg/dL, SGOT-200 U/L, SGPT-150 U/L, and BP: 140/96 mm Hg. Her coagulation profile and renal function tests are normal. What is the diagnosis?
a. HELLP syndrome
b. Acute fatty liver of pregnancy
c. Viral hepatitis
d. Intrahepatic cholestasis

153. A primigravida presents to the labour room at 40 weeks of gestation with lower abdominal pain. She has in labour for 3 hours. Which of the following will determine if she is in active labour?
a. Fetal head 5/5 palpable on abdominal examination
b. Two contractions lasting for 10 seconds in 10 minutes
c. More than 5 cm cervical dilatation with complete effacement
d. Rupture of membranes

154. While discharging a patient, who underwent a vesicovaginal fistula repair, which of the following would you recommend?
a. Sexual abstinence for 3 months and avoid pregnancy for a year
b. Sexual abstinence for 3 months and avoid pregnancy for 6 months
c. Sexual abstinence for 6 months and avoid pregnancy for a year
d. Sexual abstinence for 6 months and avoid pregnancy for 6 months

155. Testosterone helps in the development of various organs in the fetus. Which of the following is the first stimulus for its production?
a. LH from maternal pituitary
b. hCG from placenta
c. Inhibin from corpus luteum
d. GnRH from fetal hypothalamus

156. A 20-year-old woman presented at 7 weeks of gestation, unwilling to continue the pregnancy. What are the drugs used for medical termination of pregnancy in this patient?
a. Misoprostol and medroxyprogesterone
b. Misoprostol and mifepristone
c. Mifepristone and methotrexate
d. Mifepristone and medroxyprogesterone

157. A woman at 26 weeks of gestation presents for routine evaluation. On examination, fundal height corresponds to 24 weeks. Ultrasonography revealed decreased amniotic fluid. Which of the following conditions would have led to this presentation? *(NEETPG 2022, 2020)*
a. Renal agenesis
b. Cardiac abnormalities
c. Tracheoesophageal fistula
d. Ureteral stricture

PAEDIATRICS

158. A child born by normal vaginal delivery developed repeated attacks of flexion of neck over the trunk and jerks in the hands. EEG shows the presence of hypsarrhythmia. Anti-epileptic drug of choice for this patient is:
a. Phenobarbitone
b. Phenytoin
c. ACTH
d. Levetiracetam

JAYPEE BROTHERS

159. A mother reported that her baby did not pass urine on post-natal day 1. What will be the next step?
a. Start IV hydration
b. Shift to NICU and investigate
c. Continue breastfeeding and observe
d. Start formula milk

160. Regarding high-risk infants, which of the following are correct?
1. Weight 2.5 kg
2. Birth order >3
3. Single parent
4. Artificial feeding
5. Birth weight <85 percentile

a. 3 and 4
b. 1 and 2
c. 1, 2 and 3
d. 2, 3 and 5

161. Prenatal USG in a 35-year-old female showed a fetus with multiple fractures. What is the most likely diagnosis?
a. Achondroplasia
b. Osteogenesis imperfecta
c. Marfan syndrome
d. Cretinism

162. A child with exercise fatigue presented to OPD. The features were suggestive of McArdle disease. Which of the following enzyme will be deficient in this?
a. Myophosphorylase
b. Glucose 6-phosphatase
c. Lysosomal glucosidase
d. Phosphofructokinase

163. A 4-month-old child of an HIV positive mother presents with recurrent diarrhea. What will be your next investigation?
a. HIV antibody in neonate
b. GDH
c. Stool microscopy
d. HIV RNA PCR to determine viral load

164. A 6-year-old male child presents with complaints of pain in extremities and was admitted. He had episodes of chest infection and severe abdominal pain in the past too. HPLC shows increased HbF and HbA_2 and a spike were seen in the S window. What is the diagnosis?
a. Beta-thalassemia
b. Autoimmune hemolytic anemia
c. Sickle cell anemia
d. Anemia of chronic disease

165. A neonate was found to have TSH > 100 mU/L on day 4 of life. USG shows eutopic thyroid gland. What should be the next investigation?
a. Urinary iodine concentration
b. Thyroid receptor antibody levels
c. Thyroid nuclear scan
d. T3 and T4 levels

166. A 12-year-old male presents with bloating, recurrent loose stools and steatorrhea. His HLA DQ2 was positive. What should be the best management?
a. Low fat diet
b. High protein diet
c. Gluten free diet
d. Low calorie diet

167. A child presented to OPD with multiple episodes of loose stools and repeated vomiting. He was lethargic and not able to drink breast milk. Skin pinch was going back very slowly. Which grade of dehydration the child has?
a. Mild
b. Moderate
c. Severe
d. None of the above

168. A 2-year-old, pre-morbidly normal, well thriving child presented with sudden onset breathing difficulty while playing. Chest X-ray of this child shows right sided hyperinflation with normal left lung. Which of the following statements is true regarding this case?
a. The child has developed acute laryngotracheobronchitis
b. Focal area of decreased air entry will be suggestive of foreign body
c. In complete obstruction, ball valve mechanism leads to such condition
d. Flexible bronchoscopic removal is the management of choice

169. A 10-year-old boy presents with facial puffiness and generalized edema. He was diagnosed as a case of minimal change disease. Which of the following is true about this condition?
a. Light microscopy shows effacement of podocytes
b. Good response to steroids
c. More common in adults
d. Non-selective proteinuria

ORTHOPAEDICS

170. Most common complication of untreated radial head dislocation:
a. Cubitus varus
b. Cubitus valgus
c. Damage to ulnar nerve
d. Myositis ossificans

171. A patient presented with multiple swelling in hand and wrist. Finger X-ray is given. What is the diagnosis?



a. Multiple enchondromas
b. Multiple brown tumour
c. Multiple osteophytic growth
d. Multiple osteoma

172. Which will be the ideal treatment for fibular fracture?
a. Analgesic → Closed reduction → Cast
b. Neurological assessment → Analgesic
c. Neurological testing → CRIF
d. Neurological assessment → Analgesic→ Cast

JAYPEE BROTHERS

for detailed information on PGMEE books, visit our website www.jaypeebrothers.com, for detailed information on PGMEE books, visit our website www.jaypeebrothers.com, for detailed information on PGMEE books, visit o

NEET/NEXT ESSENCE

Salient Features

- Authentic questions with exact language and options including all image-based questions
- Fully coloured, thoroughly revised, updated from 20th edition of Harrison, 27th edition of Bailey & Love, 10th edition of Robbins, 13th edition of Goodman Gillman, 11th edition of Schwartz, 21th edition of Sabiston, 41st edition of Gray's Anatomy, 26th edition of Park, 30th edition of Harper, 25th edition of Ganong
- Thoroughly verified answers from subject specialist, faculty members of Dr Pritesh Institute and PG aspirants
- Explanations in tabulated form
- Explanations incorporating only high yielding and relevant facts
- Highlighted important, golden facts and previously asked questions
- Controversial questions and image-based questions are handled with special care to clear the concept
- Explanations from latest editions of standard and most authentic textbooks
- Line diagrams to minimise tedious efforts
- Mnemonics for faster learning

Ambition is the first step towards success, the second is action. The action should be smart enough that can make you reach your goal. This book can help you achieve your dreams as the preparation is lacking if you don't know the correct answers to previous year's papers. NEET Essence is an attempt to provide you with the authentic questions and accurate answers with appropriate explanation of the topics asked. The confidence you gain from knowing the repeat questions will surely get you ahead in the race. The book has been updated from the most recent editions of Robbins, Harrison, Goodman Gillman, Schwartz, Sabiston, Gray's Anatomy, Park, Harper and Ganong. The answers have been meticulously revised by the subject specialists, faculty members of Dr Pritesh Institute as well as PG aspirants. Explanations incorporate high yielding and relevant facts. Explanations are presented in tabulated form along with line diagrams and mnemonics which makes the learning efficient and interesting. While writing this book, special emphasis has been given to controversial and image-based questions as they are the ones which really make the difference. There is no secret routine, the intelligence go in drain if it is not combined with consistent hard work. Make the right choices to build a better future. All the best…



Dr Pritesh Singh
Director Dr Pritesh Institute
MBBS (MAMC) MS (Surgery)
FMAS FIAGES

Dr Pritesh Singh, graduate from Maulana Azad Medical College and postgraduate from Lady Hardinge Medical College, New Delhi, India, is an excellent teacher and has been taking awe inspiring classes in various countries since 2009. He is amongst the best faculty and is very popular with students because of his spellbinding classes. He is a renowned educationist and author of SURGERY ESSENCE, which needs no introduction and INI-CET ESSENCE and DPG entrance examination books. The students all over the country admire the way he teaches. He is not just a source of inspiration for his pupils rather he is their role model, as he is young and dynamic. He sets a positive example with his style of teaching, courtesy, cooperation and professionalism. Some students say he is a magician who keeps his students spellbound throughout his class. His performance speaks volumes about his knowledge and precision.

Printed in India

Available at all medical bookstores or buy online at www.ejaypee.com

JAYPEE BROTHERS
Medical Publishers (P) Ltd.
EMCA House, 23/23-B, Ansari Road,
Daryaganj, New Delhi - 110 002, INDIA
www.jaypeebrothers.com

Join us on facebook.com/JaypeeMedicalPublishers
Follow us on instagram.com/JaypeeMedicalPublishers

ISBN 978-93-5465-975-1
9 789354 659751