Look Inside the Book



OPERATIVE OBSTETRICS

AN ILLUSTRATED MANUAL

Arup Kumar Majhi

JAYPEE

Contents

Chapter 1. Instruments, Basic Surgical Techniques, Incision and Closure in Obstetrics 1

- Scissors *1*
- Scalpel Blades and Handles *2*
- Artery Forceps, Tissue Forceps, and Clamps *3*
- Tissue Dissecting Forceps or Dissecting Forceps *5*
- Needle Holders *6*
- Retractors *6*
- Suction during Surgery *8*
- Surgical Drains *8*
- Electrosurgical Systems *9*
- Surgical Needle *9*
- Suture Materials *10*
- Suture Tie and Knots *10*
- Suture Techniques *11*
- Staplers *12*
- Abdominal Incisions and Closure *12*
- Anatomy of Anterior Abdominal Wall *13*
- Types of Incision *15*
- Incision in Obese Woman *17*

Chapter 2. Obstetric Emergencies: Dealing with Critically Ill Mothers 18

- Obstetric Emergency *18*
- Maternal Emergencies *18*
- Maternal Mortality—Reflection of Country's Health Status *19*
- Preeclampsia/Eclampsia *20*
- HELLP Syndrome *21*
- Amniotic Fluid Embolism *23*
- Obstetric Shock *23*
- Hemorrhagic Shock *24*
- Septic Shock (Endotoxic Shock) Syn: Endotoxic Shock/Bacteremic Shock/Septicemic Shock *24*
- Acute Kidney Injury in Obstetrics *25*
- Disseminated Intravascular Coagulation *27*
- Blood and Blood Products *28*

Chapter 3. Early Pregnancy Procedures: Abortion—Spontaneous and Induced 30

- Definition and Terminology *30*
- Classification of Abortion *30*
- Spontaneous Abortion *31*
- Different Methods of Evacuation of Uterus *33*
- Induced Abortion—Medical Termination of Pregnancy *44*
- Medical Abortion *44*
- Septic Abortion *50*
- Medical Termination of Pregnancy Act of India following its Amendments 2021 *51*
- Period of Gestation, Category, and Number of Practitioners *53*
- Medical Board *53*

Chapter 4. Ectopic Pregnancy 55

- Incidence *55*
- Types *55*

JAYPEE BROTHERS

- Various Sites of Tubal Ectopic Pregnancy *56*
- Etiology and Risk Factors of Tubal Ectopic Pregnancy *56*
- Pathology of Tubal Ectopic Pregnancy *56*
- The Fates (Termination) of Tubal Pregnancy *57*
- Changing Trends *58*
- Diagnosis *58*
- Differential Diagnosis of Acute Ectopic Pregnancy *60*
- Management of Ectopic Pregnancy *60*
- Management of a Case of Disturbed Tubal Pregnancy *61*
- Steps of Management of Ectopic Pregnancy *61*
- Conservative Management of Ectopic Pregnancy *63*
- Expectant Management of Ectopic Pregnancy *64*
- Interstitial Pregnancy *64*
- Abdominal Pregnancy *66*
- Cervical Pregnancy *68*
- Ovarian Pregnancy *70*
- Cesarean Scar Pregnancy *70*
- Heterotropic Pregnancy *72*
- Pregnancy of Unknown Location *73*
- Prognosis and Outcome of Ectopic Pregnancy *73*

Chapter 5. Gestational Trophoblastic Disease 74
- Classification of Gestational Trophoblastic Disease *74*
- Hydatidiform Mole *74*
- Gestational Trophoblastic Neoplasia *79*
- Future Pregnancy *83*

Chapter 6. Cervical Incompetence and Cervical Cerclage 84
- Etiology *84*
- Diagnosis *85*
- Management *86*

Chapter 7. Invasive Prenatal Testing and Fetal Therapy 92
Kusagradhi Ghosh
- Fetal Invasive Diagnostic Procedures *92*
- Cordocentesis *97*
- Other Invasive Diagnostic Procedures *98*
- Fetal Therapeutic Procedures *98*
- Fetal Blood Transfusion *100*
- Procedures in Complicated Monochorionic Multiple Pregnancy *102*
- Fetal Reduction in Complicated Monochorionic Pregnancy *103*
- Fetal Shunt Procedures *105*
- Fetal Endoscopic Tracheal Occlusion *107*
- Fetal Cardiac Therapy *107*
- Other Closed Fetal Invasive Therapeutic Procedures *108*
- Fetal Ex-Utero Intrapartum Therapy *108*
- Open Fetal Surgery *109*
- Future of Fetal Therapy *109*

Chapter 8. Delivery of Breech and Transverse Lie 110
Breech Presentation *111*
- Incidence *111*
- Types of Breech with Frequency *111*
- Hazards of Vaginal Breech Delivery *111*
- Etiology *113*
- Diagnosis and Clinical Examination *113*

JAYPEE BROTHERS

- Antenatal Management *114*
- Mechanism of Vaginal Breech Delivery *116*
- Selection of Route of Delivery in Breech Presentation *116*
- Indications of Cesarean Delivery in Breech Presentation *116*
- Criteria for Planned Vaginal Breech Delivery *116*
- Labor Management *116*
- Complete Breech Extraction *121*
- Complicated Breech Delivery *121*
- Cesarean Delivery in Breech Presentation *125*

Transverse Lie *126*
- Definition *126*
- Etiology *126*
- Diagnosis *126*
- Mechanism of Labor in Transverse Lie *127*
- Risks of Transverse Lie *128*
- Outcome of Transverse Lie following Labor *128*
- Favorable Outcome in Transverse Lie *128*
- Management of Pregnancy with Transverse Lie *129*
- Internal Podalic Version *129*
- Difficulty in Cesarean Delivery in Transverse Lie *130*
- Neglected Shoulder Presentation *131*

Chapter 9. Twin Delivery 132
- Incidence of Multiple Gestations and Etiology *132*
- Risks and Complications of Multiple Pregnancy *132*
- Discordant Twins *133*
- Other Fates of Twin Fetuses *133*
- Special Problems Specific to Monochorionic Twins *133*
- Neonatal Prognosis in Multiple Pregnancy *133*
- Embryology of Twin Gestation *134*
- Determination of Chorionicity *135*
- Fetus in Fetu *138*
- Diagnosis of Twin Gestation *138*
- Management of Twin Pregnancy *140*
- Time of Delivery *141*
- Role of Induction and Augmentation *141*
- Choice of Route of Delivery *141*
- Indications of Cesarean Delivery *141*
- Management of First Stage of Labor in Twin Pregnancy *141*
- Management of the Second Stage of Labor in Twin Pregnancy *141*
- Management of Some of the Common Complications Encountered during Second Stage of Labor *143*
- Locked Twins *143*
- Management of the Third Stage in Twin Pregnancy *144*
- Technique of Cesarean Delivery in Twin Gestation *144*
- Twin Delivery in Pregnancy with Previous Cesarean Delivery *144*
- Triplet or Higher Order Multiple Gestation *145*

Chapter 10. Placental Disorders and Hemorrhage (Abruptio Placentae, Placenta Previa) 147
- Causes of Antepartum Hemorrhage *147*
- Vasa Previa *147*
- Abruptio Placentae *148*
- Placenta Previa *153*

Chapter 11. Placenta Accreta Spectrum 160
- Incidence *160*
- Different Varieties *160*
- Federation of Gynecology and Obstetrics Classification of Placenta Accreta Spectrum (2019) *160*

JAYPEE BROTHERS

- Complications *162*
- Risk Factors and Etiology *162*
- Pathophysiology *162*
- Diagnosis *162*
- Imaging in Placenta Accreta Spectrum *163*
- Management *165*
- Delivery and Cesarean Hysterectomy *166*
- Alternate Methods of Management *169*

Chapter 12. Induction and Augmentation of Labor 171
- Definitions *171*
- Indications *171*
- Contraindications *171*
- Determining Factors for Success of Induction *171*
- Methods of Induction of Labor *172*
- Failed Induction *175*
- Risks and Complications *175*

Chapter 13. Obstructed Labor: Symphysiotomy, Duhrssen's Incision, Impacted Head, and Vaginal Septum 177
- Definition *177*
- Causes of Obstructed Labor *177*
- Sequel of Obstructed Labor *177*
- Diagnosis a Case of Obstructed Labor *178*
- Prevention of Obstructed Labor *178*
- Definitive Management of Obstructed Labor *178*
- Cervical Dystocia *178*
- Duhrssen's Incision *179*
- Symphysiotomy *180*
- Hydrocephalus *180*
- Impacted Head *183*
- Vaginal Septum *183*

Chapter 14. Shoulder Dystocia 185
- Definition *185*
- Incidence *185*
- Mechanism *185*
- Risk Factors *185*
- Prediction *185*
- Prevention *185*
- Hazards *186*
- Diagnosis of a Case of Shoulder Dystocia *186*
- Management of a Case of Shoulder Dystocia *186*

Chapter 15. Episiotomy and Obstetric Anal Sphincter Injuries 188
- Episiotomy *188*
- Anatomy of Anal Canal and Anal Sphincter *195*
- Anal Incontinence *196*
- OASIS *196*
- Episiotomy Wound Dehiscence *200*

Chapter 16. Cesarean Delivery 202
- History *202*
- Definition 203
- Indications *203*
- Types *203*
- Reasons of Stronger (Sound) Scar in LSCS than Classical One *204*

JAYPEE BROTHERS

- Preoperative Procedures and Care *204*
- Perioperative Care *204*
- Steps of Lower-Segment Cesarean Delivery *205*
- Variation in Technical Aspects of Cesarean Delivery and Current Recommendation *215*
- CAESAR Study *217*
- Indications of Forceps Application during Cesarean Delivery *217*
- Technique of Classical Cesarean Delivery (Upper Uterine) *217*
- Postoperative Care *219*
- Complications *219*
- Cesarean Delivery in Special Situations *220*
- Incidences *222*

Chapter 17. Rectus Sheath Hematoma Following Cesarean Delivery 225
- Anatomical Considerations *225*
- Causes of Rectus Sheath Hematoma in Lower Uterine Cesarean Delivery *226*
- Diagnosis *226*
- Classification *226*
- Differential Diagnosis *226*
- Management *226*
- Prevention *229*
- Prognosis *229*

Chapter 18. Operative Vaginal Delivery: Forceps, Ventouse, and Odon 230
- Obstetric Forceps *230*
- Vacuum Extraction/Ventouse *253*
- Odon *258*

Chapter 19. Postpartum Hemorrhage Including Retained Placenta 260

Postpartum Hemorrhage *260*
- Definition *260*
- Types and Classification *260*
- Etiology and Risk-Factors (Predisposing Factors) for Obstetric Hemorrhages *261*
- Causes of Primary Postpartum Hemorrhage *261*
- Dangers of Postpartum Hemorrhage *262*
- Measures to Prevent Death from Postpartum Hemorrhage *262*
- Management of Atonic Postpartum Hemorrhage *265*
- Pelvic Pressure Packing (Transvaginal) *269*
- Internal Iliac Artery Ligation *270*
- VP Paily's Vascular Clamps for Management of Postpartum Hemorrhage *277*
- Samartha Ram's SR Vacuum Suction Cannula for the Management of Atonic Postpartum Hemorrhage *278*
- Hysterectomy in Postpartum Hemorrhage *278*
- Secondary Postpartum Hemorrhage *279*
- Management of a Case of Secondary Postpartum Hemorrhage *279*

Oxytocics *282*
- Oxytocin *282*
- Methylergometrine *283*
- Misoprostol *283*
- Carbetocin *283*
- Tranexamic Acid *284*

Retained Placenta *284*
- Causes of Retained Placenta *284*
- Management of a Case of Retained Placenta *284*
- Steps of Manual Removal of the Placenta *284*

Chapter 20. Inversion of Uterus 286
- Incidence *286*
- Classification and Degrees *286*

JAYPEE BROTHERS

- Causes of Inversion of the Uterus *286*
- Differential Diagnosis *287*
- Diagnosis of Uterine Inversion *287*
- Management of Uterine Inversion *288*
- O'Sullivan's Hydrostatic Method (1945) *290*
- Huntington Technique (1928) *290*
- Haultain Technique (1901) *290*
- Newer Techniques *290*

Chapter 21. Genital Tract Injuries and Puerperal Hematomas 292
- Risk Factors for Traumatic Postpartum Hemorrhage *292*
- Sites of Laceration *292*
- Puerperal Hematomas *294*
- Broad Ligament Hematoma *296*
- Rupture Uterus *297*

Chapter 22. Obstetric Hysterectomy 303
- Introduction, Definition, and Incidence *303*
- History of Obstetric Hysterectomy *303*
- Varieties and Classification of Obstetric Hysterectomy *304*
- Indications of Cesarean Hysterectomy *304*
- Variations in Type of Obstetric Hysterectomy *311*
- Variations in Technique in Total Hysterectomy *311*
- Postoperative Management *311*
- Complications of Obstetric Hysterectomy *311*
- Peroperative Complications *311*
- Ureter and Bladder Injury *312*
- Postoperative Complications *312*
- Mortality *313*

Chapter 23. Laparoscopic Procedures in Obstetrics 314
Abhinibesh Chatterjee
- History of Laparoscopy in Obstetrics—Past and Present *314*
- Reasons for Difficulties and Challenges of Use of Laparoscopy in Obstetrics *314*
- Advantages of Laparoscopy in Obstetrics *315*
- Indications of Laparoscopy in Obstetrics *316*
- Contraindications of Laparoscopy in Obstetrics *316*

Chapter 24. Anesthesia and Analgesia in Obstetrics 321
- Determining Factors of Perception of Pain During Labor *321*
- Physiology of Labor Pain *321*
- Methods of Pain Relief in Labor *322*
- Local Perineal Infiltration 325
- General Anesthesia in Pregnancy and Labor *326*

Chapter 25. Puerperal Contraception: Postpartum IUCD and Puerperal Sterilization 327
- Types of Contraceptive and Family Planning Methods in Postpartum Period *327*
- Injectable Contraceptives *327*
- Postpartum IUCD *328*
- Postpartum Ligation or Sterilization *331*
- Regret of Permanent Sterilization *335*

Chapter 26. Destructive Operation 336
- Types of Destructive Operations in Obstetrics *336*
- Craniotomy *336*
- Decapitation *338*

JAYPEE BROTHERS

- Evisceration *339*
- Spondylotomy *339*
- Cleidotomy *340*

Chapter 27. Gynecological Diseases in Pregnancy 341
- Pregnancy with Uterine Fibroid (Myoma, Fibromyoma, or Leiomyoma) *341*
- Ovarian Tumor *343*
- Cervical Cancer *345*
- Cervical Polyp *346*
- Pregnancy with Pelvic Organ Prolapse *346*

Chapter 28. Surgical Illness in Pregnancy 348
- Appendicitis *348*
- Peptic Ulcer *349*
- Cholecystitis and Gallstone *349*
- Pancreatitis *349*
- Renal Stone *349*

Chapter 29. Gastrointestinal Tract Injury and Urinary Tract Injury 351
- Risk Factors *351*
- Gastrointestinal Tract Injury *351*
- Rectovaginal Fistula *353*
- Urinary Tract Injuries during Child Birth *353*

Chapter 30. Postoperative Complications and Management 358
- Venous Thrombosis *358*
- Pulmonary Embolism *359*
- Anticoagulants used in Thromboembolic Phenomenon *360*
- Infections *360*
- Wound Problems and Surgical Site Wound Infection *362*
- Peritonitis *364*
- Necrotizing Fasciitis *365*
- Septic Pelvic Thrombophlebitis *365*

Index 367

JAYPEE BROTHERS

CHAPTER 8

Delivery of Breech and Transverse Lie

Learning Objectives

- Types of Breech with Frequency
- Hazards of Vaginal Breech Delivery
- Etiology and Diagnosis
- Antenatal Management
- Selection of Route of Delivery in Breech Presentation
- Indications of Cesarean Delivery in Breech Presentation
- Criteria for Planned Vaginal Breech Delivery
- Labor Management
- Complete Breech Extraction
- Complicated Breech Delivery
- Cesarean Delivery in Breech Presentation
- Transverse lie—Etiology and Diagnosis
- Risks of Transverse Lie
- Outcome of Transverse Lie Following Labor
- Management of Pregnancy with Transverse Lie
- Internal Podalic Version
- Difficulty in Cesarean Delivery in Transverse Lie
- Neglected Shoulder Presentation

BREECH PRESENTATION

INTRODUCTION

Breech presentation and delivery is strongly associated with excessive perinatal morbidity and mortality. It complicates 3–4% of all deliveries at term. Multiple factors such as prematurity, congenital anomaly, and birth injury account for the adverse perinatal outcome. To minimize the birth injury, elective cesarean delivery has been advocated by many for breech delivery. From the "Term Breech Trial" (2000) involving 26 countries and 126 centers, it was interpreted that elective cesarean delivery is the safest mode of delivery to minimize perinatal mortality and morbidity. There was no difference in maternal morbidity in abdominal and vaginal modes of deliveries. However, the interpretation of Term Breech Trial is not without controversy, and cesarean section and abdominal incision were not considered as morbid outcome in the trial. On the other hand, PREMODA study (Presentation et Mode d'Accouchement), a French prospective observational study comprising 8,000 women with term singleton breech, showed no difference in neonatal morbidity and outcome with the mode of delivery (2006) and by secondary analysis the rate of severe maternal morbidity was not different (2019) in two modes of deliveries. In reality, cesarean delivery is associated with several complications in the present and future pregnancies. Besides, many mothers come in advance labor with breech presentation when abdominal delivery does not become possible. Many patients refuse cesarean delivery, and cesarean delivery may not be available in all settings. In addition, vaginal breech delivery has been documented with highly satisfactory outcomes in properly selected cases. However, it requires technical skill, knowledge, and judgment of the accoucheur which is only possible with experience. Due to a smaller number of vaginal breech delivery, technically skilled persons are less available now and the new generations lack proper training. Medicolegal concern also has reduced the attempt of vaginal breech birth.

In the literature and textbooks published in last century and onward, there is lack of consensus on the proper technique of vaginal breech delivery; even with the same nomenclature, the procedure differs. Not all pregnancies with breech presentation need cesarean section and not every pregnancy with breech is a candidate for vaginal delivery. One must be acquainted with the vaginal breech delivery technique and also be aware of the precautions to be taken during abdominal breech delivery.

JAYPEE BROTHERS

INCIDENCE

At term, the incidence of breech presentation is 3–4%. The frequency is much higher in lower gestational age. The lesser the gestational age, the more the frequency. At 34 weeks, it is 5% and at 28 weeks, it is 20%.

TYPES OF BREECH WITH FREQUENCY (FIGS. 1 TO 7)

Breech is broadly subdivided into complete breech, frank breech, and incomplete breech.

- *Complete breech* (5%) ***(Figs. 1 to 3)****:* Here, the extremities are in flexed attitude. Two buttocks, feet, and external genitalia are the presenting parts.
- *Frank breech* (65%) ***(Figs. 4 and 5)****:* Here, the thighs are flexed and legs are extended. This is the most common variety.
- *Incomplete breech* (30%): (1) Breech with knee presentation where thighs are extended but knees are flexed and (2) breech with footling presentation **(Figs. 6 and 7)**—both thighs and legs are extended.

When the head is in extreme hyperextended attitude, it is called *star gaze fetus* or *flying fetus*. In this type of breech, vaginal delivery is difficult and may result in injury to the cervical spinal cord. This is an indication for cesarean section if present after labor has begun. This is diagnosed by sonography.

In Frank breech, prognosis is best as it is a good cervical dilator and the incidence of cord prolapse is less. It is common in *primigravida*. In complete breech, prognosis is not as good as frank breech. However, as it is common in *multigravida*, the course of birth is smooth. In footling presentation, prognosis is worst for vaginal delivery.

HAZARDS OF VAGINAL BREECH DELIVERY

Hazards of vaginal breech delivery include maternal morbidity, perinatal morbidity, and mortality.



Fig. 1: Complete breech.

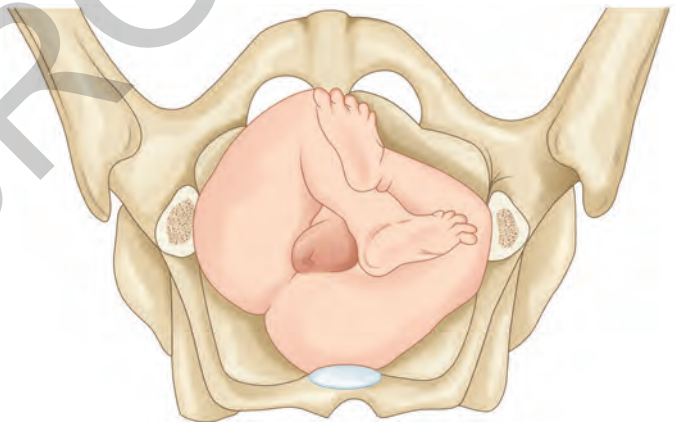

Fig. 2: Vaginal findings of flexed breech (right sacroposterior).



Fig. 3: Vaginal findings of flexed breech (right sacroposterior). *Courtesy:* Dr Anirban Mondal, Associate Professor, Bankura Sammilani Medical College and Hospital, Bankura, West Bengal, India.



Fig. 4: Frank breech.

JAYPEE BROTHERS



Fig. 5: Breech presentation in advance labor showing fetal scrotum.



Fig. 6: Footling presentation.



Fig. 7: Only leg is delivered (footling).
Courtesy: Dr Abhishek Bhadra, Assistant Professor, Medical College, Kolkata, West Bengal, India.

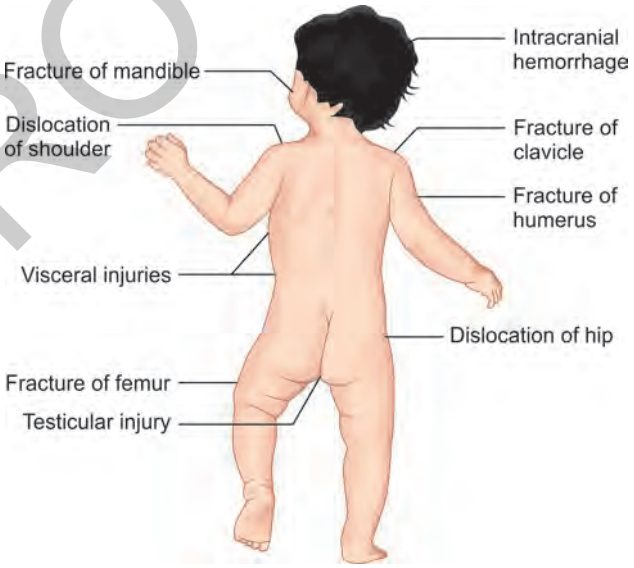

Fig. 8: Potential injuries of baby during vaginal breech delivery.

Increased perinatal morbidity and mortality are the main threats of breech presentation. There is no effect on maternal health as such due to breech presentation itself except the events related to the delivery and the etiologies causing breech presentation such as placenta previa.

The events related to the delivery causing maternal complications are trauma to the genital tract during vaginal delivery, manipulation, instrument application, cesarean section, increased hemorrhage, sepsis, and anesthetic complications.

Fetal hazards in breech presentation are due to the hazards in vaginal birth and due to inherent problems of the fetus itself such as prematurity and congenital abnormality (if any).

Fetal hazards of vaginal breech delivery **(Fig. 8)** are as follows:

- *Structural injuries* from below upward are fracture of femur, dislocation of hip, visceral injuries such as injury to testis, liver, spleen, kidney, suprarenal gland, lungs, fracture of humerus, clavicle, dislocation of the shoulder, fracture of mandible, fifth and sixth cervical vertebrae, trauma to sternomastoid muscle, and torticollis.
- *Nerve injury*: Erb's palsy—Policeman's tips (due to upper brachial plexus injury) and Klumpkey's palsy (lower brachial plexus injury)
- *Asphyxia*: Due to cord prolapse, cord compression, premature attempt at respiration, and premature separation of placenta take place.

JAYPEE BROTHERS

- Hanging like death of the fetus due to sudden trauma over the medulla oblongata by the odontoid process.
- *Intracranial hemorrhage*: It occurs due to the tear of tentorium cerebelli and hemorrhage in the subarachnoid space because of the sudden compression followed by decompression during delivery of aftercoming head of breech. Premature babies are more prone to developing this problem.
- Neonatal seizure and intubation within 24 hours of birth are common among breech babies born vaginally.

Perinatal mortality in breech presentation is three to five times more than the vertex presentation. It ranges from 5 to 35 per 1,000 births.

ETIOLOGY

Common causes of breech presentation are prematurity, congenital malformation of the uterus, multiple pregnancy, placenta previa, and congenital anomaly of the fetus. Prematurity is the most common. For more details, see author's *Bedside Clinics in Obstetrics*, 5th edition, Academic Publishers.

Causes of recurrent breech are congenital malformation of the uterus and cornufundal attachment of placenta.

DIAGNOSIS AND CLINICAL EXAMINATION

Clinically, breech is diagnosed by abdominal palpation (first, second, third, and fourth Leopold maneuvers; **Figs. 9 to 12**). In the first Leopold maneuver hard, globular, ballotable head is palpable at fundus. In the second Leopold maneuver, fetal dorsum is on one side and ventral aspect is palpable on the other side of the umbilicus. By third and fourth Leopold maneuvers, the soft, broad and irregular podalic end is palpable. Lie is longitudinal. Fetal heart sound (FHS) lies above, in comparison to vertex presentation.

On per vaginal examination if the patient is not in labor, soft irregular mass is palpable through the fornix and sacrum may be palpable and if the patient is in labor ischial tuberosities, sacrum, external genitalia, and feet are palpable in case of complete breech **(Figs. 2 and 3)** whereas feet are not palpable in frank breech **(Fig. 5)**. Fetal sacrum helps to determine the position of breech. In case of footling presentation, only the feet are palpable and identified by the heels.

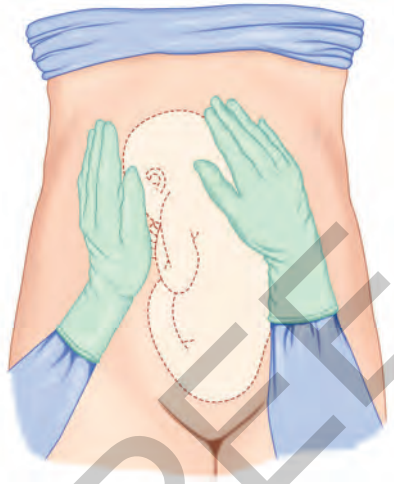

Fig. 9: Fundal grip (first Leopold maneuver).



Fig. 10: Lateral grip (second Leopold maneuver)

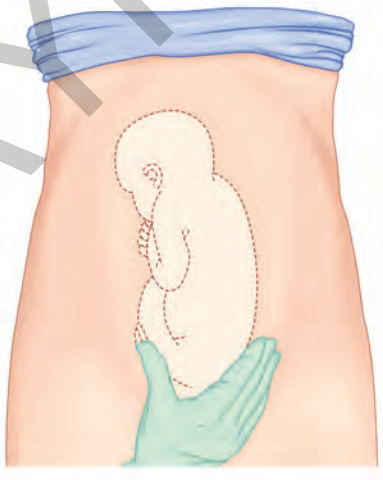

Fig. 11: First pelvic grip—Pawlik grip (third Leopold maneuver).



Fig. 12: Second pelvic grip (fourth Leopold maneuver).

JAYPEE BROTHERS

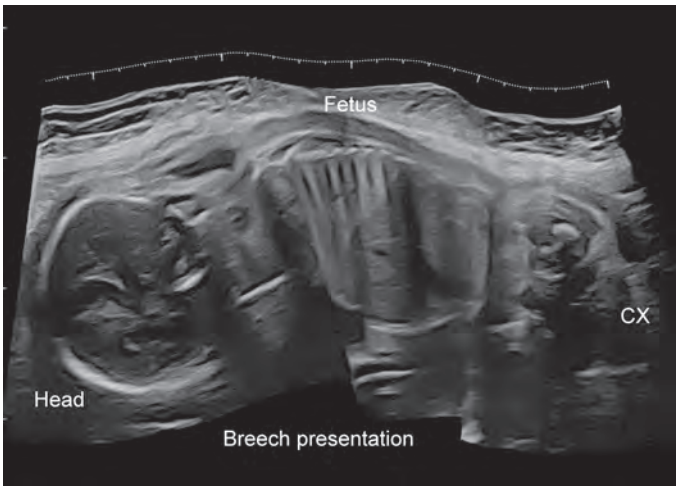

Fig. 13: Breech presentation at 32 weeks.
Courtesy: Professor Kamal Oswal, Head, Department of Radiodiagnosis, Vivekananda Institute of Medical Sciences, Kolkata, West Bengal, India.

Sonography **(Fig. 13)** confirms the diagnosis, determines the maturity of the fetus, finds out the type of breech and the attitude of head (*Star gaze appearance*), and can detect any congenital anomaly of the fetus. Presence of placenta previa is diagnosed which may be the cause of breech presentation. The amount of liquor is also estimated.

ANTENATAL MANAGEMENT

Routine antenatal management includes rest, nutritious diet, iron, folic acid, and immunization. Any obstetric complication including placenta previa must be checked for.

Specific antenatal management of pregnancy with breech presentation is *external cephalic version* (ECV). ECV makes the breech to cephalic presentation. ECV is attempted, where there is no contraindication.

External Cephalic Version

Version is an obstetric maneuver by which presentation with or without lie is changed from an unfavorable to a favorable one. In case of breech presentation, manipulation is done to make it vertex presentation whereas the lie remains the same, called external cephalic version.

In case of transverse lie, shoulder presentation is changed to either vertex or breech presentation and lie is also changed from transverse to longitudinal. Hence, in transverse lie, both presentation and lie are changed during version.

External version may be ECV and external podalic version. Internal version is always podalic version. Internal podalic version (IPV) is done only in second baby in twin. In a large-sized baby with less liquor, IPV should not be attempted.

Rationality of ECV in breech presentation is that it reduces the chance of vaginal breech delivery and also the complications arising out of it. It also reduces the cesarean section rate which is >85% in breech presentation. However, all cases are not suitable for version and contraindications are considered.

Contraindications of ECV

- Antepartum hemorrhage (placenta previa, accidental hemorrhage)
- Severe pre-eclampsia
- Contracted pelvis
- Multiple pregnancy
- Pregnancy with prior cesarean delivery
- Premature rupture of membranes (PROM)
- Congenital malformation of uterus
- Fetal factors—gross congenital anomaly, intrauterine growth restriction (IUGR), intrauterine fetal demise (IUFD)
- Other obstetric conditions—elderly primi, bad obstetric history (BOH)

Time of Version

In recent practice, ECV is done in a woman who has reached $37^{0/7}$ weeks before the onset of labor (ACOG 2020). In too early version, the possibility of reversion is more and besides, there is still a chance of spontaneous version. The possibility of failure increases when the version is performed after this period of pregnancy.

Dangers of ECV are PROM, onset of labor, chance of accidental hemorrhage due to placental separation, and fetal distress; even fetal death may occur due to cord entanglement and placental separation.

There is more chance of fetomaternal hemorrhage for which *routine anti-D gamma-globulin is given to a nonimmunized Rh-negative mother when ECV is performed.*

Procedure of ECV (Figs. 14 to 17)

External cephalic version is an outpatient department (OPD) procedure which should always be done in a well-equipped center where facility of cesarean delivery is available.

The patient is asked to pass urine. Consent is taken. The position of the patient is dorsal position with legs slightly drawn up. A pillow can be placed behind the buttocks or the patient may be placed in Trendelenburg position. This will help in disengagement of an engaged breech. The obstetrician will stand on the right side of the patient. After exposing abdomen lie, the presentation and position of the fetal back are determined by abdominal palpation. FHS is auscultated. Talcum powder is sprinkled over the abdomen. By the pelvic grip, the podalic end is displaced to one iliac fossa toward which the back lies. The head at the fundus is grasped by the left hand and the podalic pole is grasped by the right hand **(Fig. 14)**. With gentle and steady pressure, the breech is pushed to the back and head to the front of the fetus making the trunk well flexed, and this movement

JAYPEE BROTHERS

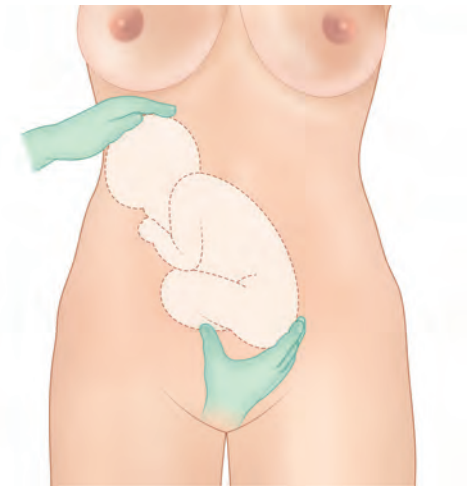

Fig. 14: External cephalic version (ECV) by forward roll—first step.

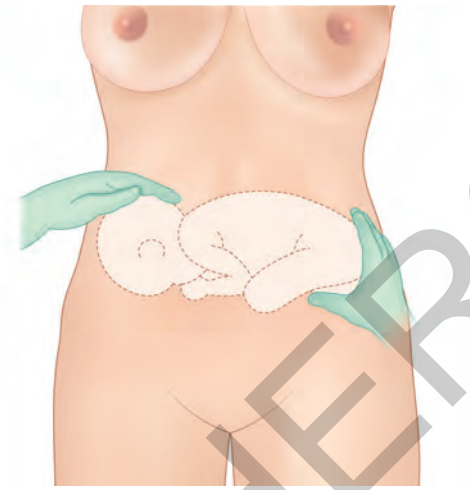

Fig. 15: External cephalic version (ECV) by forward roll—second step.

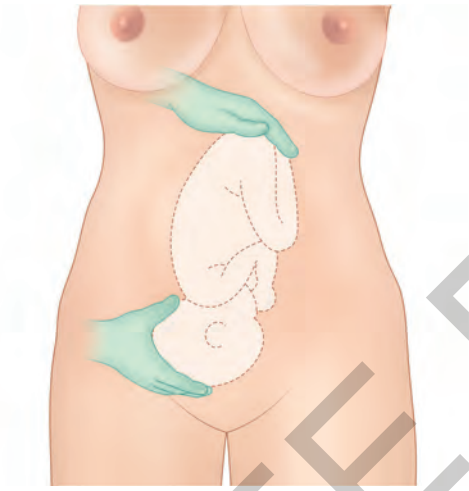

Fig. 16: External cephalic version (ECV) by forward roll—third step.

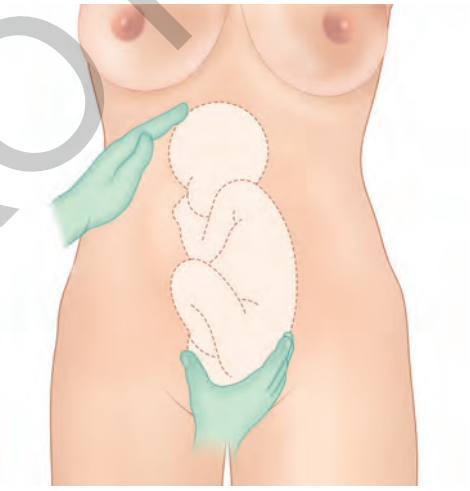

Fig. 17: External cephalic version in backward roll.

is continued until the lie becomes transverse **(Fig. 15)**. At this point, the hands are to be changed following which FHS is auscultated.

Now with the changed hands (right hand on the head and left hand on the podalic end), the head is pushed downward toward the pelvis and the breech toward the fundus to make the lie longitudinal **(Fig. 16)**. All manipulations are done in the relaxation phase. FHS is auscultated again. There may be transient bradycardia which usually passes off after few minutes. FHS is monitored at least for 30 minutes. This is *forward somersault movement* or "forward roll."

If forward roll is unsuccessful, the procedure is done in the opposite direction, which is called "backward roll" **(Fig. 17)**, but not recommended now [Royal College of Obstetricians and Gynaecologists (RCOG) 2017].

Nonstress test (NST) should be done before and after the procedure. Tocolytic drugs such as terbutaline 250 μg SC or isoxsuprine 50–100 mg IV or calcium-channel blocker (nifedipine) may be used during ECV for relaxation of uterus. However, their effectiveness is controversial.

If bradycardia does not pass off within 1 or 2 minutes, oxygen inhalation is given to the mother. If it still persists after 10 minutes' version, reversion is to be considered as there is possibility of cord entanglement. Cardiotocography (CTG) is helpful to detect any abnormality.

The *success rate* of ECV ranges from 50 to 60%, average being 58%.

If the version fails, pregnancy is continued till term. In the meantime, there is possibility of spontaneous version in few cases. In case of persistent breech presentation, it is judged on its own merit whether vaginal or abdominal delivery will be done.

Causes of failure of ECV are scanty liquor, large baby, breech with extended leg (difficult to flex the trunk due to splinting action of the limbs), uterine anomalies, obesity, and irritable uterus.

JAYPEE BROTHERS

MECHANISM OF VAGINAL BREECH DELIVERY

In case of breech denominator is sacrum. Position is determined by relation of sacrum to the maternal pelvis. Various positions are left sacroanterior (LSA), right sacroanterior (RSA), right sacroposterior (RSP), and left sacroposterior (LSP). Other two positions are left sacrotransverse (LST) and right sacrotransverse (RST). Station is determined by relation of the lowermost point of buttock to the ischial spines.

Bitrochanteric diameter is 10 cm and bisacromial diameter is 12 cm. Aftercoming head should always be delivered in flexed attitude to prevent entrapment of head. The anteroposterior diameter of aftercoming head is suboccipitofrontal diameter which is 10 cm.

Delivery of the breech consists of delivery of buttocks, shoulders, and head.

Buttock is delivered by engagement in one oblique diameter of pelvic inlet, then descent, internal rotation of anterior buttock and lateral flexion with further descent followed by restitution. In the shoulder the cardinal movements are engagement, descent with internal rotation, and delivery of posterior shoulder followed by anterior shoulder. Then restitution and external rotation occur. For the delivery of fetal head engagement occurs in one oblique diameter, then descent with flexion occurs, followed by internal rotation of the occiput to put the occiput behind the symphysis pubis. Head is finally born by flexion.

For details and elaborate discussion on the mechanism of vaginal breech delivery, see author's *Bedside Clinics in Obstetrics*, 5th edition, Academic Publishers.

SELECTION OF ROUTE OF DELIVERY IN BREECH PRESENTATION

Route of delivery depends upon various maternal factors: fetal factors, maternal factors, maternal choice, amount of liquor, and availability of skill provider. Sonography is very helpful for taking the decision.

INDICATIONS OF CESAREAN DELIVERY IN BREECH PRESENTATION

Maternal factors:

- Any degree of pelvic contraction or unfavorable shape of pelvis
- Postcesarean pregnancy
- Breech with obstetric complications
- Previous history of perinatal death
- Maternal request for vaginal delivery

Sonographic findings:

- Large fetus of estimated weight >3.5 kg
- Fetus with hyperextended head
- Footling presentation
- Severe fetal growth restriction
- Preterm but apparently healthy fetus with the mother in either active labor or in whom delivery is indicated
- Congenital fetal anomaly of fetus not compatible with vaginal birth
- Oligohydramnios or nuchal loop of cord
- Nuchal arm

Provider's factor: Nonavailability of provider skilled with vaginal breech delivery

CRITERIA FOR PLANNED VAGINAL BREECH DELIVERY

Candidates Suitable for Vaginal Breech Delivery

The criteria should be chosen such that there is maximum possibility of vaginal delivery and minimizing the fetal risk. The cases suitable for vaginal breech delivery are:

- Estimated fetal weight between 2,000 and 3,500 g
- Adequate pelvis by clinical assessment
- Frank breech or complete breech presentation
- Flexed head
- Absence of other complications
- Absence of fetal anomalies where vaginal delivery is not feasible
- Experienced person for vaginal breech delivery is available
- Patient gives the consent

LABOR MANAGEMENT

Induction is controversial for breech delivery. Most studies find no outcome difference, few studies show higher neonatal intensive care unit (NICU) admission in the induction group, and some show an increased cesarean rate in the induction group. Augmentation of breech labor is also controversial. In general, progress of labor in breech presentation is slow. Many avoid augmentation. Few schools prefer to augment only in uterine hypotonicity. Others prefer amniotomy for labor augmentation.

Management of Breech Presentation in the First Stage of Labor

- History taking and examination including contraction, type of breech, FHS, dilatation of os, status of membranes, station and pelvic capacity.
- Patient should be at rest and nonambulatory to avoid early rupture of membranes.
- Monitor the fetal condition frequently, preferably with the help of CTG.
- Progress of labor is monitored.
- Oral diet is stopped; instead, intravenous fluid is given.
- Vaginal examination is done following rupture of membranes to exclude cord prolapse.

JAYPEE BROTHERS

- Analgesics and sedatives
- Cesarean section is indicated in case of *uterine dystocia, prolonged labor, early rupture of membranes*, and *cord prolapse.*

Management of Breech Presentation in the Second Stage of Labor

The various options of vaginal breech delivery are:

- Spontaneous breech delivery
- Assisted breech delivery
- Total breech extraction

Spontaneous breech delivery refers to the expulsion of fetus entirely without any manipulation or even traction except support of the baby.

Assisted breech delivery in which the delivery is done with support but with minimal interference is the most preferred approach and commonly performed. In this method, the obstetrician performs maneuvers after almost spontaneous expulsion of fetal body up to umbilicus.

Complete breech extraction is the hurried delivery of baby by the obstetrician, usually under general anesthesia (GA). Indications are second baby of twin after IPV, fetal distress, and cord prolapse in the late second stage.

There is another popular term "partial breech extraction" which is used for the approach almost similar to assisted breech delivery. There is no consensus and uniformity of the terminology of various approaches of vaginal breech delivery.

Assisted Breech Delivery

Essential requirements for the assisted breech delivery are: (1) An obstetrician skilled in the art of breech delivery; (2) Presence of an anesthetist; (3) An assistant; (4) A neonatologist with baby resuscitative measures; (5) Episiotomy set; and (6) Obstetric forceps.

The principles of vaginal breech delivery are never traction from below, push the fetus through the mother's abdomen, try to keep the dorsal aspect of the fetus anteriorly, and never to be in haste.

Steps of assisted breech delivery:

1. The patient is brought to the edge of the table when buttocks are visible at the perineum. She is made to lie in lithotomy position when buttocks distend the perineum. Antiseptic dressings, draping, and evacuation of bladder are done.
2. Per vaginal examination is done to confirm full dilatation of cervix and to exclude cord prolapse. Mediolateral episiotomy is given under local infiltration of 1% xylocaine solution with or without pudendal block when the perineum is thinned out by the posterior buttock **(Figs. 18 and 19)**.
3. Legs are easily delivered if they are flexed. The anterior leg is released first, followed by the release of the posterior leg. In case of frank breech, the extended legs are delivered by abduction and flexion of the thighs with gentle pressure over the popliteal fossa **(Fig. 20)**. The ankle is grasped and the foot is delivered **(Fig. 21)**.
4. The baby is allowed to be born up to the level of the umbilicus by wait-and-watch policy **(Fig. 22)**. As soon as the umbilicus is delivered, the umbilical cord is palpated, drawn to some extent and kept in a safe position like in one sacral bay to prevent its compression.
5. If the back lies posteriorly, the fetus is rotated to bring the back to the front. Transient cessation of cord pulsation is very common at this stage. It has no effect on the outcome of the baby. The trunk of the baby is wrapped with a sterile towel. The towel will help in proper gripping of the baby and also prevent the fetus from external stimulus. The position of the arms is noted—whether they are in flexed or in extended condition.



Fig. 18: Buttock is in the perineum showing fetal external genitalia.

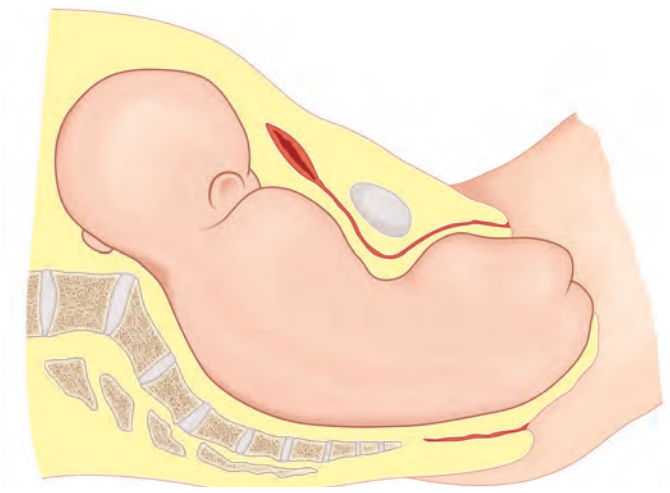

Fig. 19: Buttock is being delivered.

JAYPEE BROTHERS

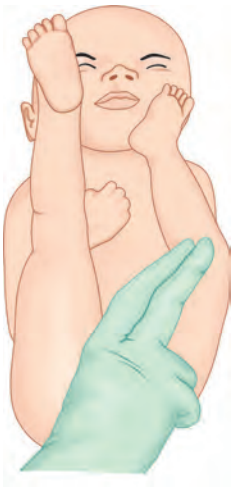

Fig. 20: Extended leg is delivered by abduction and flexion of the thigh with gentle pressure over the popliteal fossa which makes the leg flexed.



Fig. 21: Leg is delivered by grasping the ankle.



Fig. 22: Baby is born up to the level of umbilicus.

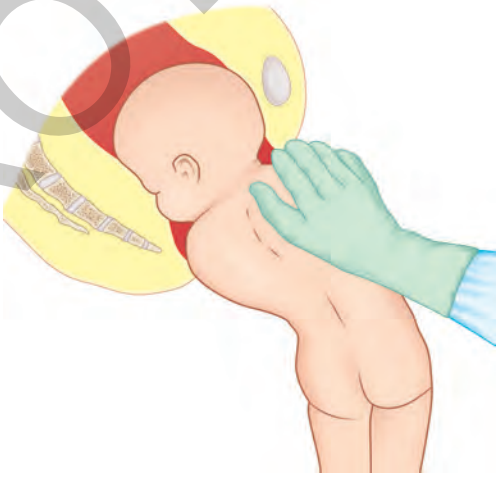

Fig. 23: Delivery of anterior arm.

6. The position of the arms is determined by two methods: (1) By palpating the medial margins of the scapula and (2) By searching for the presence of arms in front of the chest. In case of extended arms, there is *winging of the scapula*. In flexed arms, the medial borders of the scapula become parallel to the vertebral column and the arms are found in front of the chest.
7. Delivery of the flexed arms—the arms are delivered one after another by simply hooking the elbow with the fingers **(Figs. 23 and 24)**. Two fingers of the appropriate hand (right for right shoulder) are placed over the clavicle and swept round the point of shoulder that is traced down the humerus to the elbow and the forearm is thus made free. The baby is lifted by holding the ankle and keeping the index finger in between the ankles and the posterior arm is delivered in the same way. The extended arm is delivered by the classical method or Lovset maneuver



Fig. 24: Delivery of posterior arm.

JAYPEE BROTHERS

described later. Lovset maneuver is employed routinely by many irrespective of the status of hand.

8. Delivery of the aftercoming head—one of the following methods is employed to deliver the aftercoming head in breech presentation:
   - Burns-Marshall technique
   - Delivery with the help of forceps
   - Malar flexion and shoulder traction method (Mauriceau–Smellie–Veit technique)

Burns and Marshall technique (1934) (Figs. 25 to 32):
After the delivery of the shoulders, the baby is allowed to hang **(Figs. 25 and 26)** on its own weight for a brief period of time (1–2 minutes). In the meantime, the assistant is asked to give suprapubic pressure in downward and backward directions putting pressure more toward the sinciput so that the head is made more flexed. As soon as the nape of the neck or the hairline is visible under the pubic arch, the trunk of the baby is gradually lifted with steady traction and swung toward the mother's abdomen, making a wide arc of a circle by holding the baby's legs just above the ankles keeping a finger in between the two **(Figs. 27 to 32)**. In this method, the *pivot* should be the subocciput and not the neck. The left hand is kept over the perineum and the face and brow is gradually delivered **(Fig. 30)**. As soon as the mouth is seen, the mouth and pharynx are sucked with mucus sucker preventing the temptation of quick delivery of the head **(Figs. 31 and 32)**. The rest of the head is delivered by depressing the trunk toward the floor.

Delivery by forceps (Fig. 33):
- *Criteria to be fulfilled*: The head should be engaged and the occiput should lie against the back of the symphysis pubis (i.e., occiput directly anterior).

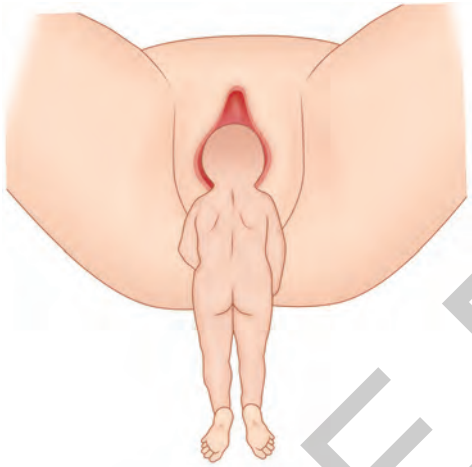

Fig. 25: Burns and Marshall technique—the baby is allowed to hang on its own weight for a brief period of time (1–2 minutes) (diagrammatic).



Fig. 26: Burns and Marshall technique—the baby is allowed to hang on its own weight for a brief period of time (1–2 minutes).

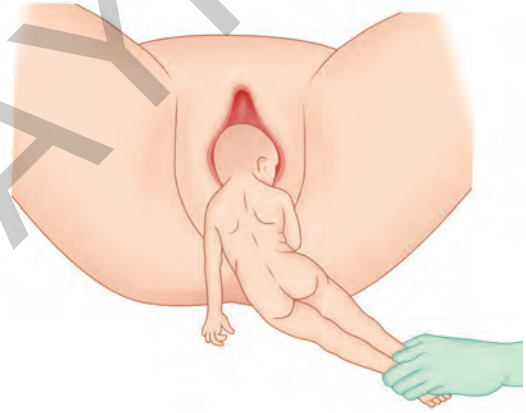

Fig. 27: Burns and Marshall technique—as soon as the nape of the neck or the hair line is visible under the pubic arch, the baby's legs are grasped just above the ankles keeping a finger in between the two.



Fig. 28: Burns and Marshall technique—the trunk of the baby is gradually lifted with steady traction and swung towards the mother's abdomen.

JAYPEE BROTHERS

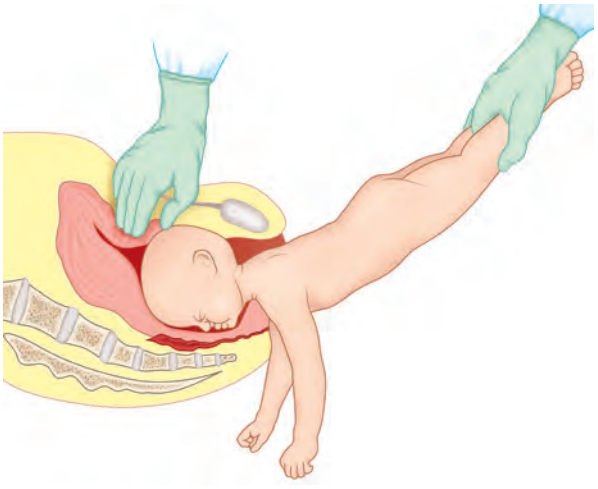

Fig. 29: Burns and Marshall technique—an wide arc of a circle is made.



Fig. 30: Burns and Marshall technique. Baby's mouth is released.



Fig. 31: Burns and Marshall technique. Baby's mouth is sucked as soon as it is released.



Fig. 32: Burns and Marshall technique—face is almost delivered.

- *Steps*: The assistant lifts the baby up by holding the legs, and then forceps blades are introduced from below the trunk of the baby **(Fig. 33)**. The pull of the forceps is given along the axis of the birth canal. This can be accomplished by Das's forceps or especially designed Piper forceps used for this purpose. The *Piper forceps* is devoid of pelvic curve.
- *Advantages*: Head can be delivered with controlled traction, flexion can be maintained in a better way, and head is delivered in a protective cage.
- *Disadvantages*: Rotation should be complete. Head must be at low down station.

Malar flexion and shoulder traction method (Mauriceau–Smellie–Veit technique) (Fig. 34)

Steps ***(Fig. 34)****:* Over the supinated left forearm, the baby is placed with the limbs hanging on both sides. The left index and the middle fingers are placed on either malar prominence of the baby. The index and ring fingers of the pronated right hand are forked over the shoulder on each side of the neck, and the middle finger is placed along the dorsum of the neck reaching up to the occiput. The fingers of the left hand maintain the flexion of the head, the index and ring fingers of the right hand provide main pull of the traction, and the middle finger of the right hand prevents extension. Holding in such a way, traction is given in downward and backward direction till the nape of the neck appears below the pubic arch following which the fetus is carried upward and forward toward the mother's abdomen delivering the face and brow. Then, the trunk is depressed to deliver the rest of the head. An *assistant gives suprapubic pressure* while pulling the head in the same way as Burns and Marshall technique.

Advantages: This procedure can be applied even when the head is high up and not necessarily in the anteroposterior direction

JAYPEE BROTHERS

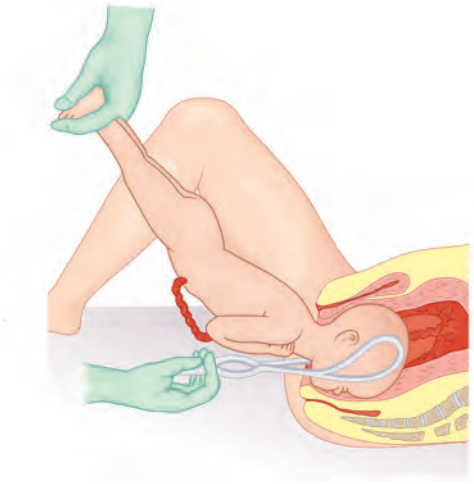

Fig. 33: Forceps in aftercoming head of the breech.

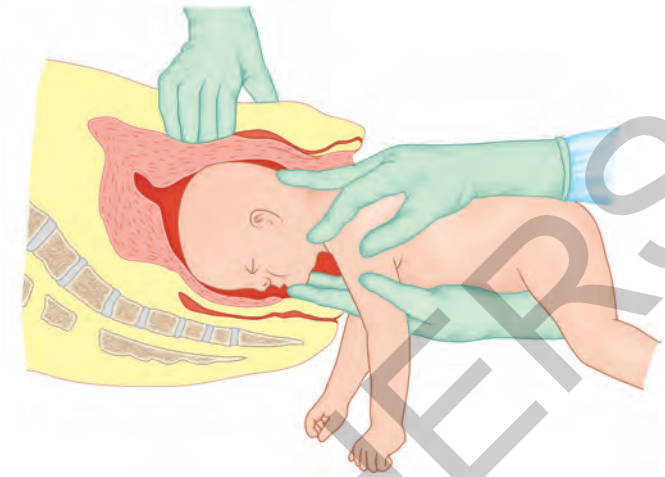

Fig. 34: Malar flexion and shoulder traction method.

(i.e., rotation is not completed). The baby may be asphyxiated and resuscitated. This method was originally known as "jaw flexion shoulder traction" where the index finger of the left hand was introduced into the mouth for hooking.

Of these three methods in delivery of aftercoming head of breech, no method is superior to other. It depends on the obstetrician's choice. When the Burns and Marshall technique fails, the head can be delivered by *malar flexion and shoulder traction* method. For forceps application, criteria must be fulfilled.

Delivery of the aftercoming head of breech is the most crucial part of delivery of the breech. Arrest of the aftercoming head of breech may result in either delivery of an asphyxiated baby or a stillborn baby. Sudden compression followed by sudden decompression during hurried delivery of fetal head may cause *intracranial hemorrhage*. Optimal time between the delivery from umbilicus and the mouth is *5–10 minutes* after which there is chance of asphyxia.

Third-stage Management in Assisted Breech Delivery

It is managed as usual. At this stage, active management of labor is done with Inj. oxytocin 10 IU IM after delivery of the fetus.

Usefulness of Episiotomy in Vaginal Breech Delivery

Episiotomy straightens the birth canal. It prevents the compression of the aftercoming head. It is essential for instrumental delivery and manipulation.

Bracht maneuver: Bracht maneuver (1935) is the delivery of breech with minimal interference. It has been described by Erich Bracht (1882–1969). The procedure involves spontaneous delivery only by supporting the baby's body against gravity during birth, without use of traction. The traction interferes with the normal mechanism of labor.

COMPLETE BREECH EXTRACTION

Hurried delivery of the baby is done by an obstetrician prior to engagement usually under GA. Groin traction is performed to deliver the podalic end. Lovset maneuver is employed routinely. Downward traction is done to bring the head in pelvis. All the stages of assisted breech delivery are done actively by the obstetrician Second baby of twin which is in transverse lie is delivered by breech extraction after IPV.

COMPLICATED BREECH DELIVERY

Arrest of Buttocks at the Perineum

The causes are weak uterine contraction, rigid perineum, large baby with extended legs, and pelvic outlet contraction.

Management if Arrest Occurs at the Perineum

It depends upon the causes. In weak uterine contraction, oxytocin infusion is started. In rigid perineum, episiotomy with groin traction is given. In breech with extended legs, groin traction is given. In case of pelvic outlet contraction, cesarean section can be done even at this stage.

Groin Traction (Figs. 35 and 36)

Indications are breech with extended legs and arrest at outlet. Types are single-groin traction and double-groin traction.

Procedure: Following episiotomy, the index finger is placed at the anterior groin and traction is given more toward the trunk than the femur. This is done during contractions. Simultaneous fundal pressure is also given. Anterior groin is manipulated at the beginning. Traction with the other index finger may also be given in the posterior groin when the buttocks are born. The traction is continued till the delivery up to the level of knee when the anterior leg is released followed by the posterior leg. Breech hook is applied only in the case of *dead fetus*. Groin traction is seldom practiced nowadays.

JAYPEE BROTHERS

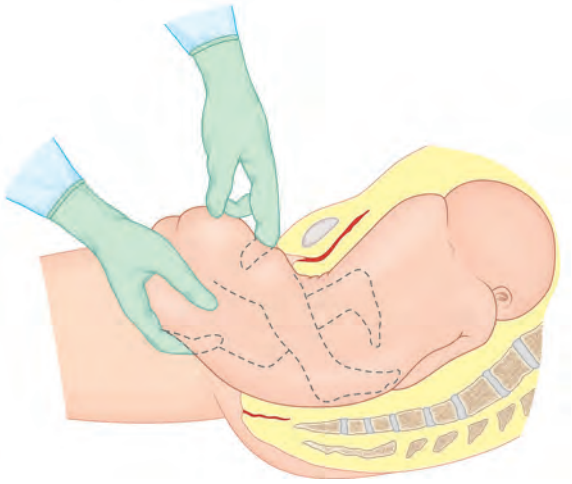

Fig. 35: Groin traction in frank breech (diagramatic).

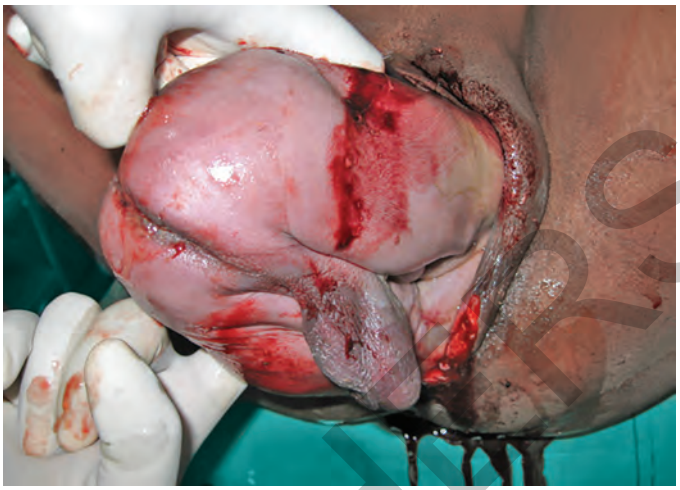

Fig. 36: Groin traction in frank breech.

Arrest of Buttocks in the Pelvic Cavity and Above

The causes are weak uterine contractions, large baby, contracted pelvis, combination of multiple factors such as extended legs, and weak uterine contractions. When buttocks in the pelvic cavity (ischial spine) and above it are usual than when cervix becomes fully dilated, buttocks should come to the perineum. If this does not occur, interference is needed. Cesarean section is the treatment of choice in this condition. However, *Pinard's maneuver* may be attempted in breech with extended legs.

Pinard's Maneuver (Frank Breech Extraction) (1889)

Indications: Breech with extended legs gets arrested in the pelvic cavity and above (groin traction is given when arrest occurs at the level of perineum).

Principle: It is the process of breech delivery which involves manipulation within the birth canal to convert a frank breech into a footling breech. It helps in bringing the fetal feet within the reach of the operator (bringing down the legs).

Procedure ***(Fig. 37)****:* The index and middle fingers are carried up to the knee (popliteal fossa); then pressure is exerted and leg is abducted. Spontaneous flexion usually occurs and then the foot is grasped and brought down. The hand is chosen in such a way that the palmer aspect will face the ventral aspect of the fetus. This procedure should be done under anesthesia.

Delay In Delivery of the Shoulder

Reasons are mainly due to extended arms with lateral or dorsal (nuchal) displacement. Extension of the arms occurs mostly due to unnecessary pulling of fetus from below during delivery. The principle "Don't traction from below but push from above" is followed to avoid extension of arms. Diagnosis is done by observing the winging of scapula and absence of the fetal arms in front of the chest of the fetus.

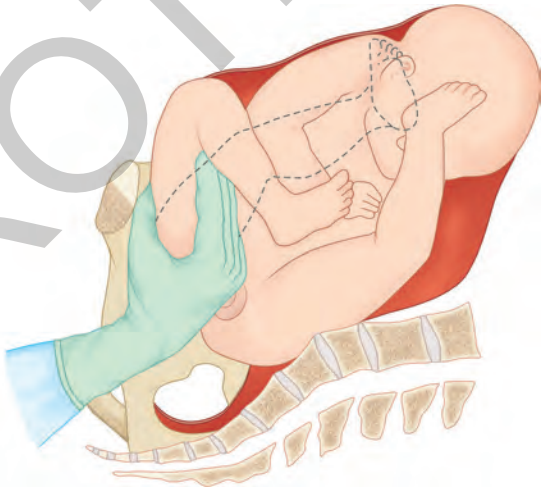

Fig. 37: Pinard's maneuver for bringing down a leg.

Management of breech with extended arms are classical method or Lovset maneuver.

Classical Method

Principle: By internal manipulation, the posterior arm is brought down first followed by the anterior one.

Procedure: General anesthesia is administered. The choice of hand to be introduced is one that corresponds to the back of the baby. The angle of the anterior shoulder is brought under subpubic angle by pulling the fetus. The baby's trunk is lifted along the ventral aspect of the baby by holding the ankles. The index and middle fingers of the selected hand are introduced along the posterior arm till the elbow is reached. Then the fingers are applied as splint to the posterior arm which is pushed over the face of the baby and then gradually pulled down. The extended anterior arm is pushed down by introducing the other arm in similar fashion while the baby's trunk is depressed toward the perineum. In case of dorsal or nuchal displacement, the baby's trunk is rotated so that the arm is made posterior and delivery is done as previously.

JAYPEE BROTHERS

Lovset Maneuver (Figs. 38 to 41)

Lovset maneuver is one of the methods of bringing down the extended arms (1937) during breech delivery.

Principle: The method is based on taking advantage of configuration of pelvic architecture where the lower part of the anterior wall of pelvis is deficient. When the posterior shoulder which lies below the sacral promontory is rotated forward, it would appear below the symphysis pubis and can be delivered easily. The other shoulder can also be delivered by rotation of the trunk in reverse direction.

Prerequisites are that the inferior angle on the anterior scapula must come below the symphysis pubis before attempting the procedure. The shoulder should lie in the anteroposterior diameter of the pelvis. The posterior shoulder should lie below the sacral promontory.

Procedure

Step I: The trunk of the baby is grasped with *femoropelvic grip* keeping medial sides of the thumbs parallel to each other. The buttock is slightly elevated anteriorly at first, thus maintaining the downward pull to make lateral flexion of the trunk. This will bring the posterior shoulder much below the sacral promontory. The trunk of the baby is rotated 180° keeping the back anterior. The completion of rotation will bring the posterior shoulder to emerge below the symphysis pubis and then brought down by hooking.

Step II: The other shoulder is then delivered by rotation of the trunk in reverse direction keeping the back anterior.

Advantages are that no internal manipulation is needed, no GA is required, it can be done when the classical method is difficult, and it is safe and easy to do.

Entrapment of the Aftercoming Head of Breech

This is the most crucial condition as it causes compression of the umbilical cord, and until and unless delivered quickly the baby will be asphyxiated or will die. The causes are deflexed head, large baby, occipitoposterior position, hydrocephalus,

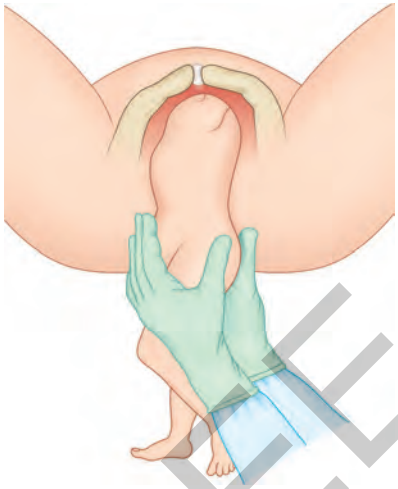

Fig. 38: Lovset maneuver. Trunk is grasped with femoro pelvic grip, slightly elevated anteriorly and then rotated 180°.

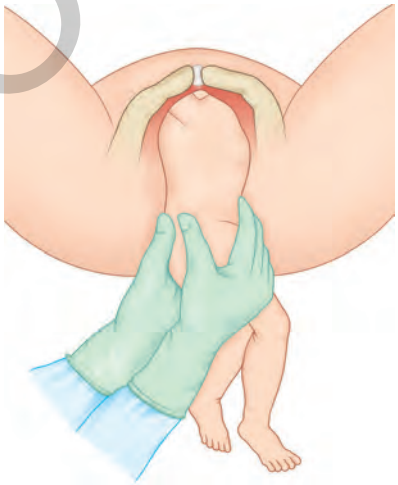

Fig. 39: Lovset maneuver. Posterior shoulder emerges below symphysis pubis as anterior.

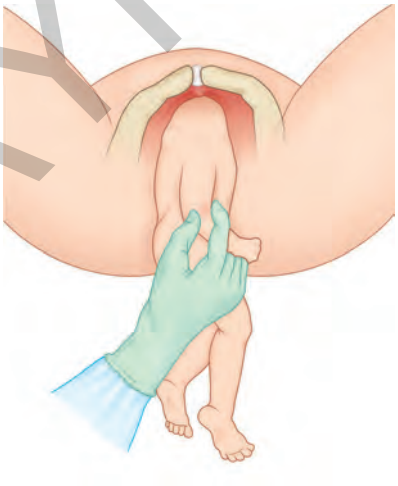

Fig. 40: Lovset maneuver. The shoulder is delivered and again trunk is rotated 180° in reverse direction.



Fig. 41: Lovset maneuver. The other shoulder is delivered below the symphysis pubis.

JAYPEE BROTHERS

rigid perineum, incompletely dilated cervix, and pelvic contraction.

Management depends on the cause. If it is due to rigid perineum, episiotomy is given. If needed, either forceps delivery or malar flexion shoulder traction is done depending upon the station of the head. If it is only for deflexed head if the head is in the pelvic cavity, episiotomy and forceps are given to deliver fetal head.

When head is high up, it is delivered by malar flexion and shoulder traction. If the cause is large baby, malar flexion and shoulder traction may be attempted. In occipitoposterior position, the fetal trunk and head are rotated to bring back of the fetus to anterior. If not possible (in case of premature baby), the head is delivered face to pubis by reverse jaw flexion and shoulder traction maneuver (Prague maneuver) **(Fig. 42)** or by forceps. Prague maneuver is the reversed malar flexion and shoulder traction method.

In hydrocephalus, perforation of the head is done. In incompletely dilated cervix which usually occurs in the case of small premature baby, the cervix may be manually slipped over the occiput while giving gentle traction on the fetus (shoe-horn method). **Figures 43 to 45** show arrest of aftercoming head in undilated cervix in prolapsed uterus and living baby was delivered vaginally by manual slipping over the occiput.

If this fails, *Duhrssen incisions* at 10, 2, and 6 o'clock positions are given **(Fig. 46)**. The positions are so selected that bleeding from laterally located cervical branches of the uterine artery is minimum. After delivery, the cut margins are repaired.

Contracted pelvis: Malar flexion and shoulder traction method may be tried in minor contractions. If the pelvic contraction is significant, the baby usually dies and craniotomy is done to deliver it.



Fig. 42: Prague maneuver.



Fig. 43: Arrest of aftercoming head of breech in undilated cervix in a case of genital prolapse.
Courtesy: Dr Anirban Mondal, Associate Professor, Bankura Sammilani Medical College and Hospital, Bankura, West Bengal, India.



Fig. 44: Cervix is manually slipped over the occiput to deliver the aftercoming head as in the patient (Figure 43).

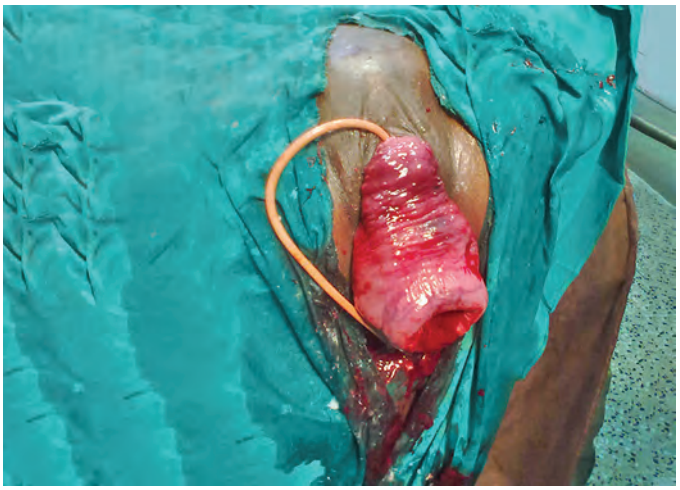

Fig. 45: Prolapsed cervix atter delivery as case in Figures 43 and 44. Look, there is no injury of cervix.

JAYPEE BROTHERS

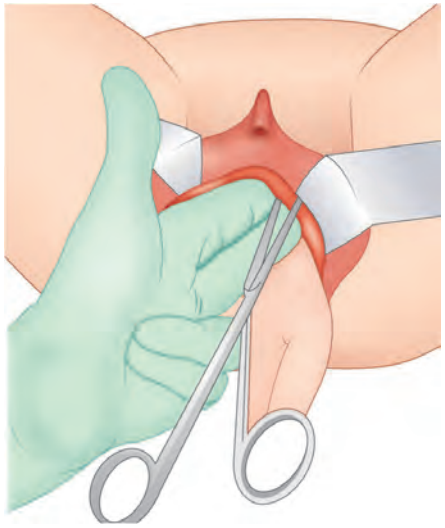

Fig. 46: Duhrssen incisions.

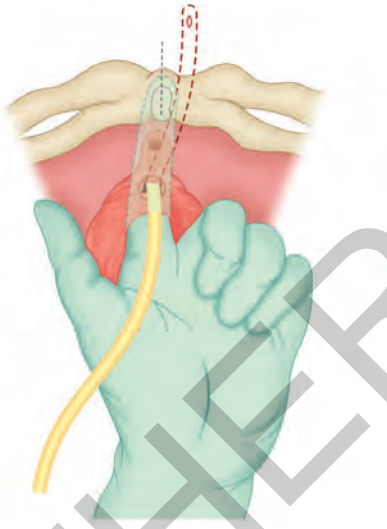

Fig. 47: Symphysiotomy—catheterization done and finger is kept behind symphysis pubis.

Symphysiotomy (Figs. 47 and 48)

Though rarely done, in case of arrest of aftercoming head of breech, symphysiotomy may be practiced deliberately to enlarge the anterior pelvis to complete the delivery. The details are given in chapter 13.

Zavanelli Maneuver

Zavanelli maneuver is a method by which the fetus is replaced into the vagina and uterus, and cesarean delivery is accomplished. It is classically practiced in shoulder dystocia.

CESAREAN DELIVERY IN BREECH PRESENTATION

Cesarean delivery in breech presentation is not without risk to the baby and the same type of injury may occur as encountered in vaginal breech delivery. Long bone fracture is common in abdominal breech delivery.

Procedures and Precautions During Cesarean Delivery

Laparotomy incision should be adequate and uterine incision should be generous.

In preterm fetus, the lower uterine segment is not well formed, especially when the patient is not in labor. If the lower uterine segment is not wide, it is better to give vertical incision than to extend by T-shaped or H-shaped incision.

In case of frank breech, buttock is lifted through uterine wound and is delivered in leg-extended condition by hooking the index finger inside groin and applying traction. Simultaneously, the back of the fetus is made anterior.

In case of incomplete breech, the feet are delivered one by one; then traction is given holding both the feet. Once the buttock comes outside, the fetus is held in femoropelvic grip



Fig. 48: Symphysiotomy—symphysis pubis is severed by scalpel.

by placing the fingers on iliac crest and this will protect fetal abdominal structure from compression.

The arms are delivered one after another by simply hooking the elbow with the fingers. Two fingers of the appropriate hand (right for right shoulder) are placed over the clavicle and swept round the point of shoulder that is traced down the humerus to the elbow and the forearm is thus made free. Arms can be delivered by rotating the trunk in Lovset maneuver fashion when hands are extended.

Aftercoming head is delivered by malar flexion and shoulder traction method (Mauriceau–Smellie–Veit technique) or by using forceps (Piper). In all cases, the neck should not be extended. Forceps are applied below the body of the fetus keeping the operator's hand inside the uterus. After articulation, head is delivered by flexion.

All manipulations should be gentle, slow, and not to be hurried avoiding mishandling of the fetus.

JAYPEE BROTHERS

TRANSVERSE LIE

INTRODUCTION

Transverse lie or shoulder presentation is not uncommon in clinical practice. Premature rupture of membranes, cord prolapse, and obstructed labor are the consequences if unattended and not cared for in time. Cesarean delivery is the mode of delivery for term fetus. External version may be tried at term or in early labor where feasible. IPV can be done for second baby of twin in transverse lie provided the liquor is adequate. With the improved obstetric care, the incidence of neglected shoulder presentation has become less; still it is seen some developing countries and referred from rural areas.

The incidence of shoulder presentation is near 3 in 1,000 deliveries at term.

DEFINITION

Lie is said to be transverse when the long axis of the fetus lies perpendicular to the long axis of the maternal spine or centralized uterus. When the long axis of the fetus forms an acute angle, it results in oblique lie. In labor, the oblique lie becomes either longitudinal or transverse; therefore, oblique lie is usually transitional.

In transverse lie, the shoulder lies over the pelvic inlet; hence, it is called shoulder presentation.

ETIOLOGY

Transverse lie may be due to maternal factors and fetal factors. No obvious cause is detected in a significant number of cases.

Maternal causes are multiparity with lax abdomen—10-fold increase with four or more deliveries, contracted pelvis, placenta previa, uterine anomaly—subseptate or arcuate, hydramnios, and pelvic tumor.

Fetal causes are prematurity, multiple pregnancy, intrauterine fetal death, and fetal congenital anomaly.

DIAGNOSIS

Diagnosis is based on clinical findings and by sonography. There is no such history specific to transverse lie; few patients may present with premature rupture of membranes, cord prolapse, and hand prolapse some may present with bleeding per vagina if associated with placenta previa.

Per Abdominal Examination

On inspection, uterus looks broad and transversely oval.

On palpation **(Fig. 49)**, the height of the uterus is less than the period of amenorrhea and symphysiofundal height is less than expected in longitudinal lie. The fundal and pelvic grips are empty, head is palpated on one side of midline or obliquely on one or other iliac fossa by lateral grip and breech on the other side.

Per Vaginal Examination

(It should only be done after exclusion of placenta previa)

Patient not in labor—presenting part is at higher level from the cervix and fornix. Only some soft parts are palpable with difficulty.

Patient in labor:

- *In early stage*: There may be an elongated bag of membranes. The side of the thorax, if approachable, may be identified by the "grid iron" feel of the ribs.
- *With cervical dilatation*: Following rupture of membranes, shoulder presentation is diagnosed by the palpation of the acromion process, scapula, clavicle, and axilla **(Fig. 50)**. The position of the axilla indicates the side of the mother toward which the shoulder is situated. There may be prolapse of the hand and arm **(Figs. 51 to 53)**.
- There may be presence of cord prolapse.

Prolapsed hand may also be found in case of compound presentation like with head and breech **(Figs. 54 and 55)**.

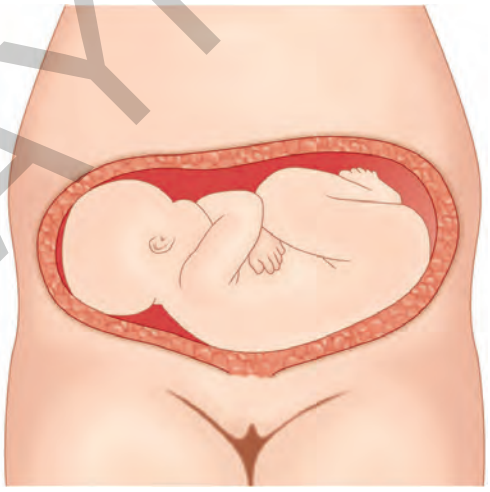

Fig. 49: Transverse lie.

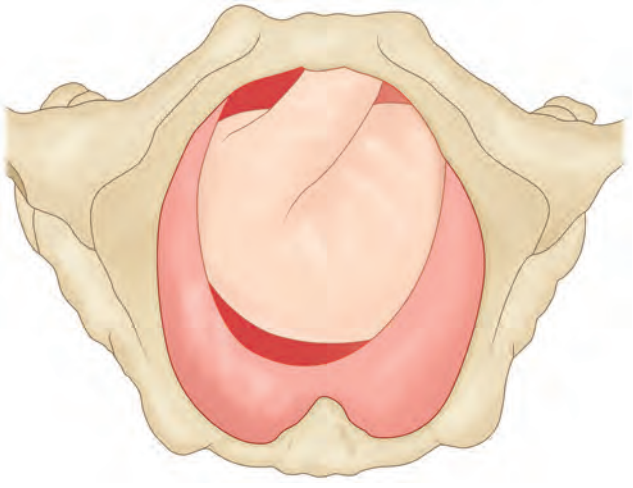

Fig. 50: Vaginal findings of shoulder presentation (Dorsoposterior).

JAYPEE BROTHERS



Fig. 51: Transverse lie with hand prolapse.

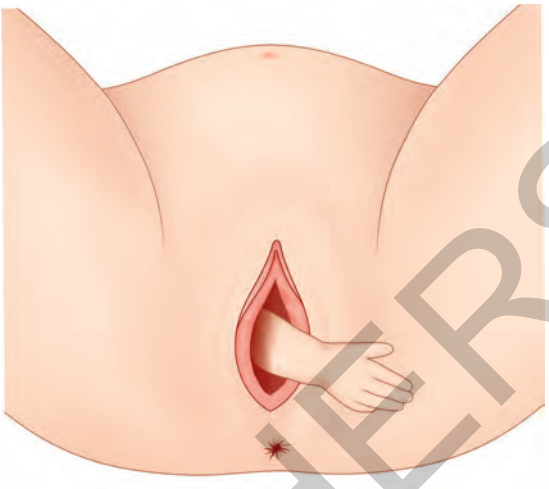

Fig. 52: Prolapsed hand visible through perineum.



Fig. 53: Hand prolapse in transverse lie.
Courtesy : Dr Abhisek Bhadra, Assistant Professor, Calcutta Medical College, Kolkata, West Bengal, India.

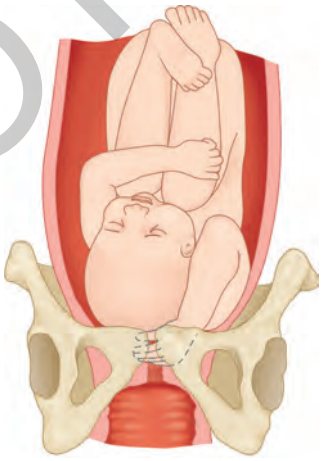

Fig. 54: Compound presentation—hand below the head.



Fig. 55: Compound presentation—hand below the head.
Courtesy: Professor SL Seal, Department of Gynecology and Obstetrics, RG Kar Medical College, Kolkata, West Bengal, India.

Determination of Position of Fetal Head by the Prolapsed Hand

In outstretched hand when the palm points toward the fetal abdomen, the direction of the thumb indicates the direction of the fetal head.

Sonography

Diagnosis of transverse lie is confirmed by sonography. The other advantages of sonography are the same as in breech presentation.

MECHANISM OF LABOR IN TRANSVERSE LIE

Denominator in case of transverse lie is the back of the fetus. There may be eight positions in transverse lie:

1. (Right acromion) Dorsoanterior **(Fig. 56)**
2. (Left acromion) Dorsoanterior

JAYPEE BROTHERS

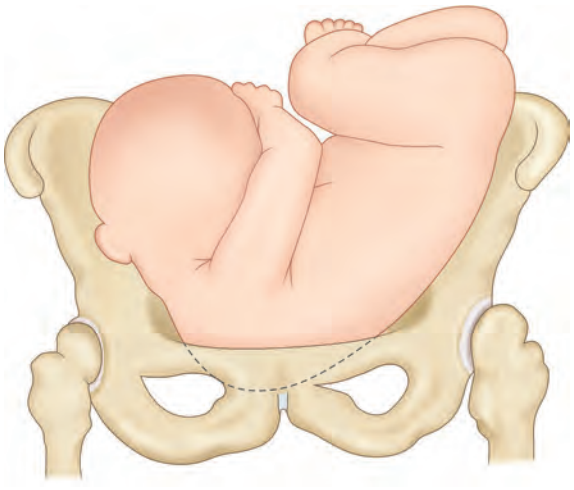

Fig. 56: Dorsoanterior (right acromion) shoulder presentation (most common).

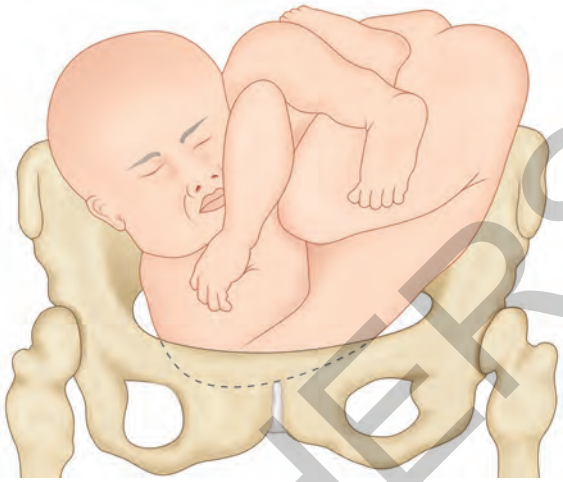

Fig. 57: Dorsoposterior (right acromion) shoulder presentation.

3. (Right acromion) Dorsoposterior **(Fig. 57)**
4. (Left acromion) Dorsoposterior
5. (Right acromion) Dorsosuperior
6. (Left acromion) Dorsosuperior
7. (Right acromion) Dorsoinferior
8. (Left acromion) Dorsoinferior

The last four are very rare. The dorsoanterior (60%), either right or left, is the most common position as the ventral aspect of the fetus fits well against the convexity of maternal spine. The left one is more common than the right.

Spontaneous vaginal delivery is not possible in case of mature fetus in transverse lie. If the labor progresses, it is inevitable that obstructed labor will occur (unfavorable outcome). In very rare instances when the fetus is small (<800 g), spontaneous delivery is possible by a special mechanism (see here).

RISKS OF TRANSVERSE LIE

Risks of transverse lie are early or premature rupture of membrane, chance of cord prolapse, hand prolapse **(Figs. 53 and 58)**, and development of obstructed labor and its consequences.

Maternal risks are dehydration, ketosis, sepsis, shock, hemorrhage, chances of operative interference, and rupture of uterus.

Fetal risks are increased perinatal morbidity and mortality (25–50%) due to cord prolapse, dry labor and tonic uterine contraction, prolonged labor, and rupture of uterus.

In dorsoposterior position, the chance of fetal extension is more; hence, there is more chance of hand prolapse.

OUTCOME OF TRANSVERSE LIE FOLLOWING LABOR

If labor is allowed to continue uncared for in case of mature fetus with persistent transverse lie, rupture of membranes occurs with drainage of liquor. There may be cord prolapse



Fig. 58: Hand prolapse and cord prolapse together.

→ fetal shoulder is forced into the pelvis → corresponding arm is prolapsed → more descent → shoulder is arrested in the pelvic inlet with head in one iliac fossa and breech in the other → shoulder is wedged and impacted in the pelvis → vigorous uterine contraction → features of obstructed labor with formation of a pathological retraction ring → neglected shoulder presentation results **(Fig. 59)** → if left uncared for, the mother gets exhausted with dehydration, ketosis and sepsis, and the fetus usually dies → rupture of uterus occurs specially in multigravida.

FAVORABLE OUTCOME IN TRANSVERSE LIE

In a very small fetus (weight <800 g), spontaneous vaginal delivery may occur by the following:

- *Spontaneous version or rectification*: It is the sudden correction of the lie after the onset of labor where uterine contraction forces the head (rectification) or breech by

JAYPEE BROTHERS

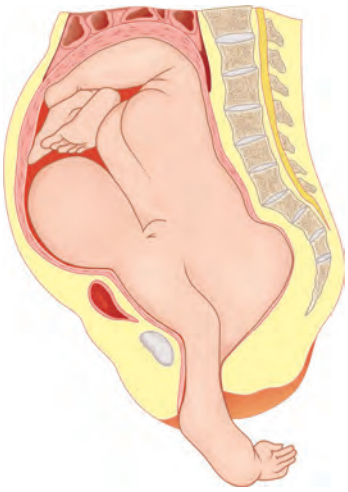

Fig. 59: Neglected shoulder presentation.



Fig. 60: Spontaneous evolution.

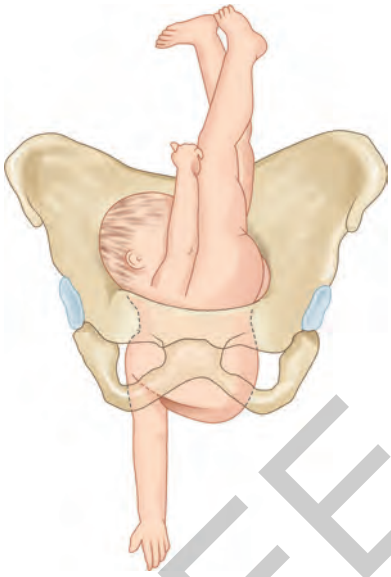

Fig. 61: Spontaneous expulsion or conduplicato corpore.

version to come into the pelvic inlet. It may occur when the liquor amount is good.

- *Spontaneous evolution* **(Fig. 60)**: When the contraction is vigorous, breech and trunk are delivered first followed by the delivery of the head.
- *Spontaneous expulsion or conduplicato corpore* **(Fig. 61)**: In this condition, the spontaneous expulsion of fetus occurs after *doubling up* at the trunk. It occurs rarely.

MANAGEMENT OF PREGNANCY WITH TRANSVERSE LIE

Definitive Management of Transverse Lie in Antenatal Period

External cephalic version is the treatment of choice after 36 weeks if there is no contraindication or co-complication.

Some prefer attempt of ECV only after 39 weeks because there is a high chance of spontaneous version if done earlier.

In case of Rh-negative mother, Rh anti-D immune prophylaxis is given.

If ECV is contraindicated or it fails, elective cesarean section is performed at term. The patient is admitted at 37 weeks. The version can be repeated before lower uterine cesarean section (LUCS) if there is no contraindication.

Transverse Lie with Mature Baby in Early Labor

When the mother is in early labor, the membranes are intact. ECV is attempted, if there is no other complication or contraindication for ECV. Following version, the head should be held in the pelvis during the next several contractions in an attempt to fix the head. If ECV fails or is contraindicated, cesarean section is performed. With ruptured membranes, delivery by cesarean section is the preferred option.

Transverse Lie with Mature Fetus in Late Labor

If the baby is alive, *cesarean section* is the most preferred method. However, if the membrane is intact, ECV may be attempted. When the cervix is fully dilated, IPV under GA is an option to deliver the baby immediately after the rupture of membranes although not preferred in case of singleton pregnancy. *In the modern-day obstetrics, the role of IPV is limited only to the second baby of twin in transverse lie.*

If the baby is dead, destructive operation, either decapitation (when neck is approachable) or evisceration (when neck is not approachable), is done. Uterine cavity is routinely explored following destructive operation. However, when the obstetrician is not well conversant with destructive operation, cesarean section is the safer method of delivery even for dead baby.

INTERNAL PODALIC VERSION

Internal podalic version is a type of version which is done through the vaginal approach, and the podalic end is drawn

JAYPEE BROTHERS

inside the vagina to make the presentation breech and the lie longitudinal. Following version, the baby is delivered by breech extraction.

Indications

In modern obstetrics, the only indication of internal podalic version is *second baby twin which is in transverse lie (shoulder presentation)*. However, any small or dead fetus in shoulder presentation can be delivered through the vaginal approach by IPV. In singleton pregnancy, IPV is not done nowadays. Very rarely, vertex presentation with cord prolapse IPV is done.

Criteria to be Fulfilled before Attempting Internal Podalic Version

Cervical os must be fully dilated (patient is in second stage).

There should be good relaxation of the uterus. There should be presence of sufficient liquor amnii. Membranes are immediately ruptured or attempt of IPV is done just after rupturing the membranes.

When there is no liquor, attempt of IPV will be dangerous which may result in ruptured uterus.

Fetus should be alive. Obstetrician must be experienced in this procedure.

Contraindications of Internal Podalic Version

Contraindications are neglected shoulder presentation, absence of liquor amnii, and pregnancy with prior cesarean delivery.

Procedures of Internal Podalic Version (Figs. 62 and 63)

- It should always be done at the operation theater and under GA.
- Patient is in lithotomy position. Antiseptic dressing, draping, and catheterization are done.
- *Choice of hand*: The hand which is on the side of the podalic end is the internal hand. Like in shoulder presentation, if the podalic end is on the left side of the patient, the right hand is to be introduced.
- The appropriate hand is introduced in a cone-shaped fashion separating the labia with the other hand outside the uterus. A foot is grasped and pulled down by holding the ankle. The foot is then identified by the palpation of the heel. The leg which comes first is drawn first.
- The other (external) hand is placed over the head per abdomen, and the head is pushed toward the fundus so that the fetus is made longitudinal and the leg is drawn inside the vagina with a steady traction.
- The other leg is brought down easily after the first leg. The fetus is delivered by breech extraction following IPV.
- Following delivery of the placenta, the uterine cavity is explored to exclude the rupture of uterus.

Dangers of Internal Podalic Version

- Rupture of the uterus
- Postpartum hemorrhage
- Shock
- Infection
- Fetal complications—fetal asphyxia and fetal death

DIFFICULTY IN CESAREAN DELIVERY IN TRANSVERSE LIE

As no pole lies in the lower uterine segment, *it is not well formed* and so low transverse cesarean section approach leads to the difficulty of extraction of the fetus. By grasping the legs first (podalic end), the baby is delivered as breech delivery. Transverse uterine wound may be extended by "J"-shaped incision or by inverted "T." "J"-shaped incision

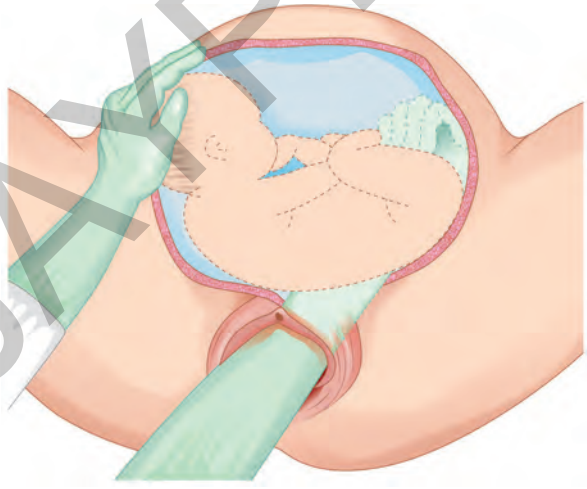

Fig. 62: Internal podalic version (IPV). A foot is grasped and pulled down by holding the ankle.



Fig. 63: Internal podalic version (IPV)—the head is pushed by outer hand towards the fundus so that the fetus is made longitudinal and the leg is drawn inside the vagina gently.

JAYPEE BROTHERS

is preferred to inverted "T." Vertical incision is also preferred by many obstetricians. (See Chapter16 of Cesarean Delivery)

NEGLECTED SHOULDER PRESENTATION (FIGS. 59 AND 64)

Neglected shoulder presentation or neglected transverse lie is a situation comprising several complications that develop due to uncared for and unattended labor in a shoulder presentation. The sequences are impaction and wedging of the shoulder → obstructed labor → dehydration, ketosis, sepsis → ruptured uterus.

Management aims at prevention of the condition by managing the shoulder presentation in early labor. In established cases, first the resuscitation of mother is done with IV fluid, antibiotics, and blood transfusion followed by delivery of the baby.

Method of Delivery in Neglected Shoulder Presentation

When the baby is dead (which invariably occurs in almost all cases), destructive operation, either decapitation or evisceration (see Chapter 26 of Destructive Operation), is performed provided there is no ruptured uterus or impending rupture. In cases of suspected rupture or impending rupture or when the obstetrician is not well conversant with the procedure, laparotomy and cesarean delivery are done. Internal podalic version should never be attempted in neglected shoulder presentation.



Fig. 64: Hand prolapse in neglected shoulder presentation.

JAYPEE BROTHERS

for detailed information on obstetrics & gynecology books, visit our website www.jaypeebrothers.com, for detailed information on obstetrics & gynecology books, visit our website www.jaypeebrothers.com, for detailed inform

OPERATIVE OBSTETRICS
AN ILLUSTRATED MANUAL

This book is written realizing the need of an operative obstetrics with surgical details with titbits of every step with abundant illustrations both original and diagrammatic. This manual consists of 30 chapters starting from basic surgical skill development to postoperative complications. Each area of obstetrics which is associated with maneuvers and operative procedures has been covered with relevant theoretical background with the latest information and description of maneuvers and procedures. In each procedure the indications, preoperative considerations, detailed steps, postoperative management, potential complications and their prevention and management have been described in lucid language with case scenario in many cases. The book is incorporated with 278 original figures and 531 drawing arts which have made understandable, more live and attractive. The author has shared his experiences and also from his colleagues to make this manual practical as far as possible.

This book will be very useful for postgraduates and also for all obstetric practitioners in the day-to-day practice to tackle the versatile clinical situations and also to keep them updated.



Arup Kumar Majhi is a renowned Professor in Obstetrics and Gynecology now at Santiniketan Medical College, Bolpur, Birbhum, West Bengal, India. He was Former Head, Department of Obstetrics and Gynecology, RG Kar Medical College and Hospital, Kolkata with a teaching experience of more than three decades in different Government Medical Colleges and Hospitals. From the very early days of his medical career, he had a special interest in teaching both undergraduate and postgraduate students. He is well-known for his extraordinary teaching capability, clinical acumen, decision making, surgical skills and sincerity to the patients. He is an Examiner, for both undergraduate and postgraduate examinations of different universities of India including DNB. He is very popular in the Obstetrics and Gynecology fraternity and also amongst his students for his academic and teaching skills. He is also the author of *Bedside Clinics in Gynecology* published by Jaypee Brothers Medical Publishers and *Bedside Clinics in Obstetrics*, published by Academic Publishers. He is the National President Elect, ISOPARB (Indian Society of Perinatology and Reproductive Biology); and Past President, Bengal Obstetric and Gynecological Society. A regular contributor to various journals, he has to his credit around 100 articles in national and international journals and books. He is the Emeritus Editor of Indian Journal of Perinatology and Reproductive Biology and past National Corresponding Editor of Journal of Obstetrics and Gynecology of India (FOGSI Journal).

Printed in India

Available at all medical bookstores
or buy online at www.jaypeebrothers.com

JAYPEE BROTHERS
Medical Publishers (P) Ltd.
EMCA House, 23/23-B, Ansari Road,
Daryaganj, New Delhi - 110 002, INDIA
www.jaypeebrothers.com

Join us on facebook.com/JaypeeMedicalPublishers

Shelving Recommendations
OBSTETRICS & GYNECOLOGY

ISBN 978-93-5465-988-1