65th All India Congress of
Obstetrics & Gynaecology

AICOG 2023 Workshop Manual

Scopy in Gynecology

Series Editors
Bhaskar Pal
Basab Mukherjee
Dibyendu Banerjee
Kusagradhi Ghosh

Volume Editors
Abhinibesh Chatterjee
Amit Basu
Arnab Kumar Basak
Subhash Chandra Biswas

aicog 2023 | Kolkata
Creating Tomorrow Together

Organized by:
The Bengal Obstetric and Gynaecological Society
04–08 January 2023
Biswa Bangla Mela Prangan, Kolkata

JAYPEE

Contents

1. **Basics of Laparoscopy 1**
   Sanket Pisat, Pranay Desai
2. **Basics of Hysteroscopy 10**
   Pandit Palaskar, Apurva Rodge
3. **Laparoscopic Management of Adnexal Masses 18**
   B Ramesh, Minal Kumbhalwar, Priyanka Das, Kiran R Konda
4. **Laparoscopic Management of Ectopic Pregnancy 27**
   Kusum Lata, Isha Kriplani, Alka Kriplani
5. **Laparoscopic Management of Endometriosis (Practical Tips) 36**
   Sanjay Patel, Smeet Patel, Prakshal Shah
6. **Laparoscopic Hysterectomy in Different Scenarios 53**
   PG Paul, George Paul
7. **Laparoscopy in Urogynecology 61**
   Amita Jain
8. **Operative Hysteroscopy 66**
   S Krishnakumar, Anurag Bhate
9. **Benign Gynecological Surgeries and the Role of Robotics 84**
   Rooma Sinha, Rupa Bana
10. **Laparoscopic Nerve Sparing Radical Hysterectomy 91**
    Shailesh Puntambekar, Madhavi Patil, Ravindra Sathe, Seema Puntambekar, Mihir Chitale, Aishwarya Puntambekar

Chapter 2

Basics of Hysteroscopy

Pandit Palaskar, Apurva Rodge

INTRODUCTION

Hysteroscopy is perhaps the simplest yet most hazardous procedure a gynecologist must perform. The most important prerequisites for starting hysteroscopy are—knowledge of uterine and cervical anatomy, instruments, distending media, managing complications and signs of fluid overload.

Hysteroscopy was performed first in 1869 when Pantaleoni visualized polypoidal tumor in uterus. Later Rubin used cystourethroscope to visualize the uterus. He used water to distend the uterus, later he used CO_2.

INSTRUMENTATION (FIGS. 1 TO 5)

Hysteroscope consists of parts such as telescope, eyepiece, barrel and objective lenses. Angle options are 0, 12, 15, 25, 30 and 70°. 0° provides a panoramic view. Angled one improves the view of ostia in an abnormally shaped uterus. Various designs are available such as Bipartite design containing inner and outer sheaths. In which there are independent inflow and outflow channels for distention media. This helps to flush the uterine cavity and maintain a clear field of vision.



Fig. 1: Diagnostic hysteroscopy set.

JAYPEE BROTHERS

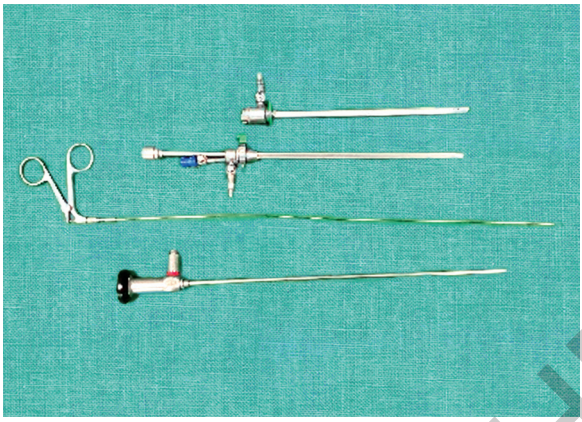

Fig. 2: Operative hysteroscopy set.

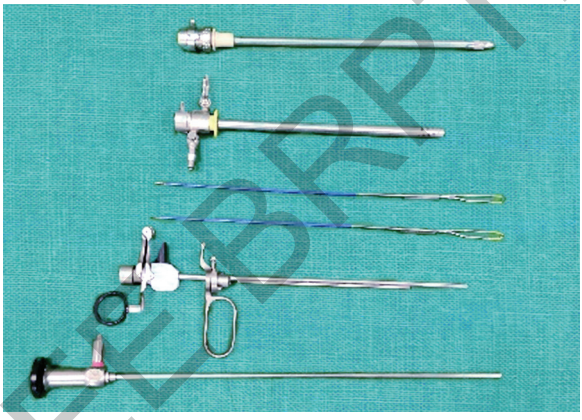

Fig. 3: Resectoscope.

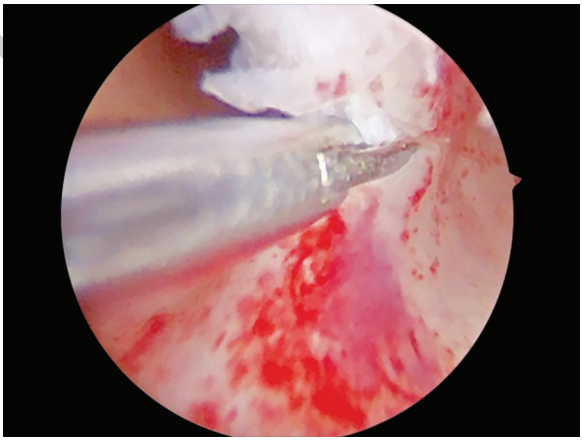

Fig. 4: Septum resection with scissor.

JAYPEE BROTHERS

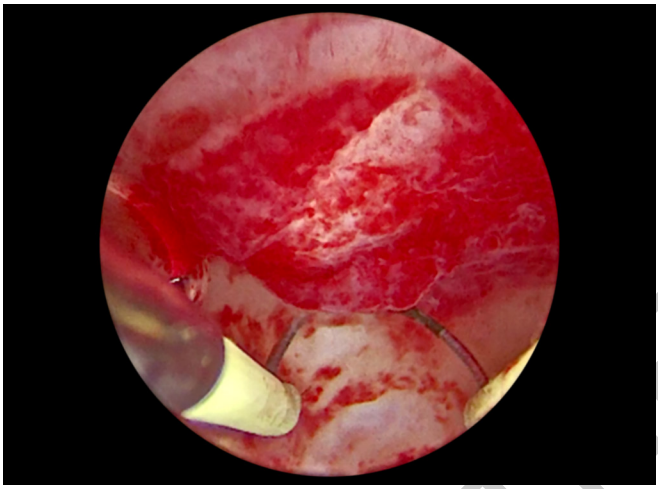

Fig. 5: Myomectomy with resectoscope.

Many types of hysteroscopes are available in many sizes such as flexible, rigid and semi-rigid.

Flexible hysteroscope: It is mostly used for office hysteroscopy. Tip can bend up to 120–160° to allow better visualization. Light and image bundle within the scope transmit light into the uterus and return to eyepiece.

Diagnostic scopes have a single channel for distention medium, while operative hysteroscopes have another channel for instrumentation. The outer diameter varies from 3.1 to 5 mm. Narrow diameter enables introduction into the uterine cavity without anesthesia and also reduces the need of cervical dilatation and manipulation, reduces pain and complications.

Rigid hysteroscope: It contains complex optical telescope element. Glass lenses and spacers are aligned precisely in between the ocular lens and objective lens at the distal tip. The diameter of telescope ranges from 1.9 mm to 4 mm. The outer diameter of sheath ranges from 3 mm to 8 mm.

Diagnostic sheaths: These sheaths are used to deliver the distention media. They fit by means of water-tight seal lock. It is 4–5 mm in diameter with 1 mm clearance between the inner wall and the telescope through which the distention media is transmitted.

Operative sheath: Larger diameter is 7–10 mm. This allows space for instillation of medium, the telescope and for the insertion of operating device.

Operative hysteroscopy instruments: Instruments needed for operative hysteroscopy are hysteroscope (rigid and 30°), operating sheath 6 F, accessory instruments—grasping forceps, biopsy forceps, scissors, monopolar and bipolar electrodes. Various tubal cannulation catheters are used for proximal tubal cannulation.

JAYPEE BROTHERS

Resectoscope: This is a very versatile instrument in operative hysteroscopy. It consists of operating channels, working elements and electrodes. Electrodes are of different types—Collin's knife, cutting loop, barrel, and ball type. Resectoscope can be monopolar or bipolar depending on the type of energy used for electrosurgery. Nowadays there is a trend of using bipolar resectoscopes, as normal saline is used as distending media.

Hysteroscopic morcellator: This instrument uses mechanical energy, which easily removes polyps, submucous fibroid and other intrauterine pathology quickly. There is no need of energy source, so no damage to endometrium. The only limiting factor for morcellator is that it is very costly.

Light source: The commonly used light sources are halogen, Xenon or LED.

High definition (HD) medical grade camera: To have better vision and outcome during hysteroscopy, high definition (HD) camera is essential along with data capturing systems.

OFFICE HYSTEROSCOPY

Office hysteroscopy uses miniature hysteroscope (2.9 mm). It does not require cervical dilation and is performed by vaginoscopic technique without any catch on cervix. It is usually done in an office setting without using operating rooms. It does not require anesthesia, though local anesthesia, mild sedation and analgesics can be given. Minor pathologies such as polyps, small type 1–2 fibroids, septum resection, endometrial biopsy can be treated with office hysteroscopy. So, this procedure is more cost effective.

Energy Sources in Hysteroscopy

- *Monpolar electrosurgery:* This can be used for septum resection, myomectomy, adhesiolysis, lateral metroplasty, etc. Glycine is commonly used as distention media.
- *Bipolar electrosurgery:* Bipolar energy is relatively safe, but the electrodes are costly; normal saline can be used as distention media.
- *Laser:* Lasers can be used for hysteroscopic surgery such as septum resection, endometrial ablation, if available. Commonly used lasers are ND:YAG, KTP laser.

DISTENTION MEDIA

There are various distention media available. The most popular once are normal saline and glycine. It is a common misconception that normal saline is safe than glycine but the rate of absorption of both is same under pressure. It is most important to monitor inflow and outflow at regular intervals, the values should be reported. One person in OT should be dedicated to note amount of fluid used and collected in suction bottle and inform surgeon and anesthetist if discrepancy is more than 500 mL in a healthy patient.

JAYPEE BROTHERS

Following table shows various medias available for hysteroscopy and their pros and cons:

Media type	*Maximum flow rate*	*Pros*	*Cons*	*Volume discrepancy*	*Complications*
CO_2 gas	• Cannot use laparoscopic insufflators • Flow rate of 40–60 mL/min • Maximum pressure 100 mm Hg	• Rapidly absorbed • Safe • Easy to use	Poor visibility in the presence of bleeding		High pressure and rates can cause cardiac arrhythmia and embolism and arrest
Normal saline and ringer lactate	Maximum pressure 80–100 mm Hg	• Isotonic • Conductive • Low viscosity • Safe with mechanical laser and bipolar energy	• Miscible with blood • Excellent conductivity • Not suitable for monopolar energy	1,000 mL	Fluid overload
3% sorbitol, 1.5% glycine, 5% mannitol	Maximum pressure 80–100 mm Hg	• Hypotonic • Low viscosity • Nonconductive • Miscible with blood but improved visibility over saline • Electrolyte-free	Hypotonic	Stop at 1,000 mL	Risk of volume overload and hyponatremia with intravascular absorption
Dextran 70		• High viscosity • Nonelectrolyte • Nonconductive • Immiscible	Highly viscus difficult to deliver	Stop at 500 mL	• Allergic reactions and anaphylaxis • Fluid overload • Disseminated intravascular coagulation • Destruction of instruments

JAYPEE BROTHERS

Technique for optimal cavity distention: Use medium to dilate the cervix for entry, aim for continues flow, limit amount of trauma to the cavity, cavity distention pressure usually limited to 50 mm Hg because of pain.

Prevention of fluid overload: Use appropriate distention media and delivery systems, keeping the operative time to minimum, keeping fluid pressure below 80 mm Hg, accounting of fluid balance to be done. Procedure must be abandoned, if the deficit raises 1.5 L or there is evidence of venous congestion.

FLUID DELIVERY SYSTEMS

Gravity Assisted

Positive pressure bags: BP cuffs, Medex pressure bags **(Fig. 6)**. They are simple and economical, widely used, need vigilant staff to prevent air embolism, fluid overload, overdistention of uterine cavity. But frequent collapse of cavity can occur while changing bottles and becomes difficult to maintain inflow and outflow chart.

Pressure cuff: There is pressure bag with pressure meter. The pressure has to be maintained manually. Ideally a pressure of 80–120 mm Hg is utilized.

Hysteromat or Endomat: It is automated fluid delivery systems. A monitored unit that automatically controls a constant flow of fluid entering the cavity. It is easy to calculate input of media with this equipment. Ideally the pressure of 80–120 mm Hg is utilized. It reduces the chance of fluid overload, maintains the optimum intrauterine cavity and reduces the chances of spillage **(Fig. 7)**.

Fluid overload initial symptoms: In conscious patient—nausea, vertigo, confusion, disorientation. But in patients with general anesthesia, transient



Fig. 6: Pressure bag.

JAYPEE BROTHERS



Fig. 7: Hysteromat.

hypertension and bradycardia followed by hypotension and tachycardia are only signs.

MONITORING DURING HYSTEROSCOPY

To avoid these complications, we need safe monitoring with the use of multipara monitor—temperature, pulse, BP, RR, ECG, SPO_2, end-tidal CO_2 ($ETCO_2$) monitors, intraoperative spirometry, etc. Input and output monitoring with fluid accountancy is a very important aspect in hysteroscopy. Postoperative recovery room monitoring with trained staff is needed to detect and treat the complications at the earliest.

INDICATIONS FOR HYSTEROSCOPY

The indications for hysteroscopy are increasing with widespread availability of the facility and increasing awareness among gynecologists and patients. Hysteroscopy is indicated in following patients:

- Pre-IVF or infertility evaluation
- Heavy menstrual bleeding not responding to medical management
- Recurrent IVF or implantation failure
- Surgery for intrauterine fibroid, polyp, septum
- Forgotten or missing IUD or removal of foreign body
- Proximal tubal block for tubal cannulation
- Recurrent miscarriage
- Removal of retained products of conception
- Asherman's syndrome (intrauterine adhesions)
- Suspected endometrial hyperplasia and carcinoma
- Hysteroscopic-guided PRP endometrial injection
- Endometrial ablation and transcervical resection of the endometrium (TCRE).

JAYPEE BROTHERS

PATIENT PREPARATION FOR HYSTEROSCOPY

Diagnostic hysteroscopy is a daycare procedure, patients are usually admitted on the morning of procedure. Preoperative diagnosis should be established with clinical examination and transvaginal or transabdominal USG. Routine blood investigations are required for fitness point of view. The procedure is done empty stomach at least four hours.

Antibiotic prophylaxis is given prior to diagnostic or operative hysteroscopy. Diagnostic hysteroscopy although is simple procedure, can be disastrous, so counseling of patient regarding nature of procedure, what finding to expect during procedure, what are benefits of procedure and possible complication should be done. Even when a patient is taken for diagnostic hysteroscopy, all preparations should be done for operative hysteroscopy in the same sitting. Proper preoperative counseling and consent is necessary.

Anesthesia

Hysteroscopic procedures can be done under local, spinal or general anesthesia depending on the types of procedure and complexity of surgery.

Position for Hysteroscopy

The position should be dorsal lithotomy position. Sterile cleaning and draping should be done.

Hysteroscopy Procedure

Hysteroscopy involves introduction of rigid or flexible hysteroscope via cervix into uterus. It is attached to a camera along with sheaths that allows distending media to enter the uterine cavity. Uterine cavity is inspected systematically viewing all the walls of uterus, both ostia are visualized, their relation with uterine cavity is also noted. Falloposcopy can be done with flexible hysteroscope to visualize the fallopian tubes, if available. Falloposcopy is not done routinely.

If any intrauterine pathologies are found, like polyps, fibroid, septum, intrauterine adhesions, they can be treated in the same sitting.

COMPLICATIONS OF SURGERY

Common complications are false passage, uterine perforation, hemorrhage and inability to dilate the cervix. Most complications occur during dilatation of cervix, which can be avoided by the use of office hysteroscopy.

Delayed complications: Infection, discharge, adhesion formation, infertility, etc.

JAYPEE BRPTHERS



Printed in India

Available at all medical bookstores
or buy online at www.jaypeebrothers.com

JAYPEE BROTHERS
Medical Publishers (P) Ltd.
EMCA House, 23/23-B, Ansari Road,
Daryaganj, New Delhi - 110 002, INDIA
www.jaypeebrothers.com

Join us on facebook.com/JaypeeMedicalPublishers

Shelving Recommendations
OBSTETRICS & GYNECOLOGY

ISBN 978-93-5696-125-8