65th All India Congress of
Obstetrics & Gynaecology

AICOG 2023 Workshop Manual

Preventive Oncology

Series Editors
Bhaskar Pal
Basab Mukherjee
Dibyendu Banerjee
Kusagradhi Ghosh

Volume Editors
Dipanwita Banerjee
Ranajit Mandal

aicog 2023 | Kolkata
Creating Tomorrow Together

Organized by:
The Bengal Obstetric and Gynaecological Society
04–08 January 2023
Biswa Bangla Mela Prangan, Kolkata

JAYPEE

Contents

1. **Guidelines on Cervical Cancer Screening 1**
   Priya Ganeshkumar
2. **Steps of Colposcopy and Documentation of Findings..... 7**
   Saritha Shamsunder, Priyanka Pangtey
3. **Management of Cervical Intraepithelial Neoplasia 13**
   Ranajit Mandal, Manisha Vernekar, Puja Chatterjee, Sreeya Bose
4. **Lessons Learnt from the HPV Vaccination Programs with Special Reference to India: Implications for Clinicians..... 20**
   Neerja Bhatla, Dipanwita Banerjee
5. **Quality Assurance in Colposcopy 25**
   Jaydip Bhaumik, Suchismita Bhaumik
6. **Artificial Intelligence: Linked Technology to Prevent Cervical Cancer..... 30**
   Walter Prendiville
7. **Newer Colposcopy Devices 36**
   Jyoti Meena, Chandrima Ray
8. **Global Breast Cancer Initiative (GBCI): A Global Effort to Tackle the Rising Burden of Breast Cancer 43**
   VC Ravindran, Krishna Nadha Pai, Harsha Gangadharan, Partha Basu
9. **Scope of Ovarian Cancer Screening 50**
   Uma Singh, Sabuhi Qureshi, Chitrangada Gupta
10. **Genetic Testing for Hereditary Breast and Ovarian Cancer: BRCA and Beyond 54**
    Niharika Dhiman, Seema Singhal
11. **Screening for Endometrial Cancer..... 60**
    Sneha Rajgopal, Amita Maheshwari
12. **Precancerous Lesions of Vulva and Vagina..... 67**
    Bhagyalaxmi Nayak, SK Giri

Chapter 2

Steps of Colposcopy and Documentation of Findings

Saritha Shamsunder, Priyanka Pangtey

INTRODUCTION

WHO has given a call for Elimination of cervical cancer by 2030 with 90% vaccination, 70% screening and 90% treatment of screen positive women. A standard method of triage of screen positive women is by Colposcopy. To perform colposcopy one must be trained and be prepared which is the key to a smooth and rewarding colposcopic examination. Treatment should be offered and carried out at the same visit if possible to minimize loss to follow-up.

Various types of colposcopes are available like Binocular and Digital. Images can be taken for comparison or even discussion if required (telemedicine). Further for peripheral settings, portable colposcopes are also available.

STEPS OF COLPOSCOPY

Following are the steps of performing colposcopy.

- *When to perform?*
  The best time perform Colposcopy is during the post menstrual period till day 8 of menses. During this time there is no chance of pregnancy. Also there is mucoid discharge which acts as a refractive medium and the os is slightly open which helps as it provides better visualization of the transformation zone.
- *Examination table*
  For colposcopic examination, a couch with adjustable height, recline, leg support, and space for an instrument tray is ideal. However, one can perform colposcopy on an ordinary gynecological examination table as well.
- *Speculum*
  The woman is asked to adopt a lithotomy position. She is asked to move down the couch so that her buttocks are just over the edge of the examination table. Pass the speculum comfortably and position it so that the cervix is fully visible in a plane perpendicular to the colposcopic

JAYPEE BROTHERS



Fig. 1: Grave speculum

line of vision. A metal bivalve speculum [e.g., Cusco speculum, Graves speculum **(Fig. 1)**] is used. A little gel lubricant or warm water should allow smooth passage through the introitus. If treatment is required, then the speculum should have a suction tube on the underside of its anterior blade so that the smoke is evacuated immediately during the procedure - LLETZ (Large Loop Excision of Transformation Zone). If the woman has lax vaginal walls, one can surround the speculum with a cut finger of a large glove or a condom.

- *Initial assessment*
  We then have to examine the cervix and comment on the adequacy of the examination.
  - For any signs of infection (viral, fungal, or bacterial)
  - For any visible lesion (e.g., leukoplakia and lesion)
  - For any areas suspicious of invasion
- *Low-power and high-power view*
  Once the cervix is fully visible, apply saline to wash away any mucoid discharge if present. This step must be performed gently but thoroughly and be cautious not to cause any injury and epithelial bleeding. The cervix is then visualized under green filter which helps in better visualization of the blood vessels as they stand out as black lines. Once must make note of any abnormal vessels. Normal vessels have branching patterns which are at acute angles and have a central stem from which smaller vessels branch out. While abnormal vessels have truncated branches and even uneven calibers **(Figs. 2A and B)**.

We then apply 5% freshly prepared acetic acid liberally using a cotton swab. This step must be performed gently so as not to affect the epithelium. If the mucus has not all been wiped away, it may give a false impression

JAYPEE BROTHERS

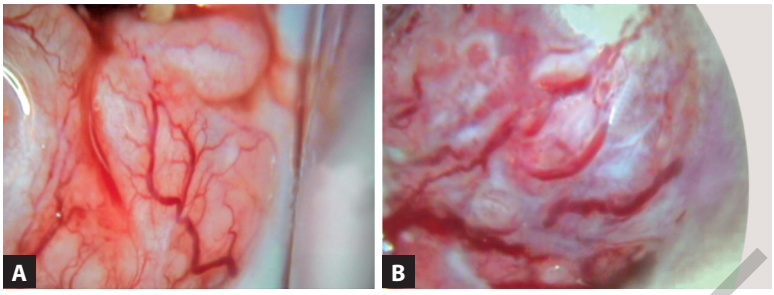

Figs. 2A and B: Vessel pattern on colposcopy. (A) Normal vessel pattern and (B) Abnormal vessel pattern

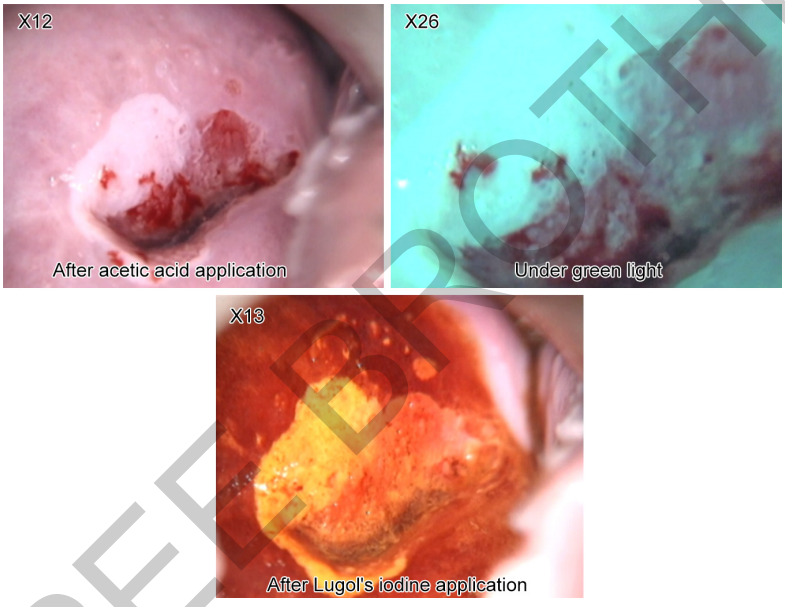

Fig. 3: Colposcopic images

of non-uptake of acetic acid. We then have to switch on the timer and wait for 1 minute. After 1 minute, we examine the cervix and upper vagina for any acetowhite areas. The cervix is first visualized under low-power magnification. Note is made of the transformation zone (TZ). The TZ is of three types.[1] If the TZ is type 1, then the SCJ will be visible on the ectocervix. But if not, we then use a cotton swab or endocervical speculum to visualize the transformation zone. If the TZ is visualized with manipulation, it is a type 2 TZ. If not visualized even after manipulation, it is termed as TZ type 3.

The transformation zone is examined and the old squamocolumnar junction is noted. Accordingly the type of transformation zone is labelled. The acetowhite areas are graded as per scoring systems (e.g., Reid's Colposcopic score and Swede score). These are then examined under high power and under green filter **(Fig. 3)**.

JAYPEE BROTHERS

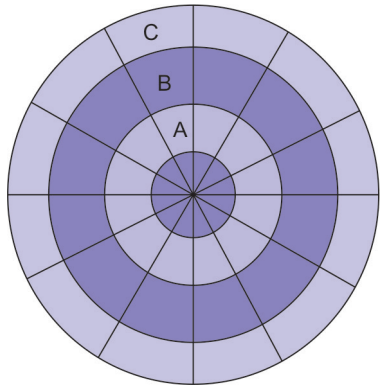

Fig. 4: Hammond's graph—(A) Endocervix, (B) Transformation zone, and (C) Ectocervix

Lugol's iodine is then applied. Normal squamous epithelium takes up a mahogany brown color whereas dysplastic epithelium will be unstained **(Fig. 3)**. We document the findings by the IFCPC 2011 nomenclature and score the lesion. The location of the lesion can be plotted using Hammond's graph of cervix **(Fig. 4)** or four quadrant division of cervix for pictorial representation. If any suspicious lesion is present it can be biopsied. Further the woman can be offered treatment with ablative of excisional methods as per the calculated score.

DOCUMENTATION OF FINDINGS

Once the woman is examined, the findings must be documented using a standard format.

As a standard, IFCPC (International Federation of Cervical Pathology and Colposcopy) 2011 nomenclature is used for documenting the findings.

The IFCPC terminology incorporates the following:[2]

TABLE 1: IFCPC nomenclature[2]

General assessment	• Adequate/inadequate for the reason ...(i.e., cervix obscured by inflammation, bleeding, scar) • *Squamocolumnar junction visibility:* Completely visible, partially visible, not visible • Transformation zone types 1, 2, 3
Normal colposcopic findings	• Original squamous epithelium: – Mature – Atrophic • Columnar epithelium – Ectopy • Metaplastic squamous epithelium – Nabothian cysts – Crypt (gland) openings • Deciduosis in pregnancy

Contd...

JAYPEE BROTHERS

Contd...

Abnormal colposcopic findings	*General principles*	• *Location of the lesion:* Inside or outside the T-zone, Location of the lesion by clock position • *Size of the lesion:* Number of cervical quadrants the lesion covers, size of the lesion in percentage of cervix	
	Grade 1 (Minor)	• Thin aceto-white epithelium • Irregular, geographic border	• Fine mosaic • Fine punctation
	Grade 2 (Major)	• Dense aceto-white epithelium • Rapid appearance of acetowhitening • Cuffed crypt (gland) openings	• Coarse mosaic • Coarse punctation • Sharp border, • Inner border sign • Ridge sign
	Non-specific	Leukoplakia (keratosis, hyperkeratosis), Erosion Lugol's staining (Schiller's test): stained/non-stained	
Suspicious for invasion		Atypical vessels *Additional signs:* Fragile vessels, irregular surface, exophytic lesion, necrosis, ulceration (necrotic), tumor/gross neoplasm	
Miscellaneous finding		• Congenital transformation zone • Condyloma • Polyp (Ectocervical/endocervical) • Inflammation	• Stenosis • Congenital anomaly • Post-treatment consequence • Endometriosis

The standard documentation as per IFCPC is followed and helps the colposcopist with a stepwise approach and covers all the parameters and not misses any findings.

The scoring system commonly used nowadays is Swede score. This scoring system includes the following parameters:[3]

TABLE 2: Swede score

	0	*1*	*2*
Acetowhite uptake	Zero or transparent	Shady, Milky (not transparent; not opaque)	Distinct, opaque white
Margins/ Surface	Diffuse	Sharp but irregular, jagged, 'geographical' satellites	Sharp and even, difference in surface level, including 'cuffing'
Vessels	Fine, regular	Absent	Coarse or atypical
Lesion size	<5 mm	5–15 mm or 2 quadrants	>15 mm or 3–4 quadrants/ endocervically undefined
Iodine staining	Brown	Faintly or patchy yellow	Distinct yellow
Total score (maximum 10)			

JAYPEE BROTHERS

Each parameter is scored between 0 and 2 and summed up at the end of examination which is interpreted to make a provisional diagnosis as follows:[1]

Final score		Colposcopic prediction of probable histology
0–4	:	Normal/CIN1
5–6	:	CIN2/CIN3
7–10	:	CIN3/suspected cancer

As per the score the patient can undergo biopsy or treatment which includes both ablative (Cryotherapy or thermal ablation) and excisional (LLETZ) procedures.

During the entire procedure one must ensure the woman's comfort and consent. The result of the colposcopy must be discussed with the woman and an informed decision and plan of management must be formulated.

REFERENCES

1. Basu P, Sankaranarayanan R (2017). Atlas of Colposcopy – Principles and Practice: IARC CancerBase No. 13 [Internet]. Lyon, France: International Agency for Research on Cancer. Available from: https://screening.iarc.fr/atlascolpo.php, accessed on [25-11-2022].
2. Prendiville W, Sankaranarayanan R. Colposcopy and Treatment of Cervical Precancer. Lyon (FR): International Agency for Research on Cancer; 2017. (IARC Technical Report, No. 45.) Chapter 7., Colposcopic terminology: the 2011 IFCPC nomenclature. Available from: https://www.ncbi.nlm.nih.gov/books/NBK568368/
3. Bowring J, Strander B, Young M, Evans H, Walker P. The Swede score: evaluation of a scoring system designed to improve the predictive value of colposcopy. J Low Genit Tract Dis. 2010 Oct;14(4):301-5. doi: 10.1097/LGT.0b013e3181d77756. PMID: 20885156.

JAYPEE BROTHERS



Printed in India

Available at all medical bookstores
or buy online at www.jaypeebrothers.com

JAYPEE BROTHERS
Medical Publishers (P) Ltd.
EMCA House, 23/23-B, Ansari Road,
Daryaganj, New Delhi - 110 002, INDIA
www.jaypeebrothers.com

Join us on facebook.com/JaypeeMedicalPublishers

Shelving Recommendations
OBSTETRICS & GYNECOLOGY

ISBN 978-93-5696-127-2