tailed information on dermatology books, visit our website www.ejaypee.com, for detailed information on dermatology books

2nd Edition



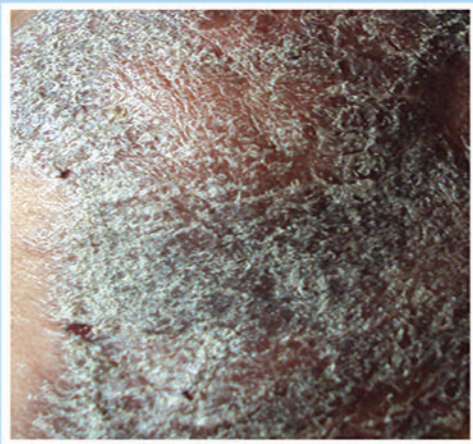


SNAPSHOTS IN DERMATOLOGY

Editors
S Sacchidanand
Savitha AS
Shilpa K

JAYPEE

SNAPSHOTS IN
DERMATOLOGY

Second Edition

Editors

S Sacchidanand
MD DVD DHA FRCP
Executive Director
Siddaganga Medical College & Research Institute
Vice Chancellor, Rajiv Gandhi University of Health Sciences (2018–2021)
Karnataka, India

Savitha AS
MD DNB FRGUHS MNAMS
Professor
Department of Dermatology
Sapthagiri Institute of Medical Sciences and Research Centre
Bengaluru, Karnataka, India

Shilpa K
MD(DVL) FRUGHS(Dermatosurgery)
Professor and Head
Department of Dermatology
Bangalore Medical College and Research Institute
Bengaluru, Karnataka, India

Associate Editor

Chaithra S
MD(Dermatology)
Assistant Professor
Sapthagiri Institute of Medical Sciences and Research Centre
Bengaluru, Karnataka, India



JAYPEE BROTHERS MEDICAL PUBLISHERS
The Health Sciences Publisher
New Delhi | London

JAYPEE **Jaypee Brothers Medical Publishers (P) Ltd**

Headquarters
EMCA House, 23/23-B
Ansari Road, Daryaganj
New Delhi 110 002, India
Landline: +91-11-23272143, +91-11-23272703
+91-11-23282021, +91-11-23245672
e-mail: jaypee@jaypeebrothers.com

Corporate Office
4838/24, Ansari Road, Daryaganj
New Delhi 110 002, India
Phone: +91-11-43574357
Fax: +91-11-43574314
e-mail: jaypee@jaypeebrothers.com

Overseas Office
JP Medical Ltd.
83, Victoria Street, London
SW1H 0HW (UK)
Phone: +44-20 3170 8910
e-mail: info@jpmedpub.com

EU GPSR Authorised Representative
Logos Europe, 9 rue Nicolas Poussin
17000, La Rochelle, France
Phone: +33 (0) 6 67 93 73 78
e-mail: contact@logoseurope.eu

Website: www.jaypeebrothers.com

Website: www.jaypeedigital.com

© 2025, Jaypee Brothers Medical Publishers

The views and opinions expressed in this book are solely those of the original contributor(s)/author(s) and do not necessarily represent those of editor(s) or publisher of the book.

All rights reserved. No part of this publication may be reproduced, stored or transmitted in any form or by any means, electronic, mechanical, photocopying, recording or otherwise, without the prior permission in writing of the publishers.

All brand names and product names used in this book are trade names, service marks, trademarks or registered trademarks of their respective owners. The publisher is not associated with any product or vendor mentioned in this book.

Medical knowledge and practice change constantly. This book is designed to provide accurate, authoritative information about the subject matter in question. However, readers are advised to check the most current information available on procedures included and check information from the manufacturer of each product to be administered, to verify the recommended dose, formula, method and duration of administration, adverse effects and contraindications. It is the responsibility of the practitioner to take all appropriate safety precautions. Neither the publisher nor the author(s)/ editor(s) assume any liability for any injury and/or damage to persons or property arising from or related to use of material in this book.

This book is sold on the understanding that the publisher is not engaged in providing professional medical services. If such advice or services are required, the services of a competent medical professional should be sought.

Every effort has been made where necessary to contact holders of copyright to obtain permission to reproduce copyright material. If any have been inadvertently overlooked, the publisher will be pleased to make the necessary arrangements at the first opportunity.

Inquiries for bulk sales may be solicited at: jaypee@jaypeebrothers.com

Snapshots In Dermatology* / *S Sacchidanand, Savitha AS, Shilpa K

First Edition: 2013

Second Edition: **2025**

ISBN: 978-93-5696-171-5

Printed in India

Contents

1. Acquired Bilateral Nevus of Ota-like Macules 1
2. Acanthosis Nigricans 4
3. Acne Keloidalis Nuchae 8
4. Acne Vulgaris 11
5. Acrochordon 17
6. Acrodermatitis Enteropathica 20
7. Actinic Cheilitis 24
8. Actinic Keratosis 27
9. Acute Generalized Exanthematous Pustulosis 31
10. Albinism 35
11. Alopecia Areata 38
12. Amyloidosis 43
13. Anagen Effluvium 47
14. Androgenetic Alopecia 49
15. Anetoderma 53
16. Angioedema 57
17. Angiokeratoma 60
18. Angioma 65
19. Angular Cheilitis 68
20. Antiphospholipid Syndrome 71
21. Aphthous Stomatitis 75
22. Ashy Dermatosis 79
23. Atopic Dermatitis 83
24. Bacillary Angiomatosis 88
25. Bacterial Vaginosis 91

26. Balanitis Xerotica Obliterans 94
27. Balanoposthitis 97
28. Basal Cell Carcinoma 100
29. Becker's Nevus 104
30. Behçet's Disease 107
31. Blastomycosis 111
32. Botryomycosis 114
33. Bowen's Disease 117
34. Bowenoid Papulosis 120
35. Bullous Pemphigoid 123
36. Café-au-lait Macule 128
37. Calcinosis Cutis 132
38. Calciphylaxis 136
39. Corns and Calluses 139
40. Candidiasis 143
41. Canities 147
42. Carbuncle 150
43. Cellulitis 153
44. Chancroid 157
45. Chromoblastomycosis 161
46. Cicatricial Alopecia 165
47. Cicatricial Pemphigoid 168
48. Condyloma Acuminatum 173
49. Confluent and Reticulated Papillomatosis 177
50. Congenital Syphilis 181
51. Contact Dermatitis 185
52. Cryoglobulinemia 188
53. Cryptococcosis 191
54. Cutis Laxa 196
55. Cylindroma 200

56. Cydnidae Pigmentation 203
57. Darier's Disease 206
58. Demodicidosis 212
59. Dermatitis Herpetiformis 215
60. Dermatofibroma 218
61. Dermatomyositis 221
62. Dermatosis Papulosa Nigra 226
63. Dermoid Cyst 229
64. Diabetic Dermopathy 232
65. Diaper Dermatitis 234
66. Dilated Pore of Winer 237
67. Discoid Lupus Erythematosus 240
68. Dowling–Degos Disease 245
69. DRESS Syndrome (Drug Reaction with Eosinophilia and Systemic Symptoms) 248
70. Ecthyma 250
71. Ectodermal Dysplasias 256
72. Eczema Herpeticum 260
73. Ehlers–Danlos Syndrome 263
74. Epidermolysis Bullosa 266
75. Erysipelas 272
76. Erythema Ab Igne 275
77. Erythema Elevatum Diutinum 278
78. Erythema Infectiosum 280
79. Erythema Multiforme 283
80. Erythema Nodosum 287
81. Erythrasma 290
82. Erythroderma 293
83. Exogenous Ochronosis 296
84. Figurate Erythemas 299

85. Fixed Drug Eruption 302
86. Folliculitis 306
87. Fordyce Disease 309
88. Fordyce Spots 312
89. Freckles 314
90. Furuncles 317
91. Gianotti–Crosti Syndrome 320
92. Glomus Tumor 323
93. Gonorrhea 326
94. Gottron's Syndrome 330
95. Graft-versus-host Disease 333
96. Gram-negative Folliculitis 337
97. Granuloma Annulare 339
98. Granuloma Faciale 344
99. Granuloma Venereum 347
100. Granulomatous Cheilitis 351
101. Grover's Disease 354
102. Hairy Tongue 357
103. Hand, Foot, and Mouth Disease 360
104. Hemangiomas 365
105. Henoch–Schönlein Purpura 370
106. Herpes Simplex 374
107. Herpes Zoster 379
108. Hidradenitis Suppurativa 383
109. Hirsutism 390
110. Histoplasmosis 397
111. Hyperhidrosis 400
112. Hypertrichosis 406
113. Ichthyosis 410
114. Idiopathic Guttate Hypomelanosis 416

115. Impetigo 421
116. Incontinentia Pigmenti 425
117. Kaposi's Sarcoma 429
118. Kawasaki Disease 433
119. Keloid 436
120. Keratoacanthoma 441
121. Keratolysis Exfoliativa 445
122. Keratosis Pilaris 449
123. Koilonychia 453
124. Leishmaniasis 455
125. Lentigo 459
126. Leukocytoclastic Vasculitis 463
127. Leukonychia 466
128. Leukoplakia 468
129. Lichen Nitidus 471
130. Lichen Planus 475
131. Lichen Sclerosus 481
132. Lichen Simplex Chronicus 486
133. Lichen Spinulosus 490
134. Lichen Striatus 493
135. Linear IgA Disease 496
136. Lipodystrophy 500
137. Lipoma 507
138. Lupus Vulgaris 510
139. Lyme Disease 514
140. Lymphangioma Circumscriptum 517
141. Lymphogranuloma Venereum 520
142. Lymphocytoma Cutis 524
143. Melanoma 526
144. Melasma 531

145. Melanocytic Nevi 534
146. Milia 537
147. Miliaria 540
148. Molluscum Contagiosum 544
149. Mongolian Spot 550
150. Monilethrix 553
151. Morphea 556
152. Mucormycosis 561
153. Mycetoma 563
154. Mycosis Fungoides 567
155. Necrobiosis Lipoidica 571
156. Netherton Syndrome 574
157. Neurofibromatosis 577
158. Nevus Anemicus 583
159. Nevus Comedonicus 585
160. Nevus Depigmentosus 588
161. Nevus Flammeus 591
162. Nevus of Ota and Ito 594
163. Nevus Sebaceous 597
164. Nevus Spilus 601
165. Nocardiosis 604
166. Nummular Dermatitis 607
167. Onychomycosis 610
168. Oral Hairy Leukoplakia 615
169. Osler–Weber–Rendu Syndrome 617
170. Pachydermoperiostosis 620
171. Pachyonychia Congenita 623
172. Paederus Dermatitis 627
173. Paget's Disease of Breast 630
174. Palmoplantar Keratodermas 633

175. Papular Urticaria 640
176. Parapsoriasis 643
177. Paronychia 647
178. Pediculosis 651
179. Piebaldism 658
180. Pellagra 662
181. Pemphigus 666
182. Perforating Disorders 672
183. Perioral Dermatitis 678
184. Periorbital Melanosis 681
185. Peutz–Jeghers Syndrome 684
186. Phrynoderma 687
187. Piedra 691
188. Pilar Cyst 694
189. Pilomatricoma 696
190. Pitted Keratolysis 700
191. Pityriasis Alba 704
192. Pityriasis Lichenoides Chronica 707
193. Pityriasis Rosea 710
194. Pityriasis Rubra Pilaris 714
195. Pityriasis Versicolor 718
196. Pityrosporum Folliculitis 722
197. Pityriasis Lichenoides Et Varioliformis Acuta 725
198. Poikiloderma 729
199. Polyarteritis Nodosa 731
200. Polymorphic Light Eruption 735
201. Pompholyx 738
202. Porokeratosis 740
203. Porphyrias 745
204. Progeria 752

205. Prurigo 754
206. Pruritic Urticarial Papules and Plaques of Pregnancy 757
207. Pseudofolliculitis Barbae 760
208. Pseudoxanthoma Elasticum 762
209. Psoriasis 765
210. Psoriatic Arthritis 771
211. Pterygium Unguis 775
212. Purpura Fulminans 778
213. Pustular Psoriasis 782
214. Pyoderma Faciale 786
215. Pyoderma Gangrenosum 788
216. Pyogenic Granuloma 791
217. Raynaud's Phenomenon 795
218. Reactive Arthritis 799
219. Rosacea 802
220. Roseola Infantum 807
221. Rubella 810
222. Rubeola 813
223. Sarcoidosis 816
224. Scabies 821
225. Scarlet Fever 825
226. Schamberg Disease 827
227. Scleredema 830
228. Sclerema Neonatorum 833
229. Scleroderma 835
230. Scrofuloderma 841
231. Sebaceous Cyst 844
232. Seborrheic Keratosis 847
233. Seborrheic Melanosis 851

234. Seborrheic Dermatitis 853
235. Sjögren's Syndrome 857
236. Solar Elastosis 860
237. Solar Lentigo 863
238. Spider Angioma 866
239. Spitz Nevi 868
240. Sporotrichosis 871
241. Squamous Cell Carcinoma 875
242. Staphylococcal Scalded Skin Syndrome 878
243. Stasis Dermatitis 881
244. Steatocystoma Multiplex 885
245. Stevens–Johnson Syndrome 889
246. Stiff Skin Syndrome 892
247. Striae 894
248. Subcorneal Pustular Dermatosis 898
249. Subcutaneous Zygomycosis 902
250. Sweet's Syndrome 904
251. Syphilis 908
252. Syringoma 914
253. Systemic Lupus Erythematosus 917
254. Telogen Effluvium 924
255. Terra Firma-Forme Dermatosis 928
256. Tinea 931
257. Tinea Capitis 940
258. Toxic Epidermal Necrolysis 945
259. Trichoepithelioma 949
260. Trichomycosis Axillaris 953
261. Trichorrhexis Nodosa 956
262. Trichotillomania 959
263. Tropical Acne 963

264. Tuberculides **965**
265. Tuberculosis Verrucosa Cutis **969**
266. Tuberous Sclerosis Complex **972**
267. Twenty Nail Dystrophy **980**
268. Uncombable Hair Syndrome **983**
269. Urticaria **986**
270. Urticaria Pigmentosa **990**
271. Varicella **993**
272. Vascular Malformation **997**
273. Venous Leg Ulcer **1001**
274. Verrucous Hemangioma **1004**
275. Viral Exanthem **1007**
276. Vitiligo **1012**
277. Verruca **1016**
278. Wooly Hair **1022**
279. Wrinkles **1025**
280. Juvenile Xanthogranuloma **1029**
281. Xanthoma **1032**
282. Xeroderma Pigmentosa **1037**
283. Zoon's Balanitis **1040**

Index **1043**

4 Acne Vulgaris

➲ SYNONYMS

Pimples.

➲ HISTORY

Emperor Justinian's physician Aetius Amidenus used the term "acne" for the first time during the 6th century AD. It is derived from the Greek word "acme" meaning "peak".

➲ ETIOLOGY

The pathogenesis of acne is multifactorial, but four basic steps have been identified.

1. Follicular epidermal hyperproliferation
2. Excess sebum production
3. Inflammation
4. The presence and activity of *Propionibacterium acnes*

➲ EPIDEMIOLOGY

Most commonly seen in 12–25-year age group (puberty). Both sexes are equally affected.

➲ CLINICAL FEATURES

Lesions of acne vulgaris are seen on the sebaceous gland-rich body regions, mainly the face, mid-chest, back, shoulders, and upper arms. Comedones are characteristic early lesions of acne. A comedone is a plug of sebaceous and keratinous material

JAYPEE BROTHERS

lodged in the opening of a hair follicle. The inflammatory lesions of acne originate with comedo formation but then expand to form papules, pustules, nodules, and cysts of varying severity. Erythematous papules range from 1 to 5 mm in diameter **(Figs. 1 to 3)**.

- *Grade I (mild)*: Comedones, occasional papules
- *Grade II (moderate)*: Comedones, many papules, few pustules
- *Grade III (severe)*: Predominantly pustules, nodules and abscesses
- *Grade IV (cystic)*: Mainly cysts or abscesses, widespread scarring

Variants of acne are neonatal, infantile, juvenile acne, acne excoriee, senile acne, drug-induced, chloracne, mechanical acne, Mallorca acne, tropical acne, acne tarda, pomade acne, hippie's acne, etc. Acne conglobata, acne fulminans, pyoderma faciale, and gram-negative folliculitis are severe forms of acne.



Figure 1: Inflammatory papules and nodules over the cheek.

JAYPEE BROTHERS



Figure 2: Ice pick, box scars, and rolling type of acne scars.

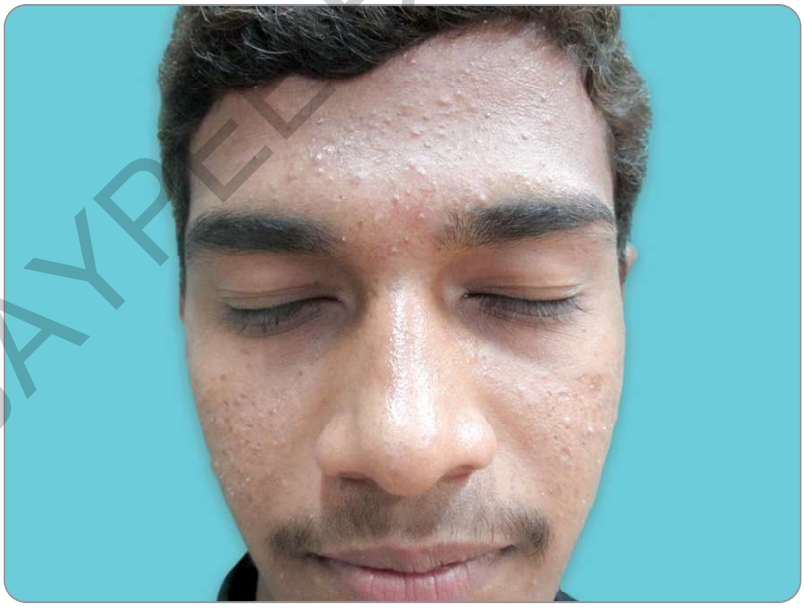

Figure 3: Grade II acne vulgaris with multiple papules and few comedones.

JAYPEE BROTHERS

➲ SYNDROMES ASSOCIATED

- Hyperandrogenism, insulin resistance-acanthosis nigricans (HAIR-AN)
- Apert syndrome
- Stein Leventhal syndrome
- Pyogenic arthritis, pyoderma gangrenosum, and acne (PAPA)
- Synovitis, acne, palmoplantar pustulosis, hyperostosis, and osteitis (SAPHO) syndrome

➲ DERMOSCOPY

- *Comedonal acne*: Dilated, roundish, central pore filled with a white-yellow or brown-yellow plug (more evident in open comedones) corresponding to oxidized keratin
- *Inflammatory acne*: Round structures with well-defined white center and thin brown borders and erythematous periphery
- *Pustular acne*: Well to ill-defined white-yellowish structure (corresponding to purulent material) with erythematous periphery

➲ HISTOPATHOLOGY

In early lesions, microcomedones show a mildly distended follicle with a narrowed follicular opening impacted by shed keratinocytes. In closed comedones, the degree of follicular distension is increased, and a compact cystic structure forms. Open comedones have broad, expanded follicular ostia and greater follicular distension. The sebaceous glands are typically atrophic or absent. A mild perivascular mononuclear cell infiltrate circles the expanding follicle. As the follicular epithelium distends, the cyst (keratin, hair, and bacteria) ruptures and releases its contents into the dermis inducing a marked and brisk inflammatory response. Plenty of neutrophils appear in the pustular stage. As the lesion matures, foreign body granulomatous inflammation engulfs the follicle, and end-stage scarring results.

JAYPEE BROTHERS

➲ DIFFERENTIAL DIAGNOSIS

- *Rosacea*: Conspicuous absence of comedones, there is the presence of erythema and telangiectasias; photosensitivity, flare seen with spicy food, hot beverages, emotions
- *Oil acne*: More of hyperpigmented monomorphic papules, extremities, and trunk more commonly involved
- *Senile acne*: Large porous comedones with black keratinous plug, absence of inflammatory lesions
- *Drug-induced acne*: Monomorphic papules seen, absence of comedones
- Lupus miliaris disseminatus faciei
- Sycosis barbae
- *Demodex folliculitis*: Absence of comedones, pruritic lesions, and demonstration of mite
- *Sebaceous hyperplasia*: Yellowish to white papules, absence of other acne lesions
- *Angiofibroma*: Skin-colored papules concentrated in nasolabial folds
- *Warts*: Flat skin colored to hyperpigmented flat papules, Koebner's phenomenon seen

➲ COMPLICATIONS

Scarring, hyperpigmentation, depression and suicidal ideation, anxiety, psychosomatic symptoms (pain and discomfort), embarrassment, body dysmorphic disorder, and social inhibition.

➲ TREATMENT

- Comedones are treated with topical retinoids viz adapalene 0.1% gel, tazarotene 0.1% cream, tretinoin 0.1 and 0.025% at night, salicylic acid 2% wash, and benzoyl peroxide gel 2.5–5%.
- For papules and pustules, topical agents used are azelaic acid 10 and 20%, antibiotics clindamycin 1%, erythromycin 1.5, 2, and 3 %, and nadifloxacin 1%.

JAYPEE BROTHERS

- *Other topical agents*: Dapsone 5%, sodium sulfacetamide 10%, and sulfur 1–10%

Systemic drugs for acne include:

Tetracyclines—250 mg qid, erythromycin 1 g/day, minocycline 50–100 mg bd, doxycycline 100 mg, clindamycin 300–450 mg/day, lymecycline 150–300 mg/day, sulfamethoxazole + trimethoprim 800/160 mg bd (resistant acne).

Isotretinoin 0.5 mg–1 mg/kg/day is a drug of choice for Grade 4 acne. System to manage accutane-related teratogenecity (SMART) program.

Hormonal therapy: Hormonal agents provide effective second-line treatment in women with acne regardless of underlying hormonal abnormalities. Spironolactone 100–200 mg/day, flutamide 250 mg bd, and oral contraceptive drugs are used.

Physical modalities: Comedone extraction, chemical peeling (glycolic acid, salicylic acid, and Jessner's solution), intralesional corticosteroids (0.05–0.25 mL of triamcinolone acetonide) in nodulocystic acne, cryotherapy, lasers, and light sources.

➲ PROGNOSIS

The disease usually runs a self-limiting course, remitting in the late twenties or early thirties. During the period of activity too, the course is variable with spontaneous flare-ups and remissions.

➲ SUGGESTED READINGS

1. Bhat YJ, Latief I, Hassan I. Update on etiopathogenesis and treatment of Acne. Indian J Dermatol Venereol Leprol. 2017;83:298-306.
2. Arshdeep, De D. What's new in the management of acne? Indian J Dermatol Venereol Leprol. 2013;79:279-87.

JAYPEE BROTHERS

for detailed information on dermatology books, visit our website www.ejaypee.com, for detailed information on dermatology

SNAPSHOTS IN DERMATOLOGY

Salient Features

- "Snapshots in Dermatology" aims to help beginners quickly recognize common skin conditions
- Dermoscopic details are given for better understanding
- More than 300 clinical images have been included
- "Suggested Readings" have been added for further understanding
- The book serves as a quick reference tool during ward rounds and outpatient clinic visits.



S Sacchidanand MD DVD DHA FRCP is a distinguished dermatologist and medical educator in India. Born in 1960, he excelled academically, earning his MBBS from JNMC Belgaum, securing a Gold Medal in Anatomy and later completing his MD in Dermatology. His career saw him rise from Lecturer in 1991 to Head of the Department at BMCRI in 2005, where he pioneered advancements like the first Dermatosurgery OT and Dermatology ICU in a government institution. He also served as Registrar (Evaluation) at RGUHS, Director of Medical Education for Karnataka, and Vice-Chancellor of RGUHS (2018–2021). A prolific academician, he has authored 15 books, published over 130 research papers, and was the first Indian researcher audited by USFDA. He introduced India's first government hair transplantation program and led several dermatology fellowships. Honored with prestigious awards like the Dr. B. C. Roy Award, he remains a mentor and an inspiration in the medical field.



Savitha AS MD DNB FRGUHS MNAMS is a Professor of Dermatology at Sapthagiri Institute of Medical Sciences and Research Centre, specializing in dermatosurgery, trichology, and onychology. She has authored 110 chapters, edited 12 books, and delivered over 200 lectures globally. A recipient of multiple awards, she has played key roles in organizing major dermatology conferences. She has served in executive positions in IADVL and is the President–Elect of IADVL Karnataka.



Shilpa K MD(DVL) FRUGHS(Dermatosurgery) is a Professor and Head of Dermatology at Bangalore Medical College and Research Institute, Bengaluru, Karnataka, India, specializes in clinical dermatology, dermatosurgery, and trichology. She has authored 30+ chapters, 80+ publications, and co-edited multiple dermatology textbooks. A recipient of ACSI awards, she has delivered 60+ lectures and played key roles in major dermatology conferences.

Buy from ejaypee

JAYPEE BROTHERS

Shelving Recommendation
DERMATOLOGY

ISBN 978-93-5696-171-5

9 789356 961715